

Pre-implant screening guided by cardiac silhouette fluoroscopy: a way to increase eligibility for the subcutaneous implantable cardioverter-defibrillator: a case report

Victoria Galizia Brito *, Aina Bibiloni Cladera ,
Maria del Carmen Exposito Pineda , and Carlos Grande Morales

Department of Cardiology (Cardiac Arrhythmia and Electrophysiology Unit), Hospital Universitario Son Espases, Carretera de Valldemossa 79, Palma de Mallorca, Spain

Received 24 May 2020; first decision 9 June 2020; accepted 31 October 2020

Background

Suitability for the subcutaneous implantable cardioverter-defibrillator (S-ICD) depends on a pre-implant electrocardiogram (ECG) screening to ensure appropriate sensing of electrical cardiac signals. Screening is performed positioning electrodes guided by chest surface anatomical landmarks.

Case summary

We report a case of a patient with an initially negative conventional automatic screening for S-ICD, who underwent a modified screening guided by cardiac silhouette position, as seen under fluoroscopy, resulting in eligibility for the S-ICD.

Discussion

The S-ICD reduces endovascular infection risk, providing therefore a potentially safer alternative in patients with prosthetic valves. It might be reasonable to perform a pre-implant ECG screening guided by fitting the cardiac silhouette in the shock vector, as this modified screening position could increase eligibility in patients who may benefit from S-ICD therapy such as the one presented.

Keywords

Implantable defibrillators • Subcutaneous ICD • Sudden cardiac death • X-ray • Case report • Valvular heart disease

Learning points

- Pre-implant electrocardiogram (ECG) screening must be done to assess eligibility for the subcutaneous implantable cardioverter-defibrillator (S-ICD) therapy, as recommended by the manufacturer, but not every chest anatomy and heart geometry are exactly the same.
- The exact position of the device in order to obtain an adequate shock vector can be different in each patient.
- Performing pre-implant ECG screening guided by fitting the cardiac silhouette in the shock vector could be useful as it might increase eligibility for S-ICD.

* Corresponding author. Tel: +34 611101865, Email: victoria.galizia@ssib.es; vgaliziabrito@gmail.com

Handling Editor: Habib Rehman Khan

Peer-reviewers: Efsthathios Papatheodorou; Konstantinos Iliodromitis; Constantinos Bakogiannis

Compliance Editor: Edwina McNaughton

Supplementary Material Editor: Ross Thomson

© The Author(s) 2020. Published by Oxford University Press on behalf of the European Society of Cardiology.

This is an Open Access article distributed under the terms of the Creative Commons Attribution Non-Commercial License (<http://creativecommons.org/licenses/by-nc/4.0/>), which permits non-commercial re-use, distribution, and reproduction in any medium, provided the original work is properly cited. For commercial re-use, please contact journals.permissions@oup.com

Introduction

Patients with prosthetic heart valves are considered at high risk to develop infectious endocarditis (IE).¹ The subcutaneous implantable cardioverter-defibrillator (S-ICD) is a completely extravascular device and thus drastically reduces the risk of blood-stream infection, therefore providing a potentially safer alternative to transvenous implantable cardioverter-defibrillator (TV-ICD) in this particular group of patients.

The current S-ICD (Emblem[®] MRI S-ICD A219 model—Boston Scientific) uses a morphology-based algorithm that relies on subcutaneous rather than endocardial electrogram sensing.² The system detects cardiac rhythm between the two sensing electrodes (on both sides of an 8-cm shock coil) or from either of them and the can. Consequently, it can construct three possible sensing vectors: primary vector (between the proximal sensing electrode and can), secondary vector (between the distal sensing electrode and can), and alternate vector (between the distal and proximal sensing electrodes). In order to assess eligibility for the S-ICD and avoid implantation in patients who are susceptible to sensing problems and inappropriate shocks in the future, the manufacturer recommends performing a pre-implant electrocardiogram (ECG) screening. Screening surface electrode position is guided by surface anatomical landmarks (SAL)³ but the anatomy and heart geometric position is not the same in every patient.⁴ Performing pre-implant screening guided by heart silhouette fluoroscopy, may increase eligibility in patients who would otherwise be excluded because of an initially negative screening.

Timeline

2003	Rheumatic mitral valve disease (severe stenosis and regurgitation)
2008	Mitral mechanical valve replacement
25 February 2018	First automatic electrocardiogram screening guided by anatomical landmarks: negative result
3 March 2018	Hospital admission
4 March 2018	Automatic screening guided by fluoroscopy: acceptable result followed by subcutaneous implantable cardioverter-defibrillator implant
5 March 2018	Hospital discharge
30 March 2018	First follow-up. No T-wave oversensing in the exercise test
15 January 2020	Last follow-up with no complications

Case presentation

We present a 66-year-old male patient with a history of mechanical mitral valve replacement due to mitral valve disease (severe stenosis and regurgitation) caused by rheumatic heart disease. He developed left ventricular dysfunction with left ventricular ejection fraction of 33%, narrow QRS, New York Heart Association functional class II

and was receiving optimal medical treatment (bisoprolol 10 mg daily, spironolactone 25 mg daily, sacubitril 97 mg/valsartan 103 mg twice daily, furosemide 40 mg twice daily). The patient had no other relevant past medical history.

In the outpatient clinic, a conventional pre-implant ECG screening was performed to determine eligibility for an S-ICD implant with the automatic screening tool: the only suitable sensing vector, both in left and right parasternal lead position (LPP/RPP), was the primary vector but only in supine position. All the others failed the test. For this reason, the option of an S-ICD implant was at first excluded.

The patient was admitted for implantable cardioverter-defibrillator (ICD) implant 1 week after. At the time of admission, he did not present any heart failure signs or symptoms. Once in the operating room, before undergoing prepping and sterile draping for device implantation, an S-ICD demonstration system (Figure 1) was positioned and secured with adhesive tape on the patient's chest. The device position was checked by fluoroscopy, and it was subsequently repositioned to fit the cardiac shadow outline in a simulated defibrillation vector. Once this was achieved, the system position was drawn onto the chest with demographic marker pen and surface electrodes were positioned to match the sensing electrodes' intended position, the distal sensing tip and the can. A modified screening was performed using these landmarks (Figure 2). This adjusted screening resulted in a positive outcome in LPP, with a suitable secondary sensing vector both in supine and standing/sitting position.

As the patient was at high risk of ventricular arrhythmias and sudden cardiac death (SCD), and considering his valvular disease history and therefore higher risk of intravascular lead infection, it was decided that S-ICD would be the most adequate option. This took into account the favourable fluoroscopy-guided screening result. The risks and benefits of the procedure were discussed with the patient. He agreed to the procedure and signed the consent form.

The S-ICD was implanted (Emblem S-ICD 219) guided by the pen landmarks and immediately afterwards, defibrillator threshold test was performed [an induced ventricular fibrillation (VF) was terminated in 12 s, with a 65 Joules energy shock with an impedance of 67 Ohm]. Following implantation, interrogation of the S-ICD confirmed that the secondary sensing vector was suitable. The patient did not suffer any procedure-related complications and was discharged the next day. We observed no T-wave oversensing in the exercise test done on the first follow-up 3 weeks after the procedure. From then on, we scheduled follow-up visits every 3 months (through remote device monitoring system) and in-office visits every year. After 22 months follow-up, no ventricular arrhythmias occurred and he did not present with sensing problems nor had he received any shocks.

Discussion

The S-ICD has emerged as an attractive alternative to TV-ICD for SCD prevention in a selected subgroups of patients (e.g. young patients, after device infection, difficult venous access, arrhythmogenic syndromes) and made its way into clinical practice guidelines.⁵ Prosthetic valve IE is a serious, life-threatening complication,⁶ this is why, the S-ICD might also be an advantageous option in patients with prosthetic heart valves as it does not bear the risk of endovascular




Figure 1 Demonstration device.

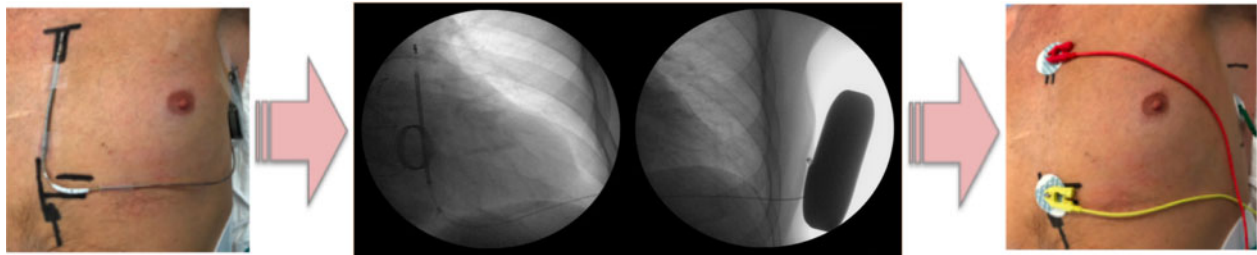


Figure 2 Step by step of the fluoroscopy-guided screening.

infection and therefore reduces dramatically device-related IE risk, compared to transvenous devices.

Although the S-ICD implant is essentially guided by SAL, and although no fluoroscopy is required, there is the possibility of using it to confirm the shock vector is adequately crossing the heart silhouette. There are a number of studies that mention performing a few seconds of fluoroscopy during the procedure. In the pivotal study by Bardy *et al.*² the S-ICD was implanted only using SAL and the device position was observed under fluoroscopy after the pocket was closed and only once testing was complete. In one patient, the device failed to terminate the induced VF at maximum output and the subsequent fluoroscopy image showed the electrode was laterally malpositioned. Subsequently, there have been reports of fluoroscopy done after a failed defibrillation threshold testing, accounted for by the mass of ventricle in between the defibrillation vector not being optimized due to migration of the electrode.⁷

There are a number of studies that report using a brief time of fluoroscopy before surgical prepping, placing a demonstration device on the patients' chest to assure an adequate system position and

therefore an optimal defibrillator vector.⁸⁻¹⁰ There are other studies that refer to the use of fluoroscopy to determine incision site to position the device in relation to the heart silhouette.¹¹ A successful S-ICD implant was described in a patient with dextrocardia due to previous thoracic surgery, implanting the can in the right chest wall. Investigators highlight the importance chest X-ray to observe cardiac position when planning the procedure in these patients as they might present distortion of the chest anatomy.¹² Regarding patients with hypertrophic cardiomyopathy, there is one study describing an unconventional position of the S-ICD in a patient with a negative first screening. The ECG screening was repeated positioning the S-ICD pulse generator in a more dorsal location and the lead in RPP and one vector was found to be suitable.¹³

Nowadays, the strive to achieve near-zero fluoroscopy interventional procedures has become increasingly popular; hence, the possibility of performing an ICD implant without using X-ray is one appealing attribute of the S-ICD. Despite the fact that suggesting the use of fluoroscopy when it is not absolutely necessary may, at first, seem unreasonable, the radiation dose used in this procedure was

remarkably low (effective dose of 0.054 mSv). We are aware that radiation exposure is an important hazard of device implantation; that is why, all operators aimed to minimize the radiation doses, following recommendations of the major cardiovascular societies.¹⁴

In summary, we present a case of a patient with an initially negative pre-implant ECG screening for S-ICD who was deemed as not being an adequate candidate for the therapy. Performing a modified screening guided by fluoroscopy view of the heart silhouette made this patient eligible for the S-ICD system. Hence, both pre-implant screening, as well as the definitive position of the S-ICD system may and certainly should vary depending on the actual position of the heart in each individual patient. It might be reasonable to perform a pre-implant screening guided by fitting the cardiac silhouette in the shock vector, as it could increase eligibility in patients who may benefit from S-ICD therapy such as the one presented.

Lead author biography



Dr Victoria Galizia Brito was born in 1989 in Buenos Aires, Argentina. She obtained her MD degree in 2013 and completed her training to become a cardiologist at Instituto Cardiovascular de Buenos Aires. She is currently an EP and device fellow at Hospital Universitario Son Espases in Spain.

Supplementary material

[Supplementary material](#) is available at *European Heart Journal - Case Reports* online.

Slide sets: A fully edited slide set detailing this case and suitable for local presentation is available online as [Supplementary data](#).

Consent: The author/s confirm that written consent for submission and publication of this case report including image(s) and associated text has been obtained from the patient in line with COPE guidance.

Conflict of interest: C.G.M. and M.d.C.E.P. are proctors for S-ICD (BostonScientific).

Funding: none declared.

References

- Nataloni M, Pergolini M, Rescigno G, Mocchegiani R. Prosthetic valve endocarditis. *J Cardiovasc Med (Hagerstown)* 2010;**11**:869–883.
- Bardy G, Smith W, Hood M, Crozier I, Melton I, Jordaens L et al. An entirely subcutaneous implantable cardioverter–defibrillator. *N Engl J Med* 2010;**363**: 36–44.
- Bostonscientific.com. 2020. <https://www.bostonscientific.com/content/dam/Manuals/us/current-rev-en/360195-001_AST_IFU_multi-GLOBAL_S.pdf> (9 May 2020).
- MacLeod RS, Ni Q, Punske B, Ershler PR, Yilmaz B, Taccardi B. Effects of heart position on the body-surface electrocardiogram. *J Electrocardiol* 2000;**33**: 229–237.
- Priori S, Blomström-Lundqvist C, Mazzanti A, Blom N, Borggrefe M, Camm J et al. 2015 ESC Guidelines for the management of patients with ventricular arrhythmias and the prevention of sudden cardiac death: the Task Force for the Management of Patients with Ventricular Arrhythmias and the Prevention of Sudden Cardiac Death of the European Society of Cardiology (ESC). *Eur Heart J* 2015;**36**:2793–2867.
- Østergaard L, Valeur N, Ihlemann N, Bundgaard H, Gislason G, Torp-Pedersen C et al. Incidence of infective endocarditis among patients considered at high risk. *Eur Heart J* 2018;**39**:623–629.
- Levine JD, Ellins C, Winn N, Kim R, Hsu SS, Catanzaro JN. Failed maximal defibrillation threshold testing in the subcutaneous implantable cardioverter defibrillator. *Cardiology* 2017;**136**:29–32.
- Winter J, Siekiera M, Shin DI, Meyer C, Kropil P, Clahsen H et al. Intermuscular technique for implantation of the subcutaneous implantable cardioverter defibrillator: long-term performance and complications. *Europace* 2016.
- Al-Ghamdi B, Shafquat A, Alruwaili N, Emmanuel S, Shoukri M, Mallawi Y. Subcutaneous Implantable Cardioverter Defibrillators Implantation Without Defibrillation Threshold Testing: A Single Center Experience. *Cardiol Res* 2017; **8**:319–326. 10.14740/cr638w
- Ferrero P, Ali H, Barman P, Foresti S, Lupo P, D'Elia E et al. Entirely subcutaneous defibrillator and complex congenital heart disease: data on long-term clinical follow-up. *World J Cardiol* 2017;**9**:547.
- Migliore F, Mattesi G, Franceschi P, Allocca G, Crosato M, Calzolari V et al. Multicentre experience with the second-generation subcutaneous implantable cardioverter defibrillator and the intermuscular two-incision implantation technique. *J Cardiovasc Electrophysiol* 2019;**30**:854–864.
- Monkhouse C, Koutsogeorgis I, Schilling R, Lambiase P. Subcutaneous implantable defibrillator in dextrocardia secondary to Lobectomy. *Clin Case Rep* 2018;**6**: 1727–1729.
- Kaczmarek K, Winter J, Wranicz J, Ptaszynski P. Atypical position of subcutaneous implantable cardioverter-defibrillator as a solution in hypertrophic cardiomyopathy patient with initially negative electrocardiographic screening. *Eur Heart J* 2015;**36**:2542–2542.
- Picano E, Vano E, Rehani M, Cuocolo A, Mont L, Bodi V et al. The appropriate and justified use of medical radiation in cardiovascular imaging: a position document of the ESC Associations of Cardiovascular Imaging, Percutaneous Cardiovascular Interventions and Electrophysiology. *Eur Heart J* 2014;**35**: 665–672.