






CT and MRI Features of Localized Peritumoral Amyloidosis in a Patient with Head and Neck Mucosa-Associated Lymphoid Tissue Lymphoma: A Case Report

두경부 MALT 림프종 환자에서 나타난 국소적 종괴 주위 아밀로이드증의 전산화단층촬영 및 자기공명영상 소견: 증례 보고

Han Joon Kim, MD¹ , Hyun Sook Hong, MD^{1*} , Ji Yoon Kim, MD² 

¹Department of Radiology, Soonchunhyang University Bucheon Hospital, Bucheon, Korea

²Department of Pathology, Samkwang Medical Laboratories, Seoul, Korea

Amyloidosis has been reported to be associated with non-Hodgkin lymphoma. Amyloidosis and lymphoma can be related in two ways: lymphoma-associated systemic amyloidosis and peritumoral amyloidosis with lymphoma. We report a rare case of peritumoral amyloidosis in a patient with head and neck mucosa-associated lymphoid tissue lymphoma. On CT, the oropharyngeal mass showed an irregularly shaped soft-tissue density with multifocal amorphous calcifications and heterogeneous enhancement. On MRI, the mass showed heterogeneous low signal intensity on both T1- and T2-weighted images. On contrast-enhanced MR images, the mass showed good enhancement with several inner non-enhancing foci. Concurrent pathologies, such as peritumoral amyloidosis, should be considered when calcifications are noted in patients with pre-treatment lymphoma.

Index terms Amyloidosis; Lymphoma, B-Cell, Marginal Zone; Computed Tomography, X-Ray; Magnetic Resonance Imaging

INTRODUCTION

The amyloidosis is a rare, slow and progressive disease characterized by extracellular

Received November 21, 2020

Revised January 10, 2021

Accepted January 13, 2021

*Corresponding author

Hyun Sook Hong, MD
Department of Radiology,
Soonchunhyang University
Bucheon Hospital,
170 Jomaru-ro,
Bucheon 14584, Korea.


Tel 82-32-621-5851

Fax 82-32-621-5874

E-mail hshong@schmc.ac.kr


This is an Open Access article distributed under the terms of the Creative Commons Attribution Non-Commercial License (<https://creativecommons.org/licenses/by-nc/4.0>) which permits unrestricted non-commercial use, distribution, and reproduction in any medium, provided the original work is properly cited.

ORCID iDs

Han Joon Kim 

[https://](https://orcid.org/0000-0003-0717-3505)

orcid.org/0000-0003-0717-3505

Hyun Sook Hong 

[https://](https://orcid.org/0000-0003-3210-9740)

orcid.org/0000-0003-3210-9740

Ji Yoon Kim 

[https://](https://orcid.org/0000-0002-6126-227X)

orcid.org/0000-0002-6126-227X

eosinophilic deposition and accumulation of abnormally folded and insoluble protein (amyloid) (1). Amyloidosis can be classified by anatomic distribution. It may be systemic (multiorgan involvement) or localized (single organ involvement). It can present as focal, tumor-like lesion (amyloidoma) or diffuse infiltrative pattern (1).

The frequency of head and neck involvement ranges from 12%–90% (2). The most common site is the tongue, followed by the larynx and thyroid (2). Amyloidoma is extremely rare, but it has been described in almost every organ (1). In contrast, oropharyngeal amyloidosis is exceedingly rare (3), with only seven case reports of in the last 30 years (4).

There are several cases describing the association between lymphoma and amyloid deposition, representatively two entities of “lymphoma associated systemic amyloidosis” and “peritumoral amyloidosis with lymphoma”. The systemic amyloidosis is predominantly associated with lymphoplasmacytic lymphoma and multiorgan involvement. On the other hand, patients with peritumoral amyloidosis with lymphoma [mostly associated with mucosa-associated lymphoid tissue (MALT) lymphoma] are reported to have peritumoral amyloid deposits and predominantly single organ involvement (5).

In this report, we describe a rare case of concurrent oropharyngeal amyloidosis and MALT lymphoma, which could be classified as peritumoral amyloidosis with lymphoma.

CASE REPORT

A 60-year-old female visited our hospital for tongue swelling and foreign-body sensation in the throat. During physical examination, a mass was found in the left tongue base. She had never smoked. Laboratory studies were not remarkable.

CT revealed an irregularly shaped high-density mass lesion with amorphous calcifications involving the left lingual tonsil, left palatine tonsil, left tongue base, the soft palate and uvula (Fig. 1A). After contrast administration, heterogeneous enhancement was noted (Fig. 1A). In addition, a less than 1 cm sized high attenuated lesion with calcification was present at the left lower eyelid (Fig. 1B). For the oropharyngeal mass, venous malformation was considered as a differential diagnosis due to the presence of calcifications. However, the possibility of systemic lymphoproliferative disease such as lymphoma could not be excluded due to the presence of the concurrent eyelid lesion. The patient underwent excisional biopsy for the oropharyngeal mass. The pathologic report revealed a MALT lymphoma. After excision, PET-CT and contrast-enhanced MRI were performed for further evaluation. PET-CT revealed a residual hypermetabolic mass suggestive of residual lymphoma with involvement in the left oropharynx. Mild fluorodeoxyglucose uptake was also noted in the left neck level I, II lymph nodes and in the inferior aspect of left eyeball, suspicious for lymphoma involvement. There was no evidence of lymphoma involvement in the other areas of the body. On contrast enhanced MRI, residual mass lesion involving the left palatine tonsil, soft palate, uvula, and the left side tongue base was suspected. The mass showed heterogeneous low signal intensity on T1 and T2 weighted images (Fig. 1C) and showed strong enhancement with internal non-enhancing foci on enhanced T1 weighted images (Fig. 1C). A repeated biopsy of the oropharyngeal mass and excisional biopsy for the orbital mass was performed. The pathology report revealed chronic inflammation with degenerative eosinophilic material in the oropharynx

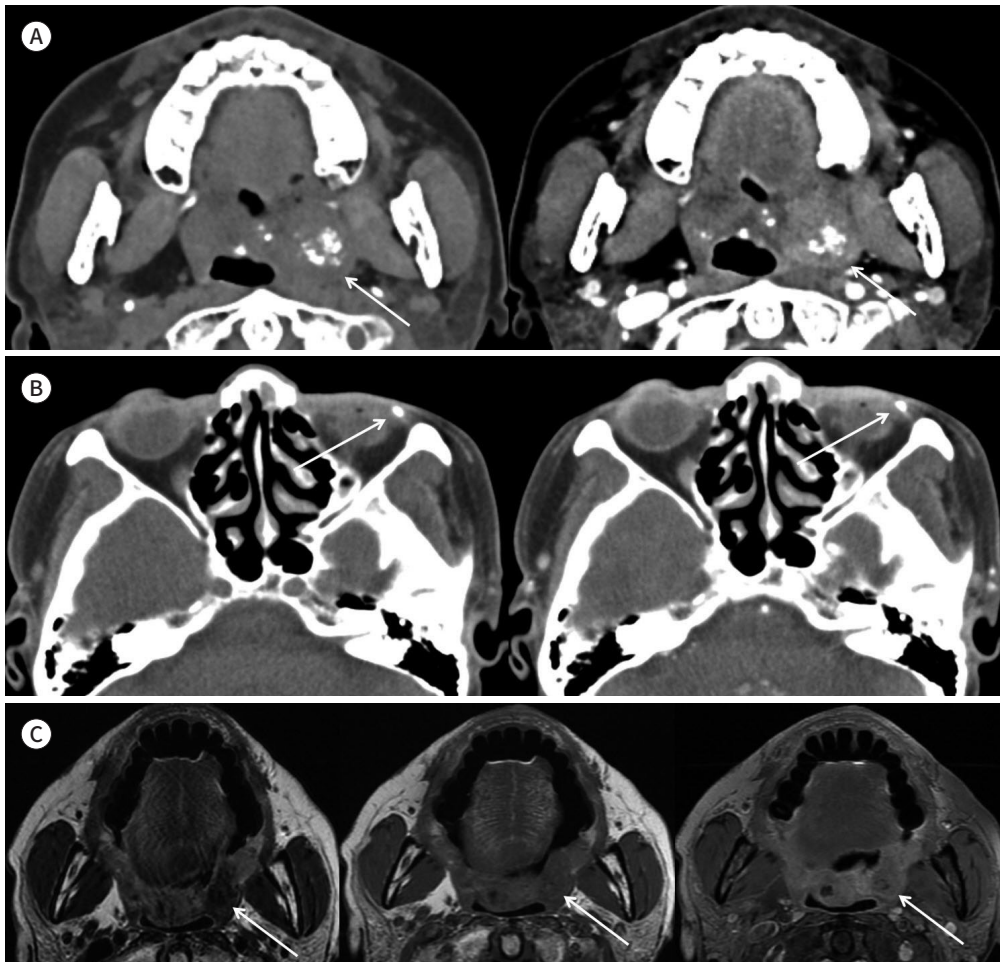
Fig. 1. A peritumoral amyloidosis in a patient with MALT lymphoma in a 60-year-old female, presenting with tongue swelling and foreign-body sensation in the throat.

A. The pre-contrast neck scan (left) shows an oropharyngeal mass with multiple amorphous calcifications (arrow). Heterogeneous enhancement (arrow) is observed on the contrast-enhanced images (right).

B. The pre-contrast neck scan (left) shows dense calcification (arrow) of the orbital mass. Heterogeneous enhancement (arrow) is observed on the contrast-enhanced images (right).

C. A tonsillar and soft-palate mass (arrows) of heterogeneous low signal intensity on the T1-weighted (left) and T2-weighted (middle) images. The contrast-enhanced MR image (right) reveals a well-enhanced mass (arrow) with internal low-signal foci.

MALT = mucosa-associated lymphoid tissue



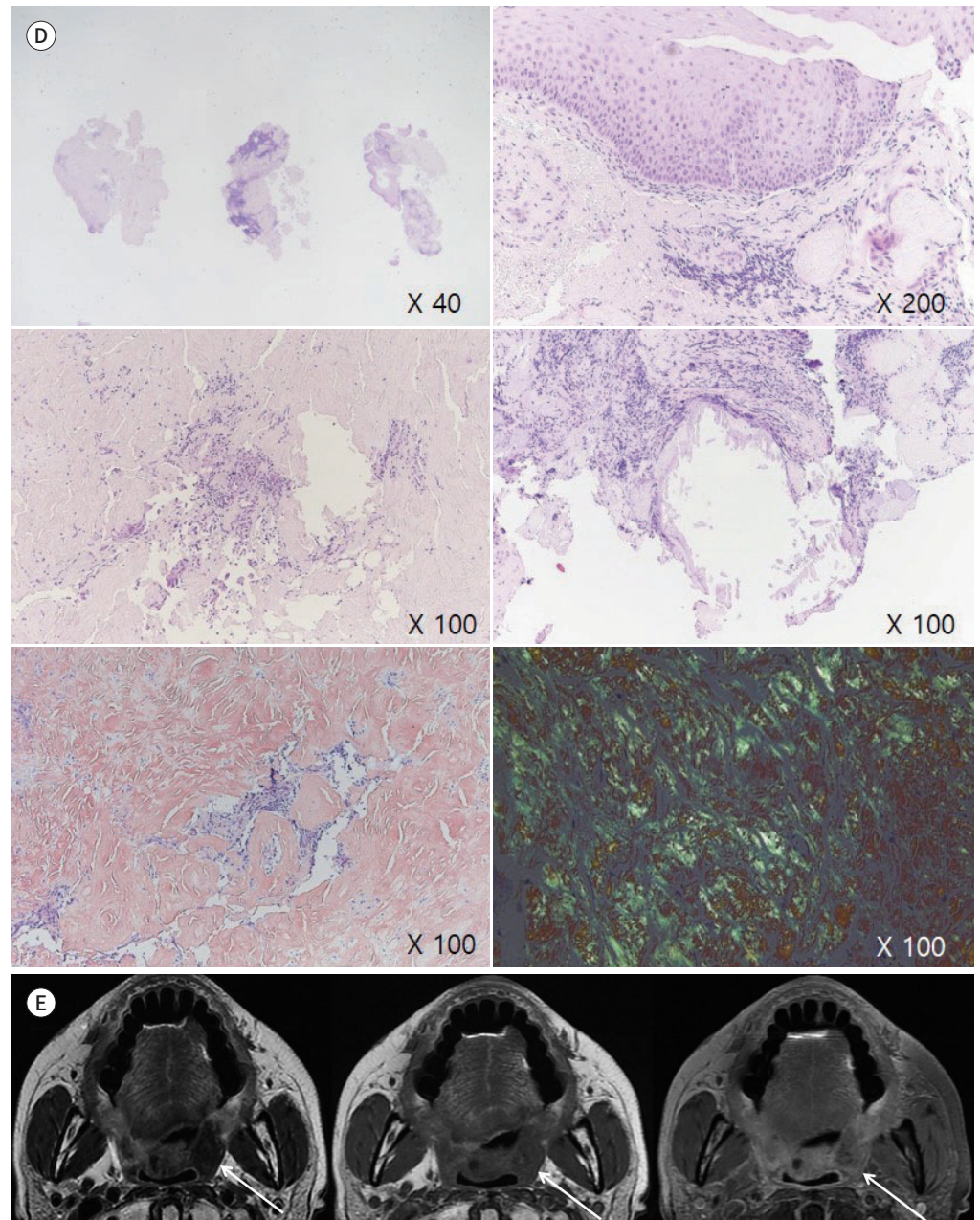
and left eyelid masses, without evidence of residual lymphoma. The patient was followed in the outpatient clinic without adjuvant therapy. Follow up MR image during 2 years showed a slow but progressive increase in the size of the oropharyngeal mass, therefore a repeated excisional biopsy was performed.

Biopsy specimen of the mass confirmed the presence of peritumoral amyloidosis with lymphoma (Fig. 1D). Histologically, the specimen consisted of amorphous eosinophilic material, a few plasma cell clusters and calcification. The material was accumulated at subepithelial connective tissue. It was salmon-pink on congo-red stain and shows a typical apple-green birefringence when viewed under cross-polarized light. This result confirmed the diagnosis of amyloidosis. The plasma cell clusters surrounded by amyloid deposition and

Fig. 1. A peritumoral amyloidosis in a patient with MALT lymphoma in a 60-year-old female, presenting with tongue swelling and foreign-body sensation in the throat.

D. On hamatoxylin and eosion staining, the specimen consists of several pieces of eosinophilic amorphous material (left upper image). This material is located within the subepithelial area (right upper image). A few clusters of plasma cells surrounded by this deposition are also noted (left middle image). Dystrophic calcification is observed (right middle image) and shows apple-green birefringence under the polarized microscope (right lower image).

E. On follow-up MRI after radiotherapy, the tonsillar and soft-palate mass (arrows) also show heterogeneous low signal intensity on T1- and T2-weighted images (left, middle). The CE MR image (right) also reveals a well-enhanced mass (arrow) with internal low-signal foci. There is no significant change in the size of the lesion. CE = contrast-enhanced, MALT = mucosa-associated lymphoid tissue



showed Kappa chain monoclonality, suggesting recurrent lymphoma. Multifocal dystrophic calcifications were also noted in this specimen.

The patient underwent radiotherapy for recurrent lymphoma. Follow up MRI after radiotherapy showed no significant change in size and signal intensities of the lesion (Fig. 1E).

On retrospective pathologic review, the initial biopsy specimens of the oropharynx and orbit were also consistent with peritumoral amyloidosis with lymphoma.

This study was approved by the Institutional Review Board of our institution and the requirement for informed consent was waived (IRB No. 2020-07-022-001).

DISCUSSION

Amyloidosis of the head and neck usually occurs in the setting of primary amyloidosis (2). Localized amyloidosis in the head and neck is extremely rare (1), with the larynx and orbits the most frequently involved sites (1). Oropharyngeal amyloidosis is even rarer (4). On CT, it appears as a well-defined submucosal homogeneous mass, except for areas of calcification (2, 3), with varying degrees of enhancement (4). The calcifications range from subtle psammomatous to well-defined foci (3). On MRI, amyloidosis has a signal intensity similar to that of skeletal muscle (3). It may show low signal intensity both on T1 weighted images and T2 weighted images, because of the molecular structure of amyloid. The compact and complex environment of the amyloid may allow increase chance for dissipation of coherent resonance, resulting in a loss of signal intensity (6). In addition, decreased water mobility in an area of densely packed protein is expected within the highly organized amyloid protein (6). Given the high vascularity of the lesion and the fragility of its vessels, it may show marked enhancement and slow washout (3). To our knowledge, in the last 20 years there have been only five case reports of amyloidosis of the palate (7) but none have described the MRI findings of amyloidosis of the palate.

There are two entities of “lymphoma associated systemic amyloidosis” and “peritumoral amyloidosis with lymphoma” (5). Previous studies have suggested that peritumoral and systemic amyloidosis are distinct disease entities, in which peritumoral amyloidosis with MALT lymphoma show indolent behavior with rare progression to disseminated disease. MALT lymphoma associated with amyloid deposition is considered as a result of immunoglobulin or immunoglobulin light chains deposition produced in MALT lymphoma (8).

Systemic amyloidosis is a life-threatening disease which can cause progressive organ failure (8). The presence of amyloid deposition could lead to difficulties in the differential diagnosis of lymphoma with non-tumorous condition (8). Clinical consensus criteria have been established to differentiate systemic amyloidosis from localized amyloid deposition (8). In addition to histologic evidence of amyloidosis, it includes evidence of organ dysfunction such as organomegaly or abnormal laboratory finding (8). In contrast to the cases of systemic amyloidosis, our case demonstrated amyloid deposits localized to involved sites of MALT lymphoma. In addition there is no laboratory finding that suggests organ dysfunction.

The fact that lymphoma relapses often contained amyloid, but amyloid was never encountered in sites not involved by lymphoma is described (8). So, amyloid-containing specimens in patient with lymphoma, the possibility of sampling error and excisional biopsy should be

considered (9). The treatment may vary according to stage and involvement site, including excision alone, localized radiotherapy, rituximab, and other chemotherapy (8). Cases of multiple recurrences were described in many cases (8).

In general, radiologically demonstrable calcifications in lymphoma are considered to be a consequence of previous treatment, usually radiotherapy or, less commonly, chemotherapy (9). Pre-treatment calcifications are rarely reported in lymphoma, and it is regarded as a consequence of hypercalcemia (9). In our patient, the laboratory findings were grossly normal. Therefore, in patients with pre-treatment lymphoma and normal laboratory findings, calcifications detected on CT could be a clue of a concurrent peritumoral amyloidosis in the background of MALT lymphoma showing plasmacytic differentiation.

In conclusion, peritumoral amyloidosis with lymphoma could demonstrate a heterogeneous high density mass with calcifications and well enhancement on CT. On MR imaging, the mass showed low signal intensity on both T1 and T2 weighted images. Calcifications on imaging in a patient with lymphoma could suggest a second concurrent pathology, such as peritumoral amyloidosis.

Author Contributions

Conceptualization, H.H.S., K.H.J.; funding acquisition, H.H.S.; resources, H.H.S., K.J.Y.; supervision, H.H.S.; writing—original draft, K.H.J., H.H.S.; and writing—review & editing, all authors.

Conflicts of Interest

The authors have no potential conflicts of interest to disclose.

Funding

This work was supported by the Soonchunhyang University Research Fund.

REFERENCES

1. Georgiades CS, Neyman EG, Barish MA, Fishman EK. Amyloidosis: review and CT manifestations. *Radiographics* 2004;24:405-416
2. Kerner MM, Wang MB, Angier G, Calcaterra TC, Ward PH. Amyloidosis of the head and neck. A clinicopathologic study of the UCLA experience, 1955-1991. *Arch Otolaryngol Head Neck Surg* 1995;121:778-782
3. Asaumi J, Yanagi Y, Hisatomi M, Konouchi H, Kishi K. CT and MR imaging of localized amyloidosis. *Eur J Radiol* 2001;39:83-87
4. Send T, Spiegel JL, Schade G, Pantelis A, Olthoff A, Bootz F, et al. Amyloidosis of the upper aerodigestive tract: management of a rare disease and review of the literature. *Dysphagia* 2019;34:179-191
5. Zhang Q, Pocrnich C, Kurian A, Hahn AF, Howlett C, Shepherd J, et al. Amyloid deposition in extranodal marginal zone lymphoma of mucosa-associated lymphoid tissue: a clinicopathologic study of 5 cases. *Pathol Res Pract* 2016;212:185-189
6. Gean-Marton AD, Kirsch CF, Vezina LG, Weber AL. Focal amyloidosis of the head and neck: evaluation with CT and MR imaging. *Radiology* 1991;181:521-525
7. Balatsouras DG, Eliopoulos P, Assimakopoulos D, Korres S. Primary local amyloidosis of the palate. *Otolaryngol Head Neck Surg* 2007;137:348-349
8. Ryan RJ, Sloan JM, Collins AB, Mansouri J, Raje NS, Zukerberg LR, et al. Extranodal marginal zone lymphoma of mucosa-associated lymphoid tissue with amyloid deposition: a clinicopathologic case series. *Am J Clin Pathol* 2012;137:51-64
9. Lautin EM, Rosenblatt M, Friedman AC, Becker RD, Fromowitz FB, Neglia W. Calcification in non-Hodgkin lymphoma occurring before therapy: identification on plain films and CT. *AJR Am J Roentgenol* 1990;155:739-740

두경부 MALT 림프종 환자에서 나타난 국소적 종괴 주위 아밀로이드증의 전산화단층촬영 및 자기공명영상 소견: 증례 보고

김한준¹ · 홍현숙^{1*} · 김지윤²

아밀로이드증과 비호지킨림프종과의 연관관계는 이전의 연구들에서 보고된 바 있다. 림프종과 아밀로이드증과의 연관관계는 두 개의 구분되는 범주로 나뉘는데 림프종 연관 전신성 아밀로이드증과 종괴 주위 아밀로이드증이다. 저자들은 두경부 MALT 림프종 환자에서 발생한 국소적 종괴 주위 아밀로이드증의 드문 증례를 보고하고자 한다. 전산화단층촬영에서 병변은 연조직음영을 보이는 부정형석회화를 동반한 불규칙한 모양의 종괴였으며, 조영증강 시 불균일한 조영증강을 보였다. 자기공명영상에서는 종괴가 T1 강조영상과 T2 강조영상에서 모두 불균일한 낮은 신호 강도를 보였다. 종괴는 강한 조영증강을 보였으며, 내부에는 여러 개의 조영증강되지 않는 부분들을 포함하고 있었다. 림프종 환자에서 치료 전 영상검사에서 발견된 석회화들은 종괴 주위 아밀로이드증과 같은 동반된 다른 이차성 병변을 시사하는 소견이 될 수 있을 것이다.

¹순천향대학교 부천병원 영상의학과,

²삼광의료재단 진단본부 병리과