

Giant cervical goiter in Hashimoto's thyroiditis: A case report

Journal of International Medical Research

50(5) 1–7

© The Author(s) 2022

Article reuse guidelines:

sagepub.com/journals-permissions

DOI: 10.1177/03000605221096379

journals.sagepub.com/home/imr

Tang Tao^{1,2} , Yang Gang^{1,2}, Sun Ji^{1,2},
Chen Xiao-Li³, Li Wei-Nan^{1,2}, Li Qiang^{1,2},
Zhu Jian-Jiao^{1,2}, Xiong Yong-Fu^{1,2} and
Li Jing-Dong^{1,2} 

Abstract

A giant cervical goiter, defined as a thyroid mass larger than 8 cm in diameter, is usually a nodular or adenomatous goiter. A giant cervical goiter can also be caused by hyperthyroidism (i.e., Hashimoto's thyroiditis). The surgical indications for patients with Hashimoto's disease include suspected malignant tumors, persistent symptoms related to the disease, or persistent enlargement of the goiter. We herein describe a woman who developed symptoms of compression from a thyroid tumor, the volume of which was almost the largest reported in the relevant literature to date. The bilateral lobes of the giant thyroid tumor were removed by total en bloc excision. We protected the bilateral recurrent laryngeal nerve and preserved the bilateral upper and lower parathyroid glands in situ. The excised left lobe tumor was 16 × 9 × 5.5 cm, whereas the right lobe tumor was 12 × 8 × 4 cm. The pathological diagnosis was Hashimoto's thyroiditis. Although surgical excision is difficult, it is still the main treatment modality for giant goiters in patients with Hashimoto's thyroiditis and can help to reduce the occurrence of complications.

Keywords

Giant goiter, Hashimoto's thyroiditis, case report, thyroid, en bloc excision, hyperthyroidism

Date received: 19 August 2021; accepted: 1 March 2022

¹The First Department of Hepatobiliary Surgery, Affiliated Hospital of North Sichuan Medical College, Nanchong, Sichuan Province 637000, China

²Institute of Hepato-Biliary-Pancreatic-Intestinal Disease, North Sichuan Medical College, Nanchong, Sichuan Province 637000, China

³Department of Pathology, Affiliated Hospital of North Sichuan Medical College, Nanchong, Sichuan Province 637000, China

Corresponding author:

Li Jing-Dong, The First Department of Hepatobiliary Surgery, Affiliated Hospital of North Sichuan Medical College, No. 1 Maoyuan South Road, Nanchong, Sichuan Province 637000, China.

Email: Li-Jingdong@hotmail.com



Introduction

Hashimoto's thyroiditis is the most common cause of acquired hypothyroidism with or without goiter.^{1,2} Surgical treatment of Hashimoto's thyroiditis is mainly applicable to patients with persistent goiter, suspicious or confirmed malignant tumors, painful thyroiditis, and symptoms of localized compression.³ A giant cervical goiter is usually a nodular or adenomatous goiter. However, it can also be caused by hyperthyroidism (i.e., Hashimoto's thyroiditis), which can cause persistent compression symptoms and an unsightly neck appearance.⁴⁻⁷ Giant goiters have always been of great interest to surgeons because surgery is the main treatment modality for this disease. As the tumor grows and compresses the trachea and esophagus, it also pushes adjacent organs and tissues, thereby causing anatomical structural variations. For this reason, it is often difficult to find and protect the parathyroid and recurrent laryngeal nerve (RLN), and the incidence of complications after thyroidectomy is higher in patients with than without Hashimoto's thyroiditis.⁸ We herein present a case of a giant cervical goiter associated with Hashimoto's thyroiditis that required surgical treatment.

Case presentation

The reporting of this study conforms to the CARE guidelines.⁹ We deidentified all patient

details and obtained patient consent for treatment. A woman in her 50s was admitted to our hospital with symptoms of compression from a neck tumor. The patient had a thyroid tumor 10 years previously. She also had a history of hypothyroidism, but she did not take medication regularly.

The patient's general information at admission was collected and documented as follows: height of 154 cm, weight of 65 kg, blood pressure of 124/67 mmHg, heart rate of 89 beats/minute, respiratory rate of 19 breaths/minute, SpO₂ of 100%, and body temperature of 36.8°C.

Physical examination revealed a left thyroid lobe mass of approximately 16 × 10 cm and a right lobe mass of approximately 13 × 9 cm. The masses exhibited poor mobility, no tenderness, and no vascular murmur on auscultation (Figure 1). The patient had no signs of dyspnea, hoarseness, or dysphagia.

Biochemical tests revealed a thyroid-stimulating hormone concentration of 6.21 mIU/L (reference range, 0.3–4.94 mIU/L), a free T3 concentration of 4.44 pmol/L (reference range, 2.23–6.47 pmol/L), a free T4 concentration of 9.03 pmol/L (reference range, 9.01–24.01 pmol/L), a thyroid peroxidase concentration of >1000 IU/mL (reference range, 0–40 IU/mL), a thyroid microsomal antibody concentration of >1000 IU/mL (reference range, 0–50 IU/mL), an anti-thyroglobulin antibody

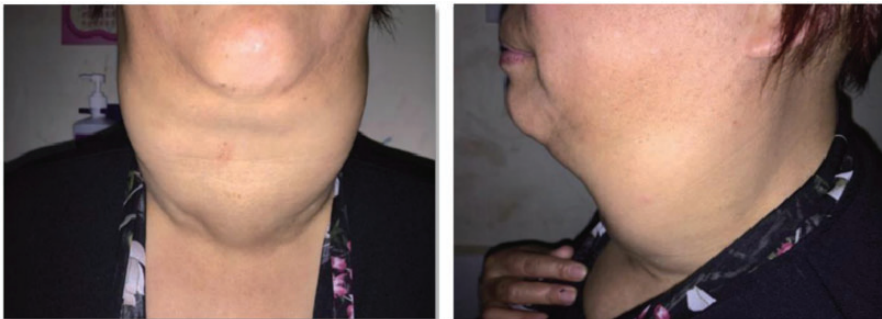

Figure 1. The patient had a large, wide-ranging diffuse goiter in the neck that was swollen before surgery.

concentration of 426.95 IU/mL (reference range, 0–4 IU/mL), a thyroglobulin concentration of 43.02 ng/mL (reference range, 0–40 ng/mL), a parathyroid hormone (PTH) concentration of 32.10 pg/mL (reference range, 14.1–50.2 pg/mL), and a carcinoembryonic antigen concentration of 0.75 ng/mL (reference range, 0–5.9 ng/mL).

Magnetic resonance imaging (MRI) examination showed giant tumors in both thyroid lobes. The tumors were encapsulated with clear boundaries and relatively uniform enhancement. The upper boundary of the left lobe tumor reached the parapharyngeal region, whereas the lower boundary reached the subclavian region (Figure 2).

After a preoperative multidisciplinary comprehensive evaluation, the patient underwent general anesthesia followed by tracheal intubation. A low collar incision was made. To fully expose the field of view, the anterior cervical muscles were removed with an ultrasonic knife and then resutured after the tumor was removed. The thyroid capsule was finely dissected, and the sternocleidomastoid muscle was fully stretched. After the upper pole of the tumor was ligated and then gradually released, the RLN and upper and lower parathyroid glands were identified and protected. The blood vessels of the lower pole of the thyroid were finally processed. The bilateral lobes of the thyroid and giant

tumors were removed by total en bloc excision. The tumor was hard in texture and diffuse with multiple nodules (Figure 3). We protected the bilateral RLN and preserved the bilateral upper and lower parathyroid glands in situ (Figure 4).

The pathological examination revealed that the tumor capsule was intact and that the surface blood vessels were dilated and hyperemic. In addition, multiple nodules were present, the cut surface was gray and yellow, and the texture was hard. Hematoxylin–eosin staining showed a large number of lymphocytes within the thyroid, which resembled a lymphoid follicular structure (Figure 5).

After surgery, the patient had no symptoms of hoarseness and no numbness of the extremities. Biochemical tests revealed a calcium concentration of 2.34 mmol/L and a PTH concentration of 16.90 pg/mL. The patient was discharged 5 days after surgery. She was prescribed long-term replacement therapy with oral levothyroxine at 75 mg/day, and she had no discomfort in the neck at the 1-year re-examination (Figure 6).

Discussion

Hashimoto's thyroiditis is a major form of autoimmune thyroiditis. The surgical indications for patients with Hashimoto's disease include suspected malignant

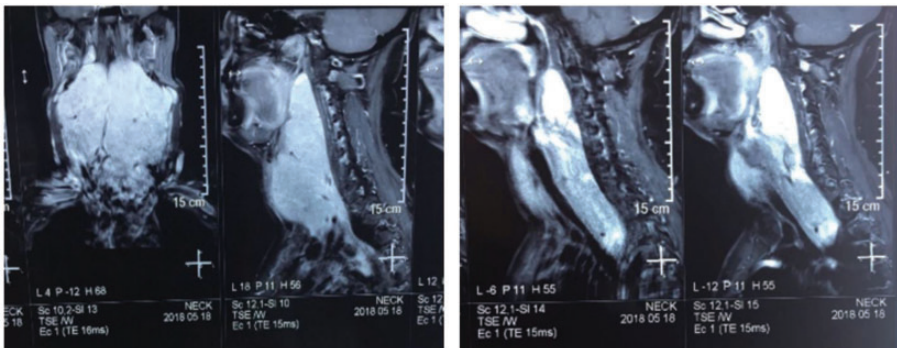


Figure 2. Enhanced magnetic resonance images showing the extent of the thyroid tumor. The upper boundary reached the parapharyngeal region, and the lower boundary reached the subclavian region.

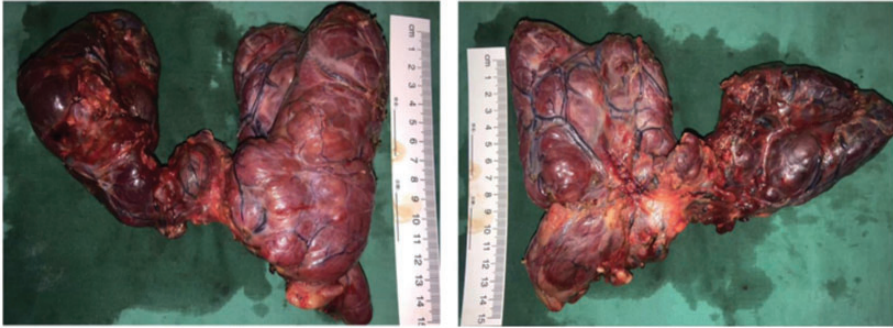

Figure 3. Total en bloc removal of the giant tumor of the bilateral thyroid lobes (left tumor, $16 \times 9 \times 5.5$ cm; right tumor, $12 \times 8 \times 4$ cm).

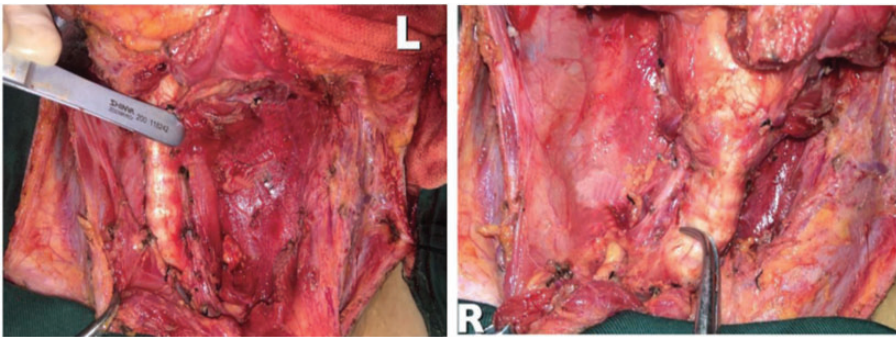


Figure 4. The surgical field conditions after complete tumor resection showed the bilateral recurrent laryngeal nerve and all parathyroid glands retained in situ. Black arrow, parathyroid gland; white arrow, recurrent laryngeal nerve.

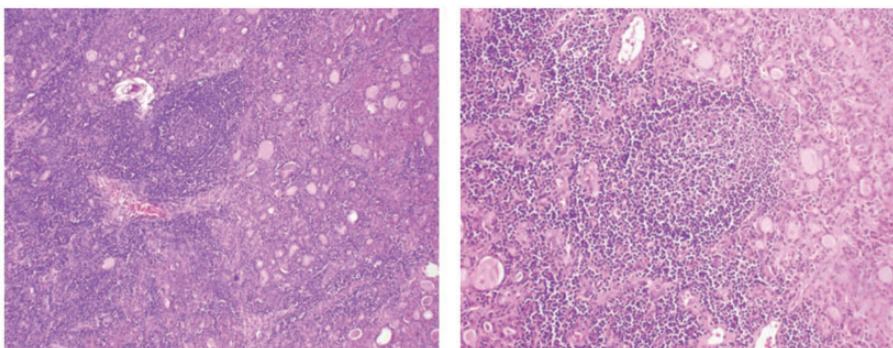


Figure 5. Hematoxylin–eosin stained images showing massive lymphocyte infiltration into the thyroid.

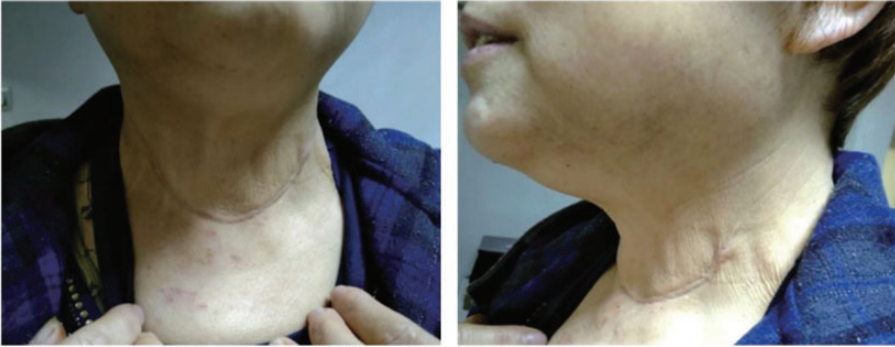

Figure 6. Follow-up images of patient 1 year after surgery.

tumors, persistent symptoms related to the disease, or persistent enlargement of the goiter.^{7,10,11} However, surgery can be difficult because of swelling and inflammation around the thyroid, and patients with Hashimoto's thyroiditis may have a higher incidence of complications after surgery.⁸

A benign giant goiter with a background of Hashimoto's disease must be distinguished from a malignant thyroid lymphoma and neck lymphoma in the surrounding tissues of the thyroid. These two diseases are characterized by the relatively short course of disease and rapid growth of neck masses. The symptoms are severe, and the condition deteriorates rapidly.^{12,13}

Preoperative biochemical tests can rule out diseases such as hyperthyroidism. Computed tomography/MRI examinations are also necessary because they can help surgeons understand the relationship between the giant mass and the surrounding tissues and organs as well as assess the degree of airway stenosis. Computed tomography/MRI examinations can also help to determine the surgical method and extent of resection.

Surgery is the best treatment modality for giant goiter. This disease is characterized by several features: (i) the patient's trachea is often compressed and narrowed, and the displacement may cause difficulty in intubation; (ii) the giant gland contains

thick and abundant blood vessels, especially in patients with Hashimoto's thyroiditis, increasing the risk of intraoperative bleeding; (iii) the RLN and parathyroid glands are compressed and displaced from their normal anatomical positions; and (iv) the upper pole of the mass can reach the hyoid bone or mandible and the lower pole can extend deep behind the sternum, thereby complicating the surgery and increasing the risk of complications.¹⁴

If a giant goiter is confined to one lobe, the normal thyroid on the opposite lobe can be saved. However, if the tumor is on the bilateral lobes, a portion of the normal thyroid gland can be saved after considering the patient's situation. In the present case, diffuse Hashimoto's thyroiditis was evident in both thyroid glands; thus, total thyroidectomy was performed.

To fully expose the surgical field in this case, a portion of the anterior cervical muscle was removed and then resutured after tumor resection. This seemed to increase muscle damage, but it reduced unnecessary bleeding and damage to the RLN and parathyroid, and it was conducive to a successful operation. Although the tumor was huge and the upper pole was high, the anatomy of the upper pole of the thyroid is relatively constant, and the surgical field can be fully exposed by pulling on the sternocleidomastoid muscle. The surgeon

resected the upper pole and then used a top-down approach to identify and protect the parathyroid and RLN in sequence.

The lower pole of a giant goiter often extends to the back of the sternum. If the lower pole of the thyroid is removed first, it would be difficult to expose the visual field because the clavicle would obstruct the view, thereby further complicating the surgery. On the contrary, if the lower pole is processed first, the overall activity of the tumor would be low, facilitating complete tumor resection.

Because of the compression effect of the huge tumor in this case, the RLN was displaced to the outside. The RLN may attach to the dorsal thyroid membrane due to chronic inflammation in such cases. Intraoperative neuromonitoring can help to identify and locate the RLN, thereby reducing possible accessory injury. The advantages of intraoperative neuromonitoring are better reflected in anatomical variation.^{15,16}

The trachea may become narrow because of long-term compression by the giant goiter. In this case, it was necessary to fully evaluate the degree of airway stenosis before surgery. If necessary, a tracheal stent should be placed before surgery or surgery should be performed after tracheotomy under local anesthesia.¹⁷

After removal of the tumor, the tracheal support point may disappear and collapse. Therefore, the status of the compressed portion of the trachea should be routinely checked after surgery. If softening and collapse are present, tracheal suspension should be performed. In addition, the tracheal intubation catheter must be removed after the patient is fully awake. Extubation can be delayed if the tracheal stenosis is low or evident in the thorax.

A goiter, especially a giant one, is rare in patients with hyperthyroidism, especially when it involves both thyroid glands as in the present case. In addition, the volume of our patient's tumor was almost the largest in the relevant literature to date, making the

treatment process quite complex. Although the surgery is difficult, an adequate preoperative evaluation and appropriate surgical approach can protect the RLN and parathyroid, avoid damage to large blood vessels, and prevent collapse of the trachea during surgery. Thus, the giant goiter can be successfully removed, thereby reducing the occurrence of complications.

Ethics approval and consent to participate

The study was approved by the hospital's ethics committee (Ethics Committee of the Affiliated Hospital of North Sichuan Medical College, File Number 2020 ER(A) 057). The patient involved in this study agreed to provide relevant information for research purposes and gave written consent to publish this information.

Declaration of conflict of interest

The authors reports no conflicts of interest in this work.

Acknowledgements

We would like to thank the patient for providing detailed information for this study and the funders for providing financial support for this study. We are also grateful to the nurses and the imaging and operating room staff who contributed to this study.

Funding


The authors disclosed receipt of the following financial support for the research, authorship, and/or publication of this article: This study was supported by Science and Technology of Sichuan Province (No. 2020YJ0186) and the Medical Research Youth Innovation Project of Sichuan Province (No. Q20024).

Authors' contributions

Tang Tao contributed to the study conception and design and the manuscript writing and drafting. Yang Gang, Sun Ji, Chen Xiao-Li, Li Wei-Nan, Li Qiang, and Zhu Jian-Jiao reviewed the literature and collected the imaging information. Li Jing-Dong and Xiong Yong-Fu reviewed the

manuscript. All authors read and approved the final version of the manuscript.

ORCID iDs

Tang Tao  <https://orcid.org/0000-0002-8613-2228>

Li Jing-Dong  <https://orcid.org/0000-0002-1923-1787>

References

- Lorini R, Gastaldi R, Traggiai C, et al. Hashimoto's thyroiditis. *Pediatr Endocrinol Rev* 2003; 1 Suppl 2: 205–211; discussion 211. 2006/01/31.
- Chiovato L, Magri F and Carlé A. Hypothyroidism in context: where we've been and where we're going. *Adv Ther* 2019; 36: 47–58. 2019/09/06. DOI: 10.1007/s12325-019-01080-8.
- Bhargav PR and Shekhar S. Surgical indications for goiter with background Hashimoto's thyroiditis: institutional experience. *Indian J Surg* 2011; 73: 414–418. 2012/12/04. DOI: 10.1007/s12262-011-0344-0.
- Gao B, Tian W, Jiang Y, et al. Peri-operative treatment of giant nodular goiter. *Int J Med Sci* 2012; 9: 778–785. 2012/11/09. DOI: 10.7150/ijms.5129.
- Harada A, Nomura E, Nishimura K, et al. Type 1 and type 2 iodothyronine deiodinases in the thyroid gland of patients with huge goitrous Hashimoto's thyroiditis. *Endocrine* 2019; 64: 584–590. 2019/02/10. DOI: 10.1007/s12020-019-01855-7.
- Li Y, Cui X, Yang Y, et al. Surgical treatment of children Graves' disease with huge goiter—a case report and literature review. *Gland Surg* 2020; 9: 467–473. 2020/05/19. DOI: 10.21037/gs.2020.02.19.
- McManus C, Luo J, Sippel R, et al. Should patients with symptomatic Hashimoto's thyroiditis pursue surgery? *J Surg Res* 2011; 170: 52–55. 2011/03/26. DOI: 10.1016/j.jss.2011.01.037.
- McManus C, Luo J, Sippel R, et al. Is thyroidectomy in patients with Hashimoto thyroiditis more risky? *J Surg Res* 2012; 178: 529–532. 2012/10/10. DOI: 10.1016/j.jss.2012.09.017.
- Gagnier JJ, Kienle G, Altman DG, et al; CARE Group. The CARE guidelines: consensus-based clinical case reporting guideline development. *Headache* 2013; 53: 1541–1547.
- Takasu N, Yamada T, Katakura M, et al. Evidence for thyrotropin (TSH)-blocking activity in goitrous Hashimoto's thyroiditis with assays measuring inhibition of TSH receptor binding and TSH-stimulated thyroid adenosine 3',5'-monophosphate responses/cell growth by immunoglobulins. *J Clin Endocrinol Metab* 1987; 64: 239–245. 1987/02/01. DOI: 10.1210/jcem-64-2-239.
- Shih ML, Lee JA, Hsieh CB, et al. Thyroidectomy for Hashimoto's thyroiditis: complications and associated cancers. *Thyroid* 2008; 18: 729–734. 2008/07/18. DOI: 10.1089/thy.2007.0384.
- Liu XM, Ma DL, Yuan G, et al. Progressively enlarging goiter: case reports of primary thyroid lymphoma and literature review. *Curr Med Sci* 2020; 40: 518–522. 2020/06/01. DOI: 10.1007/s11596-020-2204-2.
- Storck K, Brandstetter M, Keller U, et al. Clinical presentation and characteristics of lymphoma in the head and neck region. *Head Face Med* 2019; 15: 1. 2019/01/05. DOI: 10.1186/s13005-018-0186-0.
- Agarwal A, Agarwal S, Tewari P, et al. Clinicopathological profile, airway management, and outcome in huge multinodular goiters: an institutional experience from an endemic goiter region. *World J Surg* 2012; 36: 755–760. 2012/02/04. DOI: 10.1007/s00268-012-1447-x.
- Zhang D, Pino A, Caruso E, et al. Neural monitoring in thyroid surgery is here to stay. *Gland Surg* 2020; 9: S43–S46. 2020/02/15. DOI: 10.21037/gs.2019.10.24.
- Snyder SK, Sigmond BR, Lairmore TC, et al. The long-term impact of routine intra-operative nerve monitoring during thyroid and parathyroid surgery. *Surgery* 2013; 154: 704–711; discussion 711–703. 2013/09/07. DOI: 10.1016/j.surg.2013.06.039.
- Piao M, Yuan Y, Wang Y, et al. Successful management of trachea stenosis with massive substernal goiter via tracheobronchial stent. *J Cardiothorac Surg* 2013; 8: 212. 2013/11/16. DOI: 10.1186/1749-8090-8-212.