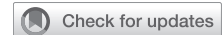

Robotic Heller myotomy and Dor fundoplication: Twelve steps



Suha Kaaki, MD,^{a,b} and Matthew G. Hartwig, MD, MHS,^a Durham, NC, and Riyadh, Saudi Arabia

From the ^aDepartment of Cardiothoracic Surgery, Duke University Medical Center, Durham, NC; and ^bDivision of Thoracic Surgery, College of Medicine, King Saud University, Riyadh, Saudi Arabia.

Disclosures: M.G.H. consults and provided educational service for Intuitive Surgical. S.K. reported no conflicts of interest.

The *Journal* policy requires editors and reviewers to disclose conflicts of interest and to decline handling or reviewing manuscripts for which they may have a conflict of interest. The editors and reviewers of this article have no conflicts of interest.

Received for publication Aug 9, 2021; revisions received July 23, 2022; accepted for publication July 29, 2022; available ahead of print Aug 20, 2022.

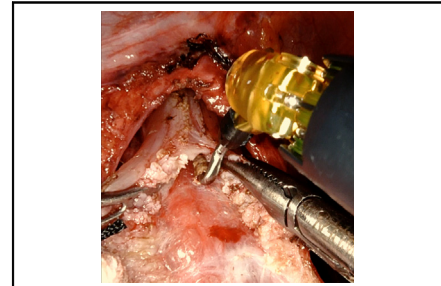
Address for reprints: Suha Kaaki, MD, Department of Cardiothoracic Surgery, Duke University Medical Center, 2530 Erwin Rd, Durham, NC 27705 (E-mail: dr.kaaki@gmail.com).

JTCVS Techniques 2022;16:163-8

2666-2507

Copyright © 2022 The Author(s). Published by Elsevier Inc. on behalf of The American Association for Thoracic Surgery. This is an open access article under the CC BY-NC-ND license (<http://creativecommons.org/licenses/by-nc-nd/4.0/>).

<https://doi.org/10.1016/j.jtc.2022.07.028>



Myotomy edges with submucosa/mucosa intact.

CENTRAL MESSAGE

The Robotic approach to Heller myotomy and Dor fundoplication provides excellent visualization of the layers of the esophageal wall, which helps in decreasing the rate of mucosal injury.

Video clip is available online.

Achalasia is an esophageal motor disorder that is characterized by failure of the lower esophageal sphincter (LES) to relax and loss of peristalsis in the esophageal body.¹ Treatment options focus on releasing the elevated pressure of the LES and include direct botulinum toxin injection, pneumatic dilation, per-oral endoscopic myotomy (POEM), and Heller myotomy. Botulinum toxin's effect is temporary, requiring repeated injections with progressively diminished efficacy over time. The effectiveness of pneumatic dilation has been shown in previous studies. When compared with Heller myotomy, pneumatic dilation was associated with a greater risk of esophageal perforation that required emergency surgery.² POEM is the most recently developed treatment option for achalasia. Its effectiveness in relieving dysphagia has been proven, but the lack of accompanying fundoplication predisposes to increased esophageal reflux.¹ Adding a partial fundoplication, whether anterior or posterior, to Heller myotomy decreases the risk of esophageal reflux from approximately 50% without a fundoplication to less than 10% with a partial fundoplication.³⁻⁵

Until recently, the gold standard treatment of achalasia has been laparoscopic Heller myotomy with partial fundoplication. However, the robotic approach continues to expand its use for foregut operations. Extending the esophageal mediastinal dissection further up into the chest is facilitated

using the robot. It also provides good visualization of the esophageal layers, which translates into an easier and safer myotomy. This robotic approach is described in 12 steps.

METHODS

The technique of robotic Heller myotomy and Dor fundoplication is described in a series of 12 distinct steps, each with an accompanying video. The described approach uses the da Vinci Xi system (Intuitive Surgical).

A list of full instrumentation is provided. No institutional review board/ethical review board approval was required. Informed consent was obtained from the patient for the video recording and its use in education and research.

RESULTS

Instruments

Robotic instruments

1. 8-mm 30° camera (0° optional)
2. Four 8-mm robotic ports
3. Small grasping retractor (liver retractor)
4. Force bipolar grasper
5. Permanent cautery spatula (optional)
6. Vessel sealer
7. Maryland bipolar forceps (optional)
8. Permanent cautery hook
9. Large SutureCut needle driver

Other instruments

1. One 8-mm AirSeal port and one 5-mm step port
2. Step insertion needle
3. Suction irrigator (optional)
4. Two laparoscopic graspers
5. Rolled (cigar) gauze
6. Penrose drain (if hiatal hernia present or posterior wrap performed)
7. 0 TiCron stitches
8. 2 to 0 TiCron stitches
9. 9-cm measuring thread

Operative Steps

1. Patient position (Figure 1): the patient is in supine position with the arms extended. The bed is 27° in reverse Trendelenburg, slid all the way toward the feet and lowered all the way down.
2. Port placement (Figure 2 and Video 1): The Veress needle is used in the left upper quadrant (location 4) to inflate the abdominal cavity with carbon dioxide. Using a 5-mm 30° camera, an 8-mm robotic trocar with a transparent tip obturator is inserted under direct vision. The rest of the trocars are inserted under direct vision, as shown in Figure 1. The 5-mm trocar is inserted with

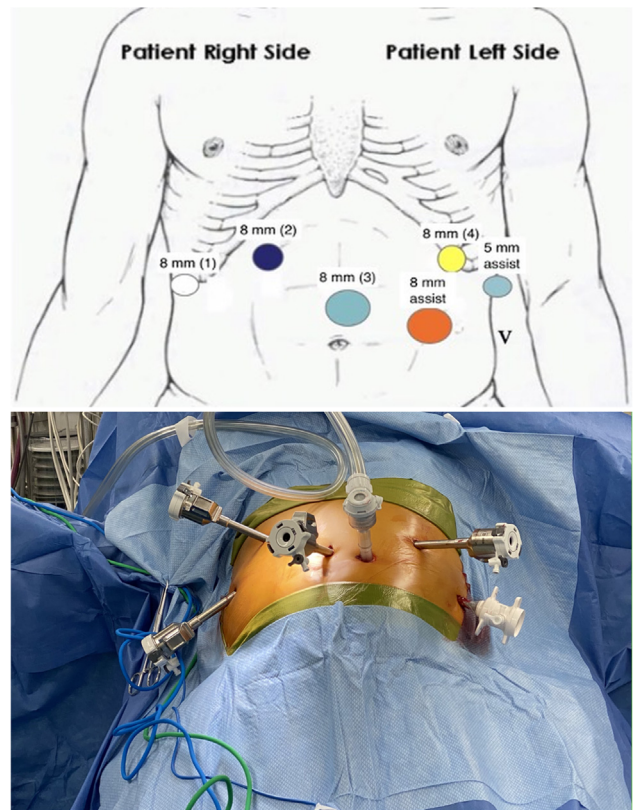


FIGURE 2. Port placement. Port 3: 10 to 15 cm below xyphoid in the midline, which correlates with the caudal end of the falciform ligament. Ports 2 and 4: 4 to 8 cm lateral to port 3 on both sides at the level of the costal margin. Port 1: 4 to 8 cm lateral to port 2 below the costal margin at the inferior to the edge on the liver. 8-mm assistant port: midway between ports 3 and 4 just inferior to the umbilicus. 5-mm assistant port: 4 to 8 cm lateral to port 4 at the level of the costal margin.

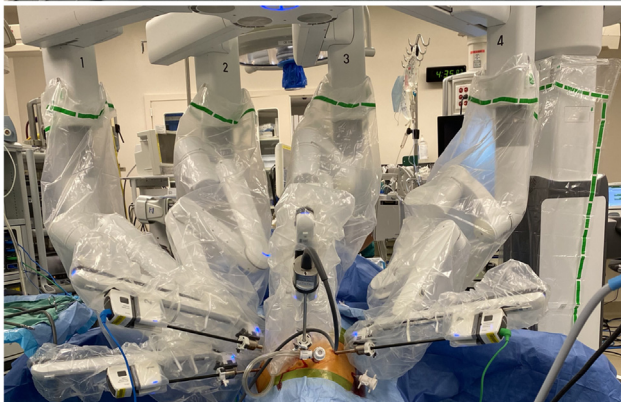
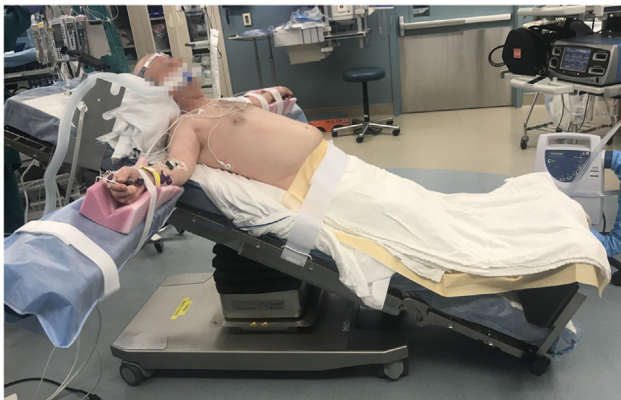
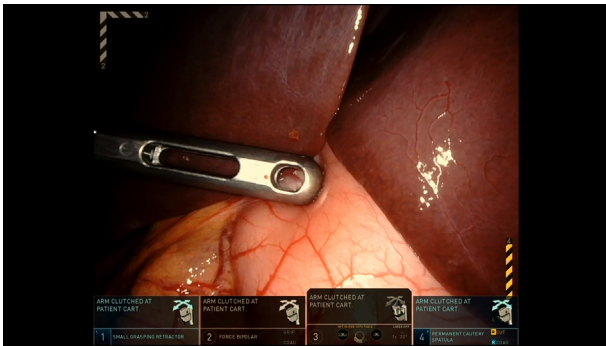
FIGURE 1. Patient position.

the aid of a step needle. The Da Vinci robot is docked, and the arms are connected to the trocars. Robotic arms are arranged as follows:

- (1) small grasping retractor as a liver retractor;
- (2) force bipolar grasper and Maryland bipolar forceps;
- (3) robotic camera; and
- (4) permanent cautery spatula, vessel sealer, permanent cautery hook, and large SutureCut needle driver.

Options to consider to reduce costs by minimizing unique instrument usage include foregoing the Maryland bipolar and using only the forced bipolar in the left working hand. We prefer the hook cautery for the myotomy; therefore, in lieu of the spatula, the hook could be used throughout the procedure. It is possible to tie with the vessel sealer and subsequently avoid the SutureCut needle driver.

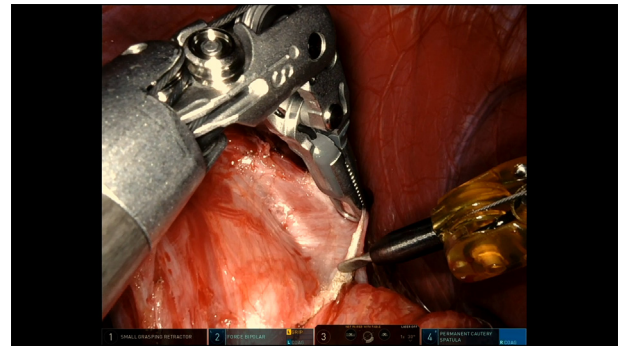
Another point of view on this thought is that replacing specific instruments with others to cut cost might be at the expense of trainees' benefit, since some instruments are



VIDEO 1. Video available at: [https://www.jtcvs.org/article/S2666-2507\(22\)00444-8/fulltext](https://www.jtcvs.org/article/S2666-2507(22)00444-8/fulltext).

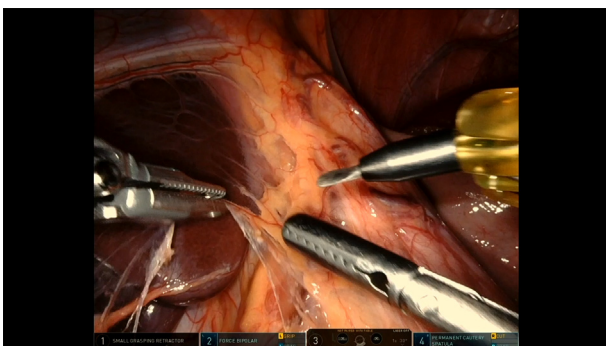
easier to use than others. A balance between these 2 valid points is achieved differently in each institution.

3. Division of the pars lucida (**Video 2**): using the force bipolar grasper and the permanent cautery spatula, the dissection is started by dividing the pars lucida. We generally preserve the hepatic branch of the anterior vagus nerve. The dissection is carried out medially to the hiatus.
4. Dissection of the esophagus off the crura and dissection of the gastric fundus off the left crus (**Video 3**): If a posterior cruraplasty is required or a posterior fundoplication preferred, then the abdominal esophagus can be circumferentially dissected. Otherwise, only the anterior and lateral edges of the esophagus require exposure. The vagus nerves are identified and protected. The right and left crura are dissected clear of surrounding tissue. We make sure to preserve the peritoneal covering of the crura to provide strength to cruroplasty. While dissecting the left crus, the attachments between it and the gastric fundus are taken down.
5. Creation of the posterior window and assessing the need for cruroplasty (as needed): after completion of the dissection around the left crus, further dissection of the base of both crura is done from the right side to create a window behind the abdominal esophagus. A Penrose

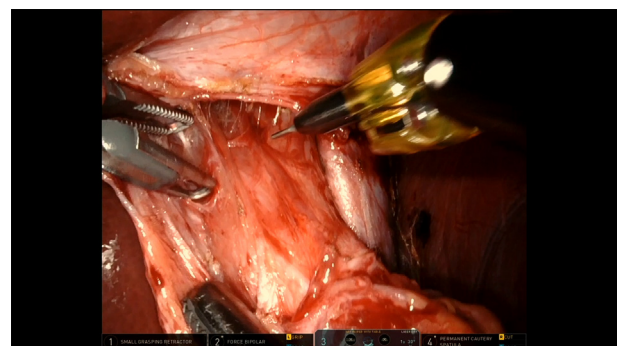


VIDEO 3. Video available at: [https://www.jtcvs.org/article/S2666-2507\(22\)00444-8/fulltext](https://www.jtcvs.org/article/S2666-2507(22)00444-8/fulltext).

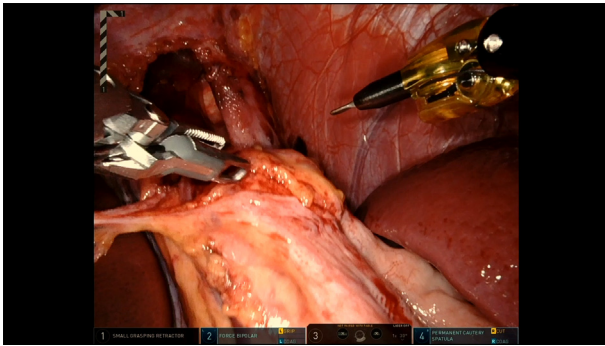
- drain wrapped around the esophagogastric junction (EGJ) to facilitate exposure and assessing the need for cruroplasty. As previously mentioned, this step is required if a posterior fundoplication is preferred, or if there is a concern about associated hiatus hernia.
6. Mediastinal dissection of the esophagus (**Video 4**): Using a combination of blunt and sharp dissection, the thoracic esophagus is dissected from the mediastinal tissues proximal enough for an adequate myotomy. Generally, to the inferior pulmonary veins is more than adequate.
7. Dissection of the fat pad off the EGJ (**Video 5**): after identifying the anterior vagus nerve, the superior edge of the fat pad is dissected off the EGJ to the left of the nerve. The fat pad is elevated off the EGJ and typically taken with the vessel sealer. This provides exposure to continue the myotomy on to the stomach and ensures clear visualization of the EGJ.
8. Takedown of the short gastric vessels (**Video 6**): Using the vessel sealer and the force bipolar grasper, the short gastric vessels are divided off the greater curvature and the gastric fundus with the help of a laparoscopic graspers through the 2 assistant ports. The posterior wall of the stomach is dissected off the retroperitoneum.



VIDEO 2. Video available at: [https://www.jtcvs.org/article/S2666-2507\(22\)00444-8/fulltext](https://www.jtcvs.org/article/S2666-2507(22)00444-8/fulltext).



VIDEO 4. Video available at: [https://www.jtcvs.org/article/S2666-2507\(22\)00444-8/fulltext](https://www.jtcvs.org/article/S2666-2507(22)00444-8/fulltext).



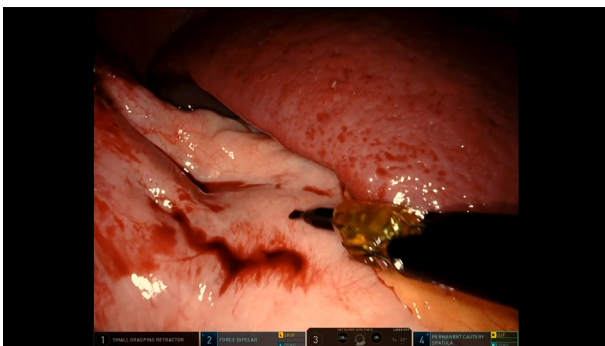
VIDEO 5. Video available at: [https://www.jtcvs.org/article/S2666-2507\(22\)00444-8/fulltext](https://www.jtcvs.org/article/S2666-2507(22)00444-8/fulltext).

Avoiding this step may save some time but lends to fundoplication failure from excessive tension on the fundus.

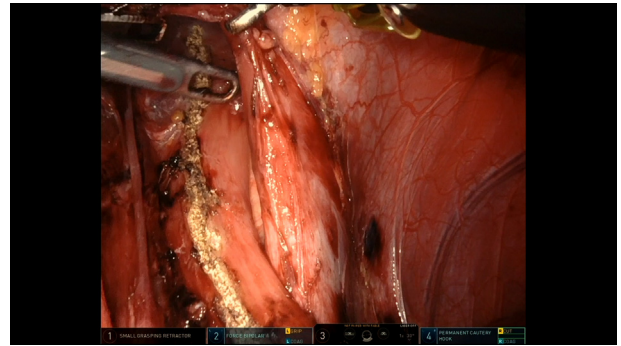
9. Myotomy measurements and Insertion of the gastro-scope to confirm the EGJ location (**Video 7**): Using a 9-cm thread, the length of the myotomy is marked: 3 cm on the stomach and at least 6 cm on the esophagus. The gastro-scope is used to assess the length of the intra-abdominal esophagus. It is left in the stomach while doing the cruroplasty, myotomy, and the fundoplication to help prevent narrowing of the esophagus. The integrity of the mucosa is checked at the end of the procedure before taking the gastro-scope out.

The esophagogastroduodenoscopy is used as a bougie, and at the same time it's used for checking the mucosa, myotomy, and fundoplication at the end of the case. It is inserted under direct vision, which decreases the risk of injury especially before the myotomy is done.

10. Start the myotomy (**Video 8**): The vessel sealer is replaced with the permanent cautery hook, and the force bipolar grasper can be replaced with Maryland grasper, which optimally holds the edges of the myotomy. The myotomy is started on the distal esophagus, where we believe it is easiest to identify, separate, and transect both muscle layers. We extend the myotomy proxi-



VIDEO 6. Video available at: [https://www.jtcvs.org/article/S2666-2507\(22\)00444-8/fulltext](https://www.jtcvs.org/article/S2666-2507(22)00444-8/fulltext).

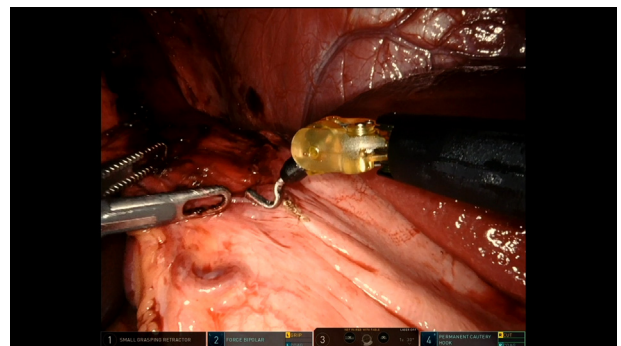


VIDEO 7. Video available at: [https://www.jtcvs.org/article/S2666-2507\(22\)00444-8/fulltext](https://www.jtcvs.org/article/S2666-2507(22)00444-8/fulltext).

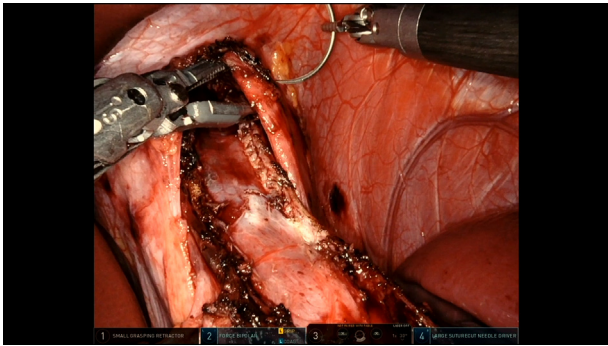
mally on the esophagus by separating first the longitudinal muscle layer, exposing the circular muscle layer. The inner circular layer is carefully dissected from the mucosa for several millimeters, elevated anteriorly and then cauterized. This remains the crux of the procedure and a point at which injury to the mucosa can occur. Once the myotomy is fully started, the muscle transection generally proceeds relatively rapidly proximally and distally.

Some surgeons would prefer doing the myotomy by blunt dissection using the bipolar Maryland forceps, as it can be safer than the L-hook in case of adhesions from previous interventions. The bipolar Maryland forceps is used for blunt dissection to achieve good hemostasis, since the blunt dissection technique is not usually as hemostatic without it.

11. Cruroplasty (as needed) (**Video 9**): with the force bipolar in arm (2) and the large SutureCut in arm (4), 1 or 2 figure-of-eight 0 TiCron stitch are used to approximate the left and right crura posteriorly and/or anteriorly. Occasionally, the anterior crura require some splitting to extend the myotomy proximally and then should be closed. Even small hernias following myotomy can be symptomatic for these patients, so an appropriately sized hiatus is critical for the best long-term success.



VIDEO 8. Video available at: [https://www.jtcvs.org/article/S2666-2507\(22\)00444-8/fulltext](https://www.jtcvs.org/article/S2666-2507(22)00444-8/fulltext).



VIDEO 9. Video available at: [https://www.jtcvs.org/article/S2666-2507\(22\)00444-8/fulltext](https://www.jtcvs.org/article/S2666-2507(22)00444-8/fulltext).

The appropriate size of the hernia is decided on based on the surgeon's judgment, but in general, it should be not tight around the esophagus with the gastroscopie in the stomach, and not too loose to allow herniation.

12. Dor fundoplication (**Video 10**): using five 2 to 0 TiCron stitches the wrap is created.

First stitch: from the tip of the fundus to left edge of the myotomy to the left crus.

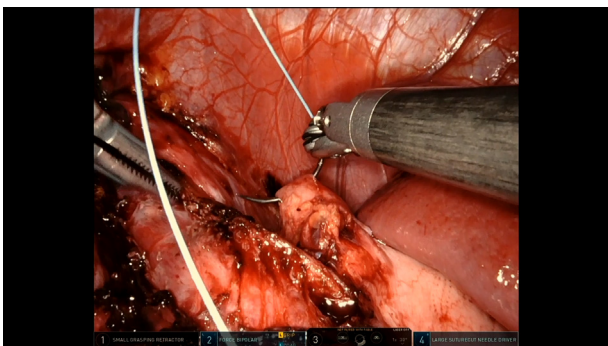
Second stitch: from the base of the fundus (at the angle of His) to the left edge of the myotomy.

Third stitch: after folding the fundus anteriorly on the esophagus, a stitch is taken between the fundus at the line of the divided short gastric vessels to the lateral edge of the right crus at "9 o'clock" on the hiatus. This bite can also incorporate the right lateral edge of the myotomy.

Fourth stitch: from the line of the divided short gastric on the fundus to the right edge of the myotomy to the right crus.

Fifth stitch: typically, fundus to edge of myotomy, but more inferiorly.

The sutured are arranged in this way to help splay the myotomy edges open to minimize the risk of esophageal outflow obstruction.



VIDEO 10. Video available at: [https://www.jtcvs.org/article/S2666-2507\(22\)00444-8/fulltext](https://www.jtcvs.org/article/S2666-2507(22)00444-8/fulltext).

Our keys to a successful Dor fundoplication include:

- (1) appropriate closure of the crura;
- (2) recreation of the angle of His;
- (3) avoid twisting of the distal esophagus/GEJ/cardia; and
- (4) avoid acute angulation across the esophagus.

We prefer to do the Dor over an EGD to help prevent angulation and torsion and to allow for inspection after the creation of the fundoplication.

The gastroscopie is taken out after checking the fundoplication and the integrity of the mucosa. Typically, the EGD The robotic instruments are taken out under direct vision, the robot is undocked, and the incisions are closed.

The patients are kept nothing by mouth on the day of surgery, advanced to clear liquid diet on the following day, then discharged on the second postoperative day on full liquid diet for 2 weeks. The diet is advanced gradually afterwards.

DISCUSSION

The treatment of achalasia continues to evolve over time; however, to date the interventions focus on relieving the inability of the LES to relax. POEM is being used more frequently by gastroenterologists and esophageal surgeons. Due to the concerns of increased esophageal reflux with associated complications, or the need for life-long medical therapy, or requiring additional procedures,¹ for many practitioners treating patients with achalasia, the laparoscopic Heller myotomy with partial fundoplication remains an optimal option for definitive and durable therapy of achalasia.

In addition to POEM, other nonoperative modalities like Botox injection and pneumatic dilation are used by the surgeons. Choosing between these modalities is based mainly on the treating physician's clinical judgment. Patients with hiatus hernias are advised to undergo Heller myotomy with fundoplication; a patient with type 3 achalasia would benefit more from POEM; and for patients who are not very good surgical candidates, nonoperative options would be safer. Counseling the patients after providing full explanation of each modality plays a major role in decision making.

The Da Vinci robotic platform inherently provides several advantages over conventional laparoscopy, and this robotic technology continues to gain popularity with general and thoracic surgeons across the spectrum of surgical diseases. The technical ease and 3-dimensional visualization that the robot delivers are just a few of the advantages that make it a very promising technology for surgeons to explore. Although anecdotally many surgeons believe robot assistance to be beneficial, in reality few studies have compared the outcomes of robotic Heller myotomy with the standard laparoscopic approach and the question of cost-effectiveness remains an important one.

Maeso and colleagues⁶ conducted a meta-analysis that compared the efficacy of the Da Vinci surgical system with laparoscopy in abdominal surgery. This analysis included 3 studies about Heller myotomy. They showed that the rate of perforation was lower with the Da Vinci system (0/102) compared with 11% (17/150) in the laparoscopic group.⁶ The same finding was reported by Perry and colleagues⁷ when they compared the rate of mucosal injury in robotic Heller myotomy with laparoscopy (0 vs 16%, $P = .01$). Similarly, Horgan and colleagues⁸ reported greater rates of esophageal perforation in the laparoscopic group (16%) compared with robotic group (0%) in their series of myotomies.

Shaligram and colleagues⁹ reported in their multicenter, retrospective review that robotic and laparoscopic Heller myotomy were comparable in terms of mortality, morbidity, length of stay, intensive care unit admissions, and 30-day readmissions. However, the cost was significantly greater with the robotic approach, as expected, when compared with the laparoscopic approach (US \$9415 ± 5515 vs US \$7441 ± 7897; $P = .0028$).⁹

In a study done by Huffman and colleagues¹⁰ that compared laparoscopic and robotic Heller myotomy over a 6-year period, the robotic approach was associated with longer operative time (287 ± 9 minutes for laparoscopic cases and 355 ± 23 minutes for robotic cases), but it didn't result in any case of esophageal perforation (vs 3 cases of esophageal perforation in the laparoscopic group).

A learning curve for the robotic approach was demonstrated in the study by Horgan and colleagues⁸ In the first half of the cases, the laparoscopic approach had a significantly shorter operative time but this difference disappeared in the second half of the cases. The operative time (including the robot setup time) for the 59 patients who underwent robotic assisted Heller myotomy was 141 ± 49 minutes. In the last 30 cases, the overall operative time decreased to 108 minutes.⁸ This learning curve for robotic assisted Heller myotomy was reproduced in another study done by Melvin and colleagues.¹¹ The mean operating time decreasing from 163 minutes during the first 2 years of the study to 113 minutes during the last 2 years of the study ($P = .0001$). In addition, there were no cases of esophageal perforation in all 104 patients who were included.¹¹

A recently published meta-analysis, Milone and colleagues¹² compared the effectiveness and safety of the robot-assisted Heller myotomy to the standard laparoscopic approach. There was no difference observed in operative times, conversion rate to open surgery, estimated blood loss, length of hospital stay, or long-term recurrence. The robotic approach was associated with a significantly

lower rate of intraoperative esophageal perforations.¹² In all these studies, the rate of dysphagia resolution postoperatively was comparable for robotic and laparoscopic approaches.

In conclusion, in experienced hands, the robotic platform maybe safer than the standard laparoscopic approach to treating achalasia with decreased perforations being noted by several studies. However, this is controversial, as a more recent registry study suggested increased postoperative complications when using robotic assistance. Regardless, as with all robotic operative techniques, the question of cost-effectiveness remains an important question that needs to be addressed in future studies.

CONCLUSIONS

This 12-step robotic approach to Heller myotomy with Dor fundoplication is a safe and an innovative approach. It paves the way for more foregut surgeries to be done robotically.

References

1. Werner YB, Hakanson B, Martinek J, Repici A, von Rahden BHA, Bredenoord AJ, et al. Endoscopic or surgical myotomy in patients with idiopathic achalasia. *N Engl J Med*. 2019;381:2219-29.
2. Boeckxstaens GE, Annese V, des Varannes SB, Chaussade S, Costantini M, Cuttitta A, et al. Pneumatic dilation versus laparoscopic Heller's myotomy for idiopathic achalasia. *N Engl J Med*. 2011;364:1807-16.
3. Richards WO, Torquati A, Holzman MD, Khaitan L, Byrne D, Lutfi R, et al. Heller myotomy versus Heller myotomy with Dor fundoplication for achalasia: a prospective randomized double-blind clinical trial. *Ann Surg*. 2004;240:405.
4. Kummerow Broman K, Phillips SE, Faqih A, Kaiser J, Pierce RA, Poulouse BK, et al. Heller myotomy versus Heller myotomy with Dor fundoplication for achalasia: long-term symptomatic follow-up of a prospective randomized controlled trial. *Surg Endosc*. 2018;32:1668-74.
5. Brown J, Egger M, Kehdy FJ. Heller myotomy: to wrap or not to wrap? *Am Surg*. 2018;84:1022-6.
6. Maeso S, Reza M, Mayol JA, Blasco JA, Guerra M, Andradas E, et al. Efficacy of the Da Vinci surgical system in abdominal surgery compared with that of laparoscopy: a systematic review and meta-analysis. *Ann Surg*. 2010;252:254-62.
7. Perry KA, Kanji A, Drosdeck JM, Linn JG, Chan A, Muscarella P, et al. Efficacy and durability of robotic Heller myotomy for achalasia: patient symptoms and satisfaction at long-term follow-up. *Surg Endosc*. 2014;28:3162-7.
8. Horgan S, Galvani C, Gorodner MV, Omelanczuck P, Elli F, Moser F, et al. Robotic-assisted Heller myotomy versus laparoscopic Heller myotomy for the treatment of esophageal achalasia: multicenter study. *J Gastrointest Surg*. 2005;9:1020-30.
9. Shaligram A, Unniravi J, Simorov A, Kothari VM, Oleynikov D. How does the robot affect outcomes? A retrospective review of open, laparoscopic, and robotic Heller myotomy for achalasia. *Surg Endosc*. 2012;26:1047-50.
10. Huffman LC, Pandalai PK, Boulton BJ, James L, Starnes SL, Reed MF, et al. Robotic Heller myotomy: a safe operation with higher postoperative quality-of-life indices. *Surgery*. 2007;142:613-20.
11. Melvin WS, Dundon JM, Talamini M, Horgan S. Computer-enhanced robotic telesurgery minimizes esophageal perforation during Heller myotomy. *Surgery*. 2005;138:553-9.
12. Milone M, Manigrasso M, Vertaldi S, Velotti N, Aprea G, Maione F, et al. Robotic versus laparoscopic approach to treat symptomatic achalasia: systematic review with meta-analysis. *Dis Esophagus*. 2019;32:1-8.