



Diagnosis and management of testicular compartment syndrome caused by tension hydrocele

Irene Chen^a, Sohrab Arora^{b,*}, Kenan Alhayek^a, David Leavitt^b, Ali Dabaja^b

^a Wayne State University School of Medicine, 540 Canfield Ave, Detroit, MI, 48201, USA

^b Vattikuti Urology Institute, Henry Ford Health System, 2799 W Grand Blvd, K9, Detroit, MI, 48202, USA

ARTICLE INFO

Keywords:

Hydrocele
Hydrocelectomy
Tension hydrocele

ABSTRACT

A hydrocele is an abnormal collection of fluid within the tunica vaginalis which may either be congenital or acquired. Hydroceles are usually painless and don't require immediate intervention unless they impact activities of daily living. This case demonstrates a rare complication of hydroceles termed tension hydrocele which presented with scrotal swelling and acute pain. Unlike the classic presentation of hydroceles with minimal pain or discomfort, it is important to recognize tension hydroceles as an extremely rare but possible cause of acute scrotum, which needs to be emergently diagnosed and treated.

1. Introduction

A hydrocele is an abnormal collection of fluid within the tunica vaginalis which may either be congenital or acquired.¹ Congenital hydroceles are usually diagnosed in the pediatric population; whereas acquired hydroceles affect about 1% of men, usually found in adults older than 40 years old.² Hydroceles are usually painless and therefore don't require immediate intervention unless it impacts activities of daily living or if they lead to pain. However, there have been a few reports of a rare complication, termed tension hydrocele, where a hydrocele can result in acute scrotal pain, presenting differently than hydroceles and more emergent. Tension hydroceles occur when there is an increase of intraparenchymal vascular resistances and pressure which decreases the amount of circulation to the testicles.² This ultimately results in pain secondary to the mechanism of compartment syndrome in the testicles.²

We are presenting a case of a patient who presented with an acute scrotal swelling and pain diagnosed with tension hydrocele. Despite the classical description of hydrocele as associated with minimal pain or discomfort, it is important to recognize this as an extremely rare but possible cause of acute scrotum, which needs to be emergently diagnosed and treated.

2. Case presentation

A 60-year-old male with history of recurrent nephrolithiasis treated

with extracorporeal shockwave lithotripsy, hypertension, and hyperlipidemia presented to the urology clinic while on vacation for worsening pain in the left side of his scrotum in the last 24 hours. He was diagnosed with a hydrocele 6 weeks prior which was only slightly painful. He also presented to an emergency department 4 days ago with similar symptoms, where an ultrasound showed a large left-sided hydrocele of 10.3cm × 6cm × 8.30cm along with multiple right epididymal head cysts. He was discharged from the emergency department with oral analgesics and asked to follow-up with his urologist upon returning home.

In clinic, his physical exam showed a large, left-sided, tense hydrocele with a nonpalpable testicle and absent cremasteric reflex. An emergent ultrasound in the clinic showed a large left hydrocele measuring 10.6cm × 6.9cm × 7.5cm with arterial waveforms demonstrating absent and intermittent reversal of diastolic flow (Fig. 1), which resulted in him being sent to the emergency department. The patient's basal metabolic profile was unremarkable with a creatinine of 1.05 mg/dL. His complete blood count was unremarkable with no leukocytosis. Urinalysis was negative for nitrite, leukocyte esterase, bacteria, or white blood cells.

Computed tomography (CT) of abdomen and pelvis without intravenous contrast showed a non-obstructive calculus in the mid-left kidney and mid-right kidney and large left scrotal hydrocele.

The hydrocele was emergently treated with aspiration of 210mL of clear yellow fluid which provided immediate pain relief. A repeat

* Corresponding author.

E-mail addresses: irene.chen@med.wayne.edu (I. Chen), sarora3@hfhs.org (S. Arora), kenan.alhayek2@med.wayne.edu (K. Alhayek), dleavitt1@hfhs.org (D. Leavitt), adabaja2@hfhs.org (A. Dabaja).

<https://doi.org/10.1016/j.eucr.2022.102091>

Received 21 March 2022; Accepted 23 April 2022

Available online 25 April 2022

2214-4420/© 2022 The Authors. Published by Elsevier Inc. This is an open access article under the CC BY-NC-ND license (<http://creativecommons.org/licenses/by-nc-nd/4.0/>).

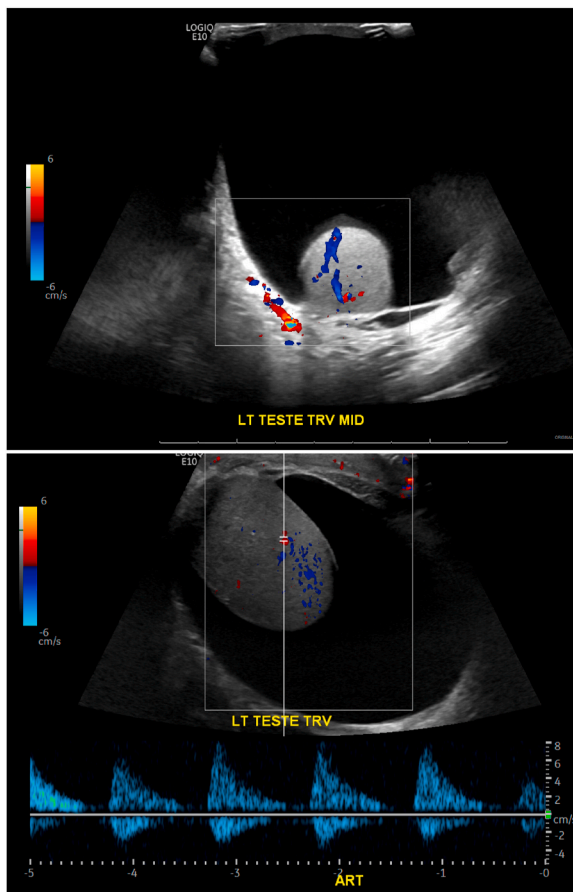


Fig. 1. Scrotal ultrasound demonstrating large left hydrocele with arterial waveforms demonstrating absent and intermittent reversal of diastolic flow in the left testicle.

doppler ultrasound demonstrated improved arterial waveforms compared to the preprocedural study with forward end diastolic flow. Arterial waveforms were demonstrated in the right testicle and venous waveforms were identified in both testicles (Fig. 2).

Although the patient noted significant improvement, he returned to the emergency department the following day with concerns of recurring symptoms. Another ultrasound of the scrotum was performed, showing no compromise to the vasculature. The patient was recommended to have a hydrocelectomy due to recurrence of hydrocele. The patient returned back home and is scheduled for a hydrocelectomy with his regular urologist.

3. Discussion

While the etiology of hydroceles may be congenital or acquired, they are often asymptomatic or minimally symptomatic presentation despite the potential for significant scrotal swelling. Typically, elective treatment of a hydrocele rests upon symptomatic complaints of pain or restraining size. Despite the benign course of the majority of presentations, prior research has demonstrated the possibility for the hydrostatic pressure of a hydrocele to exceed that of the testicular vasculature. Therefore, there exists a point at which the intratesticular pressure would exceed the perfusion pressures of the vasculature, resulting in ischemic compromise.³ In these instances, the fluid pressure may result in malfunction of spermatogenesis as well as hypoxia of the testes. Douglas et al. describes this phenomenon of vascular ischemia as a sort of “compartment syndrome”.⁴ There are instances, however, in which other conditions can induce this style of compartment syndrome.

While this potentiality for testicular ischemia exists, the incidence of

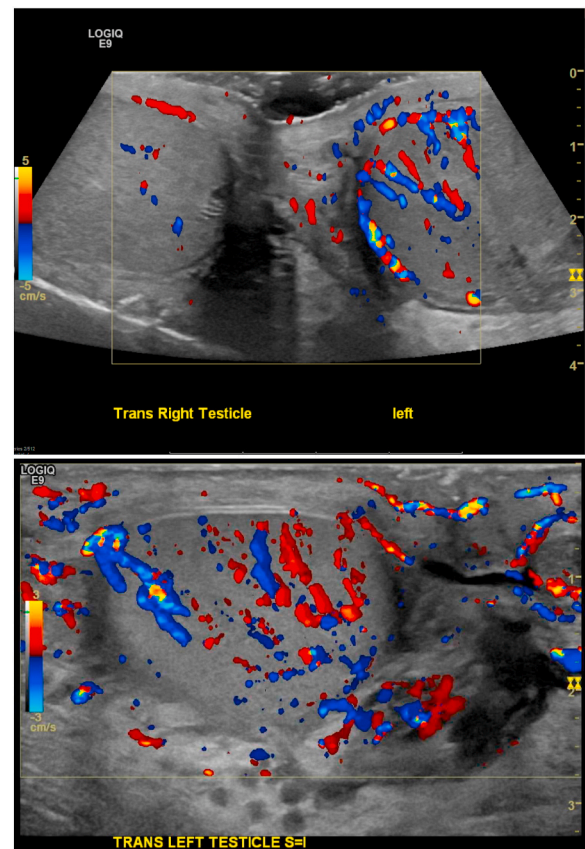


Fig. 2. Color doppler showing increased flow in the left testicle compared to the right improved compared to pre-procedural study now with forward and end diastolic flow. (For interpretation of the references to colour in this figure legend, the reader is referred to the Web version of this article.)

such pathology is exceedingly uncommon. A review of the literature showed a few instances of tension hydrocele resulting in testicular compartment syndrome.^{2,4} Most patients were initially managed conservatively with needle decompression and aspiration of fluid. Then, they were either managed with delayed repair of the hydrocele or observation.^{2,4,5} The literature did show adults and pediatric patients managed with surgical exploration. With duplex ultrasound offering radiographic evidence of impaired intratesticular blood flow, it is understandable the team operated on the presumptive diagnosis of testicular torsion despite the presence of a hydrocele, opting for emergent surgical intervention.⁵ With so few documented cases of tension hydrocele causing vascular flow compression, the decision to opt for surgical intervention over needle decompression is understandable with the risk of testicular loss from torsion.

With sufficient evidence to support the presence of tension hydrocele, our case was managed with decompression by aspiration with delayed hydrocelectomy to follow. With blood flow restored on repeat doppler ultrasonography, testicular torsion no longer remained a concern. Presently, due to the exceedingly uncommon nature of tension hydrocele, the available case reports in literature review provide the evidence for the existence of testicular compartment syndrome.

4. Conclusion

We report a rare case of tension hydrocele which is a complication of hydroceles which can result in acute scrotal pain. It is important to recognize tension hydrocele as a differential diagnosis of acute scrotal pain due to its potential for harm. Tension hydrocele has multiple treatment options such as needle decompression or surgical treatment

for recurrent or symptomatic hydroceles.

Consent

Informed consent obtained from patient and documented in electronic medical record.

Contributions

Ali Dabaja: Conceptualization, Supervision, Writing-Reviewing and Editing; **David Leavitt:** Conceptualization, Supervision, Writing-Reviewing and Editing; **Sohrab Arora:** Conceptualization, Writing-Reviewing and Editing, Project administration; **Irene Chen:** Data curation, Writing-original draft preparation; **Kenan Alhayek:** Writing-Reviewing and Editing.

Funding

This research did not receive any specific grant from funding agencies in the public, commercial, or not-for-profit sectors.

Declarations of interest statement

None.

Acknowledgements

We would like to thank the patient involved in this case report.

References

1. Lundström KJ, Söderström L, Jernow H, et al. Epidemiology of hydrocele and spermatocele; incidence, treatment and complications. *Scand J Urol*. 2019;53:134.
2. Zawaideh JP, Bertolotto M, Giannoni M, et al. Tension hydrocele as an additional cause of acute scrotum: case series and literature review. *Abdom Radiol (NY)*. 2020;45(2082).
3. Wright LA, Gerscovich EO, Corwin MT, et al. Tension hydrocele: additional cause of ischemia of the testis. *J Ultrasound Med*. 2012;31(2041).
4. Douglas J, Hicks J, Manners J, et al. A pressing diagnosis—a compromised testicle secondary to compartment syndrome. *Ann R Coll Surg Engl*. 2008;90:W6.
5. Dagrosa LM, McMenaman KS, Pais Jr VM. Tension hydrocele: an unusual cause of acute scrotal pain. *Pediatr Emerg Care*. 2015;31:584.