



Efficacy of submucosal injection of hyaluronidase after mandibular third molar surgery: a randomized controlled trial

Sanghoon Lee^{1,2}, Hyounmin Kim¹, Woong Nam¹

¹Department of Oral and Maxillofacial Surgery, Yonsei University College of Dentistry,

²Department of Oral and Maxillofacial Surgery, Private Clinic, Seoul, Korea

Abstract (J Korean Assoc Oral Maxillofac Surg 2022;48:363-370)

Objectives: This study aimed to investigate the efficacy of postoperative submucosal injection of hyaluronidase (HUD) for reducing sequelae and quality of life (QOL) after mandibular third molar (M3M) surgery.

Materials and Methods: Participants with bilateral impacted M3M underwent surgical extraction with a split-mouth randomized controlled study design. M3M were removed by the same surgeon in 2 sessions, one a control and the other experimental. Submucosal injection of HUD was performed in the experimental session and submucosal injection of saline in the control session. Mouth opening, facial swelling, and pain intensity were measured before surgery, and then 2 and 7 days after surgery. The QOL of participants following surgery was evaluated by means of a patient-centered outcome questionnaire (PCOQ).

Results: A total of 36 patients was included in the final data analysis. There was a significant reduction in the maximal mouth opening and postoperative pain in the experimental side at the 2 and 7 days after surgery ($P<0.05$), and a remarkable difference in facial swelling was reported on the experimental side 7 days after surgery ($P<0.05$). The PCOQ demonstrated that participants reported less pain and swelling on the experimental side.

Conclusion: The present study provides clinical evidence that submucosal administration of HUD immediately after M3M surgery reduced postoperative discomfort and improved patients' QOL.

Key words: Third molars, Hyaluronidase, Pain, Edema, Trismus

[paper submitted 2022. 8. 13 / revised 2022. 10. 17 / accepted 2022. 10. 24]

I. Introduction

The removal of the mandibular third molar (M3M) is one of the most common surgical procedures in the oral and maxillofacial area. In the immediate postoperative period, inflammatory complications such as swelling, pain, sensitivity, or trismus might occur from surgical damage to the adjacent hard and soft tissue^{1,2}. Preemptive approaches including cold application, postoperative instructions, and medications could prevent or reduce inflammatory complications after M3M removal³. Various medications have been employed to manage

postoperative inflammatory complications through local or systemic administration²⁻⁶.

Hyaluronidase (HUD) is an enzyme that degrades hyaluronic acid (HA), an intercellular base material of the connective tissue⁷, controls the binding force of intercellular space, and facilitates the absorption and diffusion of drugs⁸. In various clinical situations including ophthalmology, pain medicine, dermatology or otorhinolaryngology, HUD has been reported to be effective in reducing edema after surgery⁸, penetration of nerve block anesthetics⁹, and acceleration of wound healing¹⁰, and to have a reversal effect on HA filler¹¹. Submucosal injection of HUD also has been applied for supraglottic airway edema following tracheostomy¹². HUD injection was reported in clinical dentistry several decades ago¹³, but prospective controlled trials for HUD injection after M3M removal are lacking.

In the present study, we primarily aimed to evaluate the efficacy of submucosal HUD injection for postoperative sequelae (mouth opening limitations, facial swelling, and pain) immediately after surgical extraction of the M3M. Second-

Woong Nam

Department of Oral and Maxillofacial Surgery, Yonsei University College of Dentistry, 50-1 Yonsei-ro, Seodaemun-gu, Seoul 03722, Korea

TEL: +82-2-2228-2971

E-mail: omsnam@yuhs.ac

ORCID: <https://orcid.org/0000-0003-0146-3624>

© This is an open-access article distributed under the terms of the Creative Commons Attribution Non-Commercial License (<http://creativecommons.org/licenses/by-nc/4.0/>), which permits unrestricted non-commercial use, distribution, and reproduction in any medium, provided the original work is properly cited.

Copyright © 2022 The Korean Association of Oral and Maxillofacial Surgeons.

arily, we applied a patient-centered outcome questionnaire (PCOQ) for evaluation of the impact of HUD on the individual's quality of life (QOL) after M3M surgery.

II. Materials and Methods

1. Study design and sample

This study was conducted as a double-blinded, randomized controlled trial from November 2018 through September 2019. A total of 48 participants were recruited, and each M3M site (left or right side) was randomly assigned to the experimental or control group. The inclusion and exclusion criteria are shown in Table 1. The Institutional Review Board (IRB) of Yonsei University Dental Hospital approved the study (IRB No. 2-2018-0021). All participants were informed

Table 1. The inclusion and exclusion criteria of the study

Inclusion criteria	Exclusion criteria
<ul style="list-style-type: none"> • Ages between 18 and 70 years old • Bilateral impacted M3M with similar difficulty¹ • Well-controlled underlying medical conditions • Compliance with the study following voluntary participation 	<ul style="list-style-type: none"> • Unilateral impacted M3M • Significant medical conditions affecting immune response and wound healing • Edema for any reason before surgery • History of adverse effects to any drugs to be administered during the study period • Pregnant or lactating woman • Long-term use of drugs that affect systemic inflammatory response

(M3M: mandibular third molar)

¹Difficulty of M3M surgery was based on Winter, Pell, and Gregory classifications and Pederson's index.

Sanghoon Lee et al: Efficacy of submucosal injection of hyaluronidase after mandibular third molar surgery: a randomized controlled trial. J Korean Assoc Oral Maxillofac Surg 2022

about the study protocol and potential perioperative risks before obtaining their written informed consent. All procedures of the study involving human participants were in accordance with the Declaration of Helsinki (1964) and its later amendments or comparable ethical standards.

2. Study protocol

Surgical extraction of M3M was performed at the Department of Oral and Maxillofacial Surgery of Yonsei University Dental Hospital. All surgeries were performed by a single surgeon (W.N.) under local anesthesia. Surgical difficulty index (DI) was based on tooth angulation by Winter¹⁴, ramus/occlusal relationship by Pell and Gregory¹⁵, and Pederson's index¹⁶. (Table 2) Vital signs (systolic, diastolic blood pressure, and pulse rate) were verified before and after M3M surgery. Participants underwent consecutive M3M surgeries, which consisted of a first and second session, in order of random assignments. On the experimental side, the buccal mucoperiosteal flap was appropriately elevated and M3M was extracted with odontomy and ostectomy under local anesthesia (2% lidocaine hydrochloride with 1:100,000 epinephrine; Huons, Seongnam, Korea). The flap was adapted to the wound margin and sutured after submucosal injection of HUD 1,500 international units (IU)/mL (Hirax; BMI Korea, Jeju, Korea) A total of 1.0 mL was injected in the base of a mucoperiosteal flap, 0.5 mL in the mesial margin, and 0.5 mL in the distal margin. On the control side, a saline solution of 1.0 mL was administered as a placebo in the same manner. Every participant received oral medication including antibiotics (cefcapene pivoxil 100 mg three times per day), an analgesic (ibuprofen 200 mg three times per day) for three

Table 2. Difficulty index of mandibular third molar (M3M) surgery in relation to mandibular second molar (M2M)

Parameter	Score	
Spatial relationship with M2M ¹		
Mesioangular	Long axis of M3M parallel to M2M	1
Horizontal	Long axis of M3M perpendicular to M2M	2
Vertical	Long axis of M3M inclined in mesial direction to M2M	3
Distoangular	Long axis of M3M inclined in distal direction to M2M	4
Depth of impaction in relation to occlusal of M2M ²		
Position A	Uppermost portion of M3M is located at or above OP of M2M	1
Position B	Uppermost portion of M3M is located between OP and cervical line of M2M	2
Position C	Uppermost portion of M3M is located below cervical line of M2M	3
Available space in relation between mandibular ramus and distal part of M2M ²		
Class I	Sufficient space between MR and distal part of M2M for accommodation of the mesio-distal width of M3M	1
Class II	Not enough space between MR and distal part of M2M for accommodation of the mesio-distal width of M3M	2
Class III	All or most of M3M is in MR	3
Total score		3 to 10

(OP: occlusal plane, MR: ramus of the mandible)

¹Described by Winter¹⁴. ²Described by Pell and Gregory¹⁵.

Total score of three parameters is categorized as follows: minimally difficult, 3-4; moderately difficult, 5-7; very difficult, 8-10.

Sanghoon Lee et al: Efficacy of submucosal injection of hyaluronidase after mandibular third molar surgery: a randomized controlled trial. J Korean Assoc Oral Maxillofac Surg 2022

days after M3M surgery. For participants with allergies to antibiotics, alternative antibiotics (clindamycin 150 mg 4 times per day or ciprofloxacin 250 mg 2 times per day) were prescribed. If a participant suffered moderate pain (numeric rating scale [NRS] from 4 to 6) despite the administration of the drug, additional antipyretic analgesic (acetaminophen 650 mg) was recommended.

3. Data collection

Before and on days 2 and 7 after surgery (preOP, POD2, and POD7), postoperative sequelae including mouth opening and facial swelling were recorded with linear measurement. Mouth opening as a maximal interincisal distance was

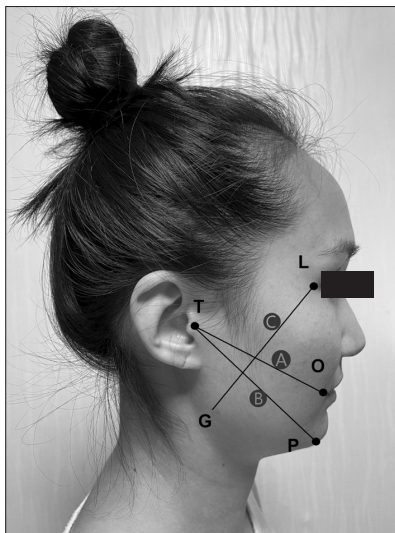


Fig. 1. Reference points in linear measurement for facial swelling. A: tragus (T)-oral commissure (O), B: tragus-pogonion (P), C: lateral canthus (L)-gonion (G). Facial swelling was calculated as a sum of three linear measurements.

Sanghoon Lee et al: Efficacy of submucosal injection of hyaluronidase after mandibular third molar surgery: a randomized controlled trial. *J Korean Assoc Oral Maxillofac Surg* 2022

measured with a metal ruler. Facial swelling was measured with a tape measure and calculated as the sum of three linear measurements along reference points. The reference points included the tragus, a small cartilaginous prominence in front of the external auditory canal of the ear; oral commissure, corner of the mouth; pogonion, the most anterior point of the chin on the mandible in the midline; lateral canthus, outer corner of the eye; and gonion, the most inferior, posterior, and lateral point on the angle of the mandible.(Fig. 1) The amount of change of linear measurement from preOP to POD2 (Δ POD2-preOP) and from preOP to POD7 (Δ POD7-preOP) were calculated as the amount of facial swelling and compared between the control and experimental sides. The degree of pain was also measured via a NRS ranging from 0 to 10.

HUD has already been approved for use, and the side effects or safety risks were minimal. However, if an adverse drug reaction occurred, the participant would be eliminated from the clinical trial and treatment of the adverse reaction prioritized. At any time during the clinical trial, participants could voluntarily withdraw for any reason, and investigators also had the authority to exclude participants from a clinical trial. A completion of the clinical trial for each patient was defined as accomplishing all processes including clinical procedures and examination as specified in the clinical trial protocol.

4. Questionnaire

A PCOQ was completed by participants at POD2 and POD7. Each participant was instructed to complete a total of 13 questions which were based on the OHIP (Oral Health Impact Profile) by Slade and Spencer¹⁷. Each item was scored as follows: never, 1; hardly ever, 2; occasionally, 3; fairly often, 4; and very often, 5.(Table 3)

Table 3. Patient-centered outcome questionnaire (PCOQ) for assessment of postoperative quality of life

After third molar surgery	Never	Hardly ever	Occa-sionally	Fairly often	Very often
1. I have had pain in my mouth.	1	2	3	4	5
2. I have taken additional pain medicine.	1	2	3	4	5
3. I have felt my facial appearance change (swelling).	1	2	3	4	5
4. I have had bleeding in my mouth.	1	2	3	4	5
5. I have had an unpleasant liquid in my mouth.	1	2	3	4	5
6. I have an unpleasant smell in my mouth.	1	2	3	4	5
7. I have felt it uncomfortable to eat.	1	2	3	4	5
8. I have had trouble pronouncing words.	1	2	3	4	5
9. I have found it uncomfortable to open my mouth.	1	2	3	4	5
10. I have had difficulty with daily activities.	1	2	3	4	5
11. I have felt that life in general is less satisfying.	1	2	3	4	5
12. I have been uncomfortable sleeping.	1	2	3	4	5
13. I have been a bit embarrassed.	1	2	3	4	5

Sanghoon Lee et al: Efficacy of submucosal injection of hyaluronidase after mandibular third molar surgery: a randomized controlled trial. *J Korean Assoc Oral Maxillofac Surg* 2022

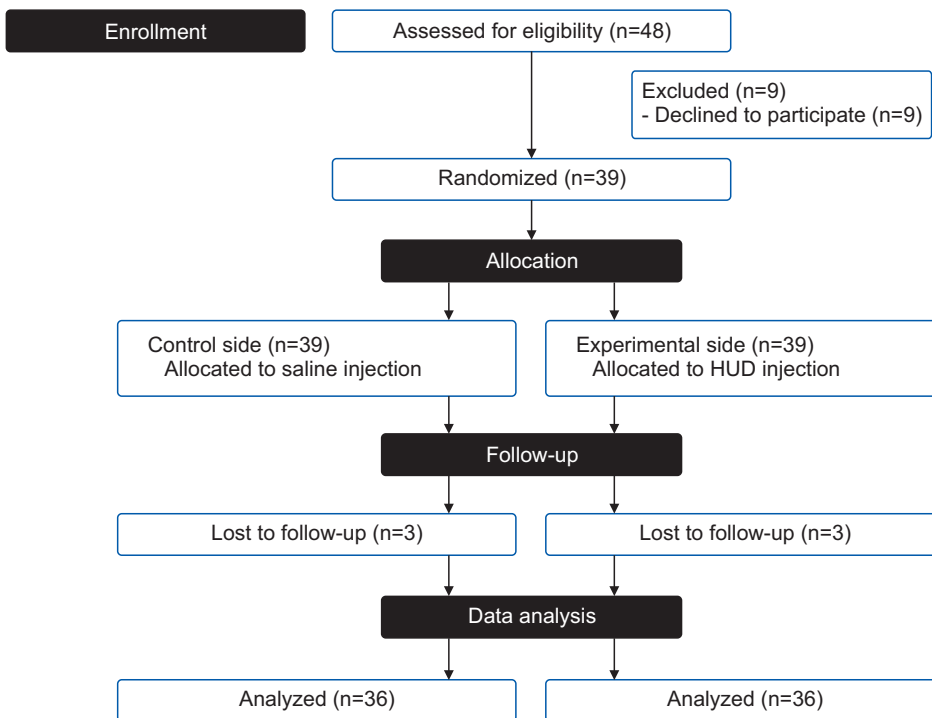


Fig. 2. Consolidated Standards of Reporting Trials (CONSORT) flow diagram. (HUD: hyaluronidase) Sanghoon Lee et al: Efficacy of submucosal injection of hyaluronidase after mandibular third molar surgery: a randomized controlled trial. J Korean Assoc Oral Maxillofac Surg 2022

5. Statistical analysis

Statistical analysis was performed with the final data obtained by distortion correction. A descriptive analysis was used for each variable and surgical difficulty between the control and experimental sides was compared using the Wilcoxon signed rank test. Statistical significance was analyzed for differences in linear measurement values or postoperative sequelae (mouth opening, facial swelling, and pain) between control and experimental sides. Analysis of variance using repeated measures was used to compare the outcome variables. All data acquisition and analyses were performed with Microsoft Excel, Microsoft 365 (Microsoft, Redmond, WA, USA) and IBM SPSS Statistics software for Windows (ver. 22.0; IBM, Armonk, NY, USA). A P -value of <0.05 was considered statistically significant.

III. Results

A total of 36 patients (17 males and 19 females) who had fulfilled the follow-up visits and completed the PCOQ were included in the final data analysis.(Fig. 2) The mean age of patients was 24.7 ± 5.35 years (range, 18-42 years). There was no significant difference in DI of M3M between the control and experimental sides ($P=0.099$).

1. Mouth opening

There was no statistical difference in baseline value of mouth opening between the control and experimental sides at preOP ($P=0.713$). After surgery, the experimental side demonstrated less change in the mouth opening than the control side at POD2 and POD7 ($P=0.028$ and 0.001).(Fig. 3. A)

2. Facial swelling

There was no statistical difference in baseline facial swelling between the control and experimental sides at preOP, POD2, and POD7 ($P=0.061$, 0.409 , and 0.352). The experimental side demonstrated significantly less change at POD2 (Δ POD2–preOP) and POD7 (Δ POD7–preOP) based on preOP than the control side ($P=0.027$). Also, Δ POD7–preOP showed less difference between the control and experimental sides compared with Δ POD2–preOP.(Fig. 3. B)

3. Pain

The mean postoperative pain score in the control and experimental sides was 4.26 ± 2.30 and 1.90 ± 1.45 at POD2 and 2.15 ± 1.35 and 0.83 ± 1.05 at POD7, respectively. The experimental side showed a significantly lower pain score than the control side at POD2 and POD7 ($P=0.000$ and 0.001).(Fig. 3. C)

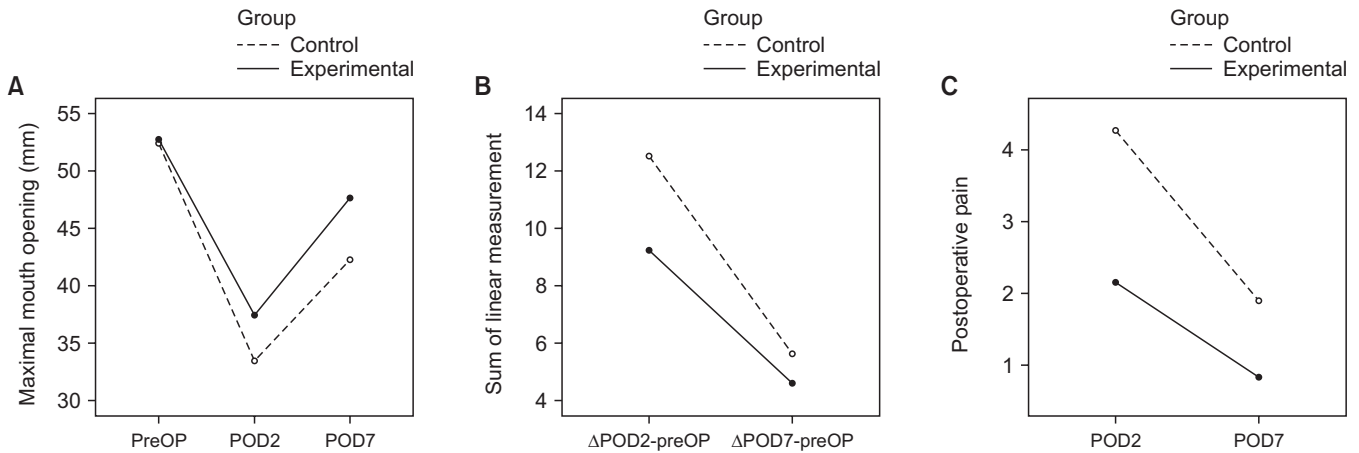


Fig. 3. A. Mouth opening: Experimental side showed less amount of change in mouth opening at 2 and 7 days after surgery (POD2 and POD7) ($P=0.028$ and 0.001). B. Facial swelling: The amount of change of facial swelling revealed that there was a significant difference between control and experimental sides over time ($P=0.027$). C. Pain: Experimental side showed a significantly lower pain score at POD2 and POD7 ($P<0.01$ and 0.01). (preOP: before surgery)

Sanghoon Lee et al: Efficacy of submucosal injection of hyaluronidase after mandibular third molar surgery: a randomized controlled trial. *J Korean Assoc Oral Maxillofac Surg* 2022

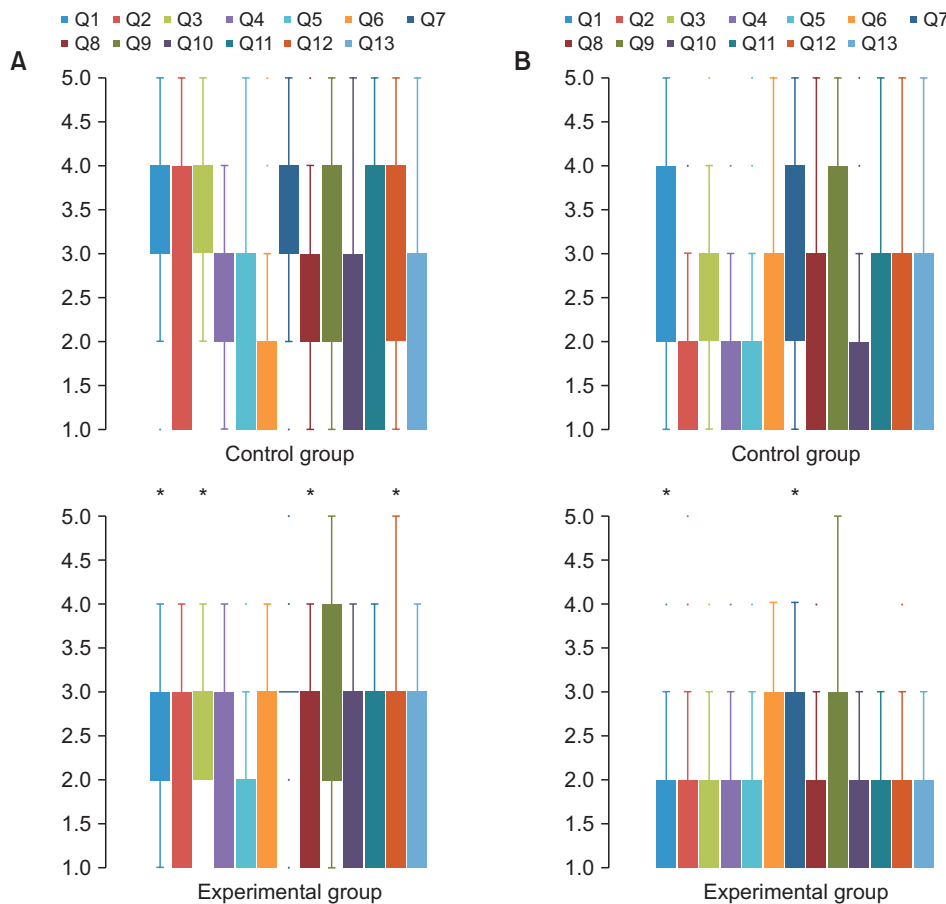


Fig. 4. A. At 2 days after surgery, the experimental side showed a significantly lower score than the control side, which indicated less discomfort after hyaluronidase (HUD) injection in Q1, Q3, Q8, and Q12 ($P=0.000$, 0.000 , 0.027 , and 0.023). B. At 7 days after surgery, experimental side showed significantly less discomfort after HUD injection in Q1 and Q7 ($P=0.001$ and 0.002). Asterisks (*) indicate statistically significant difference between the groups.

Sanghoon Lee et al: Efficacy of submucosal injection of hyaluronidase after mandibular third molar surgery: a randomized controlled trial. *J Korean Assoc Oral Maxillofac Surg* 2022

4. PCOQ

At POD2, the experimental side showed a significantly lower score than the control side, indicating less discomfort after HUD injection in Q1 (pain), Q3 (swelling), Q8 (pronun-

ciation), and Q12 (sleep) ($P<0.05$). (Fig. 4. A) At POD7, the experimental group showed significantly less discomfort after HUD injection in Q1 (pain) and Q7 (food intake) ($P<0.05$). (Fig. 4. B)

5. Adverse effects

Vital signs verified before and after M3M surgery and HUD injection were within normal range. HUD related adverse events were not observed in the control arm.

IV. Discussion

Previous studies assessed various modalities including systemic or local corticosteroids^{3,18,19}, natural substance², platelet concentrates^{20,21}, and adjuvant laser therapy²² for reducing postoperative swelling and trismus or pain after surgical extraction of M3M. For several decades in the area of dentistry or maxillofacial surgery, HUD, has been investigated in only a few studies regarding postoperative swelling after guided bone regeneration (GBR) with simultaneous dental implant placement²³ or efficacy of anesthesia for irreversible pulpitis⁹. HUD was effective in reducing swelling at the site of GBR in maxilla²³ and for increased duration of block anesthesia of the inferior alveolar nerve with lidocaine⁹. In the present study, the local administration of HUD was evaluated in M3M surgery, which is one of the most common procedures in oral and maxillofacial surgery. We also estimated the QOL of patients during the postoperative period via PCOQ.

The present study revealed a significant reduction of postoperative discomfort, including limitation of the mouth opening, facial swelling, and pain, at POD2 and POD7 on the experimental side. Like previous studies regarding the local administration of other drugs including submucosal dexamethasone or methylprednisolone¹⁹, trismus was significantly reduced on the HUD side. Several studies have reported that injection of HUD could alleviate postoperative or posttraumatic facial swelling. Kwoen et al.²³ reported that postoperative swelling after GBR with simultaneous dental implant placement was lower in the HUD group, and this result was more effective in the maxilla. In a clinical study of closed reduction surgery after nasal bone fracture, the duration from injury to surgery was significantly lower in the HUD group than the control group, leading to improved patient satisfaction resulting from earlier discharge and return to their daily life²⁴. Unlike postoperative swelling, few studies have presented data on postoperative pain related to HUD after oral and maxillofacial surgery. Contrary to the results of the present study, Kwoen et al.²³ reported that no statistically significant difference was found between HUD and control groups. Due to ethical reasons related to clinical study, the evaluation of pain might be difficult because the participants were instructed to

take an analgesic as needed for unbearable pain.

In the PCOQ, participants reported a significant improvement on the experimental side in speaking and sleeping at POD2 and in food intake at POD7 after M3M surgery. Due to spontaneous improvement of postoperative morbidities over time, the amount of difference between the control and experimental sides decreased at POD7. However, split-mouth design could induce a bias for the interpretation of PCOQ²⁵. For instance, the patient's experience of M3M surgery in the first session could affect the response to M3M surgery in subsequent sessions. Contamination or spilling from one side (the experimental or control side) could affect the other side (the experimental or control side). Considering the limitations of the split-mouth randomized controlled trial design, a careful interpretation of the study results is required.

The mechanism of HUD action has been suggested in several studies. By degrading HA in the extracellular matrix (ECM), HUD reduces HA viscosity and increases membrane permeability. Disruption of the ECM barrier increases tissue diffusion and resorption of excess fluids into the systemic circulation⁷. *In vivo* and clinical studies have documented the consequent anti-edema effect of HUD^{12,26,27}. By resolving ground substance of the connective tissue, HUD was shown to be effective in early treatment of hematoma and fibrosis^{28,29}. Furthermore, HUD regulates inflammatory response by decreasing the infiltration of inflammatory mediators such as neutrophils to the inflammatory site⁸ or increasing anti-inflammatory cytokines including TNF α (tumor necrosis factor alpha), interleukin (IL)-1 α , IL-4, and IL-10, thus promoting wound healing¹⁰.

Allergic reaction to HUD is uncommon³⁰. In this study, no participants showed any adverse effects after HUD injection. However, several cases of HUD hypersensitivity have been documented, being characterized by erythematous edema associated with immediate and delayed hypersensitivity reactions^{31,32}. Since most medical HUD is made of proteins derived from bovine, ovine, and caprine sources, the risk of hypersensitivity should be considered before HUD administration in patients allergic to bovine collagen and bee stings³³. To screen the adverse reactions, a preliminary skin test of HUD with 3 IU has been recommended^{11,31,34}. In addition to allergic reaction, areas where local infection such as acute pericoronitis or chronic abscess exist, HUD is also not indicated because it may facilitate spread of the infection.

A limitation of this study was lack of positive control employing conventional modalities such as local or systemic administration of corticosteroids. Considering the low cost

and easy access to conventional anti-inflammatory agents, the benefits of HUD should be comparatively analyzed. Further studies are required before wide clinical use, including comparison of the efficacy between HUD and conventional anti-inflammatory agents and also standardization of HUD concentration.

V. Conclusion

Despite the limitations of the present study, local injection of HUD could be an efficient modality in reducing postoperative sequelae, suggesting that HUD could be an effective preemptive modality for M3M surgery patients when conventional anti-inflammatory agents are restricted due to adverse effects.

ORCID

Sanghoon Lee, <https://orcid.org/0000-0001-9324-0596>

Hyounmin Kim, <https://orcid.org/0000-0002-1900-4744>

Woong Nam, <https://orcid.org/0000-0003-0146-3624>

Authors' Contributions

W.N. conceived the idea and S.L. designed the study. H.K. and S.L. reviewed the medical records and contributed to data acquisition. S.L. analyzed the data and prepared the manuscript. W.N. provided guidance for all aspects of the study and critical revision of the article. All authors reviewed and approved the final version of the manuscript.

Ethics Approval and Consent to Participate

The IRB of Yonsei University Dental Hospital approved the study (IRB No. 2-2018-0021). The written informed consent was obtained from all participants.

Consent for Publishing Photographs

Written informed consent was obtained from the patients for publication of this article and accompanying images.

Conflict of Interest

No potential conflict of interest relevant to this article was reported.

References

- Duarte-Rodrigues L, Miranda EFP, Souza TO, de Paiva HN, Falci SGM, Galvão EL. Third molar removal and its impact on quality of life: systematic review and meta-analysis. *Qual Life Res* 2018;27:2477-89. <https://doi.org/10.1007/s11136-018-1889-1>
- Majid OW, Al-Mashhadani BA. Perioperative bromelain reduces pain and swelling and improves quality of life measures after mandibular third molar surgery: a randomized, double-blind, placebo-controlled clinical trial. *J Oral Maxillofac Surg* 2014;72:1043-8. <https://doi.org/10.1016/j.joms.2013.12.035>
- Al-Dajani M. Can preoperative intramuscular single-dose dexamethasone improve patient-centered outcomes following third molar surgery? *J Oral Maxillofac Surg* 2017;75:1616-26. <https://doi.org/10.1016/j.joms.2017.03.037>
- Xie L, Sang L, Li Z. Does low dose of etoricoxib play pre-emptive analgesic effect in third molar surgery? A randomized clinical trial. *BMC Oral Health* 2021;21:462. <https://doi.org/10.1186/s12903-021-01837-0>
- Lim D, Ngeow WC. A comparative study on the efficacy of submucosal injection of dexamethasone versus methylprednisolone in reducing postoperative sequelae after third molar surgery. *J Oral Maxillofac Surg* 2017;75:2278-86. <https://doi.org/10.1016/j.joms.2017.05.033>
- Sugragan C, Sirintawat N, Kiattavornchareon S, Khoo LK, Kc K, Wongsirichat N. Do corticosteroids reduce postoperative pain following third molar intervention? *J Dent Anesth Pain Med* 2020;20:281-91. <https://doi.org/10.17245/jdapm.2020.20.5.281>
- Buhren BA, Schrupf H, Hoff NP, Bölke E, Hilton S, Gerber PA. Hyaluronidase: from clinical applications to molecular and cellular mechanisms. *Eur J Med Res* 2016;21:5. <https://doi.org/10.1186/s40001-016-0201-5>
- Fronza M, Muhr C, da Silveira DS, Sorgi CA, Rodrigues SF, Farsky SH, et al. Hyaluronidase decreases neutrophils infiltration to the inflammatory site. *Inflamm Res* 2016;65:533-42. <https://doi.org/10.1007/s00011-016-0935-0>
- Satish SV, Shetty KP, Kilaru K, Bhargavi P, Reddy ES, Bellutgi A. Comparative evaluation of the efficacy of 2% lidocaine containing 1:200,000 epinephrine with and without hyaluronidase (75 IU) in patients with irreversible pulpitis. *J Endod* 2013;39:1116-8. <https://doi.org/10.1016/j.joen.2012.11.049>
- Fronza M, Caetano GF, Leite MN, Bitencourt CS, Paula-Silva FW, Andrade TA, et al. Hyaluronidase modulates inflammatory response and accelerates the cutaneous wound healing. *PLoS One* 2014;9:e112297. <https://doi.org/10.1371/journal.pone.0112297>
- Wu L, Liu X, Jian X, Wu X, Xu N, Dou X, et al. Delayed allergic hypersensitivity to hyaluronidase during the treatment of granulomatous hyaluronic acid reactions. *J Cosmet Dermatol* 2018;17:991-5. <https://doi.org/10.1111/jocd.12461>
- Venkatesh KH, Rao GS. Treatment of supraglottic airway edema by local hyaluronidase. *Anesthesiology* 2007;106:1254-5. <https://doi.org/10.1097/01.anes.0000265425.52996.fc>
- Henkel GH. The role and applicability of hyaluronidase in clinical dentistry. *Oral Surg Oral Med Oral Pathol* 1956;9:463-92. [https://doi.org/10.1016/0030-4220\(56\)90125-6](https://doi.org/10.1016/0030-4220(56)90125-6)
- Winter GB. Principles of exodontia as applied to the impacted mandibular third molar: a complete treatise on the operative technic with clinical diagnoses and radiographic interpretations. St. Louis (MO): American medical Book Company; 1926.
- Pell GJ, Gregory GT. Report on a ten-year study of a tooth division technique for the removal of impacted teeth. *Am J Orthod Oral Surg* 1942;28:B660-6. [https://doi.org/10.1016/S0096-6347\(42\)90021-8](https://doi.org/10.1016/S0096-6347(42)90021-8)
- Pederson GW. Oral surgery. Philadelphia (PA): WB Saunders; 1988.

17. Slade GD, Spencer AJ. Development and evaluation of the oral health impact profile. *Community Dent Health* 1994;11:3-11.
18. Koçer G, Yuce E, Tuzuner Oncul A, Dereci O, Koskan O. Effect of the route of administration of methylprednisolone on oedema and trismus in impacted lower third molar surgery. *Int J Oral Maxillofac Surg* 2014;43:639-43. <https://doi.org/10.1016/j.ijom.2013.11.005>
19. Warraich R, Faisal M, Rana M, Shaheen A, Gellrich NC, Rana M. Evaluation of postoperative discomfort following third molar surgery using submucosal dexamethasone - a randomized observer blind prospective study. *Oral Surg Oral Med Oral Pathol Oral Radiol* 2013;116:16-22. <https://doi.org/10.1016/j.ooolo.2012.12.007>
20. Bilginaylar K, Uyanik LO. Evaluation of the effects of platelet-rich fibrin and piezosurgery on outcomes after removal of impacted mandibular third molars. *Br J Oral Maxillofac Surg* 2016;54:629-33. <https://doi.org/10.1016/j.bjoms.2016.03.016>
21. Starzyńska A, Kaczoruk-Wieremczuk M, Lopez MA, Passarelli PC, Adamska P. The growth factors in advanced platelet-rich fibrin (A-PRF) reduce postoperative complications after mandibular third molar odontectomy. *Int J Environ Res Public Health* 2021;18:13343. <https://doi.org/10.3390/ijerph182413343>
22. Eshghpour M, Ahrari F, Takallu M. Is low-level laser therapy effective in the management of pain and swelling after mandibular third molar surgery? *J Oral Maxillofac Surg* 2016;74:1322.e1-8. <https://doi.org/10.1016/j.joms.2016.02.030>
23. Kwoen MJ, Choi YH, Kim KS, Chang NH, Kim YK, Lee HJ. Efficacy of local hyaluronidase administration in guided bone regeneration surgery: a randomized controlled trial. *J Korean Assoc Oral Maxillofac Surg* 2021;47:91-8. <https://doi.org/10.5125/jkaoms.2021.47.2.91>
24. Kim JH, Yang H, Oh SH, Song SH, Kyung H. The efficacy of hyaluronidase in early surgery of nasal bone fracture. *J Craniofac Surg* 2019;30:e617-9. <https://doi.org/10.1097/SCS.0000000000005646>
25. Smail-Faugeron V, Fron-Chabouis H, Courson F, Durieux P. Comparison of intervention effects in split-mouth and parallel-arm randomized controlled trials: a meta-epidemiological study. *BMC Med Res Methodol* 2014;14:64. <https://doi.org/10.1186/1471-2288-14-64>
26. Koç O, Er N. Can hyaluronidase be an alternative postoperative anti-edema agent to dexamethasone? Preliminary results of an animal study. *J Oral Maxillofac Surg* 2018;76:1653-9. <https://doi.org/10.1016/j.joms.2018.03.010>
27. Nekoroski T, Paladini RD, Sauder DN, Frost GI, Keller GA. A recombinant human hyaluronidase sustained release gel for the treatment of post-surgical edema. *Int J Dermatol* 2014;53:777-85. <https://doi.org/10.1111/ijd.12304>
28. Han JH, Kim J, Yoon KC, Shin HW. Treatment of post-traumatic hematoma and fibrosis using hyaluronidase injection. *Arch Craniofac Surg* 2018;19:218-21. <https://doi.org/10.7181/acfs.2017.01396>
29. James L, Shetty A, Rishi D, Abraham M. Management of oral submucous fibrosis with injection of hyaluronidase and dexamethasone in grade III oral submucous fibrosis: a retrospective study. *J Int Oral Health* 2015;7:82-5.
30. Delaere L, Zeyen T, Foets B, Van Calster J, Stalmans I. Allergic reaction to hyaluronidase after retrobulbar anaesthesia: a case series and review. *Int Ophthalmol* 2009;29:521-8. <https://doi.org/10.1007/s10792-008-9258-7>
31. Kim MS, Youn S, Na CH, Shin BS. Allergic reaction to hyaluronidase use after hyaluronic acid filler injection. *J Cosmet Laser Ther* 2015;17:283-5. <https://doi.org/10.3109/14764172.2015.1007069>
32. Kim TW, Lee JH, Yoon KB, Yoon DM. Allergic reactions to hyaluronidase in pain management -a report of three cases-. *Korean J Anesthesiol* 2011;60:57-9. <https://doi.org/10.4097/kjae.2011.60.1.57>
33. Bailey SH, Fagien S, Rohrich RJ. Changing role of hyaluronidase in plastic surgery. *Plast Reconstr Surg* 2014;133:127e-132e. <https://doi.org/10.1097/PRS.0b013e3182a4c282>
34. Zamora-Alejo K, Moore S, Leatherbarrow B, Norris JH, Lake DB, Malhotra R, Selva D, Goggin M. Hyaluronidase toxicity: a possible cause of postoperative periorbital inflammation. *Clin Exp Ophthalmol*. 2013 Mar;41(2):122-6. <https://doi.org/10.1111/j.1442-9071.2012.02834.x>

How to cite this article: Lee S, Kim H, Nam W. Efficacy of submucosal injection of hyaluronidase after mandibular third molar surgery: a randomized controlled trial. *J Korean Assoc Oral Maxillofac Surg* 2022;48:363-370. <https://doi.org/10.5125/jkaoms.2022.48.6.363>