

Primary hypoparathyroidism presenting as basal ganglia calcification secondary to extreme hypocalcemia

Edite Marques Mendes,¹
Lúcia Meireles-Brandão,¹
Carla Meira,² Nuno Morais,²
Carlos Ribeiro,¹ Diana Guerra¹

¹Department of Medicine - Medicine 1; and ²Department of Medicine - Intermediate Care Unit, Unit of Alto Minho, Santa Luzia Hospital, Viana do Castelo, Portugal

Abstract

Hypoparathyroidism is a rare endocrine disorder characterized by low serum calcium and parathyroid hormone levels. The most common cause is parathyroid iatrogenic surgical removal. However, innumerable and rarer conditions can cause hypoparathyroidism. The authors describe a 27-year-old man that presented in emergency department with confusion, amnesia and decreased attention span. A cerebral computed tomography revealed bilateral extensive calcification in the basal ganglia. A complete work-up revealed low serum calcium, high serum phosphorus and low parathyroid hormone, leading to the diagnosis of idiopathic primary hypoparathyroidism. Initial intravenous therapy with calcium gluconate and calcitriol was administered, with clinical and analytical improvement. The authors describe a rare condition, with an exuberant cerebral presentation and extreme hypocalcemia, which did not directly correlate to the severity of symptoms. Not only this is a treatable disorder that may have catastrophic results if overlooked but also its symptoms may be completely reversed with prompt treatment.

Introduction

Primary hypoparathyroidism is a rare endocrine disorder characterized by hypocalcemia due to absence or deficient production of parathyroid hormone (PTH) by parathyroid glands. The most common cause of primary hypoparathyroidism is inadvertent damage to the parathyroid glands during thyroid surgery, constituting 75% of all cases.¹ Non-iatrogenic causes are scarcer, and comprise congenital or acquired diseases. Destruction of parathyroid gland due to autoimmune disorders

(autoimmune polyglandular syndrome type 1), or genetic abnormalities (as isolated mutations or as part of complex genetic syndromes) are some examples of primary hypoparathyroidism causes. Other acquired causes include radiotherapy or infiltrative disease (Wilson's disease, hemochromatosis, metastatic cancer). However, its specificity cause cannot always be promptly identified.²⁻⁵

Since parathyroid hormone is a key calcium-regulating hormone essential for calcium homeostasis, metabolic dysfunction in hypoparathyroidism originate hyperphosphatemia and consequently elevated serum calcium-phosphorus product, resulting in ectopic soft tissue calcifications. Although rarely seen, intracerebral calcifications usually deposit in the lentiform (putamen and globus pallidus) and the caudate nuclei of the basal ganglia. Other organs can be affected, more frequently kidneys (presenting as nephrolithiasis or nephrocalcinosis), but can also be seen in joints, eyes (cataract), skin, vasculature, and other organ systems.^{4,5} Primary hypoparathyroidism can cause a wide spectrum of manifestations, mainly due to low serum calcium effect on internal organs, and directly correlates with the rate of development of hypocalcemia. Acute and chronic hypocalcemia classically presents with tetany and may be clinically asymptomatic or present with trivial symptoms. Conversely, it may manifest as a medical emergency, mainly due to neurologic and cardiovascular life-threatening complications.⁴

In this case not only a rare condition was diagnosed but also it presented exuberant cerebral involvement with extreme hypocalcemia that did not directly correlate to the severity of symptoms. Written informed consent has been obtained from the patient for publication of the submitted article and accompanying images.

Case Report

The authors present a case of a previously healthy 27-year-old male civil engineer who was brought to the emergency department due to memory impairment and decreased attention span with onset early that day. He referred partial amnesia concerning activities such as working and driving, limited to the admission day, accompanied by perioral numbness and hand and feet paresthesias, but no other symptoms. The patient did not perceive any other memory impairment and denied previous neurological or other symptoms. However, contrary to his report, his parents described hyperirritability, fatigue and overall person-

Correspondence: Edite R.S. Marques Mendes, Department of Medicine - Medicine 1, Unit of Alto Minho, Santa Luzia Hospital, Viana do Castelo, Portugal.

Tel.: +351258808366.

E-mail: editemarquesmendes@gmail.com

Key words: Primary hypoparathyroidism; hypocalcemia; basal ganglia calcifications.

Acknowledgments: the authors would like to thank Sara Tavares for her assistance with manuscript preparation.

Contributions: EMM, primary author and patient care; CR, CM, NM, case diagnosis and article review; LM-B, DG, article review.

Conflict of interest: the authors declare no potential conflict of interest.

Received for publication: 17 July 2017.

Revision received: 6 October 2017.

Accepted for publication: 11 October 2017.

This work is licensed under a Creative Commons Attribution NonCommercial 4.0 License (CC BY-NC 4.0).

©Copyright E.M. Mendes et al., 2018
Licensee PAGEPress, Italy
Clinics and Practice 2018; 8:1007
doi:10.4081/cp.2018.1007

ality deterioration leading to lifestyle changes over the past two years. In the past months, gradually decreasing organizational skills, and decreased attention span was noticeable by his parents, although initially depreciated by the patient and interpreted as work-related fatigue.

An extensive medical history including familiar history was additionally performed. He had no history of neck surgery, seizure, head trauma, fever or headache. There was no family history of similar problems, other autoimmune endocrinopathies, immunodeficiencies or other congenital defects. On physical examination, vital signs were normal (blood pressure 120/85 mmHg, pulse 75 beat/min, respiratory rate 15/min, and body temperature: 36.8°C). Neurological exam revealed disorientation, with no focal deficits or meningism. Both Chvostek's and Trousseau's signs were positive. There were no dysmorphic features, mucocutaneous candidiasis, or vitiligo. Respiratory, cardiovascular, and abdominal examinations were unremarkable. Ophthalmological evaluation with fundoscopy revealed incipient opacity in left lens and excluded papilledema. Laboratory testing revealed ionized calcium of 0.26 mmol/L (normal range: 1.13-1.32 mmol/L), serum calcium of 4.6 mg/dL

(normal range: 8.6-10.3 mg/dL), albumin of 4.5 g/dL (normal range: 3.5-5.2 g/dL), serum phosphorus of 6.4 mg/dL (normal range: 2.5-4.9 mg/dL). Further laboratory testing revealed decreased parathyroid hormone (PTH) level (4.6 pg/mL, normal range: 15-85 pg/mL) and normal serum magnesium, serum alkaline phosphatase and serum 25-OH-vitamin D. Kidney function and serum protein levels were normal. Electrocardiographic examination revealed flat T waves and prolonged QT intervals. Echocardiogram was normal and excluded ventricle dysfunction.

A cerebral computed tomography was performed and revealed extensive bilateral and symmetrical calcification in the basal ganglia, thalamus and subcortical cerebral white matter (Figure 1).

Additional laboratory work-up showed negative antinuclear antibodies (ANA) and antineutrophil cytoplasmic antibodies (ANCA's), negative HIV test, as well as normal cortisol and ACTH levels; thyroid antibodies (anti-peroxidase and anti-tiroglobulin) and adrenal (anti-21 hydroxylase) antibodies were performed and were both negative. Thyroid function was also unremarkable. No pathology was observed in ultrasonography of thyroid and parathyroid glands. To exclude hypercalciuria a 24-h urine collection was performed and revealed normal urinary calcium (186 mg/24 h with normal range 100-300 mg/24 h), urinary phosphorus and creatinine levels. A diagnosis of primary hypoparathyroidism was done. He was initially admitted to an intermediate care unit under continuous electrocardiographic monitoring. Therapy with intravenous calcium gluconate and vitamin D (cholecalciferol) supplementation was immediately initiated. An improvement of his overall condition prompted a switch from intravenous to oral therapy after the first week of treatment. Ionized calcium gradually increased, with concomitant decrease in serum phosphorus (Figure 2). During hospitalization, significant clinical improvement was observed, with dramatical regression of neuromuscular symptoms on the first days of treatment. Nonetheless, although improved, neuropsychiatric symptoms were slower to perish, with memory impairment and decreased attention span still present at discharge.

A cause for hypoparathyroidism was not encountered, confirming the suspected diagnosis of idiopathic primary hypoparathyroidism, with a presumable autoimmune basis. As complications, extensive basal ganglia calcifications and incipient left catarac were identified. He had also a prolonged QT interval, but other cardiac complications were excluded.

He was discharged with long-term oral carbonate calcium 3 g per day and calcitriol 1mcg per day.

The patient remained asymptomatic with no clinical symptoms of numbness, paresthesias more than 2 years after the initial diagnose. Neurologic and psychiatric symptoms were not observed on follow-up appointments. Ionized calcium levels persisted on the lower limit of the reference range as targeted, and no evidence of hypercalciuria in 24 h-urine collection or

nephrolithiasis and/or nephrocalcinosis in renal echography were identified.

Discussion and Conclusions

Primary hypoparathyroidism is characterized by an abnormally low level of secretion of PTH, a vital importance hormone in calcium balance and homeostasis. The severity and rate of development of hypocalcemia determine its clinical mani-

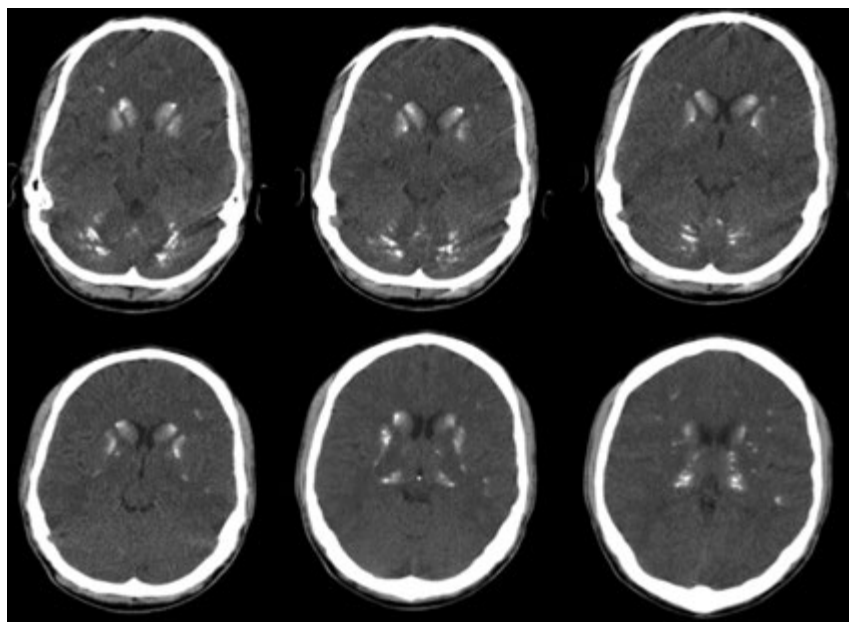


Figure 1. Cerebral CT scan revealing extensive bilateral and symmetrical calcification in the basal ganglia, thalamus and subcortical cerebral white matter.

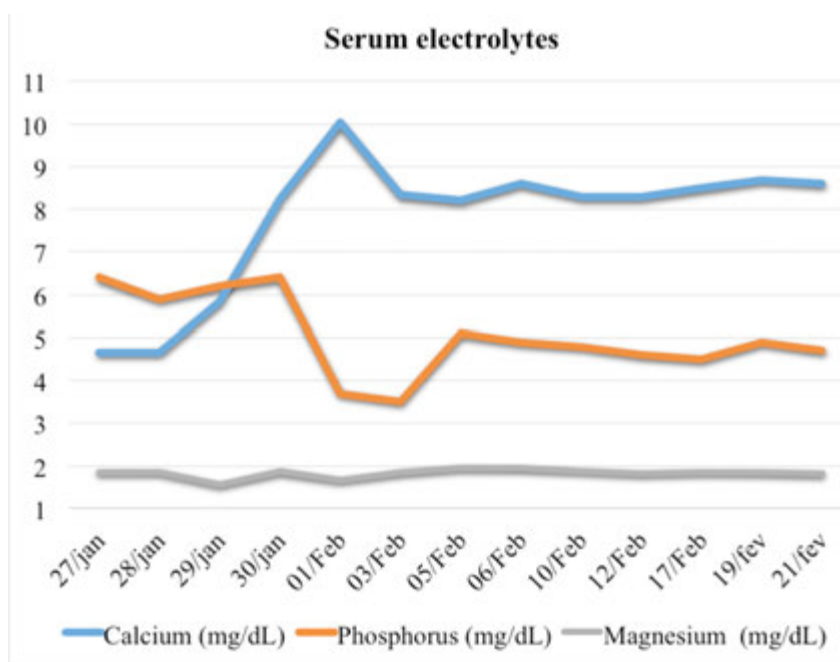


Figure 2. Serum electrolytes levels variation during hospitalization.

festations. Acute hypocalcemia classically results in severe symptoms including laryngospasm, stridor, airway obstruction, neuromuscular irritability, cognitive impairment, prolonged QT interval, cardiac arrhythmias, and in rare cases, depressed systolic function and heart failure. Neuromuscular manifestations include circumoral numbness, paresthesia, hyperreflexia, muscle cramping, tetany, and even seizures. Hyperreflexia is manifested by carpal spasms (Trousseau sign) and facial spasms (Chvostek sign). Other clinical manifestations include neuropsychiatric symptoms such as fatigue, hyperirritability, anxiety and depression.⁶ Chronic hypocalcemia may present with symptoms secondary to deposition of ectopic calcium-phosphorus complex, such as extrapyramidal symptoms (parkinsonism), dementia and cerebellar dysfunction, usually seen in intracranial calcifications. However, patients with remarkably low levels of ionized calcium may be clinically asymptomatic or present with trivial and initially neglected symptoms. Other rarer manifestations of chronic hypocalcemia include dental abnormalities and ectodermal manifestations, more frequently observed in congenital disorders. Furthermore, patients with hypoparathyroidism typically have higher bone density due to low bone turnover, although the risk of fractures is not yet certain. In this report, neurologic symptoms were so unspecific that were initially neglected, requiring several years to be perceptible.

A diagnosis of primary hypoparathyroidism is made based upon identification of characteristic symptoms, a detailed patient history, a thorough clinical evaluation and a variety of specialized tests.¹⁻⁴ Physical examination includes evaluation for anterior neck for signs of previous surgery, signs of neuromuscular irritability (Chvostek's, Trousseau's sign), and mucocutaneous candidiasis or vitiligo that may suggest autoimmune polyglandular syndrome type 1. In addition, growth retardation, congenital anomalies, hearing loss, or mental retardation suggest the possibility of genetic syndromic as causes for the disease.¹

Blood tests reveal low serum levels of calcium and elevated serum phosphorus, with low levels of parathyroid hormone. Twenty-four-hour urine calcium is most often increased, but may be normal or low before calcium supplementation is started, depending on calcium intake and bone turnover. It is important to exclude conditions like hypomagnesaemia, vitamin-D resistance or deficiency, and renal failure as the cause of the biochemical abnormalities.⁴ In our patient, calcium levels were four

times lower than the low-normal range of ionized calcium, associated with low levels of parathyroid hormone and high levels of phosphorus, consistent with the diagnosis of primary hypoparathyroidism. Other potential hypoparathyroidism causes were extensively studied and excluded.

A cerebral computed tomography (CT) scan is required to exclude cerebral complications of hypoparathyroidism. Basal ganglia calcification (BGC), also known in Fahr's syndrome, is a rare presentation in hypoparathyroidism and results due to chronic deposition of calcium-phosphorus complex in cerebral tissue. Its pathogenesis is unknown, and the factors that predispose individuals to basal ganglia calcification have not been identified.⁷ A wide range of other pathologies can cause BGC, thus it is particularly important to identify the underlying condition when upon such a discovery in cerebral CT scan. Apart from hypoparathyroidism and pseudohypoparathyroidism, other metabolic, infectious and genetic diseases, as well as toxic conditions should also be considered as differential diagnosis in basal ganglia calcifications.⁸ The treatment of hypoparathyroidism is directed toward the severity of symptoms and the level of serum calcium, mostly based on calcium supplementation and the use of vitamin D analogs. Thiazide-type diuretics and sodium restriction may be added to reduce urine calcium if hypercalcuria is present.^{4,5,9}

Acute and long-term management of hypoparathyroidism should target goal serum calcium within the low-normal range, with serum phosphorus within the high-normal range, and avoid significant hypo- or hypercalcemia. The aim is to reduce symptoms and reduce the risk of potential life-threatening complications, such as cardiac arrhythmias and seizures. Long-term management objectives also concerns the risk of excessive high levels of serum calcium, including additional ectopic soft tissue deposition, such as nephrolithiasis or nephrocalcinosis, and kidney dysfunction, complication commonly seen in patients treated for hypoparathyroidism. Thereby, it is of utmost importance routine vitamin D, phosphorous, and calcium monitoring, as well as renal calcium excretion evaluation.⁹

In the reported case, this intricate balance was obtained with oral carbonate calcium 3 g daily and calcitriol 1 mcg daily.

Although formerly said that hypoparathyroidism was the only classic endocrine disease where the hormonal insufficiency was not treated by substitution of the missing hormone,⁹ this is currently not entirely true. Despite the mainstream of

treatment is the same, an alternative therapy for patients whose calcium levels are not controlled by standard therapy was recently approved by Food and Drug Administration with a daily subcutaneous injection of recombinant human PTH (PTH 1-84).¹⁰ Unfortunately, due to financial restrictions, the drug was not available to administer in our patient. In conclusion, when dealing with a patient with neurological symptoms, including mild or nonspecific symptoms, the possibility of basal ganglia calcification secondary to hypoparathyroidism, although rare, should be taken into consideration. Benign clinical outcome with prompt treatment is possible even in patients with extreme calcium depletion and life-threatening complications.

References

1. Abate EG, Clarke BL. Review of hypoparathyroidism. *Front Endocrinol* 2016;7:172.
2. Betterle C, Garelli S, Presotto F. Diagnosis and classification of autoimmune parathyroid disease. *Autoimmun Rev* 2014;13:417-22.
3. Clarke BL, Brown EM, Collins MT, et al. Epidemiology and diagnosis of hypoparathyroidism. *J Clin Endocrinol Metab* 2016;101:2284-99.
4. Mitchell DM, Regan S, Cooley MR, et al. Long-term follow-up of patients with hypoparathyroidism. *J Clin Endocrinol Metab* 2012;97:4507-14.
5. Brandi ML, Bilezikian JP, Shoback D, et al. Management of hypoparathyroidism: summary statement and guidelines. *J Clin Endocrinol Metab* 2016;101:2273-83.
6. Bilezikian JP, Khan A, Potts JT Jr, et al. Hypoparathyroidism in the adult: epidemiology, diagnosis, pathophysiology, target-organ involvement, treatment, and challenges for future research. *J Bone Miner Res* 2011;26:2317-37.
7. Shoback D. Hypoparathyroidism. *N Engl J Med* 2008;359:391-403.
8. Basak, RC. A case report of basal ganglia calcification - a rare finding of hypoparathyroidism. *Oman Med J* 2009;24:220-2.
9. Bollerslev J, Rejnmark L, Marcocci C, et al. European Society of Endocrinology Clinical Guideline: treatment of chronic hypoparathyroidism in adults. *Eur J Endocrinol* 2015;173:G1-G20.
10. Cusano NE, Rubin MR, Bilezikian JP. PTH(1-84) replacement therapy for the treatment of hypoparathyroidism. *Exp Rev Endocrinol Metab* 2015;10:5-13.