






# A comprehensive analysis of the intramural segment in interarterial anomalous coronary arteries using computed tomography angiography

Claire J. Koppel <sup>1</sup>, Diederick B.H. Verheijen<sup>1</sup>, Philippine Kiès <sup>1</sup>, Anastasia D. Egorova<sup>1</sup>, Hildo J. Lamb <sup>2</sup>, Michiel Voskuil <sup>3</sup>, J. Wouter Jukema<sup>1</sup>, Dave R. Koolbergen<sup>4</sup>, Mark G. Hazekamp<sup>4</sup>, Martin J. Schalij<sup>1</sup>, Monique R.M. Jongbloed <sup>1,5</sup>, and Hubert W. Vliegen<sup>1,\*</sup>

<sup>1</sup>Department of Cardiology, CAHAL, Center for Congenital Heart Disease Amsterdam-Leiden, Leiden University Medical Center, Leiden, The Netherlands; <sup>2</sup>Department of Radiology, Leiden University Medical Center, Leiden, The Netherlands; <sup>3</sup>Department of Cardiology, University Medical Center Utrecht, Utrecht, The Netherlands; <sup>4</sup>Department of Cardiothoracic Surgery, CAHAL, Center for Congenital Heart Disease Amsterdam-Leiden, Leiden University Medical Center, Leiden, The Netherlands; and <sup>5</sup>Department of Anatomy & Embryology, Leiden University Medical Center, Leiden, The Netherlands

Received 7 January 2022; revised 8 April 2022; accepted 25 April 2022; online publish-ahead-of-print 2 May 2022

Handling Editor: Edit Nagy

## Aims

An anomalous coronary artery originating from the opposite sinus of Valsalva (ACAOS) with an interarterial course can be assessed using computed tomography angiography (CTA) for the presence of high-risk characteristics associated with sudden cardiac death. These features include a slit-like ostium, acute angle take-off, proximal luminal narrowing, and an intramural segment. To date, no robust CTA criteria exist to determine the presence of an intramural segment. We aimed to deduct new CTA parameters to distinguish an intramural course of interarterial ACAOS.

## Methods and results

Twenty-five patients with an interarterial ACAOS (64% female, mean age 46 years, 88% right ACAOS) from two academic hospitals were evaluated. Inclusion criteria were the availability of a preoperative CTA scan (0.51 mm slice thickness) and peroperative confirmation of the intramural segment. Using multiplanar reconstruction of the CTA, the distance between the lumen of the aorta and the lumen of the ACAOS [defined as 'interluminal space' (ILS)] was assessed at 2 mm intervals along the intramural segment. Analysis showed a mean ILS of  $0.69 \pm 0.15$  mm at 2 mm from the ostium. At the end of the intramural segment where the ACAOS becomes non-intramural, the mean ILS was significantly larger ( $1.27 \pm 0.29$  mm,  $P < 0.001$ ). Interobserver agreement evaluation showed good reproducibility (intraclass correlation coefficient 0.77,  $P < 0.001$ ). Receiver operator characteristic analysis demonstrated that at a cut-off ILS of  $<0.95$  mm, an intramural segment can be diagnosed with 100% sensitivity and 84% specificity.

## Conclusion

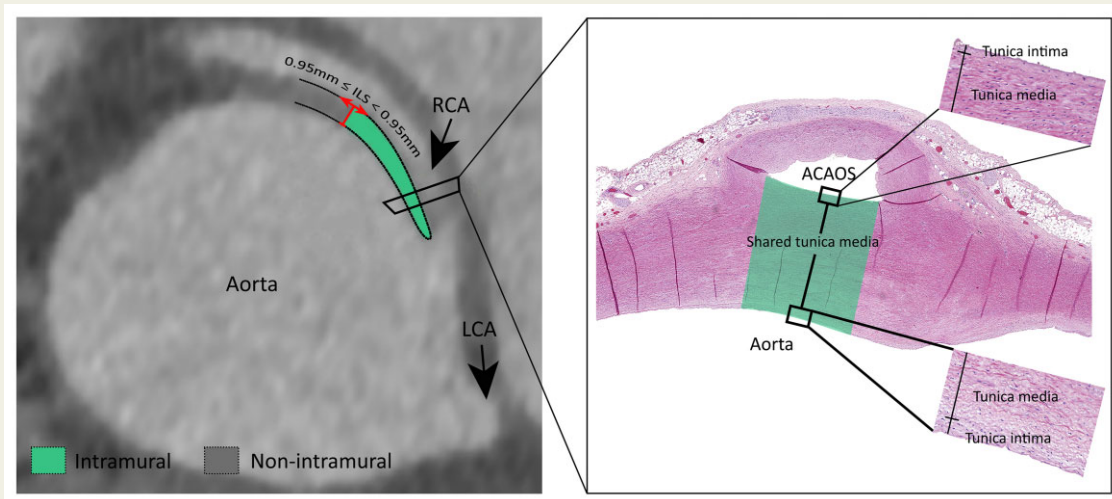
The ILS is introduced as a novel and robust CTA parameter to identify an intramural course of interarterial ACAOS. An ILS of  $<0.95$  mm is indicative of an intramural segment.

\* Corresponding author. Email: [h.w.vliegen@lumc.nl](mailto:h.w.vliegen@lumc.nl)

© The Author(s) 2022. Published by Oxford University Press on behalf of the European Society of Cardiology.

This is an Open Access article distributed under the terms of the Creative Commons Attribution-NonCommercial License (<https://creativecommons.org/licenses/by-nc/4.0/>), which permits non-commercial re-use, distribution, and reproduction in any medium, provided the original work is properly cited. For commercial re-use, please contact [journals.permissions@oup.com](mailto:journals.permissions@oup.com)

## Graphical Abstract



The ILS is introduced as a novel CTA parameter to identify an intramural course of interarterial ACAOS. An ILS of  $<0.95$  mm is indicative of an intramural segment.

## Keywords

Anomalous coronary arteries originating from the opposite sinus of Valsalva (ACAOS) • Intramural course • CT angiography (CTA)

## Introduction

An anomalous coronary artery originating from the opposite sinus of Valsalva (ACAOS) is a rare congenital anomaly. It has been estimated that an ACAOS is present in  $<1\%$  of the population, with a predisposition in patients with concomitant congenital heart disease, though the true prevalence remains a point of debate.<sup>1,2</sup> An ACAOS commonly follows a retro-aortic, pre-pulmonary, septal, or interarterial course. The first three variants are generally considered benign, whereas an interarterial course is associated with an increased risk of sudden cardiac death in selected patients due to ischaemia during or shortly after exercise. In studies looking into sudden cardiac death causes among the US athletes and military recruits, 14–33% of deaths were attributed to coronary anomalies.<sup>3–5</sup> Although to date the true mechanism causing ischaemia is still not fully elucidated,<sup>6</sup> several high-risk anatomical characteristics of the proximal ACAOS have been identified, such as a slit-like ostium, an acute angle take-off ( $<45^\circ$ ), a high take-off (i.e. above the sinotubular junction), proximal narrowing, and an intramural course.<sup>2,7</sup> These features increase the risk of ischaemia during exercise by compression of the ACAOS between the great vessels, further narrowing of an already small or hypoplastic proximal anomalous coronary arterial segment and/or a dynamic flaplike closure of the ACAOS lumen by the intramural segment. A longer intramural course increases the risk of sudden cardiac death.<sup>7</sup> Given the poor discriminative value of thoracic complaints in patients with ACAOS, only 35% of patients display typical anginal complaints, and the increasingly frequent identification of this anomaly as an incidental finding on a computed tomography angiography (CTA), robust radiological criteria for identifying an intramural segment are much needed.<sup>8</sup>

The histological definition of an intramural coronary course is the presence of a shared tunica media (without interposing adventitia) between the aorta and the coronary artery.<sup>6</sup> In case of an intramural segment, unroofing is the most used surgical technique. With this technique, the intramural part of the coronary artery is resected.<sup>1,2,6,9</sup> Since the identification of an intramural segment has important consequences for the evaluation of the surgical indication and technique, reliable diagnostic criteria are required for robust identification and characterization of the intramural segment of the ACAOS.<sup>8,9</sup> To date, assessment of the presence of an intramural segment is done by using, separately or combined, the degree of proximal narrowing, the coronary artery lumen shape, and the presence of a slit-like orifice, acute angle take-off, or peri-coronary fat.<sup>6,10–16</sup> Methods to adequately diagnose an intramural course on CTA may omit the necessity for invasive haemodynamic evaluation and improve the identification of patients who would benefit from surgical intervention. The aim of this study was to define new CTA criteria that can assess the presence and length of an intramural coronary segment using one parameter.

## Methods

### Patient inclusion

This retrospective analysis was performed in two academic referral centres—the Leiden University Medical Center and the University Medical Center Utrecht.

All adult ( $\geq 18$  years) patients with an interarterial left or right ACAOS who received care in either of the hospitals between January 2010 and July 2019 were retrospectively evaluated for inclusion ( $n=154$ ). Patients who underwent surgery for ACAOS and had a preoperative

electrocardiogram-triggered CT scan (0.5–1 mm slice thickness) were evaluated for final inclusion ( $n = 52$ ). Of this cohort, all patients with an intramural course in whom the length of the intramural segment was measured preoperatively by the surgeon were included for final analysis (the flowchart describing patient inclusion can be found in [Supplementary material online, Figure S1](#)). The length of the intramural segment was measured directly during surgery using a probe. The probe was positioned in the anomalous coronary ostium and the tip advanced through the lumen up to the point where the ACAOS became extramural (i.e. visually separated from the aortic vascular wall). Subsequently, the distance from the coronary ostium to the tip of the probe was measured.

Oral or written consent from eligible patients to use their data for research purposes was obtained where feasible, in accordance with the regulations of the local medical ethical committees. The informed consent was registered in the patients' medical charts. Demographic, clinical, and imaging patient data were collected from electronic medical file systems (EPD-Vision<sup>®</sup>, Leiden University Medical Center, Leiden, The Netherlands, and HiX, Chipsoft, Amsterdam, The Netherlands). All patient information was coded and stored in the Castor electronic data capture (EDC) platform (Castor EDC, Castor Electronic Data Capture, Amsterdam, The Netherlands).

## Computed tomography angiography image analysis

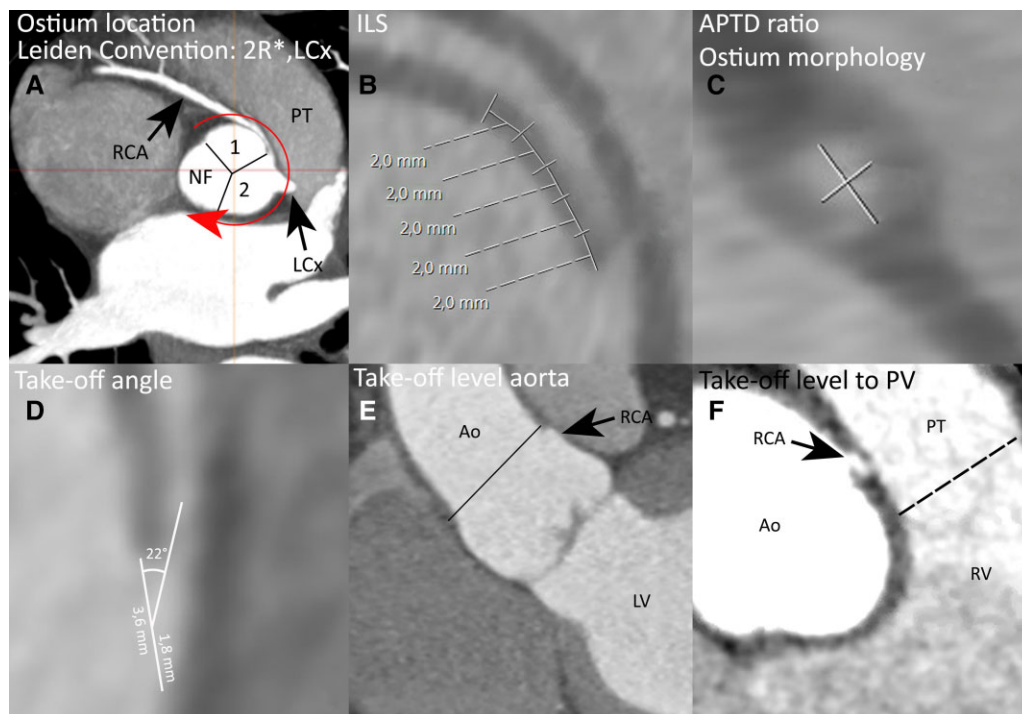
Computed tomography angiography scan images were analysed independently by two experienced researchers (C.J.K. and D.B.H.V.).

All ACAOS were classified according to the Leiden Convention coronary coding system<sup>17</sup> ([Figure 1A](#)). Coronary artery dominance pattern was determined based on the vessel giving rise to the ramus descendens posterior.

Images were rotated to a view perpendicular to the horizontal plane of the aortic valve annulus according to previously described methods.<sup>18</sup> In this view, the distance between the aortic lumen and coronary artery lumen [further referred to as 'interluminal space' (ILS)] was measured at consecutive 2 mm intervals along the length of the intramural segment that was measured preoperatively by the surgeon. The surgical measurements were used as the reference to define the length of the intramural segment ([Figure 1B](#)).

At the same 2 mm intervals where the ILS was measured, the dimensions (sphericity of the lumen) of the ACAOS were evaluated in the axis perpendicular to the vessel course, by calculating the ratio of the anteroposterior diameter and the transverse diameter (APTD ratio) as previously described by Agrawal *et al.*,<sup>19</sup> who established ostium morphology classifications based on the APTD ratio: <50% is slit-like, 50–90% is oval, and >90% is round ([Figure 1C](#)). Although the classification is designed for ostium morphology, the method can be extrapolated to the entire length of the vessel, also beyond the ostium, and was thus used to classify the vessel morphology in this study.

Additionally, the following features of the ACAOS were evaluated: acute angle take-off (<45° between the aorta and ACAOS), location of take-off within the sinus, orifice shape, level of take-off from the aortic root, and take-off level relative to the pulmonary valve (below, at, or above) ([Figure 1D–F](#)).<sup>10,19</sup>



**Figure 1** Applied methods for assessment of the computed tomography angiography images. Ao, aorta; APTD, anteroposterior–transverse diameter ratio; ILS, interluminal space; LCx, left coronary artery and circumflex artery; LV, left ventricle; NF, non-facing sinus; PT, pulmonary trunk; PV, pulmonary valve; RCA, right coronary artery; RV, right ventricle. The circular arrow indicates the clockwise rotation that must be followed in order to annotate the coronary artery anatomy according to the Leiden Convention.<sup>17</sup>

## Statistical analysis

For statistical analysis, SPSS statistics (version 25, IBM Corp., Armonk, NY, USA) was used. Normally distributed variables were reported as mean with standard deviation (SD) and non-normally distributed variables as median with first–third interquartile ranges (1st IQR–3rd IQR). To assess the distribution of the variables, the Shapiro–Wilk test was used. A normal distribution of the data was assumed with a  $P$ -value of  $\geq 0.05$ . To analyse the difference between the ILS at 2 mm from the ostium and at the end of the intramural segment (i.e. the site where the intramural segment ends to become non-intramural), the paired  $t$ -test was used. The Wilcoxon signed-rank test was performed for analysis of the difference between the APTD ratio at 2 mm from the ostium and at the end of the intramural segment. A  $P$ -value of  $< 0.05$  was considered significant.

The interobserver agreement for the ILS was statistically evaluated by calculating the intraclass correlation coefficient (ICC) in a two-way mixed model assessing the consistency of individual independently performed measurements between C.J.K. and D.B.H.V. The interobserver agreement was considered good if the ICC was 0.75 or higher.<sup>20</sup> To visually analyse the interobserver agreement, a Bland–Altman plot was constructed by calculating the mean difference between measurements and construction of the limits of agreement to include 95% of measurements ( $\pm 1.96$  SD of the difference).<sup>21</sup>

A receiver operator characteristic (ROC) analysis was performed to evaluate an ILS cut-off value for intramurality of the ACAOS. For this analysis, the ILS at 2 mm from the ostium was set as the variable for intramural, and the ILS at the distal end of the intramural segment was set as the variable for non-intramural.

## Results

### Patient and general anomalous coronary arteries originating from the opposite sinus of Valsalva characteristics

Twenty-five patients (64% female) met the inclusion criteria and were included in the analyses. The mean age at diagnosis of the ACAOS was  $46.4 \pm 11.6$  years. Eleven CTAs had a slice thickness of 0.5 mm, and one CTA had a slice thickness of 1 mm. Twenty-two patients presented with an interarterial anomalous right coronary artery from sinus 2 (Leiden Convention coding: 2R\*, LCx). The other three patients presented with an anomalous left coronary artery from sinus 1 (1R, LCx\*).<sup>17,22</sup> In 20 patients (80%), the ACAOS was the dominant coronary artery. In 22 patients (88%), the ostium of the anomalous artery had a slit-like morphology (2R\*, LCx  $n = 20$ , 1R, LCx\*  $n = 2$ ). All studied ACAOS had an acute angle take-off of  $< 45^\circ$ . The take-off level from the aorta was high, i.e. above the sinotubular junction, in six patients (24%). In relation to the pulmonary valve, take-off was above the valvular level in 20 patients (80%), at the level of the pulmonary valve in three patients (12%), and in two patients (8%), the ACAOS coursed at a level below the pulmonary valve/at the level of the right ventricular outflow tract.

Seventeen patients (68%) had undergone solitary unroofing surgery, three patients (12%) had unroofing combined with ostioplasty, one patient (4%) had unroofing and additional coronary bypass grafting of the ACAOS, because only unroofing was deemed to give insufficient surgical result, and four patients (16%) underwent ostioplasty only. A mean intramural length of  $11.28 \pm 3.16$  mm was determined during these surgeries. Findings are summarized in [Table 1](#). The

**Table 1** Baseline characteristics of patients with an intramural course

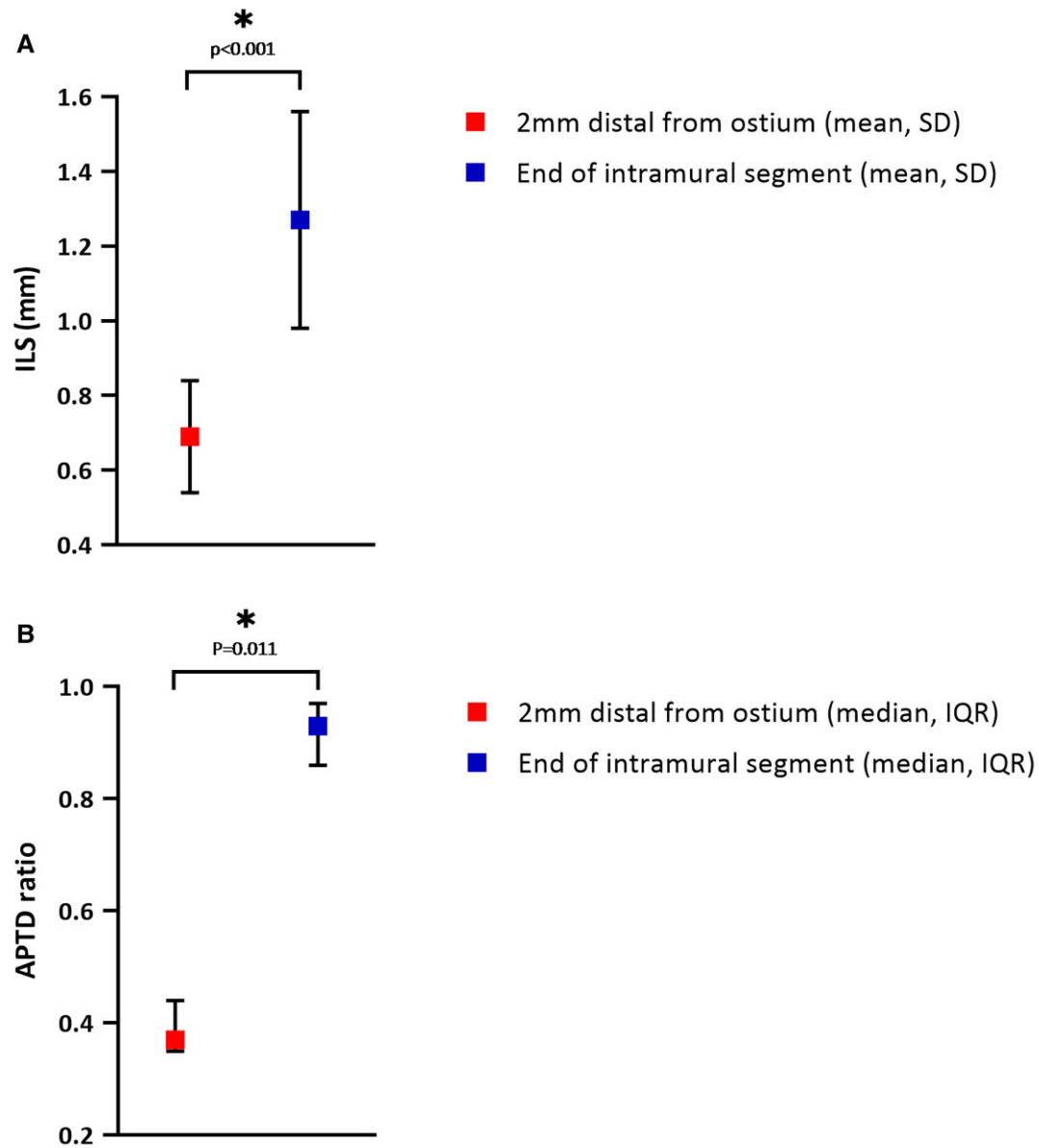
Patient characteristics	All patients (n = 25)
Female, n (%)	16 (64)
Age at diagnosis, years, mean $\pm$ SD	46.4 $\pm$ 11.6
Coronary anatomy	
2R*, LCx, n (%)	22 (88)
1R, LCx*, n (%)	3 (12)
Type of surgery	25 (100)
Unroofing, n (%)	17 (68)
Unroofing and ostioplasty, n (%)	3 (12)
Unroofing and CABG, n (%)	1 (4)
Ostioplasty, n (%)	4 (16)
CT angiography parameters	
ACAOS dominant, n (%)	20 (80)
Sinus position ostium in horizontal plane	
Middle of sinus 1, n (%)	2 (8)
Sinus 1 near commissure with sinus 2, n (%)	1 (4)
Sinus 2 near commissure with sinus 1, n (%)	22 (88)
Orifice shape	
Slit-like, n (%)	22 (88)
Oval, n (%)	3 (12)
Acute angle take-off	
Yes, n (%)	25 (100)
Take-off in relation to pulmonary valve	
Above, n (%)	20 (80)
At the same level, n (%)	3 (12)
Take-off level from aortic root	
Sinus, n (%)	7 (25)
ST-junction, n (%)	12 (48)
Above ST-junction, n (%)	6 (24)
Proximal narrowing	
Yes, n (%)	25 (100)
Surgical findings	
Length of intramural course (mean $\pm$ SD)	11.28 $\pm$ 3.16

ACAOS, anomalous coronary artery originating from the opposite sinus of Valsalva; CABG, coronary artery bypass grafting; SD, standard deviation; ST, sinotubular.

results of the measurements of the intramural length done during surgery per patient can be found in the [Supplementary material online, Table S1](#).

### Computed tomography angiography evaluation of the intramural segment

Retrospective assessment of the preoperative CTAs showed a mean ILS along the intramural segment of  $0.87 \pm 0.2$  mm. Proximally, at 2 mm from the ostium, the mean ILS was  $0.69 \pm 0.15$  mm. At the distal end of the intramural segment (i.e. the site where the intramural segment ends to become non-intramural), the mean ILS measured  $1.27 \pm 0.29$  mm. The ILS was significantly smaller at 2 mm from the ostium than at the end of the intramural segment ( $P < 0.001$ ) ([Figure 2A](#)).



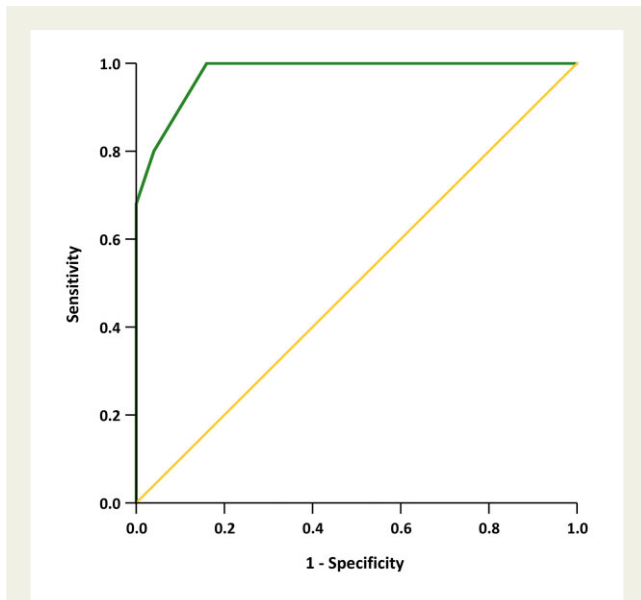
**Figure 2** (A) At 2 mm from the ostium, the mean interluminal space was significantly smaller than at the distal end of the intramural segment. (B) At 2 mm from the ostium, the median anteroposterior–transverse diameter ratio was significantly smaller than at the distal end of the intramural segment. These results indicate that the interluminal space and anteroposterior–transverse diameter ratio can be used as variables to differentiate between intramural and extramural segments of a coronary artery.

Along the entire intramural segment, the APTD ratio had a mean of  $0.64 \pm 0.10$ , indicating an average oval vessel shape along the intramural course of the ACAOS. The median APTD ratio of the ACAOS at 2 mm from the ostium was 0.37 (IQR 0.35–0.44). At the end of the intramural segment, the median APTD ratio was 0.93 (IQR 0.86–0.97). The median vessel's APTD ratio was significantly smaller at 2 mm from the ostium vs. at the end of the intramural course ( $P < 0.011$ ) (Figure 2B).

These results indicate that the ILS and APTD ratio can be used as variables to differentiate between intramural and extramural segments of a coronary artery.

### Interobserver variability of the interluminal space

The ICC was 0.77 ( $P < 0.001$ ) for single measurements performed by the two observers ( $n = 144$  in 25 patients). This indicates good reproducibility of the method to measure the ILS. The Bland–Altman plot (see [Supplementary material online, Figure S2](#)) visually confirms that the limits of agreement are acceptable, especially for the smaller ILS measurements. At larger ILS measurements  $>1$  mm, the difference between observers increases.



**Figure 3** Receiver operator characteristic curve showing an area under the curve of 0.978 ( $P < 0.001$ ), indicating that the interluminal space is an excellent predictor of intramurality of the anomalous coronary artery origination from the opposite sinus. At 0.95 mm, the sensitivity was 100% and specificity 84% for the diagnosis of an intramural segment.

## Receiver operator characteristic analysis

Receiver operator characteristic analysis showed an area under the curve of 0.978 ( $P < 0.001$ ), indicating that the ILS is an excellent predictor for the detection of an intramural course (Figure 3). At an ILS value of 0.95 mm, the Youden index was optimal at 0.84 with a sensitivity of 100% and specificity of 84% for the diagnosis of an intramural segment (coordinates of the curve can be found in [Supplementary material online, Table S2](#)).

## Discussion

Key findings in this study are (i) an ILS of  $< 0.95$  mm on CTA is indicative of an intramural segment with a sensitivity of 100% and specificity of 84%, (ii) in patients with an intramural segment, the ILS was significantly smaller at 2 mm from the ostium than at the end of the intramural segment, and (iii) the method to measure the ILS is reproducible as illustrated by an ICC of 0.77 for interobserver agreement.

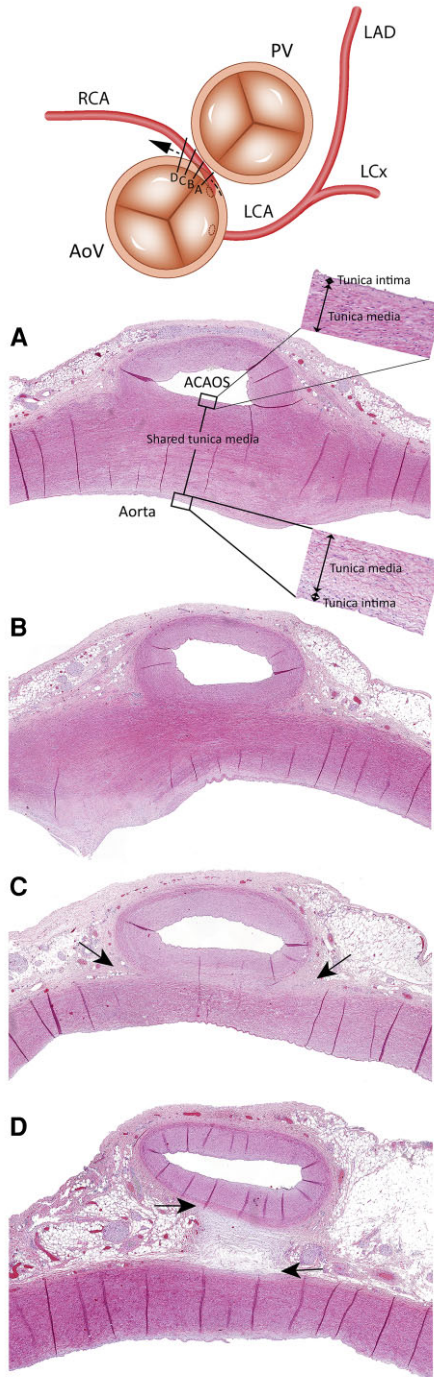
Previous studies evaluating methods to determine the presence of an intramural segment of an interarterial ACAOS on CT scan used morphological vessel characteristics, such as the degree of proximal narrowing, presence of a slit-like ostium, acute angle take-off, or peri-coronary fat to extrapolate the presence of an intramural course.<sup>6,10–16</sup> We introduce a new parameter that directly measures the interarterial area, which was designated as the interluminal space, abbreviated as ILS. This is the distance between the aorta and coronary artery lumina (as shown in [Figure 1B](#)). From a histological point of view, the area represented by the ILS is expected to contain either the shared media of the aortic and coronary vessel wall (in case of an intramural course) or (in case of a non-intramural course) also an additional layer of adventitia. To our knowledge, we are the first

to quantify the distance between the aortic and coronary arterial lumina on CTA and report a significant difference between the proximal start and the distal end of the intramural segment of the interarterial ACAOS. Other indications of an intramural course, such as an elliptical vessel shape, slit-like ostium morphology, and acute angle take-off,<sup>6,10–13</sup> were found to be associated with an intramural course in this study as well ([Table 1](#)).

The amount of proximal narrowing as related to an intramural course has been previously described by Miller *et al.*<sup>12</sup> On CTA, it was shown that a ratio of  $> 1.3$  in vessel height/width (APTD ratio equivalent of 0.77) of the proximal part of the anomalous vessel is indicative of an intramural course, when compared with surgical findings in the same patients. Our findings confirm this with an even smaller mean APTD ratio of 0.64 along the entire intramural segment. We prefer the use of the APTD ratio above the height/width ratio because the Texas Children's Hospital adhered clear ostium morphology classifications to these different ratios<sup>19</sup> and the method extrapolates, as previously mentioned, to the entire vessel's length beyond the ostium. In their study, Miller *et al.*<sup>12</sup> do not clarify at what point from the ostium the proximal narrowing was assessed and whether it was measured at one location or multiple locations and at the same distance from the ostium for each patient. Also, a method to assess the length of the intramural segment was not described. In the current study, we consistently measured all coronary arteries at the same distance from the ostium along the intramural segment and could define criteria, not only to assess the presence of an intramural course, but also to determine the probable end of the intramural course, thus providing information on the length of the actual intramural segment.

Another method to assess the presence and length of an intramural segment is the evaluation of the presence of peri-coronary fat.<sup>15</sup> In their study, Krishnamurthy *et al.* found a sensitivity of 96% and a specificity of 94.7% when averaging the results of their analysts. The ICC for determination of the intramural length using the peri-coronary fat ranged from 0.67 to 0.84 (average 0.74). These results indicate that peri-coronary fat is a good predictor of interarterial ACAOS intramurality. Though the ILS has a lower specificity, the sensitivity and ICC are higher. These results suggest that the risk of missing a diagnosis is lower and using the ILS might be easier for less experienced physicians.

An intramural course is histologically defined by a shared tunica media (without interposing adventitia) of the aorta and the coronary artery ([Figure 4](#)). We have used the ILS to determine the thickness of the space between the aortic and ACAOS lumina, in order to associate this with the presence of an intramural coronary artery segment. Of note, Angelini and Flamm<sup>23</sup> and Angelini<sup>24</sup> state that measuring the distance between the aorta and ACAOS cannot be adequately done on CTA due to limited spatial resolution. However, CTA quality has much improved over the last 14 years and is expected to improve even further in the future, expanding the possibilities for coronary artery assessment.<sup>25</sup> Marano *et al.*<sup>13</sup> did not measure the ILS because they argued that the spatial resolution was insufficient to visualize the shared tunica media. We agree that differentiation between layers is not possible with contemporary CTA quality. However, using the ILS, it is not necessary to visualize the different layers, as ROC analysis showed that the ILS is an excellent predictor of an intramural course based on the area under the curve. If the different vessel layers need to be evaluated, intravascular ultrasound has a better spatial resolution than CTA.<sup>24</sup>



**Figure 4** Haematoxylin and eosin staining of an intramural anomalous coronary artery. (A and B) The anomalous coronary artery originating from the opposite sinus of Valsalva and aorta share the tunica media. (C) The beginning of an interposing adventitia layer between the anomalous coronary artery originating from the opposite sinus of Valsalva and aorta (arrows). In (D), the anomalous coronary artery originating from the opposite sinus of Valsalva is entirely extramural (the arrows indicate the adventitial layers of both vessels). Consent was obtained for anonymous use of the tissues for research purposes. Courtesy of the Department of Pathology LUMC.

However, also on intravascular ultrasound, in our experience, the layers between the aortic and coronary artery are not easily recognizable in each patient. It is also not possible to evaluate the full area between the coronary artery lumen and aortic lumen along the intramural segment to assess the interposing layers and distance with intravascular ultrasound.<sup>26</sup> In the majority of the included patients in our study, a CTA slice thickness of 0.5 mm was used, with a maximum of 1 mm (one patient). It was possible to assess the ILS on these scans as demonstrated in the current study. On CTA imaging with larger slice thickness, we agree with Angelini<sup>24</sup> and Marano *et al.*<sup>13</sup> that the spatial resolution is not adequate for this measurement. CTA imaging can be expected to improve over the years regarding spatial resolution, rendering it possible that in the future visualization of the different vessel layers will be feasible. For now, using the ILS, we have shown that this is a reliable tool to distinguish between an intramural and non-intramural course of an interarterial ACAOS on CTA without the necessity of distinguishing vessel layers. Prognostically, it is more important not to miss the diagnosis of an intramural segment than it is to further examine a patient with a false positive diagnosis based on the measured ILS. Based on the Youden index and a sensitivity of 100% and specificity of 84%, the cut-off value of 0.95 mm was determined for the diagnosis of an intramural segment. This cut-off value can be further appreciated when comparing it to the native aortic wall thickness. The native ascending aortic wall has a median thickness of 1.46 mm for females and 1.56 mm for males in the general population based on magnetic resonance imaging data.<sup>27</sup> Because in the case of an intramural course, the aortic wall shares its tunica media with the ACAOS and lacks an adventitial layer, it can be expected that the ILS is thinner than the native aortic wall in patients with an intramural course.

An advantage of our method is the ease of application. In clinical practice, it can be done with basic radiology multiplanar reconstruction experience. A methodical approach using 2 mm intervals starting at the ostium as done in this study can be recommended, but is not imperative. The interobserver agreement evaluation showed a good ICC of 0.77, indicating that the method is reliably reproducible between observers. With regard to future directions, the possibilities of using machine learning and artificial intelligence to automate the measurements might be worthwhile to explore.

### Study limitations

The inclusion criteria of this study forestalled the creation of a control group because the surgeon's assessment of the presence of an intramural segment was used as a gold standard for measurement of the ILS on CTA. Unoperated patients do not necessarily lack an intramural course and were thus not considered to be an appropriate control group.

In order to evaluate the potential of the ILS as a new parameter for the assessment of an intramural course and determine a cut-off value for its length, the preoperative CT scan was correlated to the measurements performed during surgery. Due to this study design, the ILS measurements could not be performed in a blinded fashion for the surgical results and will require future prospective validation.

The accuracy of the ILS may be limited by the spatial resolution of the CTA. In the current study, a spatial resolution of 0.5–1 mm slice thickness of the CTAs was used for inclusion. Coronary artery motion during the CTA produces temporal and spatial blurring that can effectively

result in a lower spatial resolution than intended.<sup>18</sup> Thus, it would be advisable to use a slice thickness of 0.5 mm on CTA in all cases for the evaluation of the ILS to obtain the most reliable results. In the current study, CTAs were performed in the different referring hospitals following local protocols; therefore, not all scans included in this study were performed according to the same scanning protocol.

This study presents the ILS as a potentially useful and powerful tool to diagnose an intramural course and to give an indication of the length. However, it would be valuable to validate the ILS further in a prospective study setting in a larger patient group, following the same scanning protocol for each patient and in a blinded setting for the surgical results during CTA evaluation. Preferably also including a sufficiently large control group of patients surgically confirmed without an intramural course. This is currently being undertaken with the prospective MuSCAT study that started patient inclusion in 2021.<sup>28</sup>

Additionally, it would be worthwhile to use a combination of previously demonstrated methods<sup>6,10–16</sup> and the ILS compared with the surgical assessment to evaluate the presence and length of an intramural segment. Moreover, this can be used to determine which method or combination of methods provides the highest sensitivity and specificity to diagnose an intramural course using CTA.

## Conclusions

An intramural course is considered an important risk factor for sudden cardiac death; therefore, correct identification is essential for further SCD risk stratification and consecutive management. Our results show that an ILS < 0.95 mm (sensitivity 100%, specificity 84%) on CTA is indicative of an intramural segment.

## Clinical implications

Because non-invasive imaging has preference over invasive imaging, especially in the early diagnostic stages, it is important to correctly identify an intramural course and its length on CTA. The ILS presented in the current study can support the diagnosis of an intramural course of an interarterial ACAOS and is shown to be reliably applicable.

## Lead author biography



Claire J. Koppel is a PhD candidate and Cardiology resident at the Cardiology Department of the Leiden University Medical Center. Her research focuses on coronary anomalies and epicardial activation and innervation after myocardial infarction.

## Author contributions

C.J.K.: conceptualization, methodology, formal analysis, investigation, writing—original draft. D.B.H.V.: validation, writing—review and editing. P.K. and A.D.E.: writing—review and editing, supervision.

H.J.L., M.V., J.W.J., D.R.K., M.G.H., and M.J.S.: writing—review and editing. M.R.M.J.: conceptualization, writing—review and editing, supervision. H.W.V.: conceptualization, methodology, writing—review and editing, supervision.

## Data availability

The data underlying this article will be shared on reasonable request to the corresponding author.

## Supplementary material

Supplementary material is available at *European Heart Journal Open* online.

## Funding

This research did not receive any specific grant from funding agencies in the public, commercial, or not-for-profit sectors.

**Conflict of interest:** None declared.

## References

- Cheezum MK, Liberthson RR, Shah NR, Villines TC, O'Gara PT, Landzberg MJ, Blankstein R. Anomalous aortic origin of a coronary artery from the inappropriate sinus of valsalva. *J Am Coll Cardiol* 2017;**69**:1592–1608.
- Brothers JA, Frommelt MA, Jaquiss RDB, Myerburg RJ, Fraser CD Jr, Tweddell JS. Expert consensus guidelines: anomalous aortic origin of a coronary artery. *J Thorac Cardiovasc Surg* 2017;**153**:1440–1457.
- Harmon KG, Drezner JA, Maleszewski JJ, Lopez-Anderson M, Owens D, Prutkin JM, Asif IM, Klossner D, Ackerman MJ. Pathogenesis of sudden cardiac death in national collegiate athletic association athletes. *Circ Arrhythm Electrophysiol* 2014;**7**:198–204.
- Eckart RE, Scoville SL, Campbell CL, Shry EA, Stajduhar KC, Potter RN, Pearse LA, Virmani R. Sudden death in young adults: a 25-year review of autopsies in military recruits. *Ann Intern Med* 2004;**141**:829–834.
- Maron BJ, Doerer JJ, Haas TS, Tierney DM, Mueller FO. Sudden deaths in young competitive athletes: analysis of 1866 deaths in the United States, 1980–2006. *Circulation* 2009;**119**:1085–1092.
- Agarwal PP, Dennie C, Pena E, Nguyen E, LaBounty T, Yang B, Patel S. Anomalous coronary arteries that need intervention: review of pre- and postoperative imaging appearances. *Radiographics* 2017;**37**:740–757.
- Jegatheeswaran A, Devlin PJ, McCrindle BW, Williams WG, Jacobs ML, Blackstone EH, DeCampi WM, Caldarone CA, Gaynor JW, Kirklin JK, Lorber RO, Mery CM, St. Louis JD, Molossi S, Brothers JA. Features associated with myocardial ischemia in anomalous aortic origin of a coronary artery: a Congenital Heart Surgeons' Society study. *J Thorac Cardiovasc Surg* 2019;**158**:822–834.e3.
- Meijer FMM, Egorova AD, Jongbloed MRM, Koppel C, Habib G, Hazekamp MG, Vliegen HW, Kies P. The significance of symptoms before and after surgery for anomalous aortic origin of coronary arteries in adolescents and adults. *Interact Cardiovasc Thorac Surg* 2021;**32**:122–129.
- Padalino MA, Jegatheeswaran A, Blitzer D, Ricciardi G, Guariento A. Surgery for anomalous aortic origin of coronary arteries: technical safeguards and pitfalls. *Front Cardiovasc Med* 2021;**8**:626108.
- Cheezum MK, Ghoshhajra B, Bittencourt MS, Hulten EA, Bhatt A, Mousavi N, Shah NR, Valente AM, Rybicki FJ, Steigner M, Hainer J, MacGillivray T, Hoffmann U, Abbara S, Di Carli MF, DeFaria Yeh D, Landzberg M, Liberthson R, Blankstein R. Anomalous origin of the coronary artery arising from the opposite sinus: prevalence and outcomes in patients undergoing coronary CTA. *Eur Heart J Cardiovasc Imaging* 2016;**18**:224–235.
- Lee S, Uppu SC, Lytrivi ID, Sanz J, Weigand J, Geiger MK, Shenoy RU, Farooqi K, Nguyen KH, Parness IA, Srivastava S. Utility of multimodality imaging in the morphologic characterization of anomalous aortic origin of a coronary artery. *World J Pediatr Congenit Heart Surg* 2016;**7**:308–317.
- Miller JA, Anavekar NS, El Yaman MM, Burkhart HM, Miller AJ, Julsrud PR. Computed tomographic angiography identification of intramural segments in anomalous coronary arteries with interarterial course. *Int J Cardiovasc Imaging* 2012;**28**:1525–1532.
- Marano R, Merlino B, Savino G, Natale L, Rovere G, Paciolla F, Muciaccia M, Flammia FC, Larici AR, Palmieri V, Zeppilli P, Manfredi R. Coronary computed tomography angiography in the clinical workflow of athletes with anomalous origin of coronary arteries from the contralateral valsalva sinus. *J Thorac Imaging* 2021;**36**:122–130.



14. Tang CX, Lu MJ, Schoepf JU, Tesche C, Bauer M, Nance J, Griffith P, Lu GM, Zhang LJ. Coronary computed tomography angiography-derived fractional flow reserve in patients with anomalous origin of the right coronary artery from the left coronary sinus. *Korean J Radiol* 2020;**21**:192–202.
15. Krishnamurthy R, Masand PM, Jadhav SP, Molossi S, Zhang W, Agrawal HM, Zhang W, Agrawal HM, Mery CM. Accuracy of computed tomography angiography and structured reporting of high-risk morphology in anomalous aortic origin of coronary artery: comparison with surgery. *Pediatr Radiol* 2021;**51**:1299–1310.
16. Molossi S, Agrawal H, Mery CM, Krishnamurthy R, Masand P, Sexson Tejtetel SK, Noel CV, Qureshi AM, Jadhav SP, McKenzie ED, Fraser CD. Outcomes in anomalous aortic origin of a coronary artery following a prospective standardized approach. *Circ Cardiovasc Interv* 2020;**13**:e008445.
17. Koppel CJ, Vliegen HW, Bökenkamp R, Ten Harkel ADJ, Kiès P, Egorova AD, Jukema JW, Hazekamp MG, Schalij MJ, Gittenberger-de Groot AC, Jongbloed MR. The Leiden Convention coronary coding system: translation from the surgical to the universal view. *Eur Heart J Cardiovasc Imaging* 2021;**23**:412–422.
18. Meijer FMM, Kiès P, Verheijen DBH, Vliegen HW, Jongbloed MRM, Hazekamp MG, Lamb HJ, Egorova AD. Computed tomography derived coronary triangulated orifice area-deduction of a new parameter for follow-up after surgical correction of anomalous aortic origin of coronary arteries and call for validation. *Front Cardiovasc Med* 2021;**8**:668503.
19. Agrawal H, Mery CM, Krishnamurthy R, Molossi S. Anatomic types of anomalous aortic origin of a coronary artery: a pictorial summary. *Congenit Heart Dis* 2017;**12**:603–606.
20. Koo TK, Li MY. A guideline of selecting and reporting intraclass correlation coefficients for reliability research. *J Chiropr Med* 2016;**15**:155–163.
21. Altman DG, Bland JM. Measurement in medicine: the analysis of method comparison studies. *J R Stat Soc Ser D* 1983;**32**:307–317.
22. Gittenberger-de Groot AC, Koenraadt WMC, Bartelings MM, Bökenkamp R, DeRuiter MC, Hazekamp MG, Bogers AJC, Quaegebeur JM, Schalij MJ, Vliegen HW, Poelmann RE, Jongbloed MRM. Coding of coronary arterial origin and branching in congenital heart disease: the modified Leiden Convention. *J Thorac Cardiovasc Surg* 2018;**156**:2260–2269.
23. Angelini P, Flamm SD. Newer concepts for imaging anomalous aortic origin of the coronary arteries in adults. *Catheter Cardiovasc Interv* 2007;**69**:942–954.
24. Angelini P. Imaging approaches for coronary artery anomalies: purpose and techniques. *Curr Cardiol Rep* 2019;**21**:101.
25. Ghekiere O, Salgado R, Buls N, Leiner T, Mancini I, Vanhoenacker P, Dendale P, Nchimi A. Image quality in coronary CT angiography: challenges and technical solutions. *Br J Radiol* 2017;**90**:20160567.
26. Driesen BW, Warmerdam EG, Sieswerda GT, Schoof PH, Meijboom FJ, Haas F, Stella PR, Kraaijeveld AO, Evens FC, Doevendans PA, Krings GJ, van Dijk APJ, Voskui M. Anomalous coronary artery originating from the opposite sinus of Valsalva (ACAOS), fractional flow reserve- and intravascular ultrasound-guided management in adult patients. *Catheter Cardiovasc Interv* 2018;**92**:68–75.
27. Mensel B, Quadrat A, Schneider T, Kühn JP, Dörr M, Völzke H, Lieb W, Hegenscheid K, Lorbeer R. MRI-based determination of reference values of thoracic aortic wall thickness in a general population. *Eur Radiol* 2014;**24**:2038–2044.
28. Koppel CJ, Driesen BW, de Winter RJ, van den Bosch AE, van Kimmenade R, Wagenaar LJ, Jukema JW, Hazekamp MG, van der Kley F, Jongbloed MR, Kiès P, Egorova AD, Verheijen DBH, Damman P, Schoof PH, Wilschut J, Stoel M, Speekenbrink RGH, Voskuil M, Vliegen HW. The first multicentre study on coronary anomalies in the Netherlands: MuSCAT. *Neth Heart J* 2021;**29**:311–317.