



King Saud University
The Saudi Dental Journal

www.ksu.edu.sa
www.sciencedirect.com



A first experience with digital complete overdentures



Salwa Omar Bajunaid

Department of Prosthetic Dental Science, College of Dentistry, King Saud University, PO Box 66253, Riyadh 11576, Saudi Arabia

Received 25 September 2015; revised 16 November 2015; accepted 28 December 2015

Available online 22 July 2016

KEYWORDS

CAD/CAM;
Digital dentures;
Implant overdentures

Abstract The development of computer-aided design/computer-aided manufacturing systems for dentistry in the 1980s resulted in the successful fabrication of crowns, fixed dental prostheses, and superstructures for both natural teeth and dental implants. Today, this technology is available for constructing digitally designed and milled, completely removable dental prostheses. The procedure uses clinical and laboratory protocols that allow fabrication of completely removable prostheses within two clinical appointments. The aim of this clinical report is to present the author's first experience with digital complete overdentures, the practicality of this technology, and patient feedback. Compared with conventional overdentures, the fit of the digital prostheses was improved because the cameo and flanges of the prostheses were nicely shaped and rolled, and this enhanced their stability and retention. Occlusion was also excellent. However, aesthetics in terms of the alignment, shape, and size of the maxillary overdenture teeth were unacceptable. Despite some of the drawbacks identified in our study, the use of removable digital dentures does provide excellent adaptation of the denture base and requires fewer clinic visits. We anticipate that the unsatisfactory aesthetic outcomes presented in this report can be corrected with more experience. We also believe that acquiring an in-house scanning machine would be beneficial. We highly recommend including this technique in dental school curriculums at both the undergraduate and graduate levels in order to keep students and residents up to date on the latest technology available.

© 2016 The Author. Production and hosting by Elsevier B.V. on behalf of King Saud University. This is an open access article under the CC BY-NC-ND license (<http://creativecommons.org/licenses/by-nc-nd/4.0/>).

1. Introduction

Over the past few decades, remarkable developments in dental materials and technologies used in the fabrication of dental

E-mail address: dr_prosth@hotmail.com

Peer review under responsibility of King Saud University.



Production and hosting by Elsevier

devices have been made (Davidowitz and Kotick, 2011). In the 1980s, a major advance included the development of computer-aided design/computer-aided manufacturing (CAD/CAM) systems (Miyazaki et al., 2009; The Glossary of Prosthodontic Terms, 8th ed., 2005). CAD/CAM has been successfully used to fabricate crowns, fix dental prostheses (FDPs), and produce superstructures for placement on both natural teeth and dental implants. Implant custom abutments can also be fabricated using this technology (Kapos and Evans, 2014). The use of digital technology to fabricate dental restorations and prostheses minimizes clinician effort,

<http://dx.doi.org/10.1016/j.sdentj.2015.12.006>

1013-9052 © 2016 The Author. Production and hosting by Elsevier B.V. on behalf of King Saud University.

This is an open access article under the CC BY-NC-ND license (<http://creativecommons.org/licenses/by-nc-nd/4.0/>).

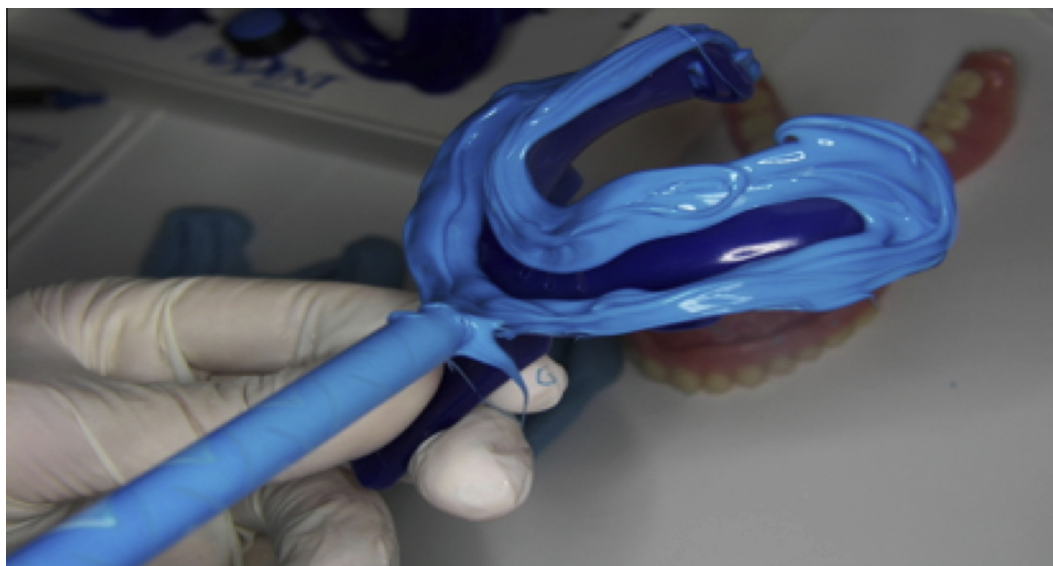

Figure 1 Border moulding of the lower tray.

laboratory time, materials, and expenses. Currently, CAD/CAM is used to construct digitally designed and milled custom complete dentures (Kanazawa et al., 2011; Kattadiyil et al., 2013). In contrast with the conventional technique of fabricating complete denture prostheses (Infante et al., 2014), CAD/CAM techniques use clinical and laboratory protocols that allow complete dentures to be fabricated over two clinical appointments (Bidra, 2014).

The purpose of this clinical report is to present our first experience with digital complete overdentures and patient feedback regarding this first effort. We will discuss the practicality of using computerized technology to fabricate complete dentures, especially when laboratory support is not readily available.

2. Case report

A 67-year-old female patient presented to the prosthodontic clinic in the College of Dentistry at King Saud University seeking replacement of her existing maxillary and mandibular implant-retained overdentures. Two implants were present in each arch and she expressed dissatisfaction with her existing overdentures. After the patient signed an informed consent for us to perform the clinical procedures, both conventional and digital removable overdentures were prepared for comparison.

A detailed patient history was obtained and both clinical and radiographic examinations were completed before the clinical procedures were performed. Digital prostheses were



Figure 2 Final impression of the upper arch.

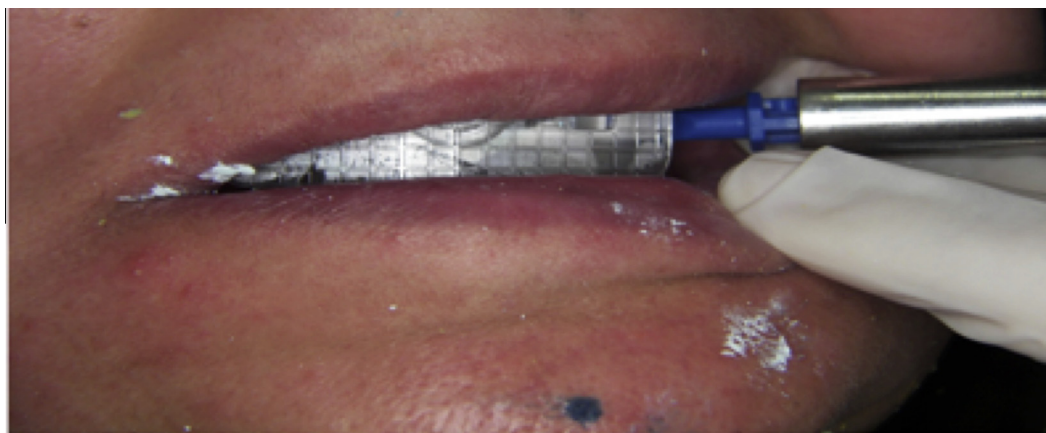

Figure 3 Vertical dimension of occlusion was adjusted on the AMD.

constructed using the AvaDent digital system (AvaDent™ Digital Dentures, Scottsdale, AZ, USA) with materials and techniques provided by the manufacturer. Briefly, maxillary and mandibular impressions were made using provided thermo-plastic trays and AvaDent heavy body and light body vinylpolysiloxane border moulding and impression materials, respectively (Figs. 1 and 2).

The maxillary-mandibular relationship was recorded using the Anatomic Measuring Device (AMD) that was provided (Fig. 3). Flange and tooth mould templates were also used to determine lip support, midline of the lip, the horizontal lip line, and the appropriate tooth size and shape (Fig. 4).

Both conventional and digital dentures were fitted during a routine insertion appointment. The fits of the intaglio surface and border extensions, as well as occlusion of the prostheses, were checked and pressure areas were adjusted. Outer surfaces of the prostheses were polished in the laboratory. Denture

aesthetics were checked by evaluating the shape, size, and position of the anterior teeth, lip support, midline, smiling line, and occlusal plane. Phonetics were also evaluated by asking the patient to pronounce different labial and labiodental sibilants such as F, V, S, Sh, and Th. Both the aesthetic properties and phonetics were approved by the patient.

3. Results

The cameo of the CAD/CAM digital complete overdentures was shaped to enhance the stability of the overdentures. Stability was subsequently assessed by alternately pressing on the right and left buccal surfaces of the premolar teeth to detect any rotational movements.

The flanges of the CAD/CAM digital complete overdentures were also rolled to enhance border seal and retention. These properties were verified by assessing the resistance of the prostheses to vertical displacement. The fit of the prostheses was also assessed using a pressure

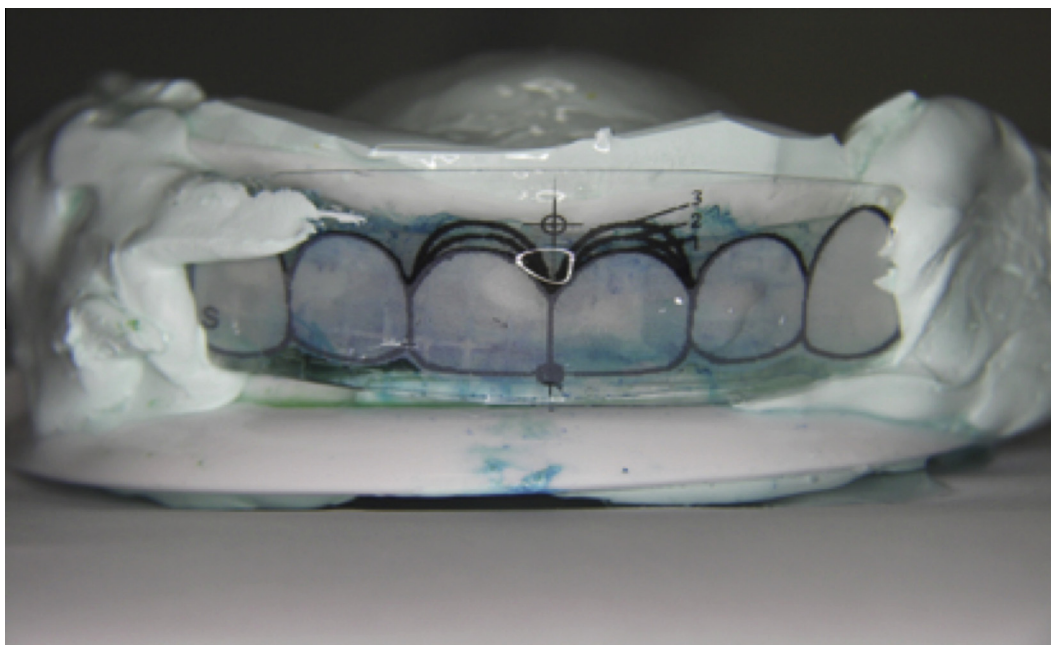


Figure 4 Tooth mould template.

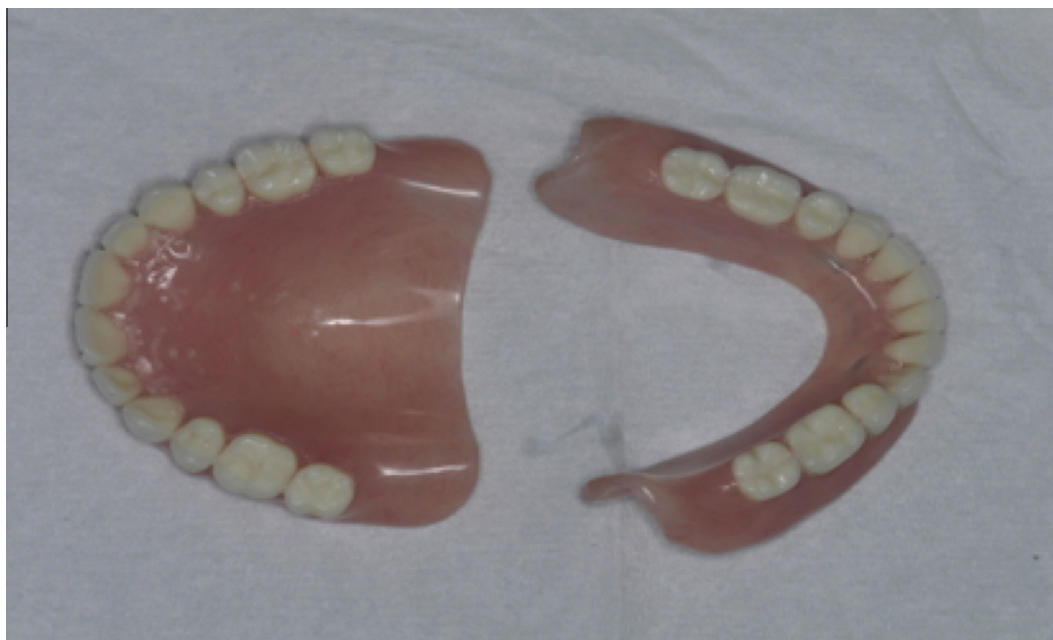

Figure 5 Perfect shape of the outer surfaces.

indicating paste (pip; Mizzy™, Myerstown, PA, USA) and only minimal adjustments were needed. In addition, both the centric and eccentric occlusions required only minor adjustments (Figs. 5 and 6).

However, the aesthetics of the CAD/CAM prostheses were found to be unacceptable to both the dentist and the patient. The position of the incisal line of the upper teeth was lower than it should have been, and this resulted in excessive exposure of the maxillary incisors and the gingival acrylic. The maxillary incisor teeth were also large and protruded (Fig. 7). In contrast, the aesthetics of the conventional overdentures were more acceptable, even though they required more adjustments to the intaglio, cameo surfaces, and occlusion (Fig. 8).

4. Discussion

AvaDent and Dentca are two commercial manufacturers of digital complete dentures worldwide, and both are based in the United States. (AvaDent Digital Dentures; Global Dental Science, <http://www.avadent.com>; Dentca-CAD/CAM Denture; Dentca Inc, <http://www.dentca.com>). AvaDent scans impressions with laser scanners and virtual dentures are produced with the use of sophisticated computer software. The bases are then milled from pre-polymerized

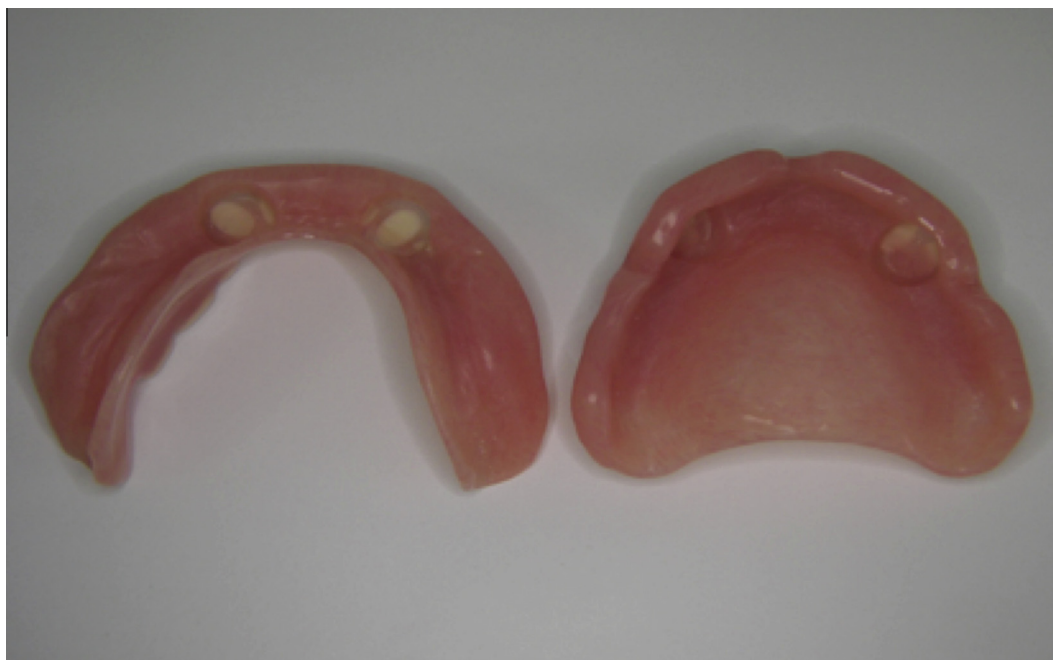

Figure 6 The flanges of the digital overdentures were nicely rolled.

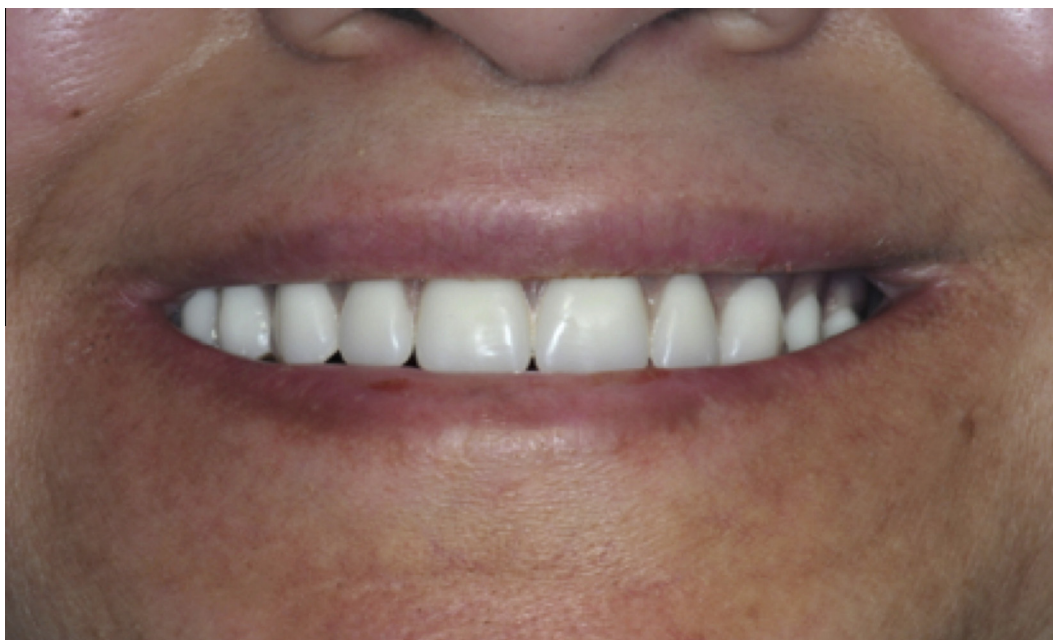

Figure 7 The final aesthetics of the dentures were not satisfactory to the patient or the dentist. The incisors appeared large and protruded.

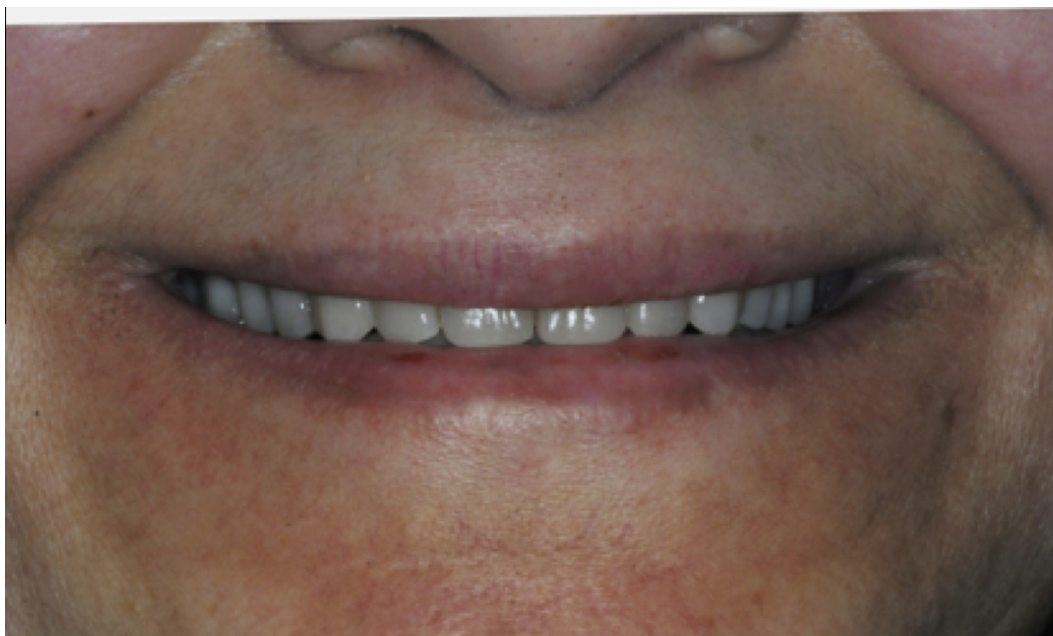

Figure 8 The patient preferred the conventional dentures since the incisors appeared smaller and greater lip support was provided.

and highly compressed acrylic materials. In contrast, Dentca uses computer software to produce virtual prostheses, and the dentures are subsequently fabricated using a conventional processing technique (Kattadiyil et al., 2013; Bidra et al., 2013; Goodacre et al., 2012).

Here, we report that the fit of the digital overdentures surpassed that of the conventional overdentures. This was evidenced by the minimal need for adjustments to the intaglio of the prostheses, and the excellent retention and stability of the overdentures. These results are consistent with those of a pilot

study conducted at Loma Linda University, where the fit of AvaDent denture bases was compared with that of three conventionally processed denture bases (Goodacre, 2014). The study concluded that complete denture bases milled from pre-polymerized blocks of resin exhibited more uniform adaptation and greater accuracy of fit compared with the complete denture bases that were fabricated using conventional processing techniques (Goodacre, 2014).

However, in the present case, the patient was not satisfied with the appearance of the digital overdentures, and preferred

the aesthetics of the conventional overdentures. This result affected the patient's overall response and lowered her appreciation for the better fit provided by the digital prostheses. This result is discordant with the results of a study conducted at the University of Detroit Mercy School of Dentistry that compared patients' feedback to digital and conventional dentures (Uszynski, 2014). The patients in the latter study reported retention to be the most advantageous property of digital dentures, especially for mandibular dentures (Uszynski, 2014). The unsatisfactory aesthetics of the digital overdentures in the present clinical effort could be attributed to two factors. One, this treatment was our first trial of the technique and more experience may prevent this problem in future attempts. For example, a try-in visit may be necessary for achieving better and more predictable results. Alternatively, a virtual try-in with submission of a patient's photo to the laboratory might be helpful. Two, the large geographic distance between the location of our dental clinics and the manufacturing lab may be a consideration. This situation could partly be addressed by establishing an in-house lab partnership with the manufacturer. Acquisition of a scanning machine could also eliminate the physical transfer of records and accelerate treatment initiation.

The manufacturer claims that the cost of digitally designed and milled dentures is comparable to that of conventional dentures. However, removable conventional dentures and overdentures are provided free of charge at our governmental sector hospitals and educational institutes. Therefore, if CAD/CAM digital removable prostheses are offered to patients, cost considerations would not be a significant factor. Another advantage of creating a 'virtual denture' is that a permanent digital record is produced. Thus, in the case of loss or breakage of the prosthesis, the patient can have an identical digital denture created in a few days without needing additional visits. The duplication of existing dentures is not a new concept, and has previously been reported with some success (Kawahata et al., 1997).

Overall, the good fit and reduced time in creating digitally constructed overdentures are motivating factors for the use of this virtual technique. It is anticipated that the unsatisfactory aesthetic results reported for the present case will be corrected with additional practice, a try-in visit, and greater experience.

Conflict of interest

The authors have no conflicts of interest to declare.

Acknowledgements

This research project was supported by a Grant from the Research Center for the Humanities, Deanship of Scientific Research at King Saud University.

References

- AvaDent Digital Dentures, Global Dental Science LLC. Available at: <<http://www.avadent.com>>.
- Bidra, A.S., 2014. The 2-visit CAD-CAM implant-retained overdenture: a clinical report. *J. Oral Implantol.* 40 (6), 722–728.
- Bidra, A.S., Taylor, T.D., Agar, J.R., 2013. Computer-aided technology for fabricating complete dentures: systematic review of historical background, current status, and future perspectives. *J. Prosthet. Dent.* 109 (6), 361–366.
- Davidowitz, G., Kotick, P.G., 2011. The use of CAD/CAM in dentistry. *Dent. Clin. North Am.* 55 (3), 559.
- Dentca-CAD/CAM Denture, Dentca Inc. Available at: <<http://www.dentca.com>>.
- Goodacre, B., 2014. Comparing the Surface Matching Accuracy of Conventional and CAD/CAM Methods of Fabricating Complete Denture Bases: A Pilot Study, Presented at the ACP 44TH Annual Session.
- Goodacre, C.J. et al., 2012. CAD/CAM fabricated complete dentures: concepts and clinical methods of obtaining required morphological data. *J. Prosthet. Dent.* 107 (1), 34–46.
- Infante, L., Yilmaz, B., McGlumphy, E., Finger, I., 2014. Fabricating complete dentures with CAD/CAM technology. *J. Prosthet. Dent.* 111 (5), 351–355.
- Kanazawa, M., Inokoshi, M., Minakuchi, S., Ohbayashi, N., 2011. Trial of a CAD/CAM system for fabricating complete dentures. *Dent. Mater. J.* 30, 93–96.
- Kapos, T., Evans, C., 2014. CAD/CAM technology for implant abutments, crowns, and superstructures term. *Int. J. Oral Maxillofac. Implants* 29 (suppl), 117–136. <http://dx.doi.org/10.11607/jomi.2014suppl.g2.3>.
- Kattadiyil, M.T., Goodacre, C.J., Baba, N.Z., 2013. CAD/CAM complete dentures: a review of two commercial fabrication systems. *J. Calif. Dent. Assoc.* 41 (6), 407–416.
- Kawahata, N. et al., 1997. Trial of duplication procedure for complete dentures by CAD/CAM. *J. Oral Rehabil.* 24, 540–548.
- Miyazaki, T. et al., 2009. A review of dental CAD/CAM: current status and future perspectives from 20 years of experience. *Dent. Mater. J.* 28, 44–56.
- The glossary of prosthodontic terms, 2005. *J. Prosthet. Dent.* 94, 20.
- Uszynski, J., 2014. Patient Denture Satisfaction at One Month Follow-up: Digital Versus Conventional. Presented at the International Association for Dental Research Poster Session, Charlotte, N.C., USA.