

Clinical findings and diagnostic procedures in 270 small ruminants with obstructive urolithiasis

Anna-Katharina Riedi¹ | Gabriela Knubben-Schweizer² | Mireille Meylan¹ 

¹Clinic for Ruminants, Vetsuisse Faculty, University of Bern, Bremgartenstrasse 109a, Bern 3012, Switzerland

²Department of Farm Animals, Vetsuisse Faculty, University of Zurich, Winterthurerstrasse 260, Zurich 8057, Switzerland

Correspondence

Mireille Meylan, Clinic for Ruminants, Bremgartenstrasse 109a, 3012 Bern, Switzerland.
Email: mireille.meylan@vetsuisse.unibe.ch

Present addresses

Anna-Katharina Riedi, Tierarztpraxis an der Simme, Simmentalstrasse 28, 3752 Wimmis, Switzerland

Gabriela Knubben-Schweizer, Clinic for Ruminants with Ambulatory and Herd Health Services, Centre for Clinical Veterinary Medicine, Ludwig-Maximilians University, Sonnenstrasse 16, Oberschleissheim 85764, Germany

Background: Details of the clinical signs of obstructive urolithiasis in male small ruminants have not been documented in a large population.

Objective: To describe the clinical presentation and diagnostic procedures in a large group of small ruminants with urolithiasis.

Animals: Two hundred and seventy small ruminants (158 sheep and 112 goats).

Methods: Retrospective study of 270 cases identified based on clinical records.

Results: 81.2% affected goats were castrated and 91.7% sheep were intact males; 65.5% of the animals had been sick ≤ 2 days before referral. Common abnormalities included dysuria (93.6%), indigestion (84.4%), reduced general state of health (79.5%), signs of pain (73%), increased heart and respiratory rates (53.6% and 39.1%), and azotemia (89.4%). Blood urea nitrogen (BUN) and creatinine concentrations were strongly correlated ($r^2 = 0.81$). Hypochloremia (52.2%), hyponatremia (43.3%), hypophosphatemia (52.4%), and abnormal potassium concentrations (26.2% hypokalemia and 24.5% hyperkalemia) were the most common serum electrolyte imbalances. Packed cell volume (PCV), plasma proteins, potassium, BUN, and creatinine concentrations were significantly increased in animals with uroperitoneum. Ultrasonography allowed for confirmation of diagnosis in 83.9% of the cases (135/161 with sufficient available information), uroliths were visible on 34 of 56 plain radiographs.

Conclusions and Clinical Importance: Our study confirmed that clinical and ultrasonographic examinations are sufficient to diagnose urolithiasis. Clinical signs can be divided into an early stage with discrete unspecific clinical signs, a painful stage with frequent straining, expression of pain and moderately reduced general condition, and an advanced stage with a markedly reduced general condition and eventually recumbency.

KEYWORDS

clinical signs, diagnosis, goats, sheep, urinary calculi

Abbreviations: BCS, body condition score; BUN, blood urea nitrogen; CK, creatinine kinase; NSAIDs, nonsteroidal anti-inflammatory drugs; PCV, packed cell volume; WBC, white blood cell count.

This is an open access article under the terms of the Creative Commons Attribution-NonCommercial License, which permits use, distribution and reproduction in any medium, provided the original work is properly cited and is not used for commercial purposes. © 2018 The Authors. Journal of Veterinary Internal Medicine published by Wiley Periodicals, Inc. on behalf of the American College of Veterinary Internal Medicine.

1 | INTRODUCTION

Obstructive urolithiasis is one of the most serious urinary tract disorders in domestic animals. Male small ruminants are commonly affected because of their particular anatomy, which includes a long, narrow, tortuous urethra with a thin urethral process.¹ Furthermore, the absence

of testosterone after early castration, as often practiced in pet goats, affects the development of the urethra in that its diameter remains small, which favors the retention of calculi and development of obstructive urolithiasis.² Uroliths in ruminants are classically classified into 2 categories based on their main component, phosphorus—associated with high-grain diets³—or calcium—associated with Ca-rich feeds such as alfalfa hay.⁴ However, amorphous magnesium calcium phosphate, alone or with struvite, is the most common urolith component in small ruminants in Texas (in 50% of analyzed uroliths). These findings underline the importance of urolith analysis to make adequate dietary recommendations.⁵ The distribution of urolith composition in Swiss small ruminants is unknown.

Unspecific clinical signs of urolithiasis include decreased appetite or anorexia, separation from the flock, congested mucous membranes, and increased heart and respiratory rates. Affected animals further show signs of discomfort, attempt to void urine, strain intermittently, or stay in a wide stance with their hind limbs stretched backwards. Complete urethral obstruction can cause rupture of the bladder or urethra within 24–48 hours.² Leakage from the distended or ruptured bladder into the abdomen leads to uroperitoneum.⁶ After bladder or urethra rupture, animals can show short-timed improvement because of reduced pressure in the urinary bladder, until progressive signs of uremia become evident. Advanced cases can also present with swelling of the ventral abdomen and of the prepuce because of leakage of urine into the surrounding tissue through a ruptured urethra. Uremic animals become increasingly weak and lethargic.² Real-time transabdominal B-mode ultrasonography can be used to assess the bladder, kidneys, and abdominal cavity. In case of suspected urolithiasis, ultrasonography is recommended to confirm the presence of a dilated bladder and to determine whether uroperitoneum is present.⁷ Radiopaque uroliths such as struvite and calcium oxalate calculi can be seen on plain radiographs, but contrast studies have been advocated for reliable radiological diagnosis of obstructive urolithiasis.⁸

Although urolithiasis in small ruminants has been described in numerous reports of small groups of affected animals, the range and distribution of clinical signs of the disease has not been documented in a large number of affected animals. Recent retrospective clinical studies included data from 25 to 107 animals.^{6,9–13} Our study describes the clinical presentation and diagnostic procedures in 270 small ruminants with obstructive urolithiasis based on the results of complete clinical examination, blood analyses, ultrasonography, and radiographic studies of the abdomen. The objective of the study was to describe the distribution of the various clinical signs and laboratory abnormalities with regard to their reliability for the diagnosis of obstructive urolithiasis in small ruminants.

2 | MATERIALS AND METHODS

The medical records of the sheep and goats with obstructive urolithiasis presented to the Clinics for Ruminants of the Vetsuisse Faculty in Bern and Zurich, Switzerland, from 1990 to 2010 were retrieved and the following variables were recorded: signalment, medical history, and

results of a complete physical examination¹⁴ upon admission, including the examination of the urethral process under spasmolytic medication, results of diagnostic imaging procedures, and blood analyses. Information about body condition score (BCS) collected upon initial examination was distributed into 5 categories: thin (1), moderate (2), good (3), very good (4), and obese (5). Ultrasonography was performed transabdominally in the inguinal region with a 5 MHz sector probe. The shape and maximal diameter of the urinary bladder, as well as the presence of free fluid in the abdomen (interpreted as uroperitoneum) were registered. If radiographs of the caudal abdomen were carried out (with the animals in lateral recumbency), information regarding the method used (plain versus contrast radiographs), whether uroliths were visible and their location, was extracted from the radiology reports. Blood analyses could include a CBC, a blood chemistry profile, a venous blood gas analysis or several of these analyses. If urine was voided, macroscopic appearance and pH were recorded. Because of incomplete records, the number of observations did not always correspond to the total number of animals included in the study.

The results of clinical examination, laboratory values, and diagnostic imaging procedures are reported. Numerical values are reported as mean \pm standard deviation (SD) for normally distributed data, otherwise as median and range (minimum–maximum). Linear logistic regression was used for assessment of associations between variables. Results of clinical examination and blood analyses were classified into 3 categories, “normal,” “increased,” or “decreased,” as compared with published reference values for sheep and goats.¹⁵ Results of blood analyses were compared between 2 categories regarding duration of disease (≤ 24 hours, > 24 hours) and between animals with and without evidence of uroperitoneum by use of the unpaired t-test for continuous variables and χ^2 -test or Fisher’s Exact Test for categorical values. Finally, the stage of disease was categorized based on clinical presentation as “early stage” (slightly reduced general condition and normal demeanor), “painful stage” (moderately reduced general condition, normal demeanor with signs of colic, and expressions of pain), and “advanced stage” (severely reduced general condition, depression, and in some cases recumbency). The blood values in these 3 categories were compared using logistic regression. A P -value ≤ 0.05 was considered significant. Statistical analyses were performed with a commercial software (NCSS, Number Crunch Statistical Software, Kaysville, Utah).

3 | RESULTS

3.1 | Animals

The study population comprised 270 male small ruminants (158 sheep and 112 goats). In sheep, the most common breeds were Swiss White Alpine (38%) and Brown Headed Meat sheep (19%). Most goats were pygmy goats (63%), followed by Swiss Saanen goats (11%). The mean age (\pm SD) of the overall population was 3.48 (± 2.31) years (minimum, 1.5 months; maximum, 12 years), or 2.94 (± 1.89) and 4.23 (± 2.63) years for sheep and goats, respectively. One hundred and four animals were castrated (13 sheep and 91 goats), and 165 were intact males (144 sheep and 21 goats). Castration status had not been registered for

1 sheep. Age at castration could be estimated by the owners of 24 animals: 9 animals had been castrated at ≤ 3 months, 9 at 3–6 months, and 6 after 6 months of age.

Information regarding feeding habits was available for 186 sheep and goats: 69 owners (37.1%) indicated that they fed no grain, but 109 (58.6%) gave grain regularly. Eight animals (4.3%) had received a high-grain diet, that is, a minimum of 0.5 kg of concentrate per day, before referral.

3.2 | Medical history

Incidence of new cases was relatively stable throughout the year, with the highest number of cases presented in January (32 cases, 12%), February and April (29 cases each, 11%) and the lowest caseload in June and July (15 and 17 cases, respectively, 6%).

The median duration of clinical signs before the animals were brought to a clinic was 2 days (range, 0–40), with 167 of 255 animals (65.5%) having been sick since ≤ 2 days. The reason for referral, if available, was a suspicion of disease in the urogenital tract in 170 cases and of a digestive disturbance in 43 cases. The history included anorexia in 141 animals and signs of colic in 157 cases. Treatment had been provided by private veterinarians in 160 cases (mostly with spasmolytic drugs—mainly metimazole—spasmolytics only in 78 animals, spasmolytics and antimicrobials in 25 cases, and spasmolytics, antimicrobials and nonsteroidal anti-inflammatory drugs [NSAIDs] in 8 cases). The referring veterinarian had amputated the urethral process in 18 of 270 cases.

3.3 | Physical examination

The findings observed upon physical examination, as recorded in the animals' charts, are given in Table 1 (condition and general signs of disease) and Table 2 (specific signs regarding expression of pain and urination).

The mean value of BCS for pygmy goats was higher than for non-pygmy goats and sheep, and pigmy goats presented BCS values between 3 and 5 only. Of the 28 animals in severely reduced general condition, 18 were presented in lateral recumbency. Fifty-four percent of the animals (135/252) showed an increased heart rate and 39.1% (97/248) an increased respiratory rate, 21.2% (51/240) had an increased temperature and 2.9% (7/240) had hypothermia. The majority of animals passed no urine at all (166/267, 62.2%), however 20 animals (7.5%) were able to void an amount of urine that was recorded as normal for the size of the animal. Of these 20 animals, 3 showed dysuria. Eighty-one animals (30.3%) voided only small amounts of urine, 30 of these in association with dysuria.

Closer examination of the urethral process was recorded for 173 cases (64.1%). The penis and urethral process could be exteriorized in 148 of these 173 cases (85.5%), but not in the other 25. Obesity prevented penis exteriorization in 19 of those 25 cases. The appearance of the urethral process was recorded for 42 cases: it was inflamed, necrotic or both in 25 animals (59.5%), a stone was located in the urethral process in 31 (73.8%).

TABLE 1 Summarized results of physical examination in small ruminants with urolithiasis (general)

Variable	No. of observations	Mean value	SD	
Body weight (kg)	Sheep	120	100.7	35.4
	Goats (nonpigmy)	33	74.5	19.8
	Pigmy goats	55	38.0	9.6
BCS	Sheep	149	3.2	0.8
	Goats (nonpigmy)	41	3.1	1.0
	Pigmy goats	66	3.9	0.8
Body temperature (°C)	240	39.1	0.7	
Heart rate (bpm)	252	114.2	26.8	
Respiratory rate (bpm)	248	50.3	31.6	
	No. of observations	n	%	
General condition	253			
	Normal	52	20.6	
	Slight depression	173	68.4	
Severe depression	28	11.1		
Skin turgor	193			
	Normal	112	58.0	
	Slightly reduced	43	22.3	
Severely reduced	38	19.7		
Mucous membranes	229			
	Normal	143	62.4	
	Reddened	60	26.2	
Altered ^a	26	11.4		
Rumen motility	250			
	Normal	39	15.6	
	Reduced	121	48.4	
Absent	90	36		
Intestinal motility	240			
	Normal	78	32.5	
	Reduced	110	45.8	
Absent	52	21.7		
Defecation	229			
	Normal	172	75.1	
	No feces	35	15.3	
Abnormal feces ^b	22	9.6		

Abbreviations: SD, standard deviation; bpm, beats per minute (heart rate) or breaths per minute (respiratory rate).

^aAltered mucous membranes = tacky (13), cyanotic (6), dry (3), pale (2), or icteric (2).

^bAbnormal feces = with mucus (10), diarrhea (5), bloody (5), too well digested (1), or malodorous (1).

Based on the results of initial examination, 258 animals could be assigned to a group according to the defined stages of disease: 48 animals (18.6%) to the early stage of disease, 127 animals (49.2%) to the painful stage, and 83 animals (32.2%) to the advanced stage of disease.

TABLE 2 Summarized results of physical examination in small ruminants with urolithiasis (specific)

Variable	No. of observations	n	%
Signs of colic	245		
Yes		143	58.4
No		102	41.6
Straining	238		
Yes		84	35.3
No		154	64.7
Expression of pain	237		
Yes ^a		101	42.6
No		136	57.4
Abdominal wall	226		
Tense		142	62.8
Normal		84	37.2
Urination	267		
Normal amount		20	7.5
Reduced amount		81	30.3
No urine		166	62.2
Urine appearance	72		
Normal		35	48.6
Altered ^b		37	51.4

^aExpression of pain = teeth grinding (76), moaning (15), screaming (6), kicking to the abdomen (5), or forced respiration (3) [total number of pain expressions > number of animals expressing pain as some animals showed 2 different signs of pain].

^bAltered urine appearance = bloody (25), turbid (6), dark (3), or colorless (3).

3.4 | Diagnostic imaging procedures

Ultrasonography of the abdominal cavity was performed on 243 animals (90.0%). No conclusive description of the findings was given for 82 animals, although the size of the urinary bladder was recorded in 178 cases and its appearance in 154 cases. The mean (\pm SD) maximal diameter recorded for the bladder was 10.6 (\pm 2.9) cm in sheep ($n = 98$), 10.0 (\pm 1.8) cm in (nonpigmy) goats ($n = 32$), and 7.98 (\pm 1.9) cm in pygmy goats ($n = 48$). Ultrasonographic examination was considered to be of diagnostic value in 135/161 cases (83.9%), based on the presence of an enlarged bladder (large diameter, round shape, and thin wall), hyperechoic material in the bladder, free abdominal fluid or several of these features. Free fluid in the abdomen was observed in 33 animals (13.6%). Animals with clinical signs for >24 hours were more likely to present uroperitoneum upon ultrasonographic examination than those with a shorter disease history (OR 6.5, 95% CI 2.4–17.7, $P < 0.0001$).

Radiology reports were available for 56 cases (20.7% of all cases). Uroliths were visible on 34 plain radiographs (60.7%). A radiograph with several uroliths is shown in Figure 1. The localization of urinary calculi on the radiographs was, in order of decreasing frequency, urinary bladder and urethra (15, 44.1%), urinary bladder only (6, 17.6%), distal urethra (between the sigmoid flexure and the urethral process)

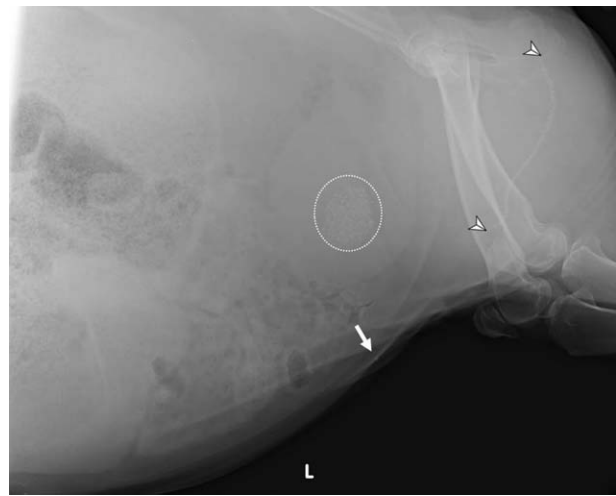


FIGURE 1 Plain radiograph of the caudal abdomen of a male goat with obstructive urolithiasis. Multiple radiopaque urinary calculi in the urinary bladder (dotted circle), along the pelvic and sigmoid flexure (arrowheads indicate beginning and end of the urolith line) and in the distal part of the urethra (arrow). Courtesy of the Radiology Unit of the Vetsuisse Faculty, University of Bern

only (5, 14.7%), urethra (with no further details on urolith localization) only (4, 11.8%), and sigmoid flexure and distal urethra, pelvic flexure only, and sigmoid flexure only (1 each, 2.9%). In 7 cases with uroliths visible both in the urinary bladder and in the urethra, the urethral location had been further specified to be the pelvic flexure in 5 cases and the sigmoid flexure in 2 cases. Contrast radiographs carried out in 3 cases did not reveal additional diagnostic information.

3.5 | Laboratory analyses

The results of blood analyses are shown in Table 3. The mean blood urea nitrogen (BUN) (\pm SD) was distinctly above normal limits (reference value: 2.1–7.2 mmol/L) with 30.25 (\pm 25.93) mmol/L, although 47 out of 246 animals (19.0%) did not have increased BUN values. The mean creatinine value (\pm SD) was also increased with 738.0 (\pm 628.3) μ mol/L (reference value: 39–102 μ mol/L). Serum creatinine was normal in 12 out of 198 cases (6.1%). A high correlation was observed between BUN and creatinine values ($r^2 = 0.81$, $P < 0.00001$). Because a complete blood chemistry profile was not performed in all cases and especially concentrations of both BUN and creatinine were not always available for animals presented during emergency hours, a variable “azotemia,” defined as increased concentrations of BUN, creatinine or both, was created. Azotemia was present in 220 of 246 animals (89.4%) for which a value of BUN, creatinine or both was available, it was the most common abnormality in the blood chemistry profile. The degree of azotemia was significantly associated with the stage of disease ($P < 0.05$; Figure 2), animals in the early or painful stages of disease showed significantly lower concentrations of BUN, creatinine or both than animals in the advanced stage of disease. Median BUN and creatinine (19.0 mmol/L, range: 1.8–115.8 mmol/L, and 456 μ mol/L, range: 46–2660 μ mol/L, respectively) were significantly ($P < 0.0001$)

TABLE 3 Summarized results of blood analyses in small ruminants with urolithiasis

Variable	5%-Quantile	Median	95%-Quantile	n	Reference values ^a
Sheep					
PCV	0.23	0.34	0.46	144	0.27-0.38
Plasma protein (g/L)	59	72	102	138	63-83
WBC ($10^9/L$)	3.7	7.5	12.8	135	4.5-11.4
Sodium (mmol/L)	136	149	156	142	149-159
Potassium (mmol/L)	3.7	5.6	9.2	138	4.6-6.5
Calcium (mmol/L)	2.0	2.5	2.8	85	2.3-2.8
Chloride (mmol/L)	84	102	118	138	104-117
Phosphate (mmol/L)	0.5	1.3	4.1	87	1.2-2.3
BUN (mmol/L)	4.7	26.0	76.3	144	2.1-7.2
Creatinine ($\mu\text{mol/L}$)	86	667	2033	121	60-102
Bilirubin ($\mu\text{mol/L}$)	1.5	3.2	6.7	129	1.0-2.8
Creatine kinase (U/L)	80	271	2400	131	86-208
Blood pH	7.207	7.439	7.558	100	n.a.
Base excess (mmol/L)	-6.6	2.9	14.3	100	n.a.
Goats					
PCV	0.25	0.36	0.52	100	0.24-0.35
Plasma Protein (g/L)	61	70	91	91	59-82
WBC ($10^9/L$)	7.3	12.9	23.7	84	7.8-19.6
Sodium (mmol/L)	139	149	156	97	147-157
Potassium (mmol/L)	3.1	4.5	7.5	98	4-5.8
Calcium (mmol/L)	2.0	2.4	3.0	73	2.2-2.7
Chloride (mmol/L)	85	102	115	93	102-114
Phosphate (mmol/L)	0.5	1.0	2.9	76	1.2-2.9
BUN (mmol/L)	3.6	16.4	102.7	101	2.8-7.2
Creatinine ($\mu\text{mol/L}$)	66	494	2634	76	39-67
Bilirubin ($\mu\text{mol/L}$)	1.4	3.2	9.7	87	0.4-2.2
Creatine kinase (U/L)	49	373	3909	92	96-268
Blood pH	7.245	7.410	7.508	75	n.a.
Base excess (mmol/L)	-12.4	-1	8.7	76	n.a.

^aReference values = 5-95% quantiles of values reported for healthy sheep and goats, respectively (Tschuor et al., 2008).¹⁵

Abbreviation: n.a., not applicable.

lower for animals with clinical signs for ≤ 24 hours than for animals with clinical signs for > 24 hours (41.5 mmol/L, range: 1.8-115.7 mmol, and 979.3 $\mu\text{mol/L}$ range: 67-3098 $\mu\text{mol/L}$, respectively).

Further abnormalities in blood chemistry included hypochloremia (121/232, 52.2%), hyponatremia (104/240, 43.3%), and imbalances in K concentrations (62/237 cases of hypokalemia, 26.2%, and 58 of hyperkalemia, 24.5%). Hypophosphatemia was observed in 86/164 animals (52.4%) and hyperphosphatemia in 19 (11.6%). The median activity of the creatinine kinase (CK) was increased with a value of 317.5 IU/L (range, 29-13'900; normal, 86-268 IU/L).

In comparison with values from affected animals with an intact urinary tract, the serum biochemistry abnormalities associated with uroperitoneum included significantly higher values of packed cell volume (PCV) ($P = 0.03$), plasma protein ($P = 0.01$), K ($P < 0.0001$), BUN ($P = 0.0001$), and creatinine ($P = 0.0002$). The Na and Cl values were lower in animals with uroperitoneum but the differences were not significant ($P = 0.08$ and $P = 0.056$, respectively). Serum P values were not significantly associated with the presence or absence of uroperitoneum, but 10 out of the 19 animals with hyperphosphatemia had uroperitoneum.

Urine color, recorded for 72 animals, was normal in 35 cases (48.6%) and altered in 37 cases (51.4%). Bloody colored urine, observed in 25 animals, was generally associated with dysuria (22 animals, 88%).

The mean urine pH (\pm SD) was 7.93 (± 0.76) in the 59 cases for which a urine sample could be analyzed.

4 | DISCUSSION

Our study describes the clinical findings and results of diagnostic procedures in 270 small ruminants with obstructive urolithiasis. While the high prevalence of the classical presentation with dysuria or ischuria combined with azotemia and pathologic ultrasonographic findings was confirmed, these results revealed that one or more of these cardinal clinical signs were absent in a considerable percentage of cases, therefore their absence did not rule out a diagnosis of obstructive urolithiasis.

In the population under study, the two most common Swiss Sheep Breeds represented almost 60% of the affected animals, thus the breed distribution appeared to correspond to the general distribution in Switzerland. In contrast, pigmy goats were over-represented with 63% of the affected goats. Since pigmy goats are mostly kept as pets, their owners were possibly more likely to endorse costs of treatment. In addition, pet (pygmy) goats are often castrated early, which is a recognized risk factor for obstructive urolithiasis.¹⁶ The approximate time of castration for the study population could be estimated by the owners of 24 of 104 castrated animals only, most of the bucks having been

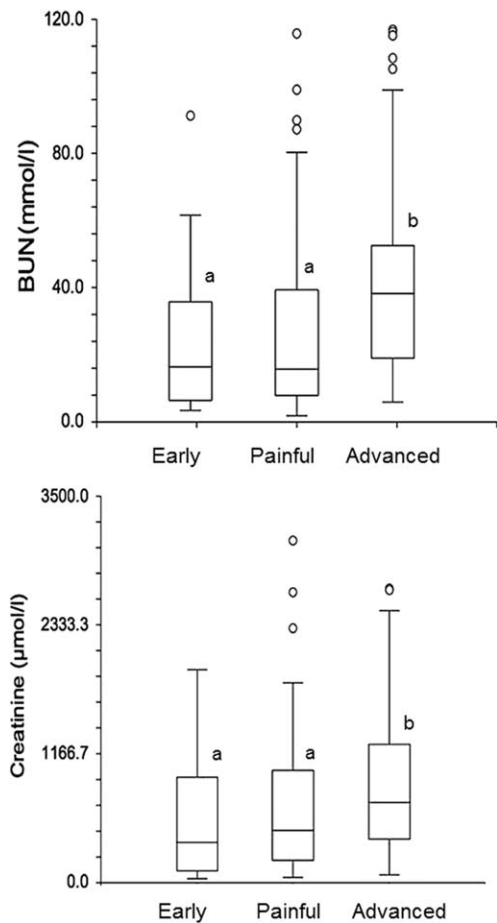


FIGURE 2 Box-plots of BUN and blood creatinine concentrations and distribution among the three consecutive stages of disease: early (normal demeanor), painful (slight depression and active expression of pain), and advanced (profound depression to recumbency). Different superscripts within a box-plot indicate significant differences ($P < 0.05$)

purchased after castration, but early castration was confirmed in 75% of those cases. Most goats (81.2%) were castrated, whereas 91.7% of the sheep were intact males. The mean age of the sheep was also lower, likely because they were used for reproduction for a limited time period only. This distribution has previously been reported by others¹⁷ and describes rather the demographics of the population at risk than an interspecies difference in the development of urolithiasis. Nonetheless, our study population included more intact than castrated animals (165 versus 104), confirming that intact males are also prone to urolithiasis, especially in presence of other risk factors such as concentrate-rich feeding. Indeed, almost 60% of all animals were fed grain regularly, and 8 animals, all intact males, had been fed high amounts of concentrates in the days and weeks before disease, in preparation for a show or a fair. While the information regarding the feeding regimen of the animals extracted retrospectively from their charts must be considered with caution, the high mean BCS supports the assumption that many animals had been fed an inappropriately rich diet before the development of disease. A high-grain diet is recognized as an important risk factor for the development of uroliths because

high P intake with concentrate feed leads to high P excretion through the urinary system and facilitates the formation of struvite calculi.¹⁸ Thus, obesity can be considered as an indicator of inappropriate high-energy feeding, predisposing animals to the formation of struvite uroliths. Male small ruminants should be fed a roughage diet to stimulate salivary function and rumination to promote fecal rather than renal phosphorus excretion.³ Their energy requirements are normally too low to warrant additional concentrate feed.¹⁹

The fact that the caseload was slightly above average during the winter months could be related to reduced water intake because of cold or frozen drinking water. Indeed, frozen water unnoticed by the owners until the animals became sick was documented in the history of several affected animals.

The duration of clinical signs of 1–2 days in 65.5% of the animals in our study was consistent with earlier reports.^{6,11,20} Only 21 animals (7.8%) had shown (intermittent) signs of disease for more than 5 days before referral. The reported duration of disease before treatment depends mostly on accurate observation by the animals' owners, thus this variable is of little value to evaluate the course of disease.

Before presentation at a referral clinic, 59.3% of the animals had been treated, mostly with spasmolytic drugs, antimicrobials, NSAIDs or several of these in combination, and the urethral process had been amputated in 6.7% of the cases. The low rate of treatment before referral, the limited specificity of treatments, and the fact that over 15% of the 270 cases were referred with a suspicion of gastrointestinal disease suggested a low awareness about urolithiasis in male small ruminants by the referring veterinarians.

Based on the records of the 270 cases under study and in accordance with the literature,^{2,4} the most common clinical signs observed in small ruminants with obstructive urolithiasis included anorexia, colic, teeth grinding, increased heart rate, and abnormal to absent micturition. The latter sign is often regarded as most specific of urolithiasis, with attempts at urination often accompanied by colic, straining, and further expressions of pain.^{2,4} In our study, signs of pain were recorded only in ~50% (134 of 270) of all animals. In contrast, colic was reported by the referring veterinarians or owners in 58.1% of the cases. This discrepancy could be because of the administration of spasmolytic drugs before referral, by a more advanced stage of disease by the time of arrival at the clinic or both. Of the 136 animals without signs of pain, 65% could not void any urine, 29% only small amounts, and 6% showed normal micturition. One third (29 of 88) of the animals with complete obstruction but no signs of pain were severely lethargic, blood analyses revealed severe uremia for 28 of them. These results confirmed that the absence of colic does not rule out obstructive urolithiasis, but possibly rather indicate an advanced stage of disease. In our study population, teeth grinding (28.1%) was the second most common sign of pain after colic. Other signs of discomfort such as straining and moaning can also be observed in animals with intestinal obstruction,²¹ thus it is important to assess fecal output in small ruminants with suspected urinary tract obstruction.

The presence or absence of micturition and signs of dysuria must be assessed carefully during clinical examination. In our study, 37.4% of the animals were still passing urine, although the majority of them

(80.2%) showed dysuria. Urine color was normal in approximately half of the cases where it could be assessed (35 of 72). Of the animals with dysuria, 41% had normally colored urine. These results indicate that neither maintained micturition nor normal gross urine appearance precluded from a tentative diagnosis of urolithiasis, although ~2 thirds of the animals had complete urinary obstruction.

Examination of the urethral process should be a routine step in the diagnostic procedure for suspected urolithiasis, because the urethral process is the most common localization of urinary calculi in small ruminants (86% of the uroliths).⁹ This was confirmed by our results with uroliths found in the urethral process in 73.8% of the cases. The manipulation can be difficult in obese animals, and adhesions between the penis tip and the preputial membrane can prevent exteriorization of the urethral process in animals castrated early. Affected animals can also resist the manipulation because of pain.² It was not possible to exteriorize the urethral process in 25 of the study animals, in 19 of these because of obesity. Visual evaluation of the urethral process was not performed before general anesthesia in animals which were immediately taken to surgery for bladder rupture or when the urethral process had been amputated before referral.

Ultrasonography was performed in 90.7% of the study animals, while radiographs were carried out in 23.3% only. This discrepancy can be explained by the ease of use of ultrasonography versus radiography at both clinics. Transabdominal ultrasonographic examination is a rapid, easy method that allows picturing a dilated urinary bladder, free fluid in the abdomen, hydronephrosis, and sometimes urinary calculi themselves. It has been reported that obstructive urolithiasis should not be diagnosed ultrasonographically in sheep based on the presence of a large urinary bladder alone because this can also be seen in healthy rams. In contrast, bladder shape, bladder wall and urethra appearance, as well as presence of free fluid in the abdomen are considered to be of diagnostic relevance.⁷ In our study, a subjectively large (in relation to the animal's size), round urinary bladder with a thin wall was considered suggestive of urinary outflow obstruction. The mean maximal diameter of the bladder of the 98 sheep with urolithiasis (10.6 cm) was distinctly higher than the diameter described in 20 healthy rams (7.5 cm).⁷ The abdomen should always be scanned for free fluid, especially if the urinary bladder does not appear to be enlarged. However, the presence of a full bladder does not rule out bladder rupture because a ruptured bladder does not always empty completely.⁷

In our study, radiographs were mostly performed in addition to ultrasonography to locate stones in the urinary tract, to assess the extent of urethral obstruction more precisely, and to determine the number and size of uroliths present in the urinary tract. To our knowledge, a comparative evaluation of ultrasonography versus plain radiographs for the diagnosis and prognosis of obstructive urolithiasis in small ruminants is not available. Unfortunately, the location, size, and number of radiopaque calculi along the urethra were not always described in the radiology reports retrieved for this retrospective study. If a location was indicated, the results confirmed the pelvic flexure, sigmoid flexure and distal urethra as the 3 predilection sites.^{9,22} In 16.1% of the radiographs, stones were seen in the urinary bladder only. Contrast radiographs have been reported to be of superior value for the

diagnosis of urolithiasis in small ruminants,⁸ however others have found that plain radiographs are sufficient.²² In our study, only 3 contrast radiographs were performed because ultrasonography and plain radiographs were considered to be sufficient to confirm the clinical diagnosis of urolithiasis, and contrast studies were waived not to delay treatment for animals in critical condition.

Blood analyses can be helpful if a complete physical examination does not allow for confirming a diagnosis of obstructive urolithiasis with certainty. Although azotemia can have multiple other causes such as dehydration (prerenal azotemia), it is commonly reported in animals with obstructive urolithiasis (postrenal azotemia).^{6,12,23} This was confirmed by the results of our study as the mean BUN and creatinine concentrations in affected animals were distinctly above reference values. Although azotemia was the most frequent abnormality in the biochemistry profile (81.5% of the affected animals), the measured BUN concentrations were within the normal range in 19.0% and creatinine concentrations in 6.1% of the cases. These animals with normal values were still in good general condition. Nonetheless, these results indicated that obstructive urolithiasis cannot be ruled out based solely on the absence of azotemia. The significant correlation demonstrated between BUN and creatinine values ($r^2 = 0.81$) confirmed that both variables can be used for diagnosis of urinary tract obstruction, depending on the laboratory methods available. As financial constraints often limit diagnostic and therapeutic options in small ruminants, these results also suggested that measurement of both variables is not necessary.

Leakage of urine into the abdominal cavity after bladder or ureter rupture or through the wall of the distended urinary bladder is a common complication of obstructive urolithiasis.⁶ Urine osmolarity is higher than that of blood, as are K, BUN, and creatinine concentrations, but Na and Cl concentrations are lower. After urine leakage into the abdominal cavity, water and electrolytes follow concentration gradients across the peritoneum, leading to hyponatremia, hypochloremia and relative hemoconcentration.²⁴

Hyponatremia, hypochloremia, hyperkalemia, and hypophosphatemia have been previously described in the context of urolithiasis in small ruminants.¹² In our study, the mean Na, K, Ca, P, Cl, and pH values were within normal limits. However, a considerable number of values were beneath the normal range for Na (38.5%) and Cl (44.8%), and increased (26.4%) or abnormally low (25.8%) for K. Since hyperkalemia can lead to cardiac dysfunction,²⁵ these results confirmed that the serum K concentration should be determined before electrolyte treatment. The serum K concentrations were significantly ($P = 0.0006$) different in the presence or absence of uroperitoneum. Hypokalemia was attributed mostly to reduced intake associated with decreased appetite. A correlation with abnormal base excess¹² was not observed in our study.

In accordance with a study in 107 goats with uroliths,¹² hypophosphatemia (31.9%) was the most common abnormality in P homeostasis. The present results confirmed that hypophosphatemia can be present in goats and sheep with urolithiasis. In contrast, 10 out of 19 animals with uroperitoneum had hyperphosphatemia, which is in accordance with observations in cattle with ruptured urinary bladder.²⁴ The development of urinary calculi has been suspected to be a hereditary

problem related to insufficient P reabsorption in the kidneys.¹² Others have found that Texel lambs developing urolithiasis have significantly higher urinary P concentrations than control animals.²⁶ The high prevalence of hypophosphatemia in our study would be in accordance with the hypothesis that small ruminants with urolithiasis excrete higher amounts of P via the kidneys than healthy animals, however, measurements of urinary excretion of electrolytes were not performed.

The CK activity was increased in most animals (138/224, 61.6%). While the elevation was mainly slight to moderate, the measured value was more than four times the reference value and up to over 10'000 IU/L in 39 animals (17.4%). Of these 39 animals, 18 were recumbent and 17 severely lethargic. Increased CK activity has not been described specifically in association with urolithiasis. The increased values observed can have been caused by recumbency because of reduced general condition, increased muscle activity because of frequent straining and colic, or transportation,²⁵ and were likely not directly associated with the pathogenesis of the primary disease.

These results confirmed that the diagnostic steps for urolithiasis in small ruminants should include a complete physical examination and ultrasonography, and can be completed, if available, by a few laboratory analyses. Although the classical clinical signs of obstructive urolithiasis, that is, reduced general condition, painful behavior, abnormal urination and signs of indigestion, were present in a large proportion of affected animals, our results underlined that the disease can be present in the absence of one or several cardinal clinical signs. Furthermore, the categorization of obstructive urolithiasis into 3 consecutive stages (early stage with an only slightly reduced general condition and no active expression of pain, likely to be noticed by most attentive owners only, followed by a stage during which colic is manifested actively by frequent straining, attempts to void urine and expression of pain, and finally a more advanced stage of depression characterized by a severely reduced demeanor and general condition, and sometimes recumbency) based on the animal's clinical presentation can be helpful for the veterinarian: a few basic clinical observations, although unspecific, can be used reliably as indicators for the severity of disease. It is important to keep these different stages of disease presentation in mind, especially for animals in the advanced stage of disease as the typical clinical signs generally associated with urolithiasis (straining, colic) can be absent. For diagnostic purposes, increased serum BUN or creatinine concentrations appear to be sufficient to support a clinical suspicion of urolithiasis; further blood work (PCV, electrolytes) is only needed for further case management, especially if surgery under general anesthesia is considered. Abdominal ultrasonography allows for final confirmation of the diagnosis, in combination with the results of clinical and blood examinations. Radiography offers little added diagnostic value, but can be used for better prognostic appraisal.

5 | CONCLUSION AND CLINICAL RELEVANCE

The analysis of the records of a large number of small ruminants with urolithiasis showed that the clinical presentation of the disease can show large discrepancies and that some of the typical clinical signs can

be absent in a considerable proportion of the affected animals. Abdominal ultrasonography and limited blood work were sufficient to confirm the diagnosis and allow for further decisions regarding management of affected animals.

ACKNOWLEDGMENT

This study was conducted at the Clinic for Ruminants of the University of Bern.

CONFLICT OF INTEREST DECLARATION

Authors declare no conflict of interest.

OFF-LABEL ANTIMICROBIAL DECLARATION

Authors declare no off-label use of antimicrobials.

INSTITUTIONAL ANIMAL CARE AND USE COMMITTEE (IACUC) OR OTHER APPROVAL DECLARATION

Authors declare no IACUC or other approval was needed.

ORCID

Meylan Meylan  <http://orcid.org/0000-0003-0191-5686>

REFERENCES

- [1] Videla R, van Amstel S. Urolithiasis. *Vet Clin North Am Food Anim Pract.* 2016;32:687–700.
- [2] Smith M, Sherman D. Urinary System. In: Smith M, Sherman D, eds. *Goat Medicine.* 2nd ed. Oxford: Wiley-Blackwell; 2009:537–569.
- [3] Hay L. Prevention and urolithiasis in sheep. *In Pract.* 1990;12:87–91.
- [4] Van Metre D. Obstructive urolithiasis in ruminants: surgical management and prevention. *Compend Contin Educ Pract Vet.* 1996;18:275.
- [5] Jones ML, Gibbons PM, Roussel AJ, Dominguez BJ. Mineral composition of uroliths obtained from sheep and goats with obstructive urolithiasis. *J Vet Intern Med.* 2017;31:1202–1208.
- [6] Ewoldt JM, Anderson DE, Miesner MD, Saville WJ. Short- and long-term outcome and factors predicting survival after surgical tube cystostomy for treatment of obstructive urolithiasis in small ruminants. *Vet Surg.* 2006;35:417–422.
- [7] Braun U, Schefer U, Föhn J. Urinary tract ultrasonography in normal rams and in rams with obstructive urolithiasis. *Can Vet J.* 1992;33:654–659.
- [8] Palmer JL, Dykes NL, Love K, Fubini SL. Contrast radiography of the lower urinary tract in the management of obstructive urolithiasis in small ruminants and swine. *Vet Radiol Ultrasound.* 1998;39:175–180.
- [9] Kümper H. [Urolithiasis in male sheep and goats. Clinical picture, therapeutic possibilities and prognostic evaluation]. *Tierärztl Prax.* 1994;22:234–241.
- [10] Fortier LA, Gregg AJ, Erb HN, Fubini SL. Caprine obstructive urolithiasis: requirement for 2nd surgical intervention and mortality after percutaneous tube cystostomy, surgical tube cystostomy, or urinary bladder marsupialization. *Vet Surg.* 2004;33:661–667.
- [11] Janke JJ, Osterstock JB, Washburn KE, Bissett WT, Roussel AJ, Hooper RN. Use of Walpole's solution for treatment of goats with urolithiasis: 25 cases (2001–2006). *J Am Vet Med Assoc.* 2009;234:249–252.

- [12] George JW, Hird DW, George LW. Serum biochemical abnormalities in goats with uroliths: 107 cases (1992–2003). *J Am Vet Med Assoc.* 2007;230:101–106.
- [13] Tamilmahan P, Mohsina A, Karthik K, et al. Tube cystostomy for management of obstructive urolithiasis in ruminants. *Vet World.* 2014;7:234–239.
- [14] Terra RL, Reynolds JR. Ruminant history, physical examination, welfare assessment and records. In: Smith BP, ed. *Large Animal Internal Medicine.* 5th ed. St. Louis, Missouri: Mosby Elsevier; 2015:2–12.
- [15] Tschuor AC, Riond B, Braun U, Lutz H. Hämatologische und klinisch-chemische Referenzwerte für adulte Ziegen und Schafe. *Schweiz Arch Tierheilkd.* 2008;150:287–295.
- [16] Bani Ismail ZA, Al-Zghoul MF, Al-Majali AM, Khraim NM. Effects of castration on penile and urethral development in Awassi lambs. *Bulg J Vet Med.* 2007;10:29–34.
- [17] Dühlmeier R, Zibell G, von Altrock C, et al. Urolithiasis beim kleinen Wiederkäuer - Behandlungsmethoden und klinische Rekonvaleszenz. *Tierärztl Prax.* 2007;35:175–182.
- [18] Hoar DW, Emerick RJ, Embry LB. Potassium, phosphorus and calcium interrelationships influencing feedlot performance and phosphatic urolithiasis in lambs. *J Anim Sci.* 1970;30:597–600.
- [19] Arrigo Y. Fütterungsempfehlungen für das Schaf und für die Ziege. In: Fütterungsempfehlungen für Wiederkäuer (Grünes Buch), Kapitel 11–12, Ed. Agroscope, Posieux, 2016. Accessed November 24, 2017.
- [20] Fazili MR, Malik HU, Bhattacharyya HK, Buchoo BA, Moulvi BA, Makhdoomi DM. Minimally invasive surgical tube cystostomy for treating obstructive urolithiasis in small ruminants with an intact urinary bladder. *Vet Rec.* 2010;166:528–531.
- [21] Tafti A. Ileoileal intussusception associated with coccidiosis in sheep. *J Vet Med Ser B.* 1999;46:659–663.
- [22] Kinsley MA, Semevolos S, Parker JE, Duesterdieck-Zellmer K, Huber M. Use of plain radiography in the diagnosis, surgical management, and postoperative treatment of obstructive urolithiasis in 25 goats and 2 sheep. *Vet Surg.* 2013;42:663–668.
- [23] May KA, Moll HD, Wallace LM, Pleasant RS, Howard RD. Urinary bladder marsupialization for treatment of obstructive urolithiasis in male goats. *Vet Surg.* 1998;27:583–588.
- [24] Sockett D, Knight AP. Metabolic changes associated with obstructive urolithiasis in cattle. *Compend Contin Educ Pract Vet.* 1984;6:311–315.
- [25] Carlson GP. Clinical Chemistry Tests. In: Smith BP, ed. *Large Animal Internal Medicine.* 5th ed. St. Louis, MI: Mosby Elsevier; 2015:375–397.
- [26] Packett LV, Hauschild JP. Phosphorus, calcium and magnesium relationships in ovine urolithiasis. *J Nutr.* 1964;84:185–190.

How to cite this article: Riedi A-K, Knubben-Schweizer G, Meylan M. Clinical findings and diagnostic procedures in 270 small ruminants with obstructive urolithiasis. *J Vet Intern Med.* 2018;32:1274–1282. <https://doi.org/10.1111/jvim.15128>