



Contents lists available at ScienceDirect

International Journal of Surgery Case Reports

journal homepage: www.casereports.com

Usefulness of cervical computed tomography and magnetic resonance imaging for rapid diagnosis of crowned dens syndrome: A case report and review of the literature



Akihiro Inoue^{a,*}, Kanehisa Kohno^a, Satoko Ninomiya^b, Hitomi Tomita^b, Shinji Iwata^a, Shiro Ohue^a, Kenji Kamogawa^b, Kensho Okamoto^b, Shinya Fukumoto^a, Haruhisa Ichikawa^a, Shinji Onoue^a, Saya Ozaki^a, Bungo Okuda^b

^a Departments of Neurosurgery, Ehime Prefectural Central Hospital, Japan

^b Departments of Neurology, Ehime Prefectural Central Hospital, Japan

ARTICLE INFO

Article history:

Received 25 August 2016

Accepted 21 November 2016

Available online 23 November 2016

Keywords:

Crowned dens syndrome

Crystalline deposition disease

Nonsteroidal anti

Inflammatory drugs

Meningitis

MRI findings

ABSTRACT

INTRODUCTION: Crowned dens syndrome is a rare disease entity which radiologically shows calcification of the cruciform ligament around the odontoid process. We report a patient with crowned dens syndrome who improved dramatically in 5 days following treatment with oral nonsteroidal anti-inflammatory medication.

PRESENTATION OF CASE: A 61-year-old man was admitted to our hospital with a severe occipital headache and sudden onset of neck stiffness. Neurological examination on admission revealed a high fever and cervical rigidity. Laboratory examination revealed a markedly elevated white blood cell count and C-reactive protein level, but cerebrospinal fluid studies revealed only a slight abnormality. A cervical computed tomography scan and its three-dimensional reconstruction detected a remarkable crown-like calcification surrounding the odontoid process. Cervical magnetic resonance imaging did not demonstrate strong direct compression of the cervical cord; however, the soft tissue surrounding the odontoid process was hyperintense on T2-weighted imaging with fat suppression. Based on the radiological findings, the patient was diagnosed with crowned dens syndrome and was immediately treated with non-steroidal anti-inflammatory drugs. The patient's condition drastically improved within 5 days.

DISCUSSION: It was very interesting that the soft tissue surrounding the odontoid process was hyperintense on magnetic resonance T2-weighted imaging with fat suppression, and the signal change disappeared 2 weeks after the administration of oral non-steroidal anti-inflammatory drugs. We think that magnetic resonance imaging is useful for proving inflammation in patients with crowned dens syndrome.

CONCLUSION: This is the first report making reference to the magnetic resonance imaging findings of crowned dens syndrome.

© 2016 The Author(s). Published by Elsevier Ltd on behalf of IJS Publishing Group Ltd. This is an open access article under the CC BY-NC-ND license (<http://creativecommons.org/licenses/by-nc-nd/4.0/>).

1. Introduction

Crowned dens syndrome (CDS) is a radioclinical entity defined by the association of microcrystalline deposition of calcium pyrophosphate dehydrate (CPPD) in the cruciform ligament around

Abbreviations: CDS, crowned dens syndrome; CPPD, calcium pyrophosphate dehydrate; CRP, creactive protein; ANCA, anti-neutrophil cytoplasmic antibody; MRI, magnetic resonance imaging; Gd, gadolinium; CT, computed tomography; 3D, three-dimensional; NSAIDs, non-steroidal anti-inflammatory drugs; FLAIR, fluid attenuated inversion recovery.

* Corresponding author at: Departments of Neurosurgery, Ehime Prefectural Central Hospital, 83 Kasugamachi, Matsuyama, Ehime Prefecture 790-0024, Japan.

E-mail address: iakihiro3@gmail.com (A. Inoue).

<http://dx.doi.org/10.1016/j.ijscr.2016.11.045>

2210-2612/© 2016 The Author(s). Published by Elsevier Ltd on behalf of IJS Publishing Group Ltd. This is an open access article under the CC BY-NC-ND license (<http://creativecommons.org/licenses/by-nc-nd/4.0/>).

the odontoid process and is demonstrated radiologically as a radiopaque density in a crown or halo-like distribution that appears at the superior and lateral portions of the odontoid process [1–4]. The deposits of CPPD can remain asymptomatic or can be responsible for chronic cervical illness or spinal cord compression and lead to periodic acute cervico-occipital pain with fever, neck stiffness, and biological inflammatory syndrome [1,5]. Here, we report a patient with CDS who dramatically improved in 5 days following treatment with oral nonsteroidal anti-inflammatory medication.

2. Case description

A 61-year-old man with a history of subarachnoid hemorrhage was admitted to our hospital because of a sudden onset of high

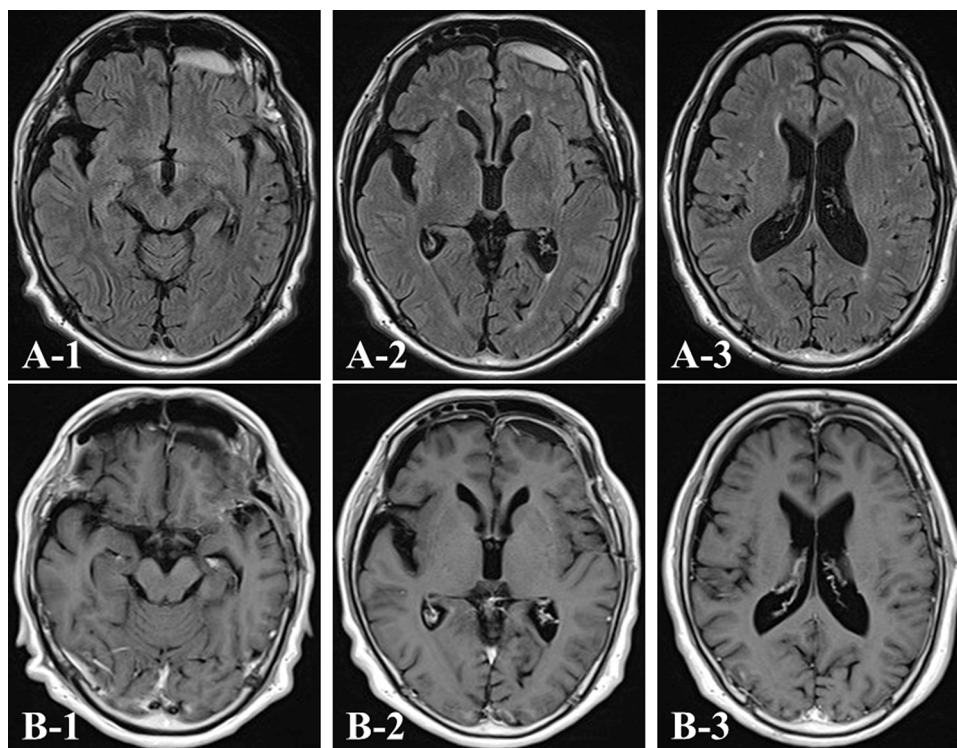


Fig. 1. Magnetic resonance imaging (MRI) findings. Axial fluid-attenuated inversion recovery (FLAIR) (A) and gadolinium (Gd)-enhanced T1-weighted (B) MR images showing slight retention of the subdural hematoma. The hematoma is not enhanced on the administration of Gd.

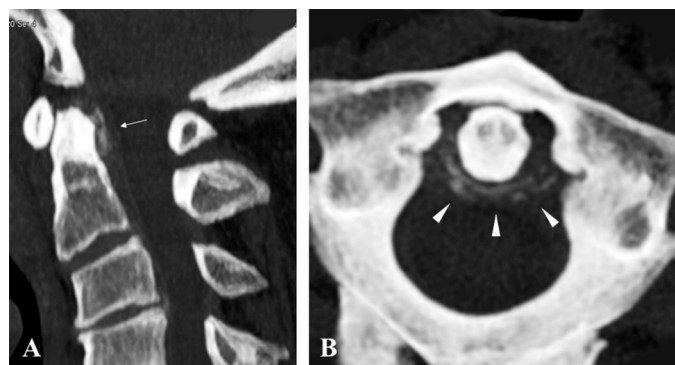


Fig. 2. Cervical computed tomography (CT) scans around the odontoid process. Sagittal reconstruction showing the linear calcification at the posterior side of the dens suggesting calcium pyrophosphate dehydrate (CPPD) (white arrow) (A). The axial image demonstrates the right-dominant, half-ringed form of calcification at the posterolateral side of the dens (white arrowhead) (B).

fever, severe occipital headache, and neck stiffness. At admission, his body temperature was 39.3 °C. He did not show any neurological deficits, including Kernig's sign. Laboratory examination revealed a markedly elevated white blood cell count (12270/ μ L) and C-reactive protein (CRP) level (23.29 mg/dL). His serum uric acid level (5.2 mg/dL) was not elevated. Blood testing for connective tissue disease or vasculitis, including rheumatoid factor, cytoplasmic anti-neutrophil cytoplasmic antibody (ANCA), perinuclear ANCA, and anti-nuclear and anti-cyclic citrullinated peptide antibodies, were all negative. These findings suggested severe infection such as sepsis and/or meningitis. However, blood cultures were negative, and his serum procalcitonin was not elevated. Routine cerebrospinal fluid studies revealed a slight abnormality (white blood cell 1/ μ L and protein 47 mg/dL), whereas cerebrospinal fluid culture and anti-herpes simplex virus and varicella-zoster virus antibodies were all negative. Intracranial magnetic resonance imaging (MRI)

demonstrated almost normal findings, except for slight retention of the subdural hematoma without gadolinium (Gd) enhancement (Fig. 1). However, a plain cervical computed tomography (CT) scan and three-dimensional (3D)-reconstruction imaging detected a remarkable crown-like calcification surrounding the odontoid process (Fig. 2). In addition, cervical MRI did not demonstrate strong direct compression of the cervical cord; however, the soft tissue surrounding the odontoid process was hyperintense on T2-weighted imaging with fat suppression without Gd enhancement (Fig. 3). Based on these radiographic findings, the patient was diagnosed with a severe case of CDS. Although clinically asymptomatic without a previous history of arthritis, the patient's X-ray and CT of the knee joints revealed calcium deposits, suggesting underlying crystalline deposition disease (Fig. 4). Non-steroidal anti-inflammatory drugs (NSAIDs) were immediately started and tapered off within 3 weeks. The patient's symptoms drastically improved within 5 days after initiating NSAID treatment, and the blood results consistent with a serum inflammatory reaction decreased to within normal range 14 days later. The T2 hyperintense lesion on MRI disappeared within 2 weeks (Fig. 5), which helped us exclude infectious meningitis and sepsis from the differential diagnosis. The symptoms improved completely, and the patient was discharged 15 days after admission.

3. Discussion

CDS is a rare disease entity which radiologically shows calcification of the cruciform ligament around the odontoid process and clinically presents with acute cervico-occipital pain, fever, and neck stiffness accompanied by a biological inflammatory reaction [1–5]. The diagnosis of CDS is based on the combination of clinical, biological, radiological, and therapeutic findings: acute periodic attacks of feverish cervico-occipital pain and neck stiffness with biological inflammatory syndrome, radiological identification of a crown-like calcification surrounding the odontoid process due to microcrystal-

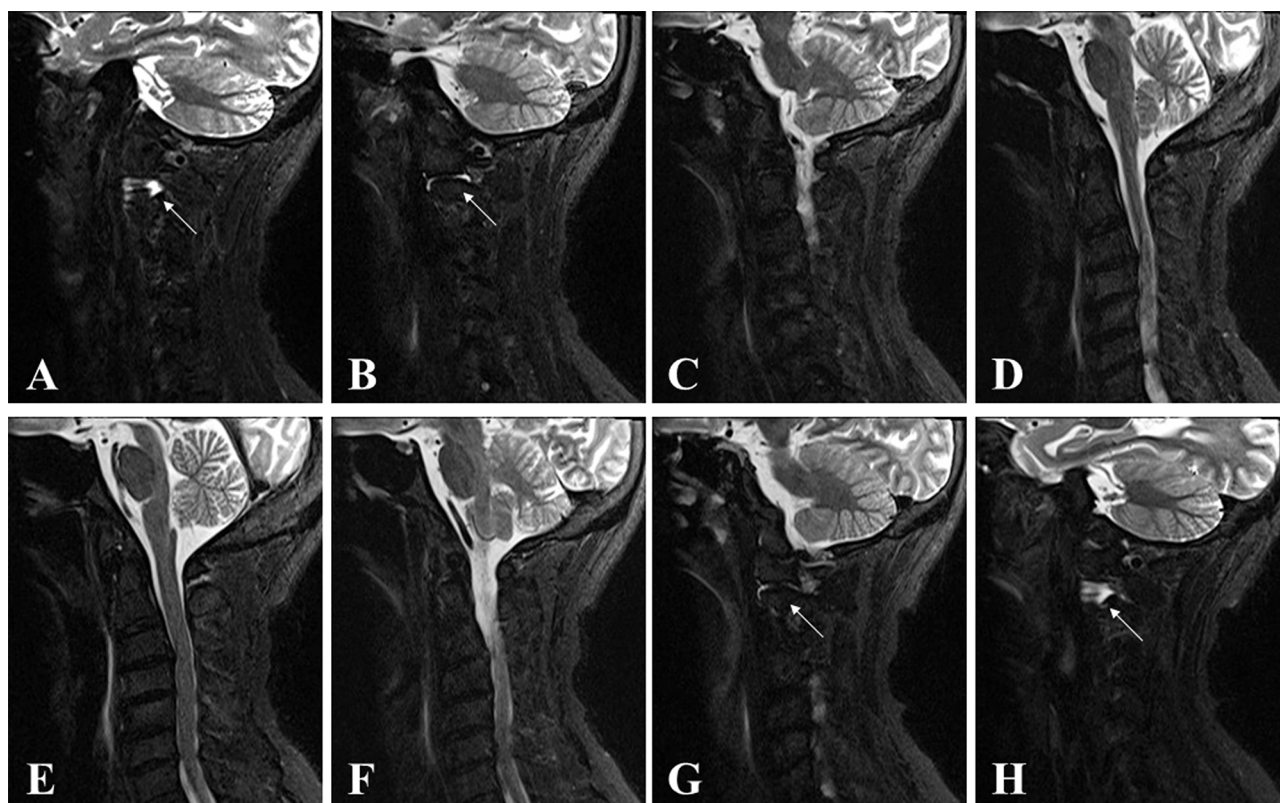


Fig. 3. Sagittal T2-weighted MR imaging with fat suppression reveals a non-invasive, mass-like lesion around the odontoid process, but the soft tissue surrounding the dense is hyperintense (white arrow) (A–H; from the right side to the left side).

talline deposits, and a drastic improvement in symptoms under treatment with NSAIDs or colchicine [1,5–7]. However, the triad of fever, headache, and neck stiffness is also suggestive of infectious meningitis and can easily warrant a lumbar puncture [5,6,8]. Therefore, CDS should be considered in the differential diagnosis of fever, headache, and neck pain of unknown origin [3,5,6].; Cervical CT scanning focusing on C1 and C2 is the gold standard of CDS diagnosis [1–8]. The typical tiny, half-ringed, crown-like form of calcification behind the dens is described as the most important and definitive feature of CDS. In the present case, cervical CT scan, especially the 3D-CT, was much more useful in assessing calcifications of the dens area than the MRI scan. Additionally, CT scan findings can lead to the definitive diagnosis of CDS, even in cases in which it is difficult to identify CPPD microcrystalline deposits directly. However, in our case, it is interesting that the soft tissue surrounding the odontoid process was hyperintense on MRI T2-weighted imaging with fat suppression. It is reasonable to assume that the increase in crystalline deposits around the odontoid process evokes the inflammatory reaction and causes symptoms such as neck pain, restriction of neck movement, and fever. In fact, the signal change in the acute stage on MRI disappeared 2 weeks after the administration of oral NSAIDs. Therefore, we think that MRI is useful for proving inflammation in patients with CDS, and this is the first report making reference to the MRI findings of CDS.; In general, CDS has a good prognosis, and symptoms usually subside within a few weeks [1,4,5,9–13]. The appropriate treatment for CDS remains controversial; however, NSAIDs are conventionally used [1,4,5,9–13]. In most of the previously reported cases, oral NSAIDs therapy alone was sufficient to improve the symptoms within several days. In some refractory cases, corticosteroids were additionally administered [6]. Because CDS mainly occurs in elderly people, steroid therapy should be prescribed with careful consideration to avoid fatal side effects. Additionally, the long-term

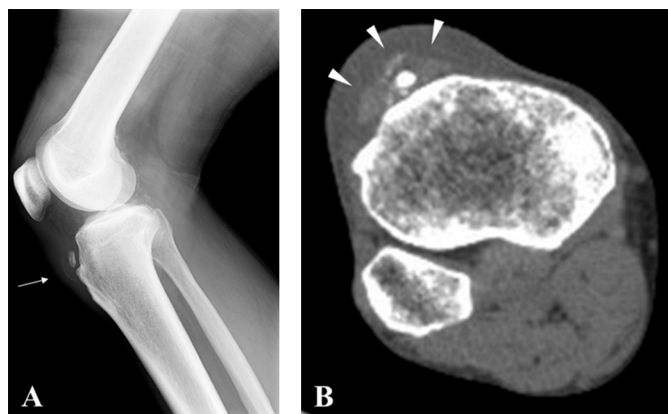


Fig. 4. X-ray and CT scan showing that calcium deposits are apparent in the right knee (white arrow and white arrowhead).

use of anti-inflammatory drugs is unnecessary for the treatment of CDS [13,14]. Clinicians should therefore be cautious about the choice of specific NSAID and length of anti-inflammatory therapy for the treatment of CDS. In our case, the patient's fever promptly resolved 1 day after oral NSAID administration, and his neck pain and restriction of cervical movement disappeared 5 days later. In addition, the patient's serum CRP normalized within 3 weeks after treatment.; Rapid diagnosis of CDS, based mainly on cervical CT and MRI scans, can prevent misdiagnosis, invasive and unnecessary investigations (lumbar puncture, biopsy), inappropriate treatment (steroids, antibiotics, antiviral drugs), and prolonged hospitalization. Nevertheless, at present, CDS is a rare neurological condition, and there have only been a few case reports. Therefore, further research and an accumulation of case reports are necessary to obtain a better understanding of the pathological conditions associated with CDS.

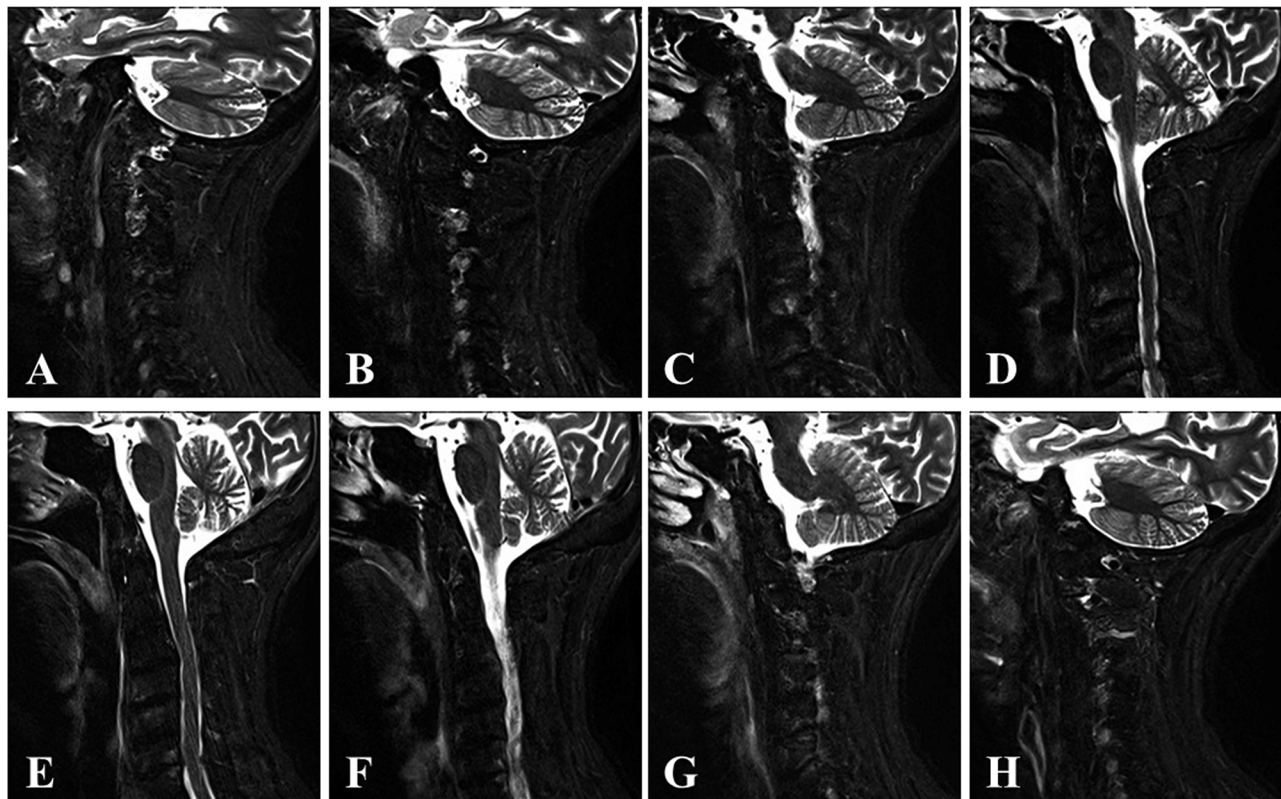


Fig. 5. Sagittal T2-weighted MR imaging with fat suppression demonstrates that the T2-hyperintense lesion on preoperative MRI has disappeared 2 weeks after oral administration of non-steroidal anti-inflammatory drugs (A-H; from the right side to the left side).

4. Conclusion

We describe a patient with CDS that manifested with clinical (acute headache, fever, and neck stiffness) and radiographic (calcium deposits in the cruciform ligament) features. This rare condition should be considered in the differential diagnosis of fever, headache, and cervical pain of unknown origin. The rapid diagnosis of CDS, based mainly on a cervical CT and MRI scans, can prevent invasive, expensive, and useless investigations and can help avoid a long course of potentially dangerous and inadequate treatments, notably with cortisone, and prolonged hospitalization of elderly patients.

Funding

This research received no specific grant from any funding agency in the public, commercial, or not-for-profit sectors.

Ethical approval

This research received no specific grant from any funding agency in the public, commercial or not-for-profit sectors.

Conflicts of interest

None of the authors have any commercial or financial involvement in connection with this study that represents or appears to represent any conflicts of interest.

Consent

Written informed consent was obtained from the patient's family for publication of this case report and any accompanying images.

A copy of the written consent is available for review by Editor-in-Chief of this journal on request.

Author contribution;

All authors in this manuscript contributed to the interpretation of data, and drafting and writing of this manuscript. AI is first and corresponding author of this paper. He and KK conceived and designed the study and drafted the manuscript. AI, SN, SI, SO, HT, KK, KO, HI, SO and SO were engaged in patient's care in his hospital including surgery under the supervision of KK and BO. All the authors read and approved the final manuscript.

Guarantor

Kanehisa Kohno, MD, PhD.

Acknowledgements

The authors would like to express their gratitude to Masato Imai, Isao Kawamata, Atsushi Kyoshita, Yukio Kobayashi, Hirotsugu Mineyuki, Takeshi Okada, Masahiro Sone, Shinichi Utsunomiya, Shotaro Kubo, and Yosuke Orikiawa of the Department of Neurology, Ehime Prefectural Central Hospital, Japan for their helpful information regarding radiological image acquisition. In particular, Masato Imai, Yukio Kobayashi, Hirotsugu Mineyuki, and Masahiro Sone contributed extensively to acquisition of the MRI results.

References

- [1] A. Constantin, G. Bouteiller, Acute neck pain and fever as the first manifestation of chondrocalcinosis with calcification of the transverse ligament of the atlas. Five case-reports with a literature review, *Rev. Rhum. Engl. Ed.* 65 (1998) 583–585.

- [2] J.P. Bouvet, J.M. le Parc, B. Michalski, C. Benlahrache, L. Auquier, Acute neck pain due to calcifications surrounding the odontoid process: the crowned dens syndrome, *Arthritis Rheum.* 28 (1985) 1417–1420.
- [3] T. Takahashi, Y. Minakata, M. Tamura, T. Takasu, M. Murakami, A rare case of crowned dens syndrome mimicking aseptic meningitis, *Case Rep. Neurol.* 5 (2013) 40–46.
- [4] G.S. Lee, R.S. Kim, H.K. Park, J.C. Chang, Crowned dens syndrome: a case report and review of the literature, *Kor. J. Spine.* 11 (2014) 15–17.
- [5] A. Aouba, V. Vuillemin-Bodaghi, C. Mutschler, M. De Bandt, Crowned dens syndrome misdiagnosed as polymyalgia rheumatica, giant cell arteritis, meningitis or spondylitis: an analysis of eight cases, *Rheumatology (Oxford)*, 43 (2004) 1508–1512.
- [6] Y. Sato, T. Yasuda, S. Konno, A. Kuwayama, K. Komatsu, Pseudogout showing meningoencephalitic symptoms: crowned dens syndrome, *Intern. Med.* 43 (2004) 865–868.
- [7] D.W. Wu, A.J. Reginato, M. Torriani, D.R. Robinson, A.M. Reginato, The crowned dens syndrome as a cause of neck pain: report of two new cases and review of the literature, *Arthritis Rheum.* 53 (2005) 133–137.
- [8] K. Ishikawa, T. Furuya, K. Noda, Y. Okuma, Crowned dens syndrome mimicking meningitis, *Intern. Med.* 49 (2010) 2023.
- [9] S. Goto, J. Umehara, T. Aizawa, S. Kokubun, Crowned dens syndrome, *J. Bone Joint Surg. Am.* 89 (2007) 2732–2736.
- [10] A. Taniguchi, K. Ogita, T. Murata, S. Kuzuhara, H. Tomimoto, Painful neck on rotation: diagnostic significance for crowned dens syndrome, *J. Neurol.* 257 (2010) 132–135.
- [11] F. Salaffi, M. Carotti, G. Guglielmi, G. Passarini, W. Grassi, The crowned dens syndrome as a cause of neck pain: clinical and computed tomography study in patients with calcium pyrophosphate dihydrate deposition disease, *Clin. Exp. Rheumatol.* 26 (2008) 1040–1046.
- [12] A. Koyfman, D. Yaffe, Crowned dens syndrome. A case report, *Neuroradiol. J.* 27 (2014) 495–497.
- [13] R. Koda, Y. Tsuchida, K. Yoshizawa, K. Suzuki, A. Kasai, T. Takeda, et al., Crowned dens syndrome as an initial manifestation of crystalline deposition disease, *Intern. Med.* 54 (2015) 2405–2408.
- [14] M. Matsumura, S. Hara, Crowned dens syndrome, *N. Engl. J. Med.* 367 (2012) 34.

Open Access

This article is published Open Access at sciedirect.com. It is distributed under the [IJSCR Supplemental terms and conditions](#), which permits unrestricted non commercial use, distribution, and reproduction in any medium, provided the original authors and source are credited.