



## Case report

## Rare cause of thyroid enlargement: Localized AA amyloid goiter – A case report

Tejas Chincholi<sup>a</sup>, Talha Ahmed<sup>a,\*</sup>, Yogesh Kumar<sup>a</sup>, Amanda Christina Pinto<sup>b</sup>, Esha Mallik<sup>a</sup>, George M Varghese<sup>c</sup><sup>a</sup> Department of General Surgery, Kasturba Medical College, Mangalore, Manipal Academy of Higher Education, India<sup>b</sup> Department of Pathology, Kasturba Medical College, Mangalore, Manipal Academy of Higher Education, India<sup>c</sup> Kasturba Medical College, Manipal, Manipal Academy of Higher Education, India

## ARTICLE INFO

## Keywords:

Amyloid goiter  
Amyloidosis  
AA amyloidosis  
Thyroid enlargement  
Case report

## ABSTRACT

**Introduction:** Amyloidosis is extracellular deposition of fibrillary amyloid proteins in various organs. Amyloid infiltration in thyroid is common; however, the occurrence of clinically enlarged thyroid, subsequently leading to goiter, is a rare phenomenon.**Case presentation:** 36 years old female presented to our OPD with multinodular goiter. She subsequently underwent total thyroidectomy. Thyroidectomy specimen revealed amyloid deposition with characteristic congophilia and birefringence. Further evaluation revealed it to be AA amyloidosis. There were no features of systemic amyloidosis.**Discussion:** Amyloidosis is classified on the type of amyloid protein. Treatment of individual types of amyloidosis is diverse, and hence identification of the protein subtype is paramount.**Conclusion:** AA amyloidosis localized primarily to thyroid is infrequent, as it usually occurs with chronic inflammatory conditions or infections. Currently, there are no guidelines for the treatment of localized AA amyloid goiter. We have evidence demonstrating the successful treatment of such a condition with no recurrence noted.

## 1. Introduction

Virchow coined the term “amyloid” in 1854 to represent deposits which have sugars that cause starch-like staining [1,2]. Amyloidosis is the extracellular deposition of fibrillary amyloid proteins in various organs; most commonly the kidney, resulting in possible structural and functional loss of the organ. It is caused due to abnormal protein folding [2].

Deposition of amyloid can be systemic, involving multiple organs or localized to a single organ.

Infiltration of amyloid into the thyroid gland was first described by Rockitansky in 1855. However, these infiltrations seldom cause a visibly enlarged swelling of the gland. Deposition of amyloid protein in thyroid gland which leads to it becoming palpable clinically is defined as amyloid goiter. This uncommon entity was described in 1858 by Beckman, and the term “amyloid goiter” was coined by Eiselberg in 1904 [1]. We present such a case of clinically enlarged localized amyloid goiter with no features of systemic amyloidosis or kidney involvement, which was

found to be of the AA protein type on immunohistochemistry. This case report has been reported in line with the SCARE Criteria [3].

## 2. Case description

A 36-year-old female patient presented to our hospital outpatient department in Mangalore, in the state of Karnataka in South India, with complaints of swelling in the anterior aspect of the neck for 3 years, predominantly in the midline. It was gradually increasing in size and was slowly progressive. It was associated with increasing dysphagia for solids for 1 year, however she had no difficulty in swallowing liquids or any odynophagia. She had no complaints of dyspnea or hoarseness of voice. There were no complaints of any visual disturbances. No features of hypothyroidism or hyperthyroidism. She had no appetite changes or recent significant weight abnormalities. She had no constitutional symptoms, comorbidities, menstrual abnormalities, respiratory, musculoskeletal or abdominal complaints. She had a past history of displaced sternal body fracture due to trauma 20 years back for which

\* Corresponding author at: Department of General Surgery, Kasturba Medical College, Mangalore, Manipal Academy of Higher Education, India.

E-mail address: [talhaahmed1994@gmail.com](mailto:talhaahmed1994@gmail.com) (T. Ahmed).<https://doi.org/10.1016/j.ijscr.2022.106876>

Received 18 December 2021; Received in revised form 16 February 2022; Accepted 22 February 2022

Available online 25 February 2022

2210-2612/© 2022 The Authors. Published by Elsevier Ltd on behalf of IJS Publishing Group Ltd. This is an open access article under the CC BY-NC-ND license

<http://creativecommons.org/licenses/by-nc-nd/4.0/>.

she had undergone open reduction and sternal plating fixation. She had no family history of thyroid conditions. The patient gave no history of chronic medications including thyroid drugs, allergies or any habits.

Examination confirmed the swelling to be a thyroid swelling, with enlargement of both lobes and isthmus, measuring 8 cm × 4 cm in its greatest dimensions in the anterior aspect of the neck, extending laterally up to sternocleidomastoid muscle on either side, deep to the deep cervical fascia, which moves up on deglutition. On palpation, there was no local rise of temperature or tenderness. A smooth swelling with well-defined margins located in the muscular triangle of the neck was noted. It was firm in consistency, with lower border well made out on deglutition (Fig. 1). There was no movement of the gland on protrusion of tongue. Lahey's test revealed no nodules in the postero-lateral aspect of the gland. There was no cervical lymphadenopathy, no dilated veins over the neck and upper chest and carotid pulsations were not displaced and felt equally bilaterally. Trachea was central with Trail sign negative. On percussion over the manubrium, resonant note was elicited confirming the absence of retrosternal extension. On auscultation no bruit was heard over the superior pole of thyroid. There were no signs of toxicity. Respiratory system examination revealed no abnormalities with no clinical evidence of effusion, consolidation, fibrosis or cavitation. Abdominal examination was within normal limits with no evidence of organomegaly or free fluid. Salivary gland examination was within normal limits. Musculoskeletal examination including skull and spine assessment revealed no joint abnormalities, deformities, restricted or painful range of movements.

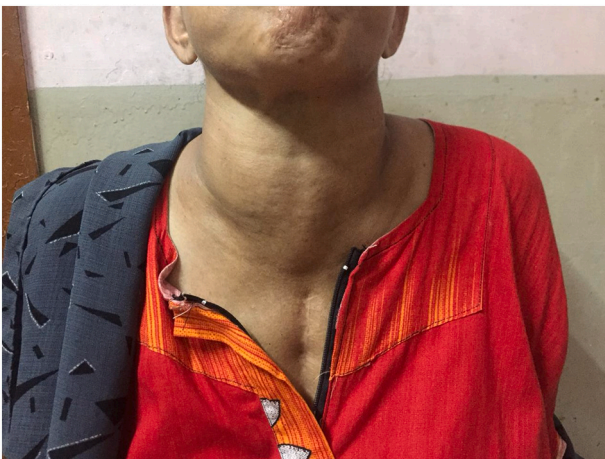### 2.1. Diagnostic assessment

Routine investigations including complete blood count, liver, renal and thyroid profile were within normal limits. Urine microscopy was normal with no evidence of proteinuria. CXR was within normal limits.

On ultrasound, the thyroid gland appeared bulky with altered echotexture showing multiple hypoechoic nodules in both lobes with the largest measuring 9.3 mm × 9 mm in the lower pole of the left lobe, with the likely diagnosis suggested as multinodular goiter with a TIRADS score of TR2.

FNAC showed follicular cells in clusters and few macrophages in hemorrhagic background and occasional stromal fragments, reported as Bethesda 2 category.

An upper GI endoscopy was done which was normal, ruling out other causes for dysphagia with no evidence of vocal cord palsy.



**Fig. 1.** Thyroid swelling involving both the lobes and the isthmus as seen on inspection.

### 2.2. Therapeutic intervention

In view of the large size of the goiter causing dysphagia and cosmetic problems, the patient was advised total thyroidectomy. After thorough pre-operative optimization and preparation, the patient was taken up for a total thyroidectomy under general anesthesia. The complications of surgery including reactionary hemorrhage, recurrent laryngeal nerve and external laryngeal nerve injury, hypoparathyroidism, hypothyroidism, hypocalcemia, post-operative respiratory distress, wound infection was conveyed. The procedure was carried out in our tertiary care center by senior consultants who had a collective surgical experience of 20 years. A Kocher's collar neck incision was placed and sub platysmal flap was raised along with lateral retraction of the strap muscle to approach the gland. Intra operatively, enlarged, bulky and firm thyroid gland was noticed, with multiple nodules on its surface with largest nodule measuring 10 mm × 9 mm in the left lobe of the thyroid, with no evidence of nerve infiltration or enlarged significant lymph nodes. The procedure was carried out by securing the superior and inferior thyroid pedicles and safeguarding the recurrent and external laryngeal nerves on either side. One of the parathyroid glands with its vascularity was preserved on the left side along the inferior pole prior to removal of the thyroid gland. There was no evidence of tracheomalacia and both the lobes with the isthmus were resected.

A closed suction drain was placed and the wound was closed in layers. Specimen was sent for histopathological examination.

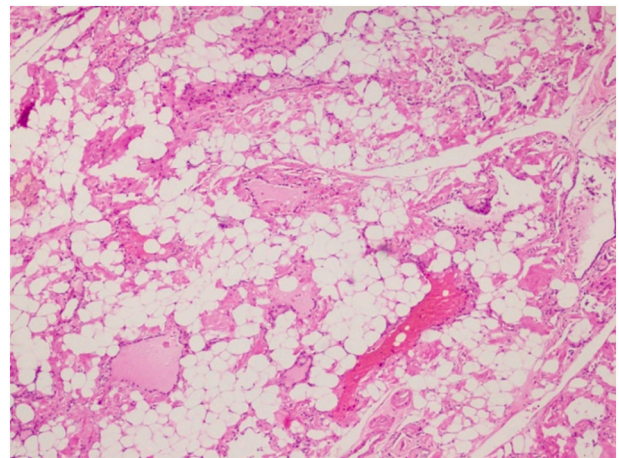
### 2.3. Pathology

On gross appearance, the specimen measuring 6 × 3 × 2 cm appeared bosselated. On cut section, it was homogenous, pale brown in colour.

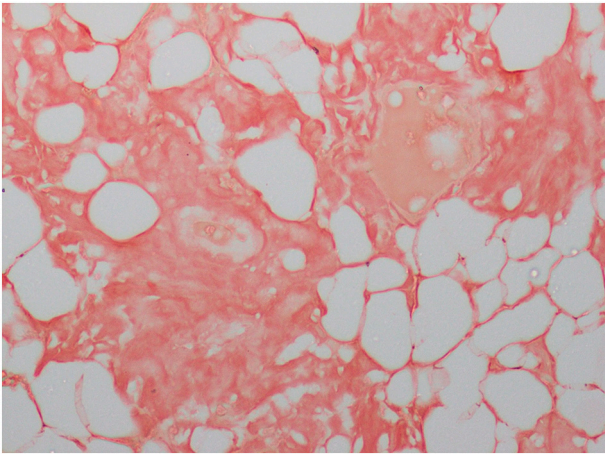
Histopathology revealed thyroid tissue with few colloid filled follicles lined by cuboidal epithelium separated by large areas of fibrosis and extensive adipocytic metaplasia. Few hemosiderin laden macrophages and atrophic follicles were noted. The stroma showed amorphous eosinophilic material in the interfollicular and perfollicular areas on 40× hematoxylin and eosin stain (Fig. 2).

Presence of amyloid deposition around thyroid follicles showing orange red stain and apple green birefringence using congo red stain highlighted by light microscopy (Fig. 3) and using polarizing light (Fig. 4), respectively.

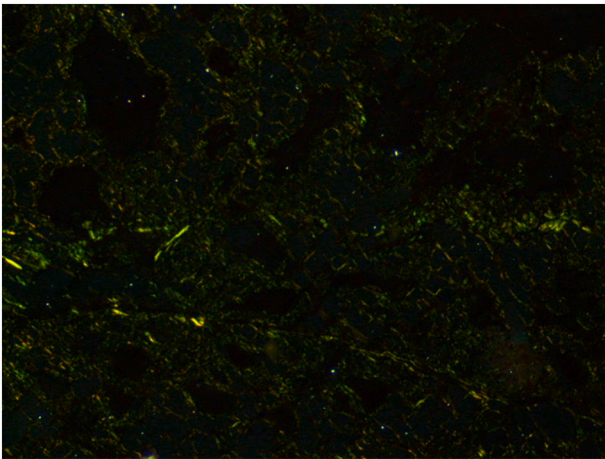
To identify the type of amyloid protein, the thyroid tissue was subjected to immunohistochemistry which revealed immunoreactivity for serum associated amyloid (SAA) protein which is a precursor and



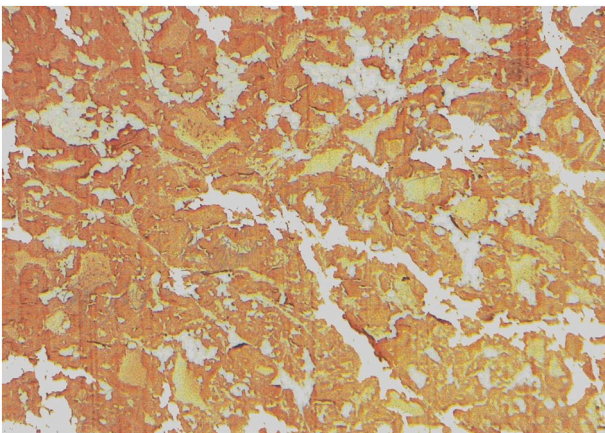
**Fig. 2.** 40× hematoxylin and eosin stain showing amorphous eosinophilic material in the interfollicular and perfollicular areas suggestive of amyloid deposition.



**Fig. 3.** 200× amyloid deposition around thyroid follicles showing orange red stain with congo red on light microscopy.



**Fig. 4.** Apple green birefringence using congo red stain highlighted by polarizing light.



**Fig. 5.** Immunohistochemistry showing the brownish SAA deposits due to strong positivity in the amyloid deposits when stained with anti-SAA antibody.

marker for AA amyloid. SAA deposits appeared brown due to strong fixation of anti-SAA antibody by amyloid deposits (Fig. 5).

#### 2.4. Follow-up and outcomes

Post operatively, the drain output was regularly monitored and removed on POD 3. There was no evidence of post-operative nerve injury, respiratory distress or clinical features of hypocalcemia. The operated site healed well with no flap necrosis.

In view of the post-operative histopathological report, she was investigated for other features of systemic amyloidosis. Inflammatory markers like CRP and plasma SAA assay were within normal limits ruling out an underlying chronic inflammatory process. HRCT chest and Mantoux test was done to rule out bronchiectasis and tuberculosis, respectively. Serum electrophoresis, peripheral smear examination and x-rays taken as part of skeletal survey were able to rule out multiple myeloma, inflammatory bony disorders like arthritis and other plasma cell dyscrasias. Ultrasound abdomen showed normal kidneys, liver, spleen and bowel with no evidence of renal failure or proteinuria on lab studies. The patient was subjected for a colonoscopy and biopsy of the large bowel, which revealed no evidence of amyloid deposition, also subsequently ruling out any inflammatory bowel disease.

A right renal biopsy was done which showed no indication of amyloid deposition. Abdominal fat pad biopsy also revealed no evidence of amyloid infiltration.

She was put on replacement dose of T. thyroxine 50 µg once a day for life.

The patient is on yearly follow up and shows no recurrence or any other features of systemic amyloidosis thus far.

### 3. Discussion

Currently, as per the International Society of Amyloidosis (ISA), amyloidosis is classified based on protein type identification, using immunohistochemistry, Western blotting, mass spectrometry and amino acid sequencing [4]. In humans, thirty-six proteins have been recognized based on the precursor protein [5].

The management of amyloidosis depends on the type of protein subunit of amyloid, as the treatment options vary for each individual type, with implementation of specific therapy for conditions which are potentially treatable.

Amyloidosis AL (localized or systemic), previously called as primary amyloidosis, is characterized by deposition of insoluble, amorphous, proteinaceous, eosinophilic light chain immunoglobulin amyloid. Systemic AL amyloidosis is usually associated with plasma cell dyscrasias, with the rest associated with multiple myeloma.

Systemic AA amyloidosis, previously called as secondary amyloidosis, is characterized by the infiltration of apo serum amyloid A which is released by the liver as an acute phase reactant. It is a rare type of amyloid deposition which usually coexists with chronic inflammatory diseases like familial Mediterranean fever, inflammatory bowel disease, bronchiectasis, rheumatoid arthritis, ankylosing spondylitis, chronic osteomyelitis, Sjogren's syndrome, tuberculosis [2,6]. These patients usually present with long standing and severe manifestations of such chronic inflammatory conditions ultimately leading to end organ failure.

AL amyloidosis was considered the leading cause of systemic disease [7] until 2009 following which ATTR was recognized as the most frequent type. This was due to the introduction of bone scan scintigraphy which made the identification of this underdiagnosed and neglected type of protein [8,9].

Chronic sustained inflammatory conditions are a usual association with AA amyloidosis, however that does not necessarily mean that they would occur simultaneously. Kidneys, liver, spleen, abdominal fat pad and the gastrointestinal tract are the common sites usually involved with AA amyloidosis [10]. There are widespread proteinaceous deposits seen

in various organs which indicate the systemic nature of the disease. However, our patient had no such associated history or involvement of these organs. Inflammatory markers like C reactive protein and plasma serum associated amyloid (SAA) were within normal limits. Thyroid tissue subjected to immunohistochemistry revealed strong positivity for SAA protein which is a marker for AA amyloidosis, thus this is a case of localized AA amyloidosis.

Amyloid infiltration in thyroid is common, however the occurrence of a clinically enlarged thyroid gland, subsequently leading to goiter, is a rare phenomenon and the presence of clinical symptoms is usually life threatening. These patients usually present with complications of compression in view of the gland attaining a large size [11]. They are often misdiagnosed with thyroiditis or thyroid malignancy such as medullary carcinoma of thyroid [12], hence mandating a thorough pre-operative work up with FNAC and radiological investigations. While most patients present in euthyroid state such as our patient, cases with hypothyroid and hyperthyroid states have also been reported.

A high index of clinical suspicion is required to rule out other common differential diagnosis for the causes of goiter and systemic AA amyloidosis which can cause proteinaceous deposits in the thyroid, and such patients have to be subjected to the 'quadruple' assessment which includes 1) clinical examination and elaborate history, 2) investigations including thyroid function tests, 3) ultrasonography of thyroid and 4) US-guided FNAC based on TI-RADS features [13]. A vast majority of the patients undergo surgery which is usually for reasons of cosmesis, compressive symptoms, toxicity, and suspicion for malignancy. However, there are no definitive guidelines for indications of surgery in patients who present with uncomplicated amyloid goiter.

Furthermore, post-operative histopathological examination of the thyroid specimen is needed to reach a diagnosis of amyloid goiter, as preoperative cytology is not very conclusive, thereby hindering the treating clinician from looking for other features of systemic amyloidosis. Moreover, the subtyping of the type of amyloid is paramount to characterizing the type of amyloidosis and for planning specific therapy, as AA amyloidosis carries a better prognosis with targeted biological treatment of the underlying cause of systemic disease. This is particularly important in the overall prognosis of the patient as a diagnosis of amyloidosis with a concurrent goiter will carry a poor prognosis in view of the systemic nature of the disease requiring lifelong immunosuppressive therapy with eventually, these patients succumbing to renal failure, cardiac failure and arrhythmias.

A preoperative diagnosis is hence essential where surgery is the first modality of treatment after weighing the potential risks with benefits in patients who present with features of systemic amyloidosis.

Therefore, patients who present with localized AA amyloid goiter, even though rare, seem to carry a better prognosis when compared to those with concurrent systemic amyloidosis.

Currently, there are no guidelines for the treatment of localized AA amyloid goiter. Surgical treatment is usually offered for patients in view of compressive symptoms such as dyspnea, hoarseness or dysphagia [11], the preferred treatment being Total thyroidectomy. However, due to the invasive nature of the procedure, and the morbidity associated, many authors argue about the need for surgery in such patients, citing evidence of decrease in the size of the goiter with improvement in thyroid function and good response with dexamethasone, targeting the systemic nature of disease in AA subtype of amyloidosis [14,15]. However, our patient had presented with compressive features and was offered total thyroidectomy.

Hence, these patients have to be kept on strict follow up to look for evidence of systemic AA amyloidosis with renal biopsy, urinary proteins, serum electrophoresis and features of another organ involvement. Our patient was thoroughly evaluated for the same and found to have no further evidence of recurrence on repeated yearly examinations.

Keeping the above in consideration we have proof showing the successful therapy of such a condition with no recurrence noted.

## Patient perspective

I am extremely delighted about how my surgeons have handled my case, with the utmost care and concern. I hope that doctors all over would benefit from my presentation and I hope to make a small contribution to the medical fraternity via my case.

## Informed consent

Written informed consent was obtained from the patient for publication of this case report and accompanying images. A copy of the written consent is available for review by the Editor-in-Chief of this journal on request.

## Provenance and peer review

Not commissioned, externally peer-reviewed.

## Ethical approval

Ethical approval was received from the Institutional Ethics Committee of Kasturba Medical College, Mangalore (Reg. no. ECR/541/Inst/KKA/2014/RR-17) bearing number IEC KMC MLR 10-19/506.

## Funding

None.

## Guarantor

Dr. Talha Ahmed is the guarantor.

## Research registration number

N/A.

## CRediT authorship contribution statement

Dr. Talha Ahmed – Study concept, Study design, Data collection, writing of original draft, Surgical Operation, Dr. Tejas Chincholi – Reviewing and Editing the article, Surgical operation, Dr. Yogesh Kumar – Reviewing and final approval of the version to be submitted, Surgical Operation, Dr. Amanda Pinto – Study concept, Data collect and analysis, Dr. Esha Mallik – Study concept, writing and editing of article, Dr. George M Varghese - Study concept, writing and editing of article.

## Declaration of competing interest

None.

## References

- [1] L. Yildiz, M. Kefeli, B. Kose, S. Baris, Amyloid goiter: two cases and a review of the literature, *Ann.Saudi Med.* 29 (2) (2009 Mar) 138–141.
- [2] A.G. Villanueva, M.J. Villanueva, M.G. Villanueva, R.R. Blanco, M.V. Guirao, J. C. Montero, R.B. Pérez, I.M. Montes, Surgical considerations about amyloid goiter, *Endocrinol.Nutr.(Engl.Ed.)* 60 (5) (2013 May 1) 254–259.
- [3] R.A. Agha, T. Franchi, C. Sohrai, G. Mathew, A. Kerwan, A. Thoma, A.J. Beamish, A. Noureldin, A. Rao, B. Vasudevan, B. Challacombe, The SCARE 2020 guideline: updating consensus Surgical CAse REport (SCARE) guidelines, *Int. J. Surg.* 1 (84) (2020 Dec) 226–230.
- [4] J.D. Gillmore, M.S. Maurer, R.H. Falk, G. Merlini, T. Damy, A. Dispenzieri, A. D. Wechalekar, J.L. Berk, C.C. Quarta, M. Grogan, H.J. Lachmann, Nonbiopsy diagnosis of cardiac transthyretin amyloidosis, *Circulation* 133 (24) (2016 Jun 14) 2404–2412.
- [5] J.D. Sipe, M.D. Benson, J.N. Buxbaum, S.I. Ikeda, G. Merlini, M.J. Saraiva, P. Westermark, Amyloid fibril proteins and amyloidosis: chemical identification and clinical classification International Society of Amyloidosis 2016 nomenclature guidelines, *Amyloid* 23 (4) (2016 Oct 1) 209–213.

- [6] E.K. Lagha, I. M'sakni, F. Bougrine, B. Laabidi, D.B. Ghachem, A. Bouziani, Amyloid goiter: first manifestation of systemic amyloidosis, *Eur. Ann. Otorhinolaryngol. Head Neck Dis.* 127 (3) (2010 Jun 1) 108–110.
- [7] S. Ravichandran, H.J. Lachmann, A.D. Wechalekar, Epidemiologic and survival trends in amyloidosis, 1987–2019, *N. Engl. J. Med.* 382 (16) (2020 Apr 16) 1567–1568.
- [8] C. Rapezzi, P. Guidalotti, F. Salvi, L. Riva, E. Perugini, Usefulness of 99mTc-DPD scintigraphy in cardiac amyloidosis, *J. Am. Coll. Cardiol.* 51 (15) (2008 Apr 15) 1509–1510.
- [9] M. Zampieri, G. Nardi, G. Del Monaco, M. Allinovi, M. Gabriele, C. Zocchi, S. Casagrande, C. Fumagalli, C. Di Mario, I. Olivotto, F. Perfetto, Changes in the perceived epidemiology of amyloidosis: 20 year-experience from a tertiary referral centre in Tuscany, *Int. J. Cardiol.* 15 (335) (2021 Jul) 123–127.
- [10] G.H. Sack, Serum amyloid A—a review, *Mol. Med.* 24 (1) (2018 Dec) 1–27.
- [11] C. Aparna, I.V. Renuka, G.S. Bala, M. Vijayasri, Primary amyloid goitre, *Int.J. Otolaryngol.HeadNeck Surg.* 9 (2014 Jan) 2014.
- [12] F. Villa, G. Dionigi, M.L. Tanda, F. Rovera, L. Boni, Amyloid goiter, *Int. J. Surg.* 1 (6) (2008 Jan) S16–S18.
- [13] A.M. Abdelkader, A.M. Zidan, M.T. Younis, S.K. Dawa, Preoperative evaluation of thyroid nodules: a prospective study comparing the accuracy of ultrasound (TI-RADS) versus the FNAC Bethesda system in relation to the final postoperative histo-pathological diagnosis, *Ann.Pathol.Lab.Med.* 5 (10) (2018 Oct).
- [14] M.A. Siddiqui, M. Gertz, D. Dean, Amyloid goiter as a manifestation of primary systemic amyloidosis, *Thyroid* 17 (1) (2007 Jan 1) 77–80.
- [15] H.J. Lachmann, P.N. Hawkins, Systemic amyloidosis, *Curr. Opin. Pharmacol.* 6 (2) (2006 Apr 1) 214–220.