

Severe urticarial rash as the initial symptom of COVID-19 infection

Sandeep Pagali,¹ Riddhi S Parikh²

¹Department of Medicine, Division of Hospital Internal Medicine & Division of Geriatric Medicine and Gerontology, Mayo Clinic, Rochester, Minnesota, USA

²Department of Medicine, Division of Hospital Internal Medicine, Mayo Clinic, Rochester, Minnesota, USA

Correspondence to

Dr Sandeep Pagali;
pagali.sandeep@mayo.edu

Accepted 16 March 2021

SUMMARY

A 54-year-old woman presented with pruritic rash and hives of 3 days' duration followed by shortness of breath for 1 day. SARS-CoV-2 PCR test for COVID-19 was positive. Cutaneous manifestations of COVID-19 include acral lesions, urticarial rash, erythematous maculopapular rash, vascular rashes and vesicular rash. The cutaneous manifestations are mostly described as self-limiting. Urticarial rashes are not reported as the initial presentation symptom of COVID-19 infection but mostly noted to occur at the same time or after the onset of non-cutaneous symptoms. Management of cutaneous manifestations of COVID-19 affecting quality of life has not been well studied. Antihistamine therapy is the primary recommended therapy. Role of antiviral therapy for severe cases of rash needs to be further assessed.

BACKGROUND

Patients with COVID-19 infection are noted with varied clinical presentations involving different organ systems. Cutaneous symptoms, though were not initially noted as a common association with COVID-19, are now increasingly recognised in a substantial proportion of patients. A recent report on cutaneous manifestations in COVID-19 noted the incidence ranging from 0.2% to 29%.¹ Cutaneous manifestations are noted to be acral areas of erythema, vesicular eruptions, urticarial lesions, maculopapular eruptions and necrosis.² Studies have noted that urticarial rash most commonly occurs at the same time or after the onset of non-cutaneous symptoms, with the mean age noted as 38.3 years and a female predominance.³ We report the presentation of our patient who had an urticarial rash prior to any non-cutaneous COVID-19 symptoms for 3 days while she was at home and our management strategies that helped quick resolution of symptoms.

CASE PRESENTATION

A 54-year-old woman presented with shortness of breath for 1-day duration along with generalised weakness and diffuse rash associated with itching and burning sensation that progressively got worse for 3 days prior to presentation to emergency department. She denied any fever, chills, cough, nausea, loose stools, abdominal pain, joint pains or sore throat. She had no known exposure to COVID-19 positive people. On arrival in the emergency department, a COVID-19 test was performed given hypoxia (oxygen saturation 84% on room air) with new requirement of 2L of nasal cannula oxygen, empirically given present pandemic

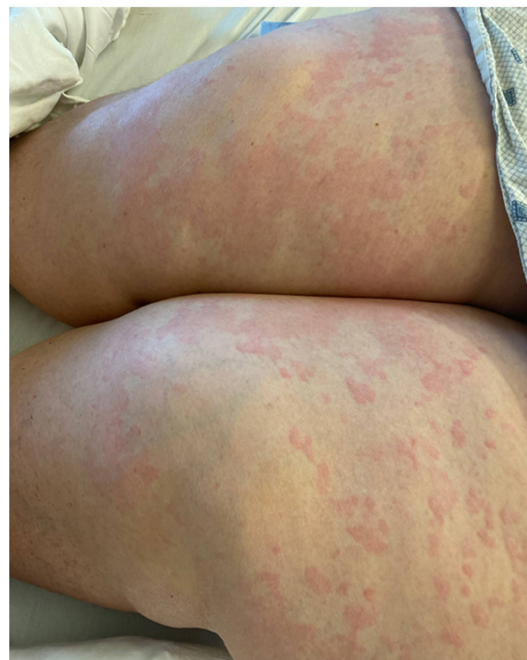

Figure 1 Diffuse urticarial rash on bilateral lower extremities.

circumstances. COVID-19 test returned positive. Her medical history was significant for medically complicated obesity, obstructive sleep apnoea, atrial fibrillation for which she was on anticoagulation

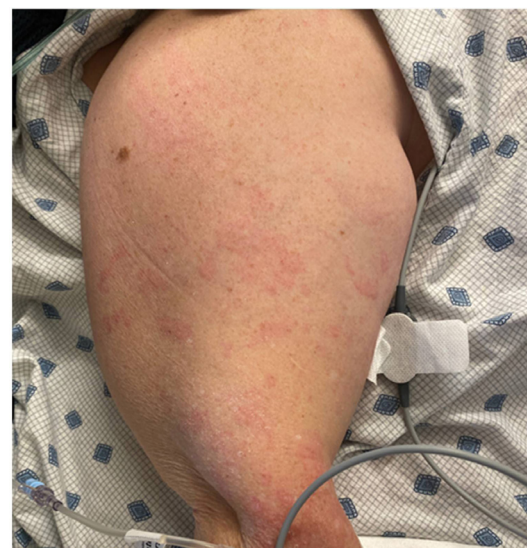


Figure 2 Diffuse urticarial rash noted on right upper extremity.



© BMJ Publishing Group Limited 2021. No commercial re-use. See rights and permissions. Published by BMJ.

To cite: Pagali S, Parikh RS. *BMJ Case Rep* 2021;**14**:e241793. doi:10.1136/bcr-2021-241793

with warfarin, pulmonary hypertension and chronic kidney disease stage IV.

A widespread rash that was erythematous, raised and pruritic and consistent with urticarial rash was noted on her bilateral upper extremities and lower extremities (figure 1 and figure 2). The urticarial rash was also present on the trunk but did not involve the palmar and plantar surfaces or any mucosal surfaces. She had significant discomfort associated with itchiness and burning sensation. No vesicular rash or acral lesions were noted. She was given two doses of diphenhydramine 25 mg orally 8 hours apart that did not relieve her rash or itching sensation.

INVESTIGATIONS

SARS-CoV-2 COVID-19 PCR testing was positive. White cell count 8.4×10^9 cells/L (normal range: $3.4\text{--}9.6 \times 10^9$ cells/L) with a normal differential count including no lymphopaenia or eosinophilia. C reactive protein elevated at 60.9 mg/L (normal range: <8.0 mg/L). D-dimer elevated at 725 ng/mL (normal: <500 ng/mL). Chest X-ray revealed left basal atelectasis and no other major abnormality otherwise. Serum creatinine is 2.6 mg/dL, with her baseline creatinine ranging from 2.3 to 2.6 mg/dL (normal range: 0.59–1.04 mg/dL).

DIFFERENTIAL DIAGNOSIS

The differential for this urticarial rash on presentation included a hypersensitivity reaction to environmental toxin, drug reaction, a viral infectious process and autoimmune vasculitis. A detailed history obtained did not reveal any concern for new medication use or change in environmental exposure including linen/soap. Given the progressive worsening over 3 days' duration, it was likely felt that this was not an anaphylactic reaction. Given the urticarial appearance of the rash, autoimmune vasculitis was felt to be less likely. Consideration of skin biopsy was done, but given a diagnosis of COVID-19, it was felt that a trial

of observation with antihistamines could be done initially for the first 24–48 hours, and if no improvement, then to pursue skin biopsy.

TREATMENT

Treatment for the rash included oral antihistamines with loratadine 10 mg daily along with topical triamcinolone 0.1% cream, given the intensity of pruritus. Antiviral therapy with remdesivir was initiated at 200 mg intravenous on day 1, followed by 100 mg intravenous once daily for four more days given her hypoxia. Within 48 hours of initiation of this treatment, she had complete resolution of the rash.

OUTCOME AND FOLLOW-UP

Patient had complete resolution of rash, rash-associated itching and burning sensation, and hypoxia within 48 hours of initiation of therapy. She discharged out of the hospital safely on day 5 of hospitalisation when she completed her antiviral therapy.

DISCUSSION

A varied incidence of cutaneous rashes has been described in different studies. A recent review of the cutaneous manifestations in patients with COVID-19 highlighted that urticarial rash is more common at or after the onset of other non-cutaneous COVID-19 symptoms but very rare before the onset of non-cutaneous symptoms. While highlighting the importance of keeping the differential of urticarial rash as a presenting symptom of COVID-19 illness, very minimal literature is available about the management guidelines/recommendations in these circumstances.

Most of the rashes reported in literature are noted to be self-limiting. When the rash becomes significant and is affecting the quality of life (secondary to pruritus), consideration could be given to antihistamine therapy and topical steroid creams. Given the time course in improvement following the intravenous antiviral medication (remdesivir), we hypothesise that antiviral therapy had a significant impact in her symptom relief, though no studies have suggested any role of antiviral therapy as a management recommendation for urticarial rash. Further studies need to be considered to identify the best management approaches and the role and benefit of intravenous antiviral medications, if significant debilitating rash would be the only presenting symptom.

Contributors SP cared for the patient directly through her hospitalisation and drafted the manuscript. RSP was part of the care team along with SP, who was involved in regular discussion about the patient care and further edited the manuscript.

Funding The authors have not declared a specific grant for this research from any funding agency in the public, commercial or not-for-profit sectors.

Competing interests None declared.

Patient consent for publication Obtained.

Provenance and peer review Not commissioned; externally peer reviewed.

This article is made freely available for use in accordance with BMJ's website terms and conditions for the duration of the covid-19 pandemic or until otherwise determined by BMJ. You may use, download and print the article for any lawful, non-commercial purpose (including text and data mining) provided that all copyright notices and trade marks are retained.

REFERENCES

- Gül Ülker. COVID-19 and dermatology. *Turk J Med Sci* 2020;50:1751–9.
- Galván Casas C, Català A, Carretero Hernández G, *et al.* Classification of the cutaneous manifestations of COVID-19: a rapid prospective nationwide consensus study in Spain with 375 cases. *Br J Dermatol* 2020;183:71–7.

Patient's perspective

I was miserable due to the itching and rash for nearly three days at home and could not take it anymore. I did not think I had COVID infection. When I tested positive for COVID in the ED, I was very scared as I did not know that rashes would occur with COVID infection. I did not hear much about it on TV or in the news. After applying creams and IV medications my medical team recommended, I had much improvement overall to the point that within 2 days, my rash completely disappeared. I am very thankful to the timely treatment that helped me in symptom resolution.

Learning points

- ▶ Cutaneous manifestations are prevalent and on occasions can be the first presenting symptom for COVID-19 infection.
- ▶ Acral lesions and vesicular rashes are noted to be the most common rash types prior to non-cutaneous COVID-19 symptoms. Rarely, urticarial rash can also present prior to other non-cutaneous COVID-19 symptoms.
- ▶ For debilitating symptomatology associated with the rash, consideration should be given to oral antihistamines and topical steroid creams for symptom control.
- ▶ Consideration and role of antiviral therapy with remdesivir for debilitating rash should be further studied and analysed.

3 Daneshgaran G, Dubin DP, Gould DJ. Cutaneous manifestations of COVID-19: an evidence-based review. *Am J Clin Dermatol* 2020;21:627–39.

Copyright 2021 BMJ Publishing Group. All rights reserved. For permission to reuse any of this content visit <https://www.bmj.com/company/products-services/rights-and-licensing/permissions/>
BMJ Case Report Fellows may re-use this article for personal use and teaching without any further permission.

Become a Fellow of BMJ Case Reports today and you can:

- ▶ Submit as many cases as you like
- ▶ Enjoy fast sympathetic peer review and rapid publication of accepted articles
- ▶ Access all the published articles
- ▶ Re-use any of the published material for personal use and teaching without further permission

Customer Service

If you have any further queries about your subscription, please contact our customer services team on +44 (0) 207111 1105 or via email at support@bmj.com.

Visit casereports.bmj.com for more articles like this and to become a Fellow