

Lateral Trochlear Inclination Angle

Measurement via a 2-Image Technique to Reliably Characterize and Quantify Trochlear Dysplasia

Sheeba M. Joseph,* MD, Chris Cheng,[†] MD, Matthew J. Solomito,[‡] PhD, and J. Lee Pace,^{§||¶} MD
Investigation performed at Elite Sports Medicine at Connecticut Children's Medical Center, Farmington, Connecticut, USA

Background: Trochlear dysplasia (TD) is a risk factor for patellar instability (PI). The Dejour classification categorizes TD but has suboptimal reliability. Lateral trochlear inclination (LTI) is a quantitative measurement of trochlear dysplasia on a single axial magnetic resonance imaging (MRI) scan.

Hypothesis: A modified LTI measurement technique using 2 different axial MRI scans that reference the most proximal aspect of the trochlear cartilage on 1 image and the fully formed posterior condyles on the second image would be as reliable as and significantly different from the single-image measurement technique for LTI. Further, the 2-image LTI would adequately represent overall proximal trochlear morphologic characteristics.

Study Design: Cohort study (diagnosis); Level of evidence, 2.

Methods: Patients aged 9 to 18 years treated for PI between 2014 and 2017 were identified. The Dejour classification was radiographically determined. Single-image LTI was measured on a single axial MRI scan at the most proximal aspect of visible trochlear cartilage. A 2-image LTI was measured from 2 separate MRI scans: 1 at the most proximal aspect of trochlear cartilage and the second at the fully formed posterior condyles. This 2-image LTI was repeated at 3 subsequent levels (the first measurement is referred to as LTI-1; repeated measurements are LTI-2, LTI-3, and LTI-4, moving distally). In total, 65 patients met the inclusion criteria, and 30 were randomly selected for reliability analysis.

Results: Inter- and intrarater reliability trended toward more variability for single-image LTI (intraclass correlation coefficient [ICC], 0.86 and 0.88, respectively) than for 2-image LTI (ICC, 0.97 and 0.96, respectively). The Dejour classification had lower intra- and interrater reliability (ICC, 0.31 and 0.73, respectively). Average single-image LTI ($9.2^\circ \pm 12.6^\circ$) was greater than average 2-image LTI-1 ($4.2^\circ \pm 11.9^\circ$) ($P = .0125$). Single-image LTI classified 60% of patients with PI as having TD, whereas the 2-image LTI classified 71% as having TD. The 2-image LTI was able to capture 91% of overall proximal trochlear morphologic characteristics.

Conclusion: LTI has higher reliability when performed using a 2-image measurement technique compared with single-image LTI and Dejour classification. The strong correlation between 2-image LTI and average LTI shows that 91% of TD is represented on the most proximal axial image. Because the single-image measurement appears to underestimate dysplasia, previously described thresholds should be reexamined using this 2-image technique to appropriately characterize TD.

Keywords: patella; trochlear dysplasia; patellar instability; anatomy; imaging and radiology

Patellar instability (PI) accounts for approximately 2% to 3% of all knee injuries in children and adolescents.^{1,2} The cause of PI is multifaceted. Demographic risk factors include age, sex, and activity level, and anatomic risk factors include limb coronal malalignment, muscular imbalance, trochlear dysplasia, patella alta, patellar tilt, ligamentous laxity, and femoral and/or tibial rotational malalignment.[#]

The Orthopaedic Journal of Sports Medicine, 8(10), 2325967120958415
 DOI: 10.1177/2325967120958415
 © The Author(s) 2020

[#]References 2, 3, 7, 11, 14-16, 19, 20, 22, 24, 26.

Trochlear dysplasia (TD) has been classically described and classified via radiographs based on the Dejour classification.^{9,10,28,33} However, suboptimal to poor inter- and intrarater reliabilities are associated with this classification system on radiographs or magnetic resonance imaging (MRI).^{4,27} Further, the Dejour classification offers a qualitative analysis of dysplasia and thus is suboptimal for determining surgical indications or identifying those at risk of recurrent instability. Lateral trochlear inclination (LTI) is a described measure of trochlear morphologic characteristics.⁵ The LTI is measured on axial MRI sequences at the level of the most proximal extent of the trochlear cartilaginous surface. Per the original authors, it is the angle

This open-access article is published and distributed under the Creative Commons Attribution - NonCommercial - No Derivatives License (<https://creativecommons.org/licenses/by-nc-nd/4.0/>), which permits the noncommercial use, distribution, and reproduction of the article in any medium, provided the original author and source are credited. You may not alter, transform, or build upon this article without the permission of the Author(s). For article reuse guidelines, please visit SAGE's website at <http://www.sagepub.com/journals-permissions>.

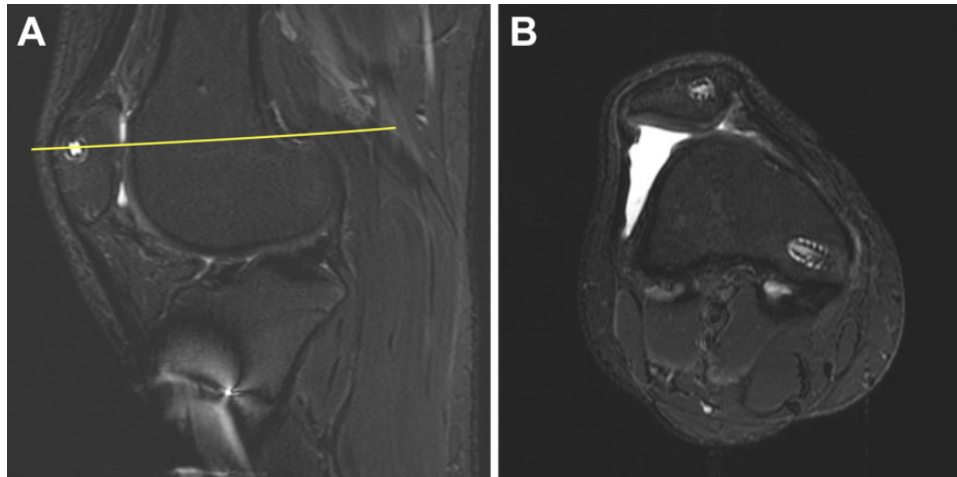


Figure 1. (A) Sagittal MRI scan with a reference line (yellow) through an area of proximal trochlear cartilage. This area of cartilage was proximal to the femoral condyles. (B) Corresponding axial MRI scan showing that this area of proximal trochlear cartilage on the distal femur had no formed posterior femoral condyles. MRI, magnetic resonance imaging.

formed between a line parallel to the lateral trochlear facet and a line parallel to the posterior femoral condyles on the same image.⁵ The posterior condyles are an internal reference of knee motion, and referencing them for the LTI measurement makes sense. Using the posterior condyles for reference is in line with accepted measurement techniques for femoral anteversion and the tibial tubercle–trochlear groove distance.^{4,24}

The LTI has been used previously to study trochlear dysplasia in the setting of PI.^{6,27,31} Because the LTI is an MRI measurement, it better characterizes the proximal trochlea, which is an area difficult to appreciate on conventional radiographs as is attempted using the Dejour radiographic classification.^{5,23,25,32} Also, LTI provides a quantitative description of dysplasia. Carrillon et al⁵ reported that an LTI of $<11^\circ$ is associated with a 95% specificity of having PI secondary to TD.

In the original description of the MRI-based LTI, Carrillon et al⁵ described a “reference image” in which the axial MRI scan showing the most proximal aspect of trochlear cartilage was identified. Those investigators determined the LTI by measuring the angle subtended between the subchondral bone of the lateral trochlea and what they called the posterior femoral condyles on that same image. However, Yamada et al³⁴ showed using 3D modeling that the dysplastic trochlea often has a cartilaginous extent that is well proximal to

the posterior femoral condyles (Figure 1). Thus, at the level of the most proximal trochlear cartilage, one is usually visualizing posterior femoral metaphysis as opposed to fully formed posterior femoral condyles. As such, the LTI taken on a single reference image may not accurately capture the rotational profile of the distal femur and may lead to incorrect measurements of lateral trochlear inclination. This observation creates an opportunity to more accurately measure trochlear dysplasia.

The purpose of this study was 3-fold. First, we sought to evaluate the reliability of a new 2 image LTI measurement technique compared with the historical single-image LTI as well as the standard Dejour classification on lateral radiographs. We hypothesized that measuring LTI using a single-image technique would have greater variability than that of a 2-image measurement that allowed for ideal reference to the orientation of the femoral posterior condylar axis. We further hypothesized that either MRI measurement would be more reliable than would the Dejour classification on lateral radiographs. Second, we hypothesized that by referencing the posterior condyles, this new 2-image measurement for LTI would be significantly different from the historical single-image LTI and thus represent a new standard for measuring LTI. Third, we hypothesized that the LTI measured (via the 2-image technique) at the most proximal level of the trochlea would adequately represent overall proximal

*Address correspondence to J. Lee Pace, MD, 399 Farmington Avenue, #300, Farmington, CT 06032, USA (email: leepace@gmail.com).

†Department of Orthopedic Surgery, Michigan State University, East Lansing, Michigan, USA.

‡Case Western Reserve Hospitals, Cleveland, Ohio, USA.

§Hartford Hospital Bone and Joint Institute, Hartford, Connecticut, USA.

¶Elite Sports Medicine at Connecticut Children’s Medical Center, Farmington, Connecticut, USA.

‡Department of Orthopedic Surgery, University of Connecticut School of Medicine, Farmington, Connecticut, USA.

Final revision submitted March 13, 2020; accepted March 19, 2020.

One or more of the authors has declared the following potential conflict of interest or source of funding: S.M.J. has received educational support from Arthrex and Smith & Nephew, consulting fees from KCI USA, and hospitality payments from Stryker. J.L.P. has received educational support from Arthrex; speaking fees from Arthrex; and consulting fees from Arthrex, Ceterix, and Smith & Nephew. AOSSM has not conducted an independent investigation on the OPD and disclaims any liability or responsibility relating thereto.

Ethical approval for this study was obtained from Connecticut Children’s Medical Center Institutional Review Board (No. 18-015).

trochlear morphologic characteristics and thus be an appropriate singular measurement to quantify trochlear dysplasia.

METHODS

With institutional review board approval, patients aged 9 to 18 years between the years of 2014 and 2017 who were treated for PI at our tertiary referral center were identified from a query using International Classification of Diseases, Ninth Revision and Tenth Revision, codes to identify patients with PI in the electronic medical record system. Inclusion and exclusion criteria were applied to obtain the study group. Inclusion criteria were as follows: diagnosis of PI that was supported from clinical notes to include a history and physical examination and presence of radiographs and MRI examinations of the symptomatic knee. Patients were excluded if they were missing one or both types of imaging studies, had previous osseous and/or chondral knee surgery, had noted coronal or rotational alignment that contributed to the instability and/or required operative treatment (eg, distal femoral osteotomy, guided growth, derotational femoral osteotomy), had an associated neuromuscular or genetic condition, or were ultimately treated for a different diagnosis based on chart review. The participants' age range was chosen for 2 reasons. First, our clinic focuses on pediatric sports medicine, and 75% of patients with first-time PI are younger than 25 years^{29,30}; therefore, this was very representative of the general patient population with PI. Second, by having a pediatric and adolescent cohort, we sought to avoid images with generalized degenerative changes in the patellofemoral joint. Previous studies have shown that the dysplastic patellofemoral joint can be reliably evaluated in the skeletally immature patient population, particularly in terms of evaluating chondral surfaces.³² A total of 65 patients met the inclusion criteria for this study. The average age of included patients was 14.2 years (range, 9.2-18.1 years), and the sex distribution was nearly even (54% male, 46% female).

We performed 2 LTI MRI measurements: a single-image LTI and a 2-image LTI, both of which are described below. Best lateral knee radiographs were used to classify knees according to the Dejour classification. An appropriate lateral knee radiograph was defined as a lateral view that had appropriate overlap of the posterior femoral condyles. This was determined based on attending surgeon-level review of specific imaging for "less than perfect" lateral radiographs on which dysplasia could still be evaluated.²¹ If the radiograph was deemed unreadable, the scan and the patient were excluded. The 3 components of the Dejour classification included the crossing sign, the supratrochlear spur sign, and the double-contour sign. An isolated crossing sign was consistent with Dejour grade A. The presence of a crossing sign and a supratrochlear spur was classified as grade B. The presence of a crossing sign and a double-contour sign was graded as C, and radiographs with all 3 signs were graded as D.

A protocol of the measurement techniques with embedded sample images and sample measurements was created

by the principal investigator (J.L.P.) and distributed for immediate reference while making measurements. The specifics of each measurement technique are detailed below. The MRI examinations of the final cohort of patients were reviewed and measured by 2 independent observers (S.M.J., C.C.) using eUnity (Version 6.9.9.1-297; Waterloo, Ontario, Canada). The proton density fat saturation sequences were selected for making measurements, and when they were not available, the T2-weighted fat saturation sequence was selected. All MRI scans were conducted on either 1.5-T or 3-T magnets with 3-mm slice intervals.

A subgroup of 30 patients was randomly selected for measurement reliability analysis, and 3 independent observers (J.L.P., S.M.J., C.C.) made the measurements of interest. For intrarater reliability analysis, these measurements were repeated on the same subgroup by all 3 observers after a minimum of 2 weeks had elapsed to reduce likelihood of recall. Observers were blinded to each other's measurements and to their previous measurements at the time of repeat measurement.

Single-Image LTI Measurement

Single-image LTI was measured as described by Carrillon et al.⁵ By cross-referencing the sagittal image, the first cranio-caudal axial image with cartilaginous trochlea was selected. A sagittal MRI scan was used to verify that the most proximal aspect of trochlear cartilage was identified. This image tended to be just slightly lateral of the intercondylar notch. The single-image LTI angle was measured as the angle formed between a line subtended from the cartilaginous surface of the lateral trochlea and a line tangential to the posterior aspect of the femur at the same axial level (ie, on the same single image) (Figure 2). If the apex of the angle was toward the medial aspect of the distal femur, it was assigned a positive value. If the apex of the angle was toward the lateral aspect of the distal femur, it was assigned a negative value.

2-Image LTI Measurement

To measure the 2-image LTI, we chose the same axial image as the single-image LTI. An angle was created between the same line previously subtended on the lateral trochlear cartilaginous surface and a horizontal line. Next, the MRI scan was scrolled distally until an image where the posterior condyles were best defined was selected. On this image, the angle was measured between a line parallel to the posterior aspect of the condyles and a horizontal line. Similar to the single-image LTI technique, sagittal MRI scans were used as a cross-reference to determine the optimum slice for measurement. The conventions of negative and positive values were the same as those for the single-image LTI. The 2-image LTI was calculated by subtracting the angle of the posterior femoral condyle orientation from the lateral trochlear angle (Figure 3). For patients with a convex or spurred trochlea, we used a best-fit line between the lateral aspect of the trochlea and the apex of the trochlea's convexity or spur (Figure 4).

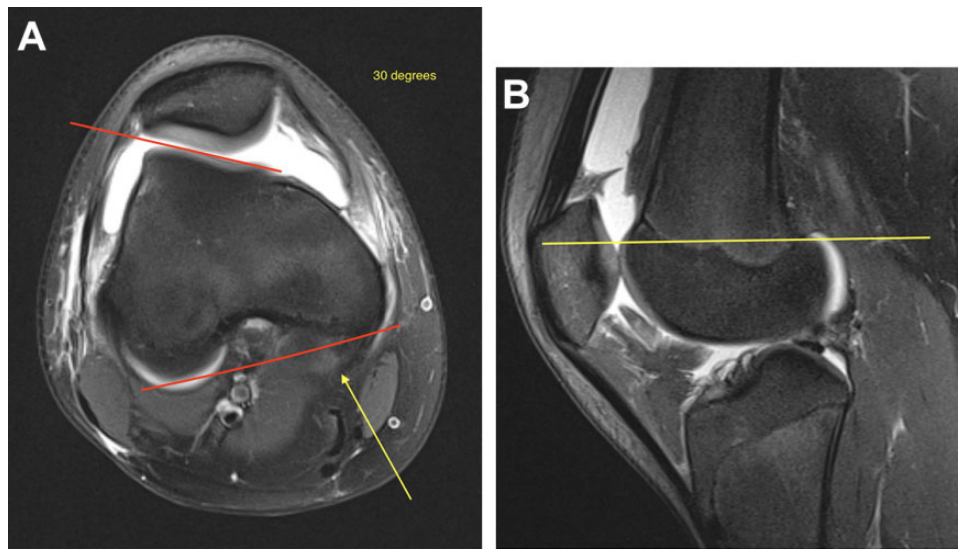


Figure 2. (A) Measurement technique for single-image lateral trochlear inclination (LTI). The angle, represented by the red lines, was determined between the most proximal aspect of trochlear cartilage and the posterior femur on an axial MRI image. Here, the LTI measured 30° . Because the apex of the angle was medial, the angle was assigned a positive value. On this image, the medial aspect of the posterior femur was somewhat ambiguous, and it was not clear where the measurement of the posterior femur should be. An arrow (yellow) highlights what appeared to be the developing posterior medial femoral condyle. This ambiguity could be due to a slight deviation from perfect positioning in the gantry or from small differences in the position of the most superior aspects of the posterior femoral condyles. Regardless, this image highlighted a not uncommon shortcoming of a single-image LTI measurement. (B) Cross-referenced sagittal magnetic resonance imaging scan of the cut with the most proximal extent of trochlear cartilage represented by the yellow line. At this level, the posterior aspect of the femur represented the junction between metaphysis and epiphysis as opposed to fully formed posterior femoral condyles.

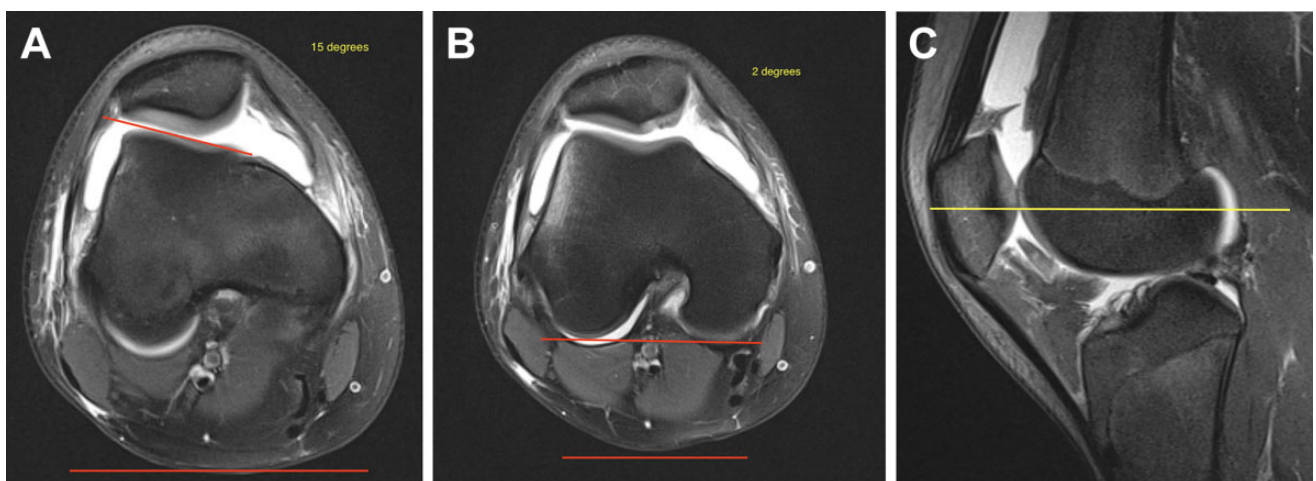


Figure 3. Measurement technique for 2-image lateral trochlear inclination (LTI). (A) An angular measurement was taken on an axial MRI image between the most proximal aspect of the lateral trochlear cartilaginous surface and a horizontal reference line represented by the red lines. This was the same image used for the single-image LTI. This angle measured 15° . This angle's apex was also medial, so it was assigned a positive value as well. (B) An angle was measured between the posterior condyles and a horizontal line represented by the red lines. This angle measured 2° . Because the apex of the angle was medial, it was assigned a positive value. The 2-image LTI was determined by subtracting the angle of the posterior femoral condyles relative to the horizontal from the angle of the proximal lateral trochlea relative to the horizontal. In this example, the LTI calculation was $15^\circ - 2^\circ = 13^\circ$. This was 17° different from the single-image LTI. (C) Cross-referenced sagittal magnetic resonance imaging (MRI) scan showing the level at which the measurement of the posterior condyle orientation was taken represented by the yellow line. The sagittal MRI scan showing the most proximal extent of trochlear cartilage was used. This tended to be just lateral to the intercondylar notch. In this example, the posterior condyles were measured 6 mm (2 MRI cuts) distal from the proximal trochlear measurement.

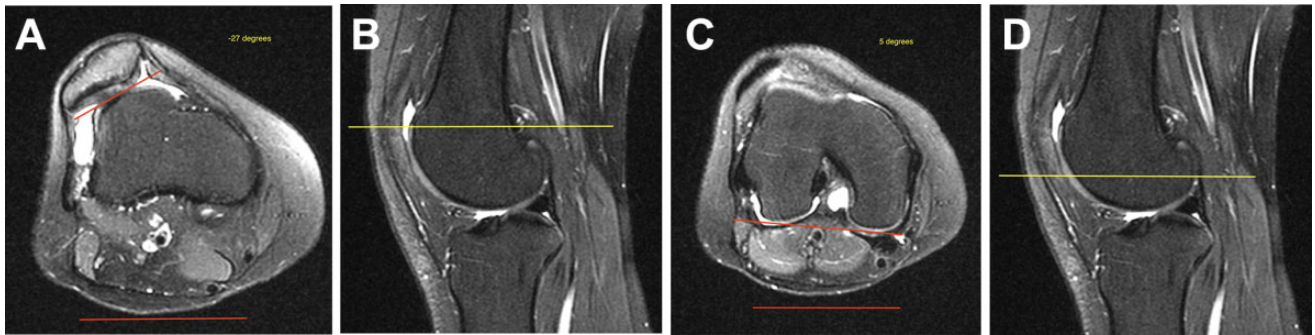


Figure 4. Measuring lateral trochlear inclination (LTI) in a patient with a convex/spurred trochlea. (A) A best-fit line between the cartilaginous surface of the lateral trochlea and the apex of the convexity was used to form an angle between the proximal trochlea and a horizontal line represented by the red lines. In this example, the single-image LTI measured -27° and was assigned a negative value because the apex of the angle was toward the lateral aspect of the distal femur. (B) Cross-referenced sagittal magnetic resonance imaging (MRI) scan confirming that the axial image in part A was the most proximal aspect of the trochlea represented by the yellow line. One can note the marked proximal extent of trochlear cartilage relative to the femoral condyles in this patient with a highly dysplastic trochlea. (C) Axial MRI scan taken where the posterior femoral condyles were clearly visible. An angle was measured between the condyles and a horizontal line represented by the red lines. In this example, the angle of the condyles had an apex toward the medial aspect of the femur and was thus assigned a positive value of 5° . Thus, the 2-image LTI measurement for this patient was $-27^\circ - 5^\circ = -32^\circ$. Had the femoral condyles been externally rotated 5° (the apex of the angle pointed toward the lateral femur), the angle would have been assigned a negative value, and the 2-image LTI calculation would have been $-27^\circ - (-5^\circ) = -22^\circ$. (D) Cross-referenced sagittal MRI scan showing the level, relative to the proximal trochlea, at which the angle of the posterior femoral condyles was measured represented by the yellow line. In this example, it was 15 mm (5 MRI cuts) distal to the proximal trochlea.

To determine how representative the LTI measurement was of overall proximal trochlear dysplasia, the 2-image LTI measurement was repeated for 3 more consecutive distal axial images of the proximal trochlea. The same posterior condylar angle was used to determine the 2-image LTI for these measurements. For this purpose, the measurements were labeled LTI-1 (which was the same as the standard LTI at the most proximal level of trochlear cartilage), LTI-2, LTI-3, and LTI-4 from proximal to distal. Finally, an average LTI (LTI-avg) was calculated from the 4 LTI measurement values (LTI-avg = $[LTI-1 + LTI-2 + LTI-3 + LTI-4]/4$).

The sequence and axial image number selected for every measurement were recorded. This information was not shared between observers, and it was not referenced during the repeat measurements.

Statistical Analysis

Inter- and intrarater reliabilities were calculated using intraclass correlation coefficients (ICC) for continuous variables and kappa statistic for categorical variables. An ICC value less than 0.5 was considered poor reliability, between 0.5 and 0.75 was considered moderate reliability, between 0.75 and 0.9 was considered good reliability, and above 0.9 was considered excellent or near perfect. Paired-samples *t* tests were used to determine whether there was a significant difference in the values for the single-image LTI compared with the 2-image LTI. Additionally, a linear regression was used to determine whether there were significant associations between LTI-1 and LTI-2, LTI-3, LTI-4, and LTI-avg.

RESULTS

The interrater reliability for the Dejour classification was poor (ICC = 0.33; 95% CI, -0.06 to 0.60); among the 4 components of the classification, the crossing sign had the highest interrater reliability at 0.74 (95% CI, 0.52 to 0.87) (Figure 5). The presence of a supratrochlear spur or a double contour was less reliably graded between observers, with ICCs of 0.52 (95% CI, 0.20 to 0.74) and 0.22 (95% CI, -0.15 to 0.54), respectively.

The interrater reliability for the single-image LTI (ICC = 0.86; 95% CI, 0.72 to 0.93) showed good agreement but trended toward more variability than did the interrater reliability for the 2-image LTI, which had near-perfect agreement (ICC = 0.971; 95% CI, 0.88 to 0.97). Intrarater reliability for single-image LTI showed near-perfect agreement but trended toward more variability than the intrarater reliability for the 2-image LTI, which also had near-perfect agreement. On average, there were 4.5 ± 1.7 MRI slices between the slice with visible and measurable trochlear cartilage and fully formed posterior femoral condyles. Given that each MRI slice thickness was 3 mm, this translated into between 13 and 14 mm of distance between the proximal trochlea and posterior femoral condyles. In the entire cohort of 65 patients, the average single-image LTI (9.2° SD $\pm 12.6^\circ$) was $7.0^\circ \pm 3.4^\circ$ greater (less dysplastic) than the average 2-image LTI (4.2° SD $\pm 11.9^\circ$) ($P = .0125$). Results are summarized in Table 1.

Inter- and intrarater reliabilities were moderate to near perfect for 2-image LTI-2, LTI-3, LTI-4, and LTI-avg (Table 2). Linear regression analysis demonstrated statistically significant positive correlations between LTI-1 and

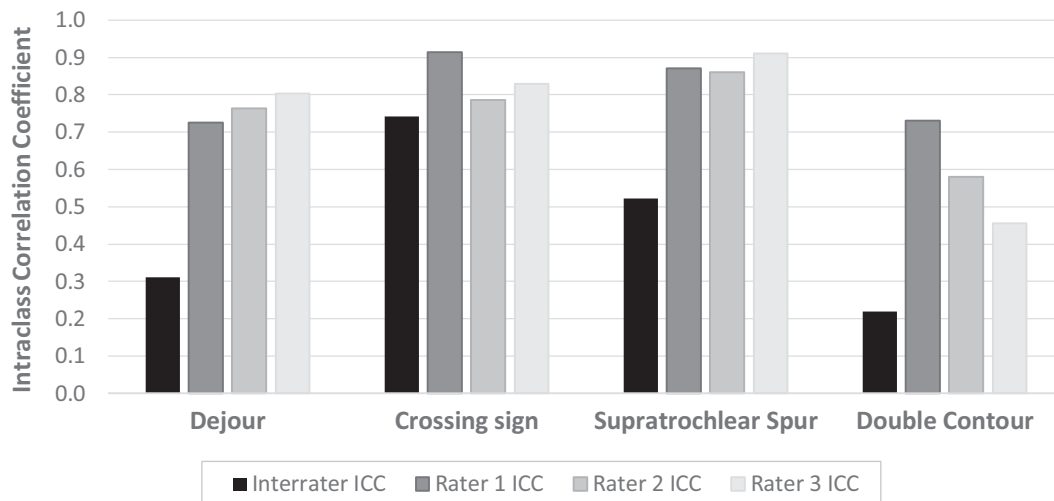


Figure 5. Dejour classification inter- and intrarater reliability along with values for each component: crossing sign, supratrochlear spur, and double contour. ICC, intraclass correlation coefficient.

TABLE 1
Inter- and Intrarater Reliability Analysis, Averages, and Differences for Single-Image LTI and 2-Image LTI^a

Measurement	Interrater ICC (95% CI)	Intrarater ICC (95% CI)			Average, deg	Difference, deg	P
		Rater 1	Rater 2	Rater 3			
Single-image LTI	0.86 (0.72-0.93)	0.88 (0.75-0.94)	0.90 (0.78-0.95)	0.93 (0.87-0.96)	9.2 ± 12.6		
2-image LTI	0.97 (0.88-0.97)	0.96 (0.91-0.98)	0.97 (0.93-0.98)	0.97 (0.93-0.98)	4.2 ± 11.9	7.0 ± 3.4	.0125

^aICC, intraclass correlation coefficient; LTI, lateral trochlear inclination.

TABLE 2
Inter- and Intrarater Reliability for 2-Image LTIs and Average LTI^a

Measurement	Interrater ICC (95% CI)	Intrarater ICC (95% CI)
LTI-2	0.874 (0.75-0.94)	0.951 (0.90-0.98)
LTI-3	0.807 (0.63-0.90)	0.924 (0.84-0.96)
LTI-4	0.772 (0.57-0.89)	0.903 (0.80-0.95)
Average LTI	0.912 (0.82-0.96)	0.973 (0.94-0.99)

^aICC, intraclass correlation coefficient; LTI, lateral trochlear inclination.

LTI-2 ($r = 0.88$; $\beta = 0.81$; $P < .0001$), LTI-1 and LTI-3 ($r = 0.67$; $\beta = 0.54$; $P < .0001$), LTI-1 and LTI-4 ($r = 0.65$; $\beta = 0.43$; $P < .001$), and LTI-1 and LTI-avg ($r = 0.91$; $\beta = 0.70$; $P < .0001$). The final regression analysis between LTI-1 and LTI-avg with an r value of 0.91 demonstrated that LTI-1 accounted for 91% of the trochlear dysplasia represented by the average of the 4 LTI values obtained across the first 12 mm of the proximal trochlea. Referencing the 11° LTI threshold value for trochlear dysplasia first reported by Carrillon et al,⁵ the single-image LTI was <11° in 60% of our patients with PI, indicating dysplasia, whereas the 2-image LTI was <11° in 71% of our patients with PI.

DISCUSSION

In evaluating a modified technique for measuring trochlear morphologic characteristics (LTI) with better reference to the orientation of clearly formed posterior femoral condyles, we found almost perfect reliability between observers and within observers for this measurement. Using the fully formed posterior condyles as a reference makes anatomic sense because they represent the axis of sagittal plane motion of the knee and are a standard reference for measuring, for example, femoral anteversion and tibial tubercle-trochlear groove distance. Further, the 2-image LTI measured at the most proximal aspect of trochlear cartilage captured 91% of the proximal trochlear morphologic characteristics as would otherwise be represented by the average of the LTI values taken along the first 12 mm of the proximal trochlea. Accordingly, this 2-image LTI measurement represents a reliable singular measurement to quantify and describe trochlear dysplasia.

Although the traditionally described single-image LTI measurement purports to reference the posterior femoral condyles, it is clear from this work that the bulk of the measurements in the Carrillon et al⁵ study, especially for patients with higher levels of dysplasia, were 1 to 1.5 cm proximal to the fully formed posterior femoral condyles. This highlights the biggest difference between our measurement technique

and the original single-image measurement. Further, the single-image technique used subchondral bone, and our 2-image technique used the cartilage surface. This is a more accurate assessment because the cartilage is the bearing surface of the joint. The difference between the 2 measurement techniques is further shown by the percentage of patients who were classified as having trochlear dysplasia using the historical standard⁵ of an LTI value of $\leq 11^\circ$ with either measurement technique. We found that 60% of this patient cohort had an LTI $\leq 11^\circ$ when we used the single-image LTI compared with 71% when the 2-image LTI technique was used. This observation is bolstered by the statistically significant difference ($P = .0125$) between the 2 measurement techniques. The average LTI obtained using our 2-image technique (4.2°) was significantly less than the average single-image LTI (9.2°). These data points indicate that the 2-image LTI measurement technique is a more accurate and reliable method to determine lateral trochlear inclination.

The original article by Carrillon et al⁵ reported superior reliability using a single-image LTI. We observed near-perfect reliability using both single-image and 2-image LTI measurements but more variability using the single-image LTI. One explanation for the discrepancy between our single-image LTI measures and the single-image measures of Carrillon et al could be the difference in age ranges for the patient populations evaluated. The average age in our patient population was 14.2 years, with an upper age limit of 18 years. In the study of Carrillon et al, patients had an average age of 24 years, with an age range of 14 to 42 years. Their youngest patient was the average age of our patient population. Given that PI clusters in patients younger than 25 years^{29,30} and is highly associated with trochlear dysplasia, it is very plausible that we evaluated a patient population with more severe disease who had a more proximal extent of trochlear dysplasia (in that the proximal aspect of the dysplastic trochlea was consistently proximal to the formed posterior condyles); this might have led to more variability in measurement using a single-image technique. As highlighted in Figure 2A, the formation of both posterior femoral condyles was not well-defined at the most proximal extent of the trochlea. This was not an uncommon finding in our entire patient cohort. Although this could have been attributable to minor patient malpositioning in the gantry of the MRI scanner, this could very easily represent very slight height differences of the posterior condyles as they came into view on the axial images. Regardless of what the exact explanation is, Figure 2A shows why a 2-image LTI measure is superior to a single-image measure: The 2-image measure will not introduce this potential source of error. Another explanation for the near-perfect reliability in the Carrillon et al article for the single-image LTI measurement is that the described technique might have taken a measurement of proximal trochlear cartilage that was actually more distal in the trochlea. This would explain why the figures in the original article showed well-formed posterior condyles, whereas this was not observed in our study. One could expect high reliability in measuring the angle of the lateral trochlea against well-formed posterior femoral condyles on a single-image. This further strengthens the case to use a

2-image measurement technique when evaluating trochlear dysplasia.

Other studies have used a single-image LTI measurement technique and have identified average LTI values of 17.32° ,¹⁷ 14.9° ,¹³ and 14.7° ¹ in their study groups of patients with PI. Although the study groups ranged in age from early teens to as old as 40 years, the average LTIs were above the historically identified 11° threshold. Stepanovich et al³² found an average LTI of 12.3° in their cohort of patients with symptomatic PI aged 9 to 16 years. It is unclear why the average LTI values were so much higher in these studies. It is possible that the LTI measurements were made on a more distal MRI scan where the posterior femoral condyles were fully formed. In this situation, the bulk if not all of the trochlear dysplasia was proximal to the MRI scan. This would lead to a higher LTI value in the more normal, distal trochlea.

With regard to either LTI measurement technique and the radiographic Dejour classification, MRI evaluation was more reliable. These findings are consistent with previous studies demonstrating inferior interobserver reliability using the Dejour classification for both radiographs and MRI scans.^{4,8,23,27,32} Obtaining a true lateral knee radiograph is critical for adequate evaluation using the Dejour classification.¹⁸ The practical challenges of getting a perfect lateral radiograph in the clinical setting pose additional radiation risk of repeated radiographs. Thus, although we excluded any radiograph that was not able to be determined due to excessive rotation, we acknowledge that several radiographs did not have complete overlap of the posterior condyles. Although it can correctly be argued that this would bias our results away from favoring the Dejour classification, from a practical aspect it highlights that radiographic evaluation of dysplasia has inherent limitations beyond the qualitative nature of the Dejour classification. The findings in this study led us to use the Dejour classification to augment MRI evaluation of the trochlea and not as a primary tool for diagnosis or treatment decisions.

The final topic to discuss is the ability of the LTI, taken at the most proximal aspect of trochlear cartilage, to represent overall proximal trochlear morphologic characteristics. Generally, trochlear dysplasia is confined to the proximal aspect of the trochlea, and as the trochlea courses distally toward the intercondylar notch, a normal or more normal groove develops. Regression analysis showed that the LTI measured at the first cut of visible trochlear cartilage represented 91% of the morphologic characteristics of the proximal 12 mm of the trochlea. This finding validates measuring the LTI at one specific location and will allow standardization of trochlear evaluation for clinical care and research purposes.

Limitations

The current study did not include a control group. However, we sought to evaluate the utility of a modified 2-image measurement technique for abnormal trochlear morphologic characteristics in individuals with symptoms. Our results of increased interrater and intrarater reliability in this patient population would be expected to persist in a

control group theoretically devoid of aberrant anatomic features. Nonetheless, a follow-up study assessing LTI measurements, referencing the fully formed posterior femoral condyles in a control, asymptomatic group, will allow a reevaluation to establish a new threshold LTI value for clinical decision algorithms and/or prognostication in patients with symptomatic PI. Although this new 2-image LTI measurement may be better and more reliably quantify trochlear dysplasia, further research in a prospective manner would elucidate the direct clinical implications of the herein proposed measurement technique.

Another limitation stems from imperfect lateral knee radiographs, which may have affected radiographic measurements and, therefore, the true interrater and intrarater reliability of these imaging measurements. However, the difficulty of practically obtaining acceptable true lateral knee radiographs in routine clinical practice points to the added benefit and consistency of MRI evaluation.

CONCLUSION

By referencing the orientation of fully formed posterior condyles in a 2-image technique, the lateral trochlear inclination was more reliably quantified within and between observers. The LTI at the most proximal aspect of the trochlea adequately represented the first 12 mm of the trochlea, where the majority of the dysplasia was located. This new 2-image LTI measurement technique identified a larger portion of our cohort with PI as having trochlear dysplasia than did the historical single-image LTI measurement technique. Last, the previously described threshold value for LTI may have underestimated pathologic trochlear dysplasia anatomy and thus should be reexamined in light of this new 2-image measurement technique to adequately risk-stratify patients with PI.

REFERENCES

- Ali SA, Helmer R, Terk MR. Analysis of the patellofemoral region on MRI: association of abnormal trochlear morphology with severe cartilage defects. *AJR Am J Roentgenol*. 2010;194:721-727.
- Arendt EA, England K, Agel J, Tompkins MA. An analysis of knee anatomic imaging factors associated with primary lateral patellar dislocations. *Knee Surg Sports Traumatol Arthrosc*. 2017;25:3099-3107.
- Arnbjornsson A, Egund N, Rydning O, Stockerup R, Ryd L. The natural history of recurrent dislocation of the patella: long-term results of conservative and operative treatment. *J Bone Joint Surg Br*. 1992;74:140-142.
- Brady JM, Sullivan JP, Nguyen J, et al. The tibial tubercle-to-trochlear groove distance is reliable in the setting of trochlear dysplasia, and superior to the tibial tubercle-to-posterior cruciate ligament distance when evaluating coronal malalignment in patellofemoral instability. *Arthroscopy*. 2017;33:2026-2034.
- Carrillon Y, Abidi H, Dejour D, Fantino O, Moyen B, Tran-Minh VA. Patellar instability: assessment on MR images by measuring the lateral trochlear inclination-initial experience. *Radiology*. 2000;216:582-585.
- Charles MD, Haloman S, Chen L, Ward SR, Fithian D, Afra R. Magnetic resonance imaging-based topographical differences between control and recurrent patellofemoral instability patients. *Am J Sports Med*. 2013;41:374-384.
- Christensen TC, Sanders TL, Pareek A, Mohan R, Dahm DL, Krych AJ. Risk factors and time to recurrent ipsilateral and contralateral patellar dislocations. *Am J Sports Med*. 2017;45:2105-2110.
- Davies AP, Costa ML, Shepstone L, Glasgow MM, Donell S. The sulcus angle and malalignment of the extensor mechanism of the knee. *J Bone Joint Surg Br*. 2000;82:1162-1166.
- Dejour D, Le Coultre B. Osteotomies in patello-femoral instabilities. *Sports Med Arthrosc Rev*. 2007;15:39-46.
- Dejour H, Walch G, Nove-Josserand L, Guier C. Factors of patellar instability: an anatomic radiographic study. *Knee Surg Sports Traumatol Arthrosc*. 1994;2:19-26.
- Dickschas J, Ferner F, Lutter C, Gelse K, Harrer J, Strecker W. Patellofemoral dysbalance and genua valga: outcome after femoral varisation osteotomies. *Arch Orthop Trauma Surg*. 2018;138:19-25.
- Fabricant PD, Ladenhauf HN, Salvati EA, Green DW. Medial patellofemoral ligament (MPFL) reconstruction improves radiographic measures of patella alta in children. *Knee*. 2014;21:1180-1184.
- Fucntese SF, Schöttle PB, Pfirrmann CW, Romero J. CT changes after trochleoplasty for symptomatic trochlear dysplasia. *Knee Surg Sports Traumatol Arthrosc*. 2007;15:168-174.
- Fulkerson JP. Anteromedialization of the tibial tuberosity for patellofemoral malalignment. *Clin Orthop Relat Res*. 1983;177:176-181.
- Hiemstra LA, Kerslake S, Lafave M. Assessment of demographic and pathoanatomic risk factors in recurrent patellofemoral instability. *Knee Surg Sports Traumatol Arthrosc*. 2017;25:3849-3855.
- Jaquith BP, Parikh SN. Predictors of recurrent patellar instability in children and adolescents after first-time dislocation. *J Pediatr Orthop*. 2017;37:484-490.
- Keser S, Savranlar A, Bayar A, Ege A, Turhan E. Is there a relationship between anterior knee pain and femoral trochlear dysplasia? Assessment of lateral trochlear inclination by magnetic resonance imaging. *Knee Surg Sports Traumatol Arthrosc*. 2008;16:911-915.
- Koeter S, Bongers EM, de Rooij J, van Kampen A. Minimal rotation aberrations cause radiographic misdiagnosis of trochlear dysplasia. *Knee Surg Sports Traumatol Arthrosc*. 2006;14:713-717.
- Kohlitz T, Scheffler S, Jung T, et al. Prevalence and patterns of anatomical risk factors in patients after patellar dislocation: a case control study using MRI. *Eur Radiol*. 2013;23:1067-1074.
- Lewallen L, McIntosh A, Dahm D. First-time patellofemoral dislocation: risk factors for recurrent instability. *J Knee Surg*. 2015;28:303-309.
- Lewallen LW, McIntosh AL, Dahm DL. Predictors of recurrent instability after acute patellofemoral dislocation in pediatric and adolescent patients. *Am J Sports Med*. 2013;41:575-581.
- Liebensteiner MC, Ressler J, Seitzinger G, Djurdjevic T, El Attal R, Ferlic PW. High femoral anteversion is related to femoral trochlea dysplasia. *Arthroscopy*. 2016;32:2295-2299.
- Lippacher S, Dejour D, Elsharkawi M, et al. Observer agreement on the Dejour trochlear dysplasia classification: a comparison of true lateral radiographs and axial magnetic resonance images. *Am J Sports Med*. 2012;40:837-843.
- Murphy SB, Simon SR, Kijewski PK, Wilkinson RH, Griscom NT. Femoral anteversion. *J Bone Joint Surg Am*. 1987;69:1169-1176.
- Paiva M, Blond L, Holmich P, et al. Quality assessment of radiological measurements of trochlear dysplasia; a literature review. *Knee Surg Sports Traumatol Arthrosc*. 2018;26:746-755.
- Parikh SN, Lykissas MG, Gkias I. Predicting risk of recurrent patellar dislocation. *Curr Rev Musculoskelet Med*. 2018;11(2):253-260.
- Remy F, Chantelot C, Fontaine C, Demoncion X, Migaud H, Gougeon F. Inter- and intraobserver reproducibility in radiographic diagnosis and classification of femoral trochlear dysplasia. *Surg Radiol Anat*. 1998;20:285-289.
- Saggin PR, Saggin JI, Dejour D. Imaging in patellofemoral instability: an abnormality-based approach. *Sports Med Arthrosc Rev*. 2012;20:145-151.
- Sanders TL, Pareek A, Hewett TE, Stuart MJ, Dahm DL, Krych AJ. High rate of recurrent patellar dislocation in skeletally immature patients: a long-term population-based study. *Knee Surg Sports Traumatol Arthrosc*. 2018;26(4):1037-1043.

30. Sanders TL, Pareek A, Johnson NR, Stuart MJ, Dahm DL, Krych AJ. Patellofemoral arthritis after lateral patellar dislocation: a matched population-based analysis. *Am J Sports Med.* 2017;45:1012-1017.
31. Stefanik JJ, Zumwalt AC, Segal NA, Lynch JA, Powers CM. Association between measures of patella height, morphologic features of the trochlea, and patellofemoral joint alignment: the MOST study. *Clin Orthop Relat Res.* 2013;471:2641-2648.
32. Stepanovich M, Bomar JD, Pennock AT. Are the current classifications and radiographic measurements for trochlear dysplasia appropriate in the skeletally immature patient? *Orthop J Sports Med.* 2016;4:2325967116669490.
33. Tecklenburg K, Dejour D, Hoser C, Fink C. Bony and cartilaginous anatomy of the patellofemoral joint. *Knee Surg Sports Traumatol Arthrosc.* 2006;14:235-240.
34. Yamada Y, Toritsuka Y, Yoshikawa H, Sugamoto K, Horibe S, Shino K. Morphological analysis of the femoral trochlea in patients with recurrent dislocation of the patella using three-dimensional computer models. *J Bone Joint Surg Br.* 2007;89:746-751.