

Emergency Ileo-cecal Anastomosis with Inclusion of Appendicular Stump in Terminal Ileal Pathology: A Newer Approach

Shyam Bhutra, Amit Singh, TP Devpura

Department of General Surgery, J.L.N. Medical College, Ajmer, Rajasthan, India

ABSTRACT

Background: In emergency settings, several surgical procedures are described while dealing with pathology of terminal ileal lying within 15 cm of the ileocecal valve, but there is still confusion and controversy over the optimal surgical treatment. **Methods:** A nonrandomized study of 210 patients with near terminal ileal pathology (within 15 cm) was carried out over a period of 10 years. The study included 112 cases in which an ileocecal anastomosis with inclusion of appendicular stump was used in terminal ileal pathologies, and in rest 98 cases, other surgical procedures were used. The outcomes were measured in relation to postoperative complications and mortality. **Results:** Postoperative complications encountered in emergency ileocecal anastomosis with the inclusion of appendicular stump were wound infection in 31 patients (34.72%), respiratory complications in 10 patients (11.2%), septicemia in 6 patients (6.72%), and anastomotic leak in one patient (1.12%). **Conclusion:** The technique of ileocecal single-layer anastomosis with the inclusion of appendicular stump was found to be very effective in dealing this common problem and had less morbidity and mortality.

KEYWORDS: *Ileocecal anastomosis, multiple terminal ileal perforations, single layer anastomosis, terminal ileal gangrene*

INTRODUCTION

Pathology near terminal ileum in emergency is always nightmare to surgeons and it is very difficult for a surgeon to choose a procedure for particular condition. Our institute largely deals with patients of middle and lower socioeconomical class who usually present late in the course of the disease, either due to ignorance or lack of resources. Management is quite challenging as these patients present late with septicemia, fluid and electrolyte derangements, shock, and/or systemic inflammatory response syndrome. The author shares his 10-year experience with technical modification of ileocecal anastomosis and probably newer approach in emergency setting.

METHODS

The present study was a retrospective study conducted by the Department of General Surgery, J.L.N Medical College, Ajmer, from December 2006 to January 2016. All the patients were admitted in emergency department.

A thorough history was taken and detailed examination done as per pro forma. Traumatic perforations and children below 12 years were excluded from our study. Baseline investigations included hemogram, renal function tests, liver function test, electrolytes, chest and abdominal X-ray, and ultrasonography. Widal test was done preoperatively only when there was a high index of suspicion of typhoid fever; otherwise, it was done postoperatively after typical findings were noted. After thorough resuscitation, the patients were subjected to exploratory laparotomy under general anesthesia. Operative findings were recorded and edge biopsy at the perforation site or the resected specimen was sent for histopathological examination. The type of surgical procedure was decided on the basis of operative findings; ileocecal anastomosis by author's modification was carried out in 112 patients who had multiple perforations

Address for correspondence: Asst. Prof. Amit Singh, J.L.N. Medical College, Ajmer - 305 001, Rajasthan, India.
E-mail: dr.amit5280@gmail.com

Access this article online

Quick Response Code:



Website: www.nigerianjsurg.com

DOI: 10.4103/njs.NJS_35_17

This is an open access journal, and articles are distributed under the terms of the Creative Commons Attribution-NonCommercial-ShareAlike 4.0 License, which allows others to remix, tweak, and build upon the work non-commercially, as long as appropriate credit is given and the new creations are licensed under the identical terms.

For reprints contact: reprints@medknow.com

How to cite this article: Bhutra S, Singh A, Devpura TP. Emergency ileo-cecal anastomosis with inclusion of appendicular stump in terminal ileal pathology: A newer approach. *Niger J Surg* 2018;24:116-20.

with poor condition of bowel and gangrene near terminal ileum. Other procedures were performed on 98 patients who had single or multiple perforations. All the operative procedures were done by the same surgeon.

Technique and observation

The principal author has been dealing with the cases of near terminal ileal pathology (multiple perforations/gangrene) for >25 years. During this long experience, it was found that sometimes condition of terminal ileum was oedematous and friable, and hemodynamic condition of patient did not permit lengthy resectional procedures. In such cases, a new option was tried single-layer ileocecal valve cutting end to side anastomosis. All operations were carried out under general anesthesia in supine position. The abdomen was opened by midline incision. Primary ileocecal anastomosis was performed in the terminal ileal pathology (multiple perforations/gangrene) lying within 15 cm of the ileocecal valve. First, after taking safe healthy margins of ileum, it was resected up to the ileocecal valve. Then, the cecum was mobilized and appendectomy performed. The cecum was opened through appendicular stump and incision extended up to the ileocecal valve which was incised. A short incision was given on the antimesenteric border of ileum to combat size of anastomotic area. Terminolateral ileocecal anastomosis was performed in the region of the ileocecal valve in a single layer using silk 2-0 [Figures 1 and 2]. A single drain (32F) was put in the pelvis, and the abdominal fascial closure was done in

a single layer in addition to skin stitches. According to author, this is a new technique as after exhaustive search in existing literature, search engines, and indexing agencies’ similar technique of ileocecal anastomosis by author’s modification with the inclusion of appendicular stump was not found.

RESULTS

There were a total of 210 cases dealt by author with pathology of terminal ileum over a period of 10 years. In our study, the maximum incidence of cases was seen in the third decade of life which constituted 53%. Male-to-female ratio was 3.45:1. Pain abdomen was only constant clinical feature in all the patients; other common findings were abdominal distension (98%), constipation, diarrhea, and vomiting. Generalized guarding, rigidity, and tenderness were found in all the patients. Among the investigation, ultrasonography was more sensitive showing the free fluid in 75% of patients. Pneumoperitoneum was present in 66.8% of patients who had an X-ray abdomen standing. On laparotomy, 50 (23.8%) patients had single perforation, 30 (14.28%) patients had two perforations, 88 (41.9%) patients had multiple perforations, and 42 (20%) patients had gangrene [Table 1]. The final diagnosis in majority was typhoid (66.66%), followed by gangrene (20%), nonspecific inflammatory conditions (6.6%), tuberculosis (3.8%), and obstruction (2.8%) [Table 2]. Ileo-cecal anastomosis by author’s modification was carried out in 112 patients in the past 10 years (December 2006 to January 2016) who had multiple perforations with poor bowel condition and gangrene near terminal ileum. The common complications encountered in the

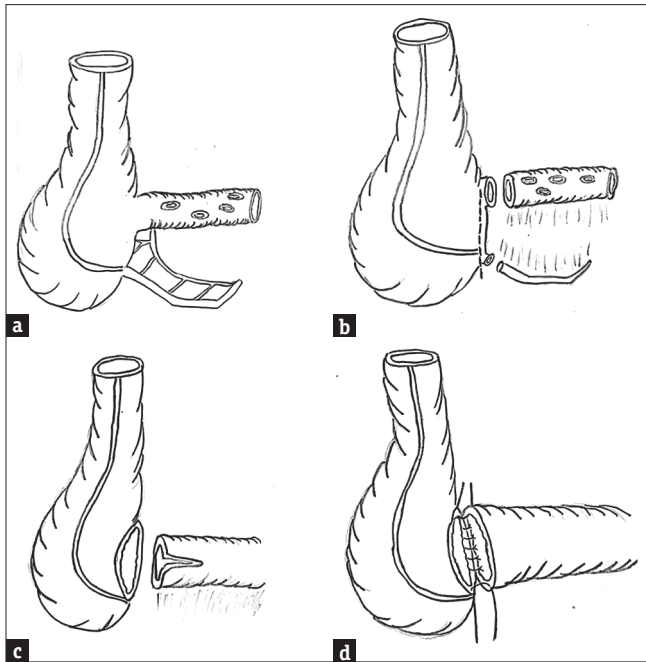


Figure 1: (a) multiple ileal perforations, (b) resection of diseased ileum with appendectomy (c) anastomotic area after cutting of ileo-cecal valve with involvement of appendicular stump, (d) approximation of posterior layer by full thickness single layer interrupted silk suture

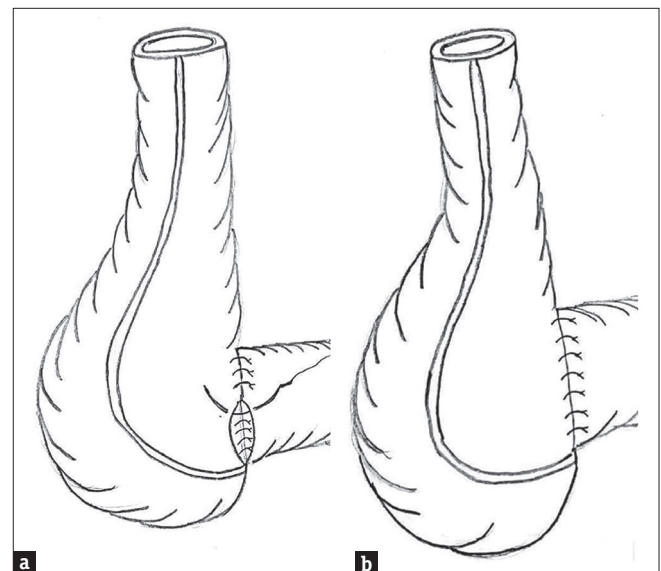


Figure 2: (a) anterior interrupted layer of single layer anastomosis, (b) final picture of ileo-cecal anastomosis

course of the present experience (112 patients) were wound infection in 31 (34.72%) patients, respiratory complications in 10 (11.2%) patients, septicemia in 6 (6.72%) patients, and anastomotic leak in 1 (1.12%) patient which was managed conservatively. One patient expired on the 3rd postoperative day because of the respiratory problem which was unrelated to the repair. All patients were followed up to 1 year; none of the patient has diarrhea or malabsorption during follow-up. Comparison of various standard procedures performed by principal author for terminal ileal pathology is given in Table 3.

DISCUSSION

Terminal ileal perforation or gangrene is still common as a cause for obscure peritonitis in developing and underdeveloped countries. The major culprit of terminal ileal perforation is typhoid fever which is an endemic disease in the Indian subcontinent. Intestinal

perforation is the most dreadful complication of enteric fever in developing countries leading to diffuse peritonitis.^[1,2] In our study, majority of perforations were due to typhoid (66.66%). The disease and its complications are more common in young males when they are in their economically productive years; in our study, majority of cases are in the third decade of life.

Tuberculosis accounts for 5%–9% of all small intestinal perforations in India and it is the second most common cause after typhoid fever.^[3]

Gangrene of distal ileum also plays a role in the adverse clinical condition of patient with grave outcome. Females are affected with three times the frequency of males and patients are usually are in late age with several comorbidities.^[4] Most events are thromboembolic and arise from a cardiac source.^[5] Nearly 50% lodge distal to the middle colic artery.^[6] In these cases, proximal intestine and ascending colon are spared. After initial resuscitation and stabilization of the patient, surgery is required for all patients who have evidence of threatened bowel.

Various operative techniques are proposed for tear terminal ileal pathology in emergency; ileoileostomy, ileoascending anastomosis, ileotransverse anastomosis, ileocecal anastomosis, and simple ileostomy. Out of these techniques, ileocecal anastomosis is less performed by most of the surgeons and least described in literature. Hussein *et al.* worked on ileocecal anastomosis with ileocecal valve reconstruction and advised to avoid anastomosis adjacent to the ileocecal valve, ileocecal anastomosis was feasible, safe, and rapid procedure, also the nipping of the terminal ileum into cecum imitated the ileocecal valve in preventing reflux of cecal contents into ileum when compared with ileotransverse anastomosis in terminal ileal lesions.^[7] Some authors

Table 1: Number of perforations/gangrene in terminal ileum

Number of perforation/gangrene	Number of patients (%)
One	50 (23.8)
Two	30 (14.28)
Multiple	88 (41.9)
Gangrene	42 (20)

Table 2: Etiology of terminal ileum pathology

Etiology	Number of patients (%)
Typhoid	140 (66.66)
Tuberculosis	8 (3.8)
Obstruction	6 (2.8)
Nonspecific inflammatory conditions	14 (6.6)
Gangrene	42 (20)

Table 3: Outcome in term of complications in ileocecal anastomosis using with appendicular stump and other operative procedures for terminal ileal pathology

Operative procedures for terminal ileal pathology	Outcome						
	No complications, n (%)	Wound infections, n (%)	Respiratory complications, n (%)	Burst abdomen, n (%)	Anastomosis leak, n (%)	Septicemia, n (%)	Death, n (%)
Ileocecal anastomosis using with appendicular stump (112)	64 (57.14)	31 (34.72)	10 (11.2)	-	1 (1.12)	6 (6.72)	-
Other procedures (98)							
Simple primary double layer repair-30 (30.61%)	8 (26.66)	6 (20)	4 (13.33)	6 (20)	2 (6.6)	4 (13.33)	-
Primary double layer repair with free omental sheet graft-38 (38.77%)	14 (36.84)	6 (15.78)	7 (18.42)	6 (15.78)	1 (2.63)	4 (10.52)	-
Resection and anastomosis-12 (12.24%)	4 (33.33)	2 (16.66)	2 (16.66)	2 (16.66)	1 (8.33)	1 (8.33)	-
Primary double layer repair with ileotransverse bypass anastomosis-6 (6.12%)	2 (33.33)	1 (16.66)	1 (16.66)	1 (16.66)	-	1 (16.66)	-
Primary double layer repair with loop ileostomy-12 (12.24%)	2 (16.66)	2 (16.66)	2 (16.66)	2 (16.66)	-	3 (25)	1 (8.33)

Table 4: Comparison of present study with other published procedures for ileal perforation

Postoperative complications	Outcome of present study and comparison with other published procedures for ileal perforation							
	Shyam Bhutra <i>et al.</i> (present study) Ileocecal anastomosis using with appendicular stump (n=112)	Madhu and Jha ^[9] Ileo transverse anastomosis (n=60)	Khalilur Rahman <i>et al.</i> ^[10] Primary closure (n=14) Ileostomy group (n=14)		Malik <i>et al.</i> ^[12] Primary closure (n=40) Ileostomy (n=54) Resection and anastomosis (n=18)			Singh <i>et al.</i> ^[12] Free omental sheet graft (n=38)
Wound infections, n (%)	31 (34.72)	2 (33)	2 (7.14)	4 (14.28)	05 (12.5)	05 (9.25)	02 (11.11)	16 (42.10)
Respiratory complications, n (%)	10 (11.2)	1 (17)	3 (10.71)	1 (3.57)	05 (12.5)	02 (3.70)	02 (11.11)	1 (2.63)
Burst abdomen, n (%)	-	0	3 (10.71)	0	07 (17.5)	02 (3.70)	01 (5.55)	2 (5.26)
Anastomosis leak, n (%)	1 (1.12)	0	1 (3.57)	0	07 (17.5)	01 (1.85)	03 (16.66)	1 (2.63)
Septicemia, n (%)	6 (6.72)	0	-	-	02 (5.0)	01 (1.85)	01 (5.55)	5 (13.15)
Death, n (%)	-	0	-	-	05 (12.5)	01 (1.85)	02 (11.11)	-

showed the importance of ileocecal valve reconstruction in ileocecal anastomosis. Ileocecal valve plays a very important role in the regulation of intestinal transit. It acts as a barrier to delay passage for small bowel contents and hence increases absorption. It also prevents reflux from the cecum into the ileum.^[8] Surprisingly, in our 1 year follow-up, we did not find any patient who had diarrhea and malabsorption. The author also performed appendectomy in all patients; with the use of appendicular stump, cecum was incised up to ileocecal valve; this is the key modification by the author to increase of anastomotic length for better results. The author did not find this technique described in the literature. We do not rank this procedure to compare with established various procedures for terminal ileum pathology because safe outcome of surgery is related to multiple factors such as preoperative morbid conditions and intraoperative findings. Comparison of various established and published procedure for terminal ileal perforation with our technique is given in Table 4. Madhu and Jha concluded that, if duration of perforation was <24 h, primary closure was the best option, if patient came 24–72 h, then ileotransverse anastomosis proved better results, but if patient came after 72 h, ileostomy was the surgery of choice.^[9] Khalilur Rahman *et al.* compared postoperative complications between primary closure and ileostomy; they proposed that ileostomy may be given priority over other surgical options, especially in those moribund patients, who present late in the course of their illness, have more than one perforation with massive fecal contamination of the abdominal cavity. Primary closure of perforation was a preferred technique in clinically stable patients with a single perforation with minimal soiling of the abdominal cavity.^[10] Malik *et al.* recommended that ileostomy was a safe way of managing ileal perforation in moribund patients.^[11] Singh *et al.* worked on free omental sheet graft repair in single

or multiple ileal perforation, and they recommended the use of free omental sheet graft on typhoid enteric perforation site was effective in lowering the repair leak rate and thereby decreases the morbidity and mortality associated with these procedures.

The following advantages were found with this technique:

1. In the emergency setting, anastomosis near ileocecal junction has a risk for leak; due to the functional distal obstruction by the valve also, the terminal ileum has poor vascularization, as the arterial supply of the terminal ileum in the region adjacent to the ileocaecal valve comes from a single arch from the ileocolic artery. Valve was cut in our technique so that we could achieve a more reliable anastomosis
2. The author used appendicular stump to incise cecum, so total length of anastomosis area increased around 4–5 cm, that’s why we achieved better mucosal approximation this helped in enhancing the healing process
3. In our technique, there was no upright dragging force which was present in ileoascending or ileotransverse anastomosis
4. We choose single layer full-thickness interrupted silk for anastomosis that’s why marginal supply of blood vessels was minimally hampered
5. In our technique, we were also able to preserve total colon length
6. In our technique, blind loop syndrome could be avoided which was a possibility in ileoascending or ileotransverse anastomosis.

CONCLUSION

Author recommends that this technique may be a safe newer option for near terminal ileum pathology in emergency settings as it would require less time than in major resectional procedures. This technique is also

particularly beneficial to population of underdeveloped countries because of their low nutritional status they could not fetch multistep surgeries or major resectional procedures.

Acknowledgment

We are thankful to Dr. TP Devpura, Professor and former Head of Department for initiating and helping me to continuing the new procedure.

Financial support and sponsorship

Nil.

Conflicts of interest

There are no conflicts of interest.

REFERENCES

1. Kouame J, Kouadio L, Turquin HT. Typhoid ileal perforation: Surgical experience of 64 cases. *Acta Chir Belg* 2004;104:445-7.
2. Rehman A. Spontaneous ileal perforation: An experience of 33 cases. *J Post Grad Med Inst* 2003;17:105-10.
3. Kapoor VK. Abdominal tuberculosis: The Indian contribution. *Indian J Gastroenterol* 1998;17:141-7.
4. Woods K, Williams E, Melvin W, Sharp K. Acquired jejunoileal diverticulosis and its complications: A review of the literature. *Am Surg* 2008;74:849-54.
5. Lock G. Acute intestinal ischaemia. *Best Pract Res Clin Gastroenterol* 2001;15:83-98.
6. Acosta S, Ogren M, Sternby NH, Bergqvist D, Björck M. Clinical implications for the management of acute thromboembolic occlusion of the superior mesenteric artery: Autopsy findings in 213 patients. *Ann Surg* 2005;241:516-22.
7. Hussein H, Bayoumi M, Abdelmoheed AM, Salama R. Ileocaecal implantation with ileocaecal valve reconstruction versus right hemicolectomy in terminal ileal lesions. *Med Rep Case Stud* 2016;1:117.
8. Cserni T, Paran S, Kanyari Z, O'Donnell AM, Kutasy B, Nemeth N, *et al.* New insights into the neuromuscular anatomy of the ileocecal valve. *Anat Rec (Hoboken)* 2009;292:254-61.
9. Madhu K, Jha NK. Study of different surgical management and their complication rates in ileal perforation. *IOSR J Dent Med Sci* 2017;16:51-6.
10. Khalilur Rahman A, Krishnaswamy J, Muthukumaran G, Sanjay Prakash J. A comparative study on outcome of ileal perforation after primary perforation closure and resection and ileostomy. *Int Surg J* 2018;5:445-51.
11. Malik AM, Laghari AA, Mallah Q, Qureshi GA, Talpur AH, Effendi S, *et al.* Different surgical options and ileostomy in typhoid perforation. *World J Med Sci* 2006;1:112-6.
12. Singh A, Gora N, Soni ML, Khandelwal RG, Vidyarthi SH, Thounaojam CK, *et al.* Comparative study of free omental sheet graft and other operative procedures of enteric perforation repair. *J Gastrointest Surg* 2014;18:751-6.