


A 56-Year-Old Male With Weight Loss, Night Sweats, Dyspnea, and Bladder Cancer

Journal of Investigative Medicine High
Impact Case Reports
Volume 9: 1–3
© 2021 American Federation for
Medical Research
DOI: 10.1177/2324709621997246
journals.sagepub.com/home/hic


Bradley C. Sanville, MD¹ and Brooks T. Kuhn, MD¹ 

Abstract

A 56-year-old man presented with subacute night sweats, fever, and weight loss with worsening dyspnea. Computed tomography (CT) scan demonstrated miliary pattern of nodules evenly distributed throughout all lung fields. Given the patient's CT findings and temporal association with Bacille Calmette-Guerin (BCG) immunotherapy for bladder cancer, the patient was diagnosed with disseminated *Mycobacterium bovis* secondary to BCG bladder instillations.

Keywords

pulmonary critical care

Introduction

Disseminated *Mycobacterium bovis* is a rare complication of intravesical Bacille Calmette-Guerin (BCG) immunotherapy. This phenomenon is most often associated with pulmonary and hepatic involvement, though a variety of other organs can be involved as well. The 2 pulmonary complications are pneumonitis and miliary dissemination, which combined occur in less than 0.5% of intravesical BCG immunotherapy complications.¹ Either pulmonary complication can occur at any point during therapy with case reviews showing a mean of 8.3 instillations before dissemination with a range of 3 to 16 instillations.²

Symptoms typically include acute or subacute onset of fever, malaise, weight loss, cough, and dyspnea.³ Risk factors include active urinary tract infections, genitourinary trauma, or hematuria in immunocompetent hosts. Administration of intravesical BCG stimulates a localized antitumor effect through patient's cell-mediated immunity. As such, any patient with a defect in this pathway is at risk for dissemination. Immunosuppressed patients are at higher risk as well, and it is a relative contraindication to intravesical therapy.³

Chest imaging findings typically show diffuse micronodular pattern or interstitial disease, and bronchoalveolar lavage (BAL) samples are rarely positive for acid-fast bacilli by smear or culture.⁴ If transbronchial or other lung biopsies are obtained, noncaseating granulomas are often seen. We describe the case of a patient who developed disseminated BCG due to bladder instillations and was successfully treated despite liver involvement.

Case Description

A 56-year-old man presents to clinic with 4 weeks of night sweats, fevers, 10-pound weight loss, and progressive

dyspnea. He denies cough, hemoptysis, rash, or arthralgias. He has a 2-pack year smoking history as a teenager, drinks approximately 15 alcoholic beverages per week, and denies any illicit drug use. He denies tuberculosis risk factors or exposure to farm soil. His past medical history is notable for bladder cancer, treated with transurethral resection of bladder tumor 2 years prior. He subsequently was started on BCG immunotherapy 1 year prior, tolerating 15 instillations without complications. His last installation was 2 weeks prior to the onset of the aforementioned symptoms. His vitals are all within normal limits. His physical examination reveals diffuse alveolar breath sounds with no adventitious sounds. The remainder of his examination is normal. Chest X-ray shows a diffuse nodular pattern, and subsequent computed tomography (CT) scan shows innumerable, small, dense nodules throughout all lobes without notable hilar or mediastinal lymphadenopathy (Figure 1). Laboratory testing shows a mixed hepatocellular/cholestatic transaminitis with alkaline phosphatase 271 U/L (normal 35-115 U/L), aspartate aminotransferase 100 U/L (normal 15-43 U/L), and alanine aminotransferase 179 U/L (normal 6-63 U/L; Table 1). Interferon- γ (IFN- γ) release assay is negative; however, a purified protein derivative (PPD) is measured as 10 mm.

¹Division of Pulmonary and Critical Care Medicine, University of California Davis Medical Center, Sacramento, CA, USA

Received January 28, 2021. Revised January 28, 2021. Accepted January 30, 2021.

Corresponding Author:

Brooks T. Kuhn, MD, Division of Pulmonary and Critical Care Medicine, University of California Davis Medical Center, 4150 V Street, Suite 3400, Sacramento, CA 95817, USA.
Email: btkuhn@ucdavis.edu



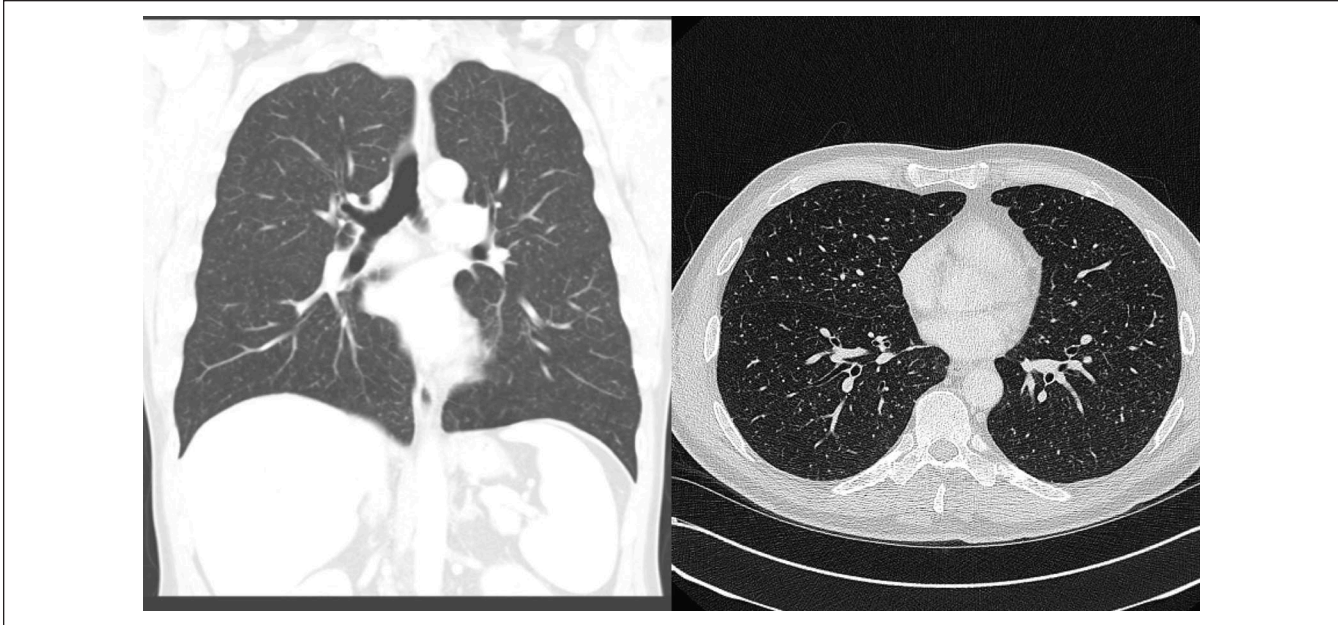


Figure 1. CT chest findings of miliary nodular pattern diffusely in all lung fields.

Table 1. Pertinent hepatic serum levels from initiation of anti-mycobacterial therapy (day 0) on through the completion of treatment (4 months).

Laboratory value (normal range)	Day 0	2 weeks	4 weeks	8 weeks	4 months
Alkaline phosphatase (35-115 U/L)	271 U/L	192	145	86	56
Aspartate aminotransferase (15-43 U/L)	100 U/L	54	44	35	32
Alanine aminotransferase (6-63 U/L)	179 U/L	107	107	41	30

Coccidioides serologies are positive immunoglobulin M (IgM) by immunodiffusion, but negative by complement fixation. CT and ultrasound imaging of the liver do not show abnormalities. Bronchoscopy with BAL of the right middle lobe reveal a lymphocytic preponderance of white blood cells (475 cells/mm³ with 70% lymphocytes; normal: <1% lymphocytes and >95% macrophages) and negative bacterial, fungal, and mycobacterial cultures. Transbronchial biopsies of the right lower lobe reveal noncaseating granulomas with negative acid-fast bacilli and fungal stains. After the diagnosis of disseminated *Mycobacterium bovis* was made based on imaging and clinical findings, the patient immediately started on rifampin, isoniazid, and ethambutol. Bronchoscopy was performed after coccidioidomycosis IgM positivity was demonstrated. BAL gram stain showed no spherules, and fungal cultures were negative. After 3 months of triple therapy, his symptoms, transaminitis, and pulmonary findings completely resolved.

Discussion

Disseminated *M bovis* is a rare but described complication of BCG bladder installation. Patients given the intradermal

BCG vaccine are well known to have false-positive tuberculin skin test (TST) reactions. The typical administered dose for the intradermal vaccine is 0.05 to 0.1 mg; however, the intravesical dose is considerably higher at 81 mg given in multiple weekly doses. Bladder instillation has an observed TST conversion rate of 65% to 68%. IFN- γ T-cell-based assays target *Mycobacterium tuberculosis* proteins CFP-10 and ESAT-6, which are not present in the BCG vaccine. This assay was created to improve specificity testing for presumed *M tuberculosis*. Thus, a positive TST and negative IFN- γ test significantly increases the likelihood of disseminated BCG over miliary tuberculous infection. Overall, the diagnosis is clinically made with supporting laboratory, TST, and imaging results.⁵

The vaccine's origins are like that of the smallpox vaccine by Edward Jenner who used the less virulent *Vaccinia* virus to create protective antibodies to the highly virulent *Variola* virus. After Robert Koch differentiated *M bovis* from *M tuberculosis*, a 19th century attempt was made in Italy to create protective antibodies to *M tuberculosis* through inoculation with *M bovis*. This was met with significant patient death as the *M bovis* strains were still highly virulent. This changed with Albert Calmette and Camille Guerin who

created an avirulent strain of *M bovis* through 230 growth cycles on glycerinated bile potato medium.²

A variety of different strains have been produced around the world for region-specific vaccination programs, though nearly all substrains in use today originated from the Calmette laboratory in the 1920s.⁶ Of note, these strains of *M bovis* are intrinsically resistant to pyrazinamide. Nearly all strains are susceptible to other first-line antimycobacterial therapies—rifampin, rifabutin, and ethambutol. As such, a 3-drug combination of any first-line antimycobacterial drugs or fluoroquinolone with the exception of pyrazinamide is sufficient with courses varying from 3 to 9 months depending on the clinical course. Outcomes with treatment are generally good with few deaths reported, as long as treatment is initiated in a timely manner.⁷

The positive coccidiomycosis IgM was likely a false positive as the patient lacked a clear exposure aside from living at the outside edge of the endemic range of the fungus. Furthermore, his clinical presentation was more consistent with disseminated *M bovis*. False-positive coccidioidomycosis IgM has been reported to be in the range of 13.5% depending on the titer cutoff used.⁸ The Infectious Disease Society of America recommends only treating positive serologies in the presence of disabling symptoms due to large amount of self-resolution.⁹

This is a case of disseminated *M bovis* due to BCG bladder installation. Despite liver involvement, liver function tests improved despite administration of medications with potential hepatotoxic side effects.

Authors' Note

This study was presented as an abstract at the American Thoracic Society in May 2019.

Declaration of Conflicting Interests

The author(s) declared no potential conflicts of interest with respect to the research, authorship, and/or publication of this article.

Funding

The author(s) received no financial support for the research, authorship, and/or publication of this article.

Ethics Approval

Our institution does not require ethical approval for reporting individual cases or case series.

Informed Consent

Verbal informed consent was obtained from the patient(s) for their anonymized information to be published in this article.

ORCID iD

Brooks T. Kuhn  <https://orcid.org/0000-0003-0036-1300>

References

1. Gupta RC, Lavengood R Jr, Smith JP. Miliary tuberculosis due to intravesical bacillus Calmette-Guerin therapy. *Chest*. 1988;94:1296-1298.
2. Oettinger T, Jørgensen M, Ladefoged A, Hasløv K, Andersen P. Development of the *Mycobacterium bovis* BCG vaccine: review of the historical and biochemical evidence for a genealogical tree. *Tuber Lung Dis*. 1999;79:243-250.
3. Gonzalez OY, Musher DM, Brar I, et al. Spectrum of bacille Calmette-Guérin (BCG) infection after intravesical BCG immunotherapy. *Clin Infect Dis*. 2003;36:140-148.
4. Larsen BT, Smith ML, Grys TE, Vikram HR, Colby TV. Histopathology of disseminated *Mycobacterium bovis* infection complicating intravesical BCG immunotherapy for urothelial carcinoma. *Int J Surg Pathol*. 2015;23:189-195.
5. Silverman MS, Reynolds D, Kavsak PA, Garay J, Daly A, Davis I. Use of an interferon-gamma based assay to assess bladder cancer patients treated with intravesical BCG and exposed to tuberculosis. *Clin Biochem*. 2007;40:913-915.
6. Ritz N, Tebruegge M, Connell TG, Sievers A, Robins-Browne R, Curtis N. Susceptibility of *Mycobacterium bovis* BCG vaccine strains to antituberculous antibiotics. *Antimicrob Agents Chemother*. 2009;53:316-318.
7. Colmenero JD, Sanjuan-Jimenez R, Ramos B, Morata P. Miliary pulmonary tuberculosis following intravesical BCG therapy: case report and literature review. *Diagn Microbiol Infect Dis*. 2012;74:70-72.
8. Kuberski T, Herrig J, Pappagianis D. False-positive IgM serology in coccidioidomycosis. *J Clin Microbiol*. 2010;48:2047-2049.
9. Galgiani JN, Ampel NM, Blair JE, et al. 2016 Infectious Disease Society of America (IDSA) clinical practice guideline for the treatment of coccidioidomycosis. *Clin Infect Dis*. 2016;63:e112-e146.