



Cervical Interlaminar Epidural Steroid Injection for Unilateral Cervical Radiculopathy: Comparison of Midline and Paramedian Approaches for Efficacy

Ji Young Yoon, MD¹, Jong Won Kwon, MD¹, Young Cheol Yoon, MD¹, Jongseok Lee, PhD²

¹Department of Radiology and Center for Imaging Science, Samsung Medical Center, Sungkyunkwan University School of Medicine, Seoul 135-710, Korea; ²School of Business Administration, Hallym University, Chuncheon 200-702, Korea

Objective: The objective of this study was to compare the clinical outcomes of the cervical interlaminar epidural steroid injection (CIESI) for unilateral radiculopathy by the midline or paramedian approaches and to determine the prognostic factors of CIESI.

Materials and Methods: We retrospectively analyzed 182 patients who underwent CIESI from January 2009 to December 2012. Inclusion criteria were no previous spinal steroid injection, presence of a cross-sectional image, and presence of follow-up records. Exclusion criteria were patients with bilateral cervical radiculopathy and/or dominant cervical axial pain, combined peripheral neuropathy, and previous cervical spine surgery. Short-term clinical outcomes were evaluated at the first follow-up after CIESI. We compared the clinical outcomes between the midline and paramedian approaches. Possible prognostic factors for the outcome, such as age, gender, duration of radiculopathy, and cause of radiculopathy were also analyzed.

Results: Cervical interlaminar epidural steroid injections were effective in 124 of 182 patients (68.1%) at the first follow-up. There was no significant difference in the clinical outcomes of CIESI, between midline (69.6%) and paramedian (63.7%) approaches ($p = 0.723$). Cause of radiculopathy was the only significant factor affecting the efficacy of CIESI. Patients with disc herniation had significantly better results than patients with neural foraminal stenosis (82.9% vs. 56.0%) ($p < 0.001$).

Conclusion: There is no significant difference in treatment efficacy between the midline and paramedian approaches in CIESI, for unilateral radiculopathy. The cause of the radiculopathy is significantly associated with the treatment efficacy; patients with disc herniation experience better pain relief than those with neural foraminal stenosis.

Index terms: Cervical spine; Epidural steroid injection; Radiculopathy; Spinal stenosis; Intervertebral disc

INTRODUCTION

Cervical interlaminar epidural steroid injection (CIESI)

Received September 22, 2014; accepted after revision February 23, 2015.

Corresponding author: Jong Won Kwon, MD, Department of Radiology and Center for Imaging Science, Samsung Medical Center, Sungkyunkwan University School of Medicine, 81 Irwon-ro, Gangnam-gu, Seoul 135-710, Korea.

• Tel: (822) 3410-2568 • Fax: (822) 3410-0049

• E-mail: jwkwon@gmail.com

This is an Open Access article distributed under the terms of the Creative Commons Attribution Non-Commercial License (<http://creativecommons.org/licenses/by-nc/3.0>) which permits unrestricted non-commercial use, distribution, and reproduction in any medium, provided the original work is properly cited.

is used for the conservative management of neck pain or cervical radiculopathy. A systematic evaluation concluded that CIESI significantly relieves chronic intractable pain of cervical origin and also provides long-term relief (1, 2). Compared with lumbar epidural steroid injections, CIESI has additional technical challenges associated with more narrowed epidural space and inconsistent 'loss of resistance technique' due to a high incidence of discontinuity in the ligamentum flavum at the cervical region (3, 4).

There are two approach techniques used in CIESI: midline and paramedian. The paramedian approach is sometimes preferred, because it is believed to provide a better therapeutic outcome due to the delivery of a relatively high volume of injectate directly into the affected nerve root

sleeve; but this has not been verified in clinical trials.

The aim of this study was to compare the clinical outcome of CIESI for unilateral radiculopathy, by using midline and paramedian approaches, and to identify factors that are predictive of therapeutic outcome after CIESI.

MATERIALS AND METHODS

Patients

This retrospective study was approved by our Institutional Review Board and did not require informed consent. From January 2009 to December 2012, 1157 CIESIs were performed in our department. This investigation was based on medical records, CT or MR images, and sets of anteroposterior and lateral fluoroscopic views obtained during CIESI.

The patients received CIESI by either a midline or paramedian approach under fluoroscopic guidance. We defined the midline approach as a confined needle tip within the vertical lines of the spinous process in an anteroposterior fluoroscopic view. The paramedian approach was defined when the needle tip was located outside of the vertical lines of the spinous process in an anteroposterior fluoroscopic view. After the CIESIs were completed, anteroposterior and lateral epidurogram were obtained to document the extent and dispersal pattern of the injectate within the epidural space. Patients were included in this study, if the patterns of epidural contrast material flow of the injectate were bilaterally symmetric with a midline approach or ipsilateral in more than two thirds of the areas of the injectate distributions with a paramedian approach. Since we were only evaluating impact of the injection on unilateral radiculopathy, we excluded the cases with unintended consequences of midline approach with asymmetric distribution or paramedian approach with symmetric or contralateral distribution of the injectate on unilateral radiculopathy.

Further inclusion criteria were patients with the following conditions: 1) unilateral cervical radiculopathy; 2) first time of receiving CIESI at our institute; 3) no previous (within 3 months) spinal steroid injection; 4) presence of a cross-sectional image, such as CT or MR image, of the cervical spine; and 5) presence of follow-up records after CIESI. Exclusion criteria were as follows: 1) bilateral cervical radiculopathy and/or dominant cervical axial pain; 2) combined peripheral neuropathy; and 3) previous cervical spine surgery. A total of 975 procedures were excluded

for the following reasons: preventive CIESIs in 539, other spinal steroid injection within three months in 71, bilateral cervical radiculopathy and/or dominant cervical axial pain in 142, no cross-sectional image in 154, previous cervical spine surgery in 11, asymmetric distribution of injectate with midline approach in 27, and symmetric or contralateral distribution of the injectate with paramedian approach in 31. Thus, 182 procedures of 182 patients were included in this study.

Cervical axial pain consisted of pain or soreness in the posterior neck muscles, with frequent radiation to the occiput or shoulder regions that did not usually follow a dermatomal distribution. Cervical radiculopathy manifested as pain traveling down the neck and shoulder into the arm of the patient, with radicular distribution (5).

Injection Technique

All CIESIs were performed under biplane fluoroscopic guidance by two musculoskeletal radiologists experienced in spinal intervention. The patient was placed in the prone position. A pillow was placed under the patients' chests to elevate the shoulders, which helps to widen the interlaminar space by flexing the spine. The skin of the posterior neck was prepared and draped in sterile fashion. A local anesthetic was administered with a 26-gauge needle. The epidural space was entered between C4 and C5 to C7 and T1. A 22-gauge 12-cm spinal needle was then advanced into the epidural space, with a midline (Fig. 1) or paramedian (Fig. 2) approach. The side of the paramedian approach was selected to match the symptomatic side. When the needle was just posterior to the spinolaminar line, where it had engaged the ligamentum flavum, test injections of contrast material (Omnipaque 300 [iohexol, 300 mg I/mL]; Amersham Health, Princeton, NJ, USA) were administered while the needle was being advanced until the epidural space was entered. When the contrast material in the needle was spreading in epidural space, we stopped advancing the needle and confirmed that the needle tip was in the epidural space with an additional test injection of contrast agent. Anteroposterior and lateral epidurogram were obtained to document the needle position and to evaluate the extent of opacification. This was followed by the injection of 1 mL of a suspension containing 40 mg of triamcinolone acetonide (Tanceton [40 mg/mL]; Hanall Pharmaceutical, Seoul, Korea) and 1.5 mL of preservative-free normal saline solution.

Image Analysis

All images were reviewed on a picture archiving and communication system workstation monitored by two

musculoskeletal radiologists. The images were analyzed by consensus between the two reviewers. The CT or MRI images were assessed for the cause of radiculopathy: disc

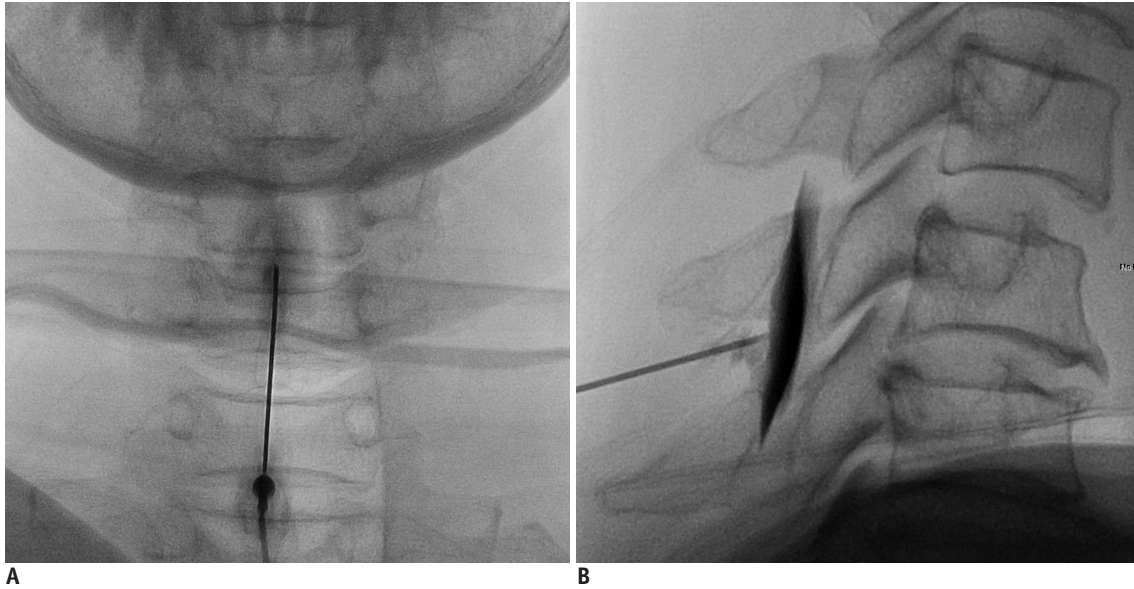


Fig. 1. 68-year-old woman with pain in left shoulder and upper arm for duration of 5 months, due to neural foraminal stenosis. Anteroposterior (A) and lateral (B) epidurogram showing midline approach at C5-6 level, and symmetric spreading of contrast media. One month after cervical interlaminar epidural steroid injection, patient's symptom was much improved with mild residual pain in left shoulder.

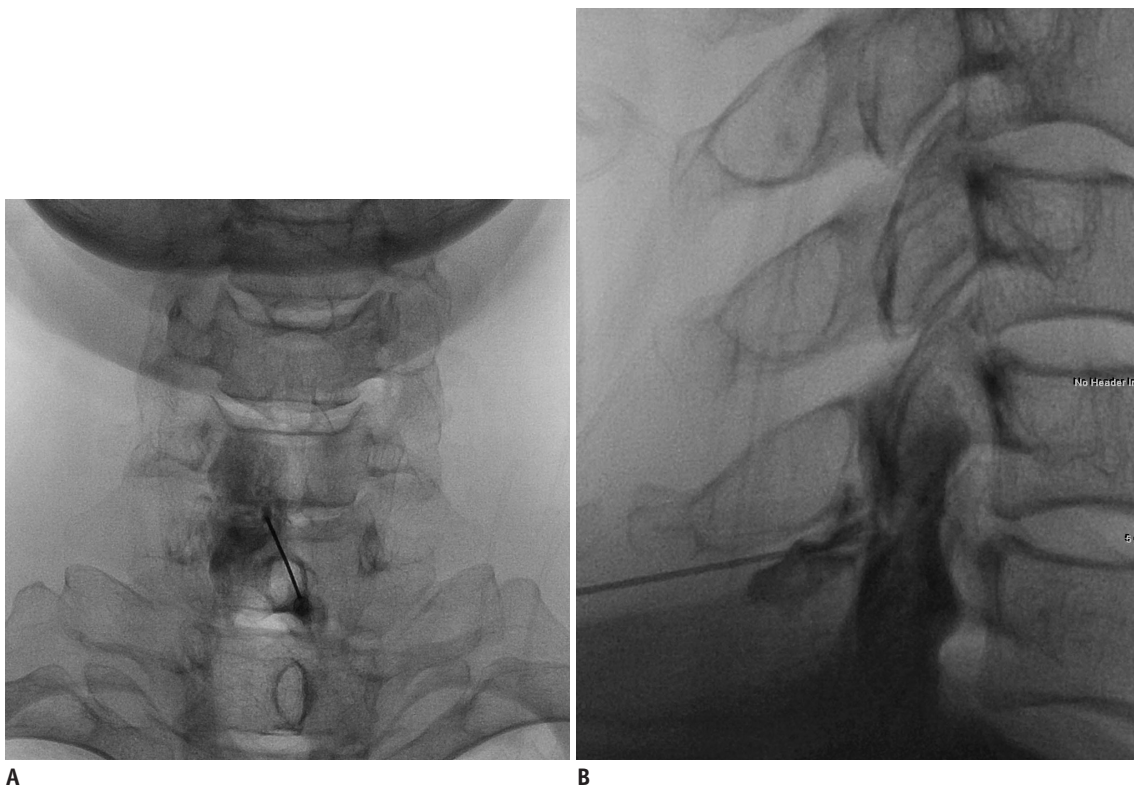


Fig. 2. 41-year-old man with left shoulder pain for duration of 3 months, due to neural foraminal stenosis. Anteroposterior (A) and lateral (B) epidurogram showing left paramedian approach at C6-7 level, and asymmetric spreading of contrast media. This patient had slightly reduced left shoulder pain and tingling sensation, 1 month after cervical interlaminar epidural steroid injection.

herniation versus neural foraminal stenosis. Disc herniation was defined as a localized displacement of disc material beyond the limits of the intervertebral disc space (6). Neural foraminal stenosis was defined as neural foraminal narrowing with uncovertebral joint hypertrophy and facet joint hypertrophy (5). The MR imaging characteristic of a disc herniation was isointense to parent disc on T1-weighted images, and iso- to increased signal intensity on gradient-recall images. An osteophyte or uncovertebral spur appeared as hypointense on T1- and T2-weighted images. On CT examination, disc herniation was in intermediate density similar to the parent disc, and osteophyte or uncovertebral spur had bone density (7). Anteroposterior and lateral fluoroscopic views obtained during CIESI were reviewed for procedure-related problems, such as penetration of the thecal sac or intravascular injection.

Review of Clinical Data

A retrospective review of patients' medical records was performed by an independent researcher. After CIESI, first follow-up was done in the department of radiology, neurosurgery, orthopedic surgery, or rehabilitation within 2 months. Pain intensity was quantified by a horizontal 100-mm visual analog scale (VAS). The treatment outcome of CIESI was also assessed by using five-point outcome scale as follows: 0 (aggravated), 1 (the same as before), 2 (slightly improved), 3 (much improved), and 4 (no residual pain). Effective outcome was defined as at least 50% reduction of VAS score or an outcome scale score of 3 or more after CIESI. The researcher reviewed the medical records of the patients for clinical data including age, gender, duration of radiculopathy, and first follow-up period after CIESI.

For the patients with previously failed CIESI, we reviewed the methods of additional treatments. If the patients had been given an additional transforaminal epidural steroid injection after ineffective CIESI, the effectiveness of the transforaminal injection was also evaluated by the same criteria as CIESI. For the patients with previously successful CIESI, we checked the number of patients who had been given an additional CIESI for the recurrence of the symptoms within one year. Among all of the patients, we counted the number of patients who had undergone an operation after CIESI within one year and described each number of operated patients according to injection approaches.

Statistical Analysis

An independent reviewer provided statistical analysis. Factors such as age, gender, approach technique, duration of radiculopathy, and cause of radiculopathy were evaluated as possible prognostic factors of the treatment effect of CIESI.

Continuous variables were summarized as medians and ranges. Categorical variables were summarized by frequency and percentage. The Mann-Whitney U exact test was used for non-normal continuous variables, and Fisher's exact test was used for categorical variables. Univariate and multivariate logistic regression analysis were used to evaluate potential prognostic factors.

A Mantel-Haenszel test was also performed to control the effects of other possible confounding variables on the effect of CIESI, between the midline and paramedian approaches. A *post hoc* power analysis was performed to calculate the statistical power. A *p* value less than 0.05 was considered statistically significant. Odds ratios are presented with a 95% confidence interval. Statistical analysis was performed using the SPSS software package (version 20.0.; SPSS Inc., Chicago, IL, USA).

RESULTS

In 1157 CIESIs, a total of 182 procedures were included in this study. The patients underwent CIESI with a midline ($n = 69$) or paramedian ($n = 113$) approach. This study included 97 males and 85 females; the median age was 54 years, with a range of 27 to 79 years. The median duration of radiculopathy until the time of the procedure was 3 months, with a range of 3 days to 36 months. The median period of the first follow-up was 20 days, with a range of 5 to 46 days. Disc herniation was found in 82 patients, and neural foraminal stenosis was in 100 patients. Patients with midline approach were significantly older than those with paramedian approach ($p = 0.006$). No statistically significant differences were found between the midline and paramedian approach, with respect to gender, duration of radiculopathy, cause of radiculopathy, and first follow-up period. These results are summarized in Table 1.

Cervical interlaminar epidural steroid injections were effective in 124 of 182 patients (68.1%), and it was ineffective in 58 of 182 patients (31.9%). Five variables were included in the univariate logistic regression analysis for prognostic significance, as listed in Table 2. The only factor significantly associated with clinical outcomes was

the cause of radiculopathy. Sixty eight of 82 patients (82.9%) with disc herniation had effective pain relief, and 56 of 100 patients (56.0%) with neural foraminal stenosis had effective pain relief ($p < 0.001$). We found no significant difference in the clinical outcomes between midline (69.6%) and paramedian (63.7%) approach ($p = 0.749$), at short-term follow-up. *Post hoc* power analysis revealed the power of the study to be 12.3% in detecting a significant difference of clinical outcome between the approaches.

After controlling for the cause of radiculopathy, there was no significant association between the approach technique and clinical outcome ($p = 0.790$). These results are shown in Table 3. After controlling for gender, there was no

significant association between the approach technique and clinical outcomes ($p = 0.896$).

When we controlled for predictive factors using the multivariate logistic regression analysis, cause of radiculopathy was the only significant factor related to the treatment effect of CIESI ($p < 0.001$). CIESI was significantly more efficacious for cervical radiculopathy in disc herniation than in neural foraminal stenosis. There was no significant association between the approach technique and the treatment efficacy, after controlling for any other variables examined ($p = 0.723$). Table 4 summarizes the multivariate logistic regression analysis of the possible predictive factors related to the efficacy of CIESI.

Among the 58 patients who had failed to improve after

Table 1. Baseline Characteristics of Midline and Paramedian Approaches

Parameter	Total (n = 182)	Approach		P
		Midline (n = 69)	Paramedian (n = 113)	
Age (years)*	54 (27–79)	57 (27–79)	52 (27–78)	0.006 [†]
Duration (months)*	3.0 (0.1–36.0)	3.0 (0.1–36.0)	3.0 (0.2–34.0)	0.378 [†]
Follow-up period (days)*	20 (5–46)	20 (5–45)	20 (5–46)	0.922 [†]
Gender [†]				0.285 [§]
Male	97 (53.3)	33 (47.8)	64 (56.6)	
Female	85 (46.7)	36 (52.2)	49 (43.4)	
Cause [†]				0.761 [§]
Disc herniation	82 (45.1)	30 (43.5)	52 (46.0)	
NF stenosis	100 (54.9)	39 (56.5)	61 (54.0)	

*Values were presented as median with range in parentheses, [†]Values were presented as number of patients with percentages in parentheses, [‡]Statistical significances were tested by Mann-Whitney U exact test, [§]Statistical significances were tested by Fisher's exact test. NF = neural foramen

Table 2. Univariate Logistic Regression Results for Predicting Clinical Outcome

Parameter	Category	Effective (n = 124)	Ineffective (n = 58)	Exp (B)	95% CI for Exp (B)	P*
Approach	Midline	48 (69.6%)	21 (30.4%)	1.113	(0.583, 2.123)	0.749
	Paramedian	76 (63.7%)	37 (32.7%)	1		
Gender	Male	65 (67.0%)	32 (33.0%)	0.895	(0.479, 1.674)	0.759
	Female	59 (69.4%)	26 (30.6%)	1		
Cause	Disc herniation	68 (82.9%)	14 (17.1%)	3.816	(1.899, 7.667)	< 0.001
	NF stenosis	56 (56.0%)	44 (44.0%)	1		
Age (years)				0.992	(0.964, 1.021)	0.586
Duration (months)				0.954	(0.910, 1.001)	0.053

*Statistical significances were tested by Fisher's exact test. CI = confidence interval, Exp (B) = estimated odds ratio, NF = neural foramen

Table 3. Association between Technical Approach and Efficacy Stratified by Cause of Radiculopathy

Cause	Approach	Effective	Ineffective	P*	COR [†]	P [‡]
Disc herniation	Midline	27 (90.0%)	3 (10.0%)	0.237	0.859	0.790
	Paramedian	41 (78.8%)	11 (21.2%)			
NF stenosis	Midline	21 (53.8%)	18 (46.2%)	0.837		
	Paramedian	35 (57.4%)	26 (42.6%)			

*Statistical significances were tested by Fisher's exact test, [†]Mantel-Haenszel common odds ratio for approach (paramedian/midline), [‡]Statistical significances were tested by Mantel-Haenszel test of conditional independence. NF = neural foramen

Table 4. Multivariate Logistic Regression Results for Predicting Clinical Outcome

Parameter	Category	Exp (B)	95% CI for Exp (B)		P
			Lower	Upper	
Approach	Midline	1.135	0.564	2.287	0.723
Gender	Male	1.125	0.575	2.201	0.730
Cause	Disc herniation	3.964	1.829	8.592	< 0.001
Age (years)		1.013	0.979	1.048	0.459
Duration (months)		0.972	0.925	1.023	0.279
Constant		0.651			0.683

Estimated odds ratio (after controlling for all other independent variables). CI = confidence interval, Exp (B) = estimated odds ratio

a previous CIESI, 32 patients were given an additional CIESI. Transforaminal epidural steroid injection was done in 14 patients. Nine patients were only prescribed with medications, and three patients underwent operation without additional injection. An additional transforaminal injection was effective in six (42.9%) patients of the 14 patients, and it was ineffective in eight (57.1%) patients. Among the 124 patients with previously successful CIESI, 36 (29.0%) patients were given an additional CIESI for the recurrence of the symptoms within one year. Among all of the patients, operation was performed after the CIESI in 9 (4.9%) out of 182 patients: 3 (4.3%) out of 69 patients with midline approach and 6 (5.3%) out of 113 patients with paramedian approach.

DISCUSSION

In the present study, effective outcome was achieved in 68.1% of patients with CIESI, at short-term follow-up. Several other studies have reported with excellent clinical outcomes in 63% to 83% of cases with cervical epidural steroid injection (8-14). To the best of our knowledge, no study has compared the clinical effects of the midline and paramedian approaches. According to our study, the efficacy of CIESI was 69.6% in the midline approach versus 63.7% in the paramedian approach, which were not significantly different ($p = 0.723$).

The epidural space is a space inside of the spinal canal but outside of the dural sac. It extends from the foramen magnum to the sacral hiatus. The space contains adipose tissue, loose areolar tissue, arteries, lymphatics, venous plexus in abundance, and spinal nerve roots. It is limited posteriorly by the vertebral laminae and the ligamentum flavum, and limited anteriorly by the posterior longitudinal ligament. The lateral border is the pedicle and intervertebral foramen. The epidural space is anatomically subdivided into anterior and posterior compartments. The anterior epidural

space is a fairly well-defined space anteriorly limited by the concavity of the vertebral body, intervertebral disc, and posterior longitudinal ligament, and posteriorly limited by the thecal sac. The posterior epidural space is bordered anteriorly by the thecal sac and posteriorly by the ligamentum flavum and the vertebral laminae (3, 15, 16).

In CIESI, a needle is inserted into the posterior epidural space. The posterior epidural space is triangularly shaped in transverse sections, with its widest part lying posteriorly in the median sagittal plane. The posterior epidural space is filled by a fat pad that becomes narrow towards its lateral margin, and the cervical epidural space is extremely narrow. Above C7-T1 level, no posterior epidural space is evident. A bigger problem with the paramedian approach is that there may not be an approachable epidural space and the intradural space may be more easily entered, which is completely undesirable (3). Thus, midline approaches are considered to be safer than paramedian approaches. In addition, inserting the needle, using a paramedian approach, away from the midline increases the likelihood of facet joint puncture.

When confirming proper needle placement for interlaminar procedures, the spinolaminar line is used as an anatomic landmark. To avoid dural and cord puncture, the needle should not be inserted beyond the spinolaminar line (16). In the paramedian approach, the spinolaminar line is a less reliable anatomic landmark for entering the posterior epidural space. When the needle tip is not midline, it will need to be advanced more ventrally beyond the spinolaminar line, due to the cylindrical shape of the thecal sac (Fig. 3).

The minor complications of CIESI include increased axial pain, non-positional headache, facial flushing, and vasovagal episodes. The major complications include permanent spinal cord injury, epidural hematoma or abscess, dural puncture, and post-dural puncture headache (17). In our series, no symptomatic procedural complications

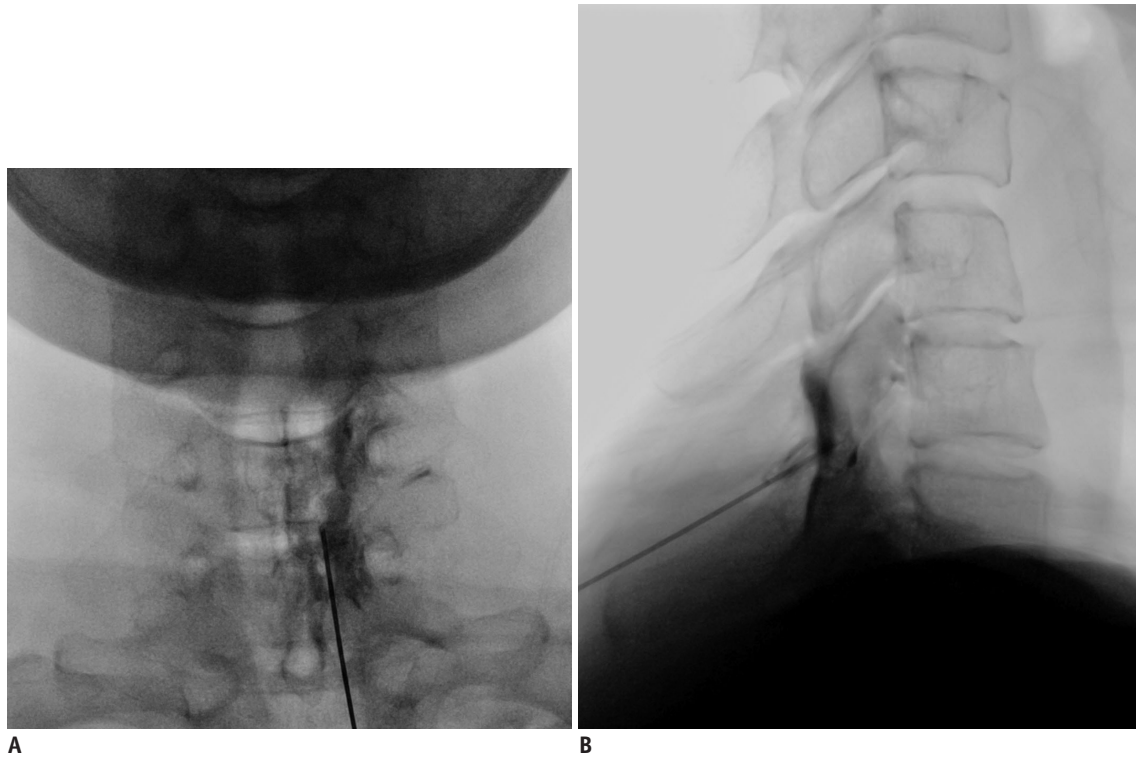


Fig. 3. 60-year-old woman with right shoulder pain for duration of 4 months, due to neural foraminal stenosis. Anteroposterior (A) and lateral (B) epidurogram showing right paramedian approach at C6–7 level, and asymmetric spreading of contrast media. Needle tip is located more ventrally beyond spinolaminar line.

occurred during or after treatment.

In previous studies, investigators have reported with some contradicting results regarding the predictive factors of the efficacy in cervical epidural steroid injection. Kwon et al. (10) showed that the patients with disc herniations showed better response to CIESIs than the patients with spinal stenoses; and Rivest et al. (18) reported with a similar result while discussing about lumbar spine pathologies. However, Fish et al. (19) reported that central canal stenosis is a significant predictor for a better response to CIESI. Ferrante et al. (20) also reported that a radiologic diagnosis of spondylosis or spinal stenosis was associated with good pain relief. Lee et al. (21) showed that the causes of radiculopathy did not make any differences in the clinical outcomes of cervical paramedian interlaminar epidural steroid injections. In our study, we did not evaluate the difference in efficacy of the approach techniques on patients with central canal stenosis. We did find that CIESI was significantly more efficacious in patients with disc herniation, than in those with neural foraminal stenosis. This is probably due to the antigenic effect of nucleus pulposus and local immune response. Clinical and radiologic studies suggest that multiple inflammatory mediators are associated with the pathogenesis of radicular pain due to

nucleus pulposus material (22). Anti-inflammatory effects of steroids had been described many years ago (23), and current studies have reported the anti-inflammatory effect of local anesthetics on cells of the immune system as well as other cells (24).

In addition, there are different research results regarding the influence of age. In transforaminal approach, Lin et al. (9) found that when comparing the patients of 50 years of age or below to males older than 50 years of age, the patients older than 50 years had more favorable outcomes. Ferrante et al. (20) also reported that older patients had significantly better outcomes after cervical epidural steroid injection. Other studies, however, have suggested that age was not a significant predictor of an improved outcome in transforaminal approach (25) and interlaminar approach (10). In this study, no statistically significant difference was found in the efficacy of CIESI with respect to the age of the patients.

Other studies have also evaluated the prognostic factors for cervical epidural injections. Lee et al. (26) concluded that the significant factors predisposing failure of epidural steroid injection were intensity of symptoms and a previous episode of cervical radiculopathy. Lee et al. (25) reported that previous operation was a poor outcome predictor in

transforaminal approach. In this study, we did not evaluate previous episodes of cervical radiculopathy and excluded the patients with previous cervical operation.

There are some limitations to our study. First, it was a retrospective study without a uniform follow-up schedule. Second, there was a lack of data on the long-term pain relief. The results of this study may be helpful when counseling patients for short-term outcomes. Third, treatment effect was measured only by the subjective relief of symptom; there was no objective functional outcome measurement. Fourth, our case definitions for the causes of radiculopathy, disc herniation, and neural foraminal stenosis might have resulted in some misclassifications; but, this is unlikely to introduce biases. Fifth, we excluded the cases of midline approach with asymmetric distribution or paramedian approach with symmetric or contralateral distribution of the injectate, which could have either exaggerated or minimized the impact of either approach in CIESI. In addition, due to the low number of patients, the study was insufficiently powered to detect a statistically significant difference.

We conclude that CIESI with midline or paramedian approach shows similar results in terms of the short-term outcome; therefore, the midline approach may be recommended, especially for the beginners who have difficulty in deciding the proper position for the paramedian approach. CIESI is significantly more efficacious in disc herniation than in neural foraminal stenosis.

REFERENCES

1. Benyamin RM, Singh V, Parr AT, Conn A, Diwan S, Abdi S. Systematic review of the effectiveness of cervical epidurals in the management of chronic neck pain. *Pain Physician* 2009;12:137-157
2. Diwan S, Manchikanti L, Benyamin RM, Bryce DA, Geffert S, Hameed H, et al. Effectiveness of cervical epidural injections in the management of chronic neck and upper extremity pain. *Pain Physician* 2012;15:E405-E434
3. Hogan QH. Epidural anatomy examined by cryomicrotome section. Influence of age, vertebral level, and disease. *Reg Anesth* 1996;21:395-406
4. Lirk P, Kolbitsch C, Putz G, Colvin J, Colvin HP, Lorenz I, et al. Cervical and high thoracic ligamentum flavum frequently fails to fuse in the midline. *Anesthesiology* 2003;99:1387-1390
5. Abbed KM, Coumans JV. Cervical radiculopathy: pathophysiology, presentation, and clinical evaluation. *Neurosurgery* 2007;60(1 Supp 1):S28-S34
6. Fardon DF, Milette PC; Combined Task Forces of the North American Spine Society, American Society of Spine Radiology, and American Society of Neuroradiology. Nomenclature and classification of lumbar disc pathology. Recommendations of the Combined task Forces of the North American Spine Society, American Society of Spine Radiology, and American Society of Neuroradiology. *Spine (Phila Pa 1976)* 2001;26:E93-E113
7. Czervionke LF, Fenton DS. *Imaging painful spine disorders*, 1st ed. Philadelphia: Saunders, 2011:180-187
8. Castagnera L, Maurette P, Pointillart V, Vital JM, Erny P, Sénégas J. Long-term results of cervical epidural steroid injection with and without morphine in chronic cervical radicular pain. *Pain* 1994;58:239-243
9. Lin EL, Lieu V, Halevi L, Shamie AN, Wang JC. Cervical epidural steroid injections for symptomatic disc herniations. *J Spinal Disord Tech* 2006;19:183-186
10. Kwon JW, Lee JW, Kim SH, Choi JY, Yeom JS, Kim HJ, et al. Cervical interlaminar epidural steroid injection for neck pain and cervical radiculopathy: effect and prognostic factors. *Skeletal Radiol* 2007;36:431-436
11. Strub WM, Brown TA, Ying J, Hoffmann M, Ernst RJ, Bulas RV. Translaminar cervical epidural steroid injection: short-term results and factors influencing outcome. *J Vasc Interv Radiol* 2007;18:1151-1155
12. Manchikanti L, Cash KA, Pampati V, Wargo BW, Malla Y. The effectiveness of fluoroscopic cervical interlaminar epidural injections in managing chronic cervical disc herniation and radiculitis: preliminary results of a randomized, double-blind, controlled trial. *Pain Physician* 2010;13:223-236
13. Manchikanti L, Cash KA, Pampati V, Wargo BW, Malla Y. Management of chronic pain of cervical disc herniation and radiculitis with fluoroscopic cervical interlaminar epidural injections. *Int J Med Sci* 2012;9:424-434
14. Manchikanti L, Malla Y, Cash KA, McManus CD, Pampati V. Fluoroscopic cervical interlaminar epidural injections in managing chronic pain of cervical postsurgery syndrome: preliminary results of a randomized, double-blind, active control trial. *Pain Physician* 2012;15:13-25
15. Douglas S, Leo FC. *Image-guided spine intervention*, 1st ed. Philadelphia: Saunders, 2002:99-126
16. Huston CW. Cervical epidural steroid injections in the management of cervical radiculitis: interlaminar versus transforaminal. A review. *Curr Rev Musculoskelet Med* 2009;2:30-42
17. Abbasi A, Malhotra G, Malanga G, Elovic EP, Kahn S. Complications of interlaminar cervical epidural steroid injections: a review of the literature. *Spine (Phila Pa 1976)* 2007;32:2144-2151
18. Rivest C, Katz JN, Ferrante FM, Jamison RN. Effects of epidural steroid injection on pain due to lumbar spinal stenosis or herniated disks: a prospective study. *Arthritis Care Res* 1998;11:291-297
19. Fish DE, Kobayashi HW, Chang TL, Pham Q. MRI prediction of therapeutic response to epidural steroid injection in patients with cervical radiculopathy. *Am J Phys Med Rehabil*

- 2009;88:239-246
20. Ferrante FM, Wilson SP, Iacobo C, Orav EJ, Rocco AG, Lipson S. Clinical classification as a predictor of therapeutic outcome after cervical epidural steroid injection. *Spine (Phila Pa 1976)* 1993;18:730-736
 21. Lee JW, Hwang SY, Lee GY, Lee E, Kang HS. Fluoroscopic cervical paramidline interlaminar epidural steroid injections for cervical radiculopathy: effectiveness and outcome predictors. *Skeletal Radiol* 2014;43:933-938
 22. Goupille P, Jayson MI, Valat JP, Freemont AJ. The role of inflammation in disk herniation-associated radiculopathy. *Semin Arthritis Rheum* 1998;28:60-71
 23. Flower RJ, Blackwell GJ. Anti-inflammatory steroids induce biosynthesis of a phospholipase A2 inhibitor which prevents prostaglandin generation. *Nature* 1979;278:456-459
 24. Cassuto J, Sinclair R, Bonderovic M. Anti-inflammatory properties of local anesthetics and their present and potential clinical implications. *Acta Anaesthesiol Scand* 2006;50:265-282
 25. Lee JW, Park KW, Chung SK, Yeom JS, Kim KJ, Kim HJ, et al. Cervical transforaminal epidural steroid injection for the management of cervical radiculopathy: a comparative study of particulate versus non-particulate steroids. *Skeletal Radiol* 2009;38:1077-1082
 26. Lee SH, Kim KT, Kim DH, Lee BJ, Son ES, Kwack YH. Clinical outcomes of cervical radiculopathy following epidural steroid injection: a prospective study with follow-up for more than 2 years. *Spine (Phila Pa 1976)* 2012;37:1041-1047