

# Paget's disease of bone and megaloblastic anemia in a 72-year-old patient: A case report and systematic literature review

VIOLETA DIANA OPREA<sup>1,2\*</sup>, VIOLETA CLAUDIA BOJINCĂ<sup>3,4</sup>, ANDRA-RODICA BĂLĂNESCU<sup>3,4</sup>,  
ALIN LAURENȚIU TATU<sup>5,6\*</sup>, MIHAI BOJINCĂ<sup>4,7\*</sup> and AURELIA ROMILA<sup>1,2</sup>

<sup>1</sup>Department of Geriatrics and Gerontology, 'St. Apostle Andrei' Clinical Emergency County Hospital, 800578 Galați;

<sup>2</sup>Medical Department, Faculty of Medicine and Pharmacy, 'Dunărea de Jos' University, 800216 Galați;

<sup>3</sup>Department of Internal Medicine and Rheumatology, 'Sf. Maria' Clinical Hospital, 011172 Bucharest;

<sup>4</sup>Department of Internal Medicine, Faculty of Medicine, 'Carol Davila' University of Medicine and Pharmacy,

020021 Bucharest; <sup>5</sup>Clinical-Medical Department, Dermatology, Faculty of Medicine and Pharmacy,

'Dunărea de Jos' University of Galati, ReForm UDJ, 800216 Galați; <sup>6</sup>Department of Dermatology,

'Sf. Parascheva' Clinical Hospital of Infectious Diseases, 800179 Galați; <sup>7</sup>Department of

Internal Medicine and Rheumatology, 'Dr. Ion Cantacuzino' Hospital, 030167 Bucharest, Romania

Received November 30, 2021; Accepted December 30, 2021

DOI: 10.3892/etm.2022.11195

**Abstract.** Paget's disease of bone (PDB) is characterized by abnormal osteoclastic bone resorption with disorganized bone neo-formation, primarily affecting elderly (>55 years) patients. Although the majority of patients are asymptomatic, some patients may experience bone pain due to local periosteal involvement or osteoarthritic lesions in the spine; in addition, limb deformities may lead to secondary gait problems or degenerative joint changes. Anemia has an overall prevalence of 12-17% in elderly adults (>65 years old), with macrocytic anemia being the less common type. Megaloblastic anemia is a macrocytic anemia characterized by the presence of large, immature, nucleated cells (megaloblasts) in the blood, with the most common cause being a deficiency of folate and/or vitamin B12. We herein report the rare case of a 72-year-old

male patient exhibiting both these conditions, with the aim of discussing the possible association between the two and, most importantly, the clinical management of the patient in a real-life setting over a period of 10 years. The patient was diagnosed based on clinical symptoms (bone pain), radiological imaging and specific laboratory tests, and received discontinuous courses of bisphosphonates and cyanocobalamin supplementation therapy, based mainly on aggravated symptomatology. A systematic literature review was also performed and revealed not only the scarcity of reports on similar cases, but also the mechanisms that may underlie the possible association of PDB with macrocytic anemia due to vitamin B12 deficiency in elderly patients.

## Introduction

Paget's disease of bone (PDB), also known as 'osteitis deformans', is a condition associated with bone fragility and a high risk of bone fractures in affected patients (1-5). This disease most often affects older individuals, occurring in 2-3% of the population aged >55 years, and is the second most common bone remodeling disease after osteoporosis (1,6,7). Epidemiological studies indicate significant geographical differences as well as a decreasing prevalence of PDB over the last 20 years (1,6-9). The causes are not well understood, but possible explanations may involve genetic variance, changes in lifestyle and diet, and decreasing exposure to certain viral infections (including availability of vaccination against measles) (9,10). As elderly patients are already at a higher risk of accidental falls, PDB further increases their risk of bone fractures and subsequent prolonged bed rest and immobilization, which inevitably lead to further complications (1,3). PDB is characterized by increased osteoclastic bone resorption, increased but disorganized bone formation and increased bone vascularity, with abnormal osteoclasts that secrete high levels of IL-6 and induce exuberant bone formation (1,2). The altered

---

*Correspondence to:* Dr Violeta Claudia Bojinca or Dr Andra-Rodica Bălănescu, Department of Internal Medicine and Rheumatology, 'Sf. Maria' Clinical Hospital, 37-39 Ion Mihalache Blvd, 011172 Bucharest, Romania  
E-mail: vmbojinca@yahoo.com  
E-mail: balanescu.andra@gmail.com

\*Contributed equally

*Abbreviations:* ALP, alkaline phosphatase; GWAS, genome-wide association studies; Hb, hemoglobin; HLA, human leukocyte antigen; HCY, homocysteine; IF, intrinsic factor; MCH, mean corpuscular hemoglobin; MCV, mean corpuscular volume; PDB, Paget's disease of bone; RANKL, receptor activator of NF-κB ligand; ULN, upper limit of normal

*Key words:* Paget's disease of bone, alkaline phosphatase, megaloblastic anemia, vitamin B12, folic acid, bisphosphonates

bone remodeling leads to the development of unstructured, fibroblastic tissue that is mechanically frail and brittle (1,11). Medical research findings suggest that the etiopathogenesis of PDB may be associated with infectious factors (such as paramyxoviruses), genetic factors [the sequestosome 1 (SQSTM1) gene has been found to be an important cause of familial PDB] and environmental factors (such as arsenic used in pesticides) (1,10,12).

The majority of patients ( $\geq 70\%$  as reported by some authors) are asymptomatic (12); however, when clinically overt, PDB is associated with bone pain, osteoarthritis, musculoskeletal deformities, hypervascularity resulting in excessive warmth, neurological complications and heart failure (2,3).

Megaloblastic anemia is characterized by the presence of large, immature, nucleated cells (megaloblasts) in the blood (4). Megaloblastic anemia is mainly caused by vitamin B12 or folic acid deficiency (3,5), which is most likely due to decreased intake or increased demand (such as malabsorption), but may also be caused by autoimmune or congenital intrinsic factor deficiency, which is known as pernicious anemia (3). 'Pernicious' is a term with a Latin root that means highly injurious or deadly, as this condition was fatal before identifying the cause and subsequently designing appropriate therapies (13).

In the present study, a systematic literature research was performed to identify scarce resources and reports on the possible association of PDB with megaloblastic anemia (13-15), as some authors have suggested a common autoimmune mechanism underlying both diseases (16).

The aim of the present study was to report a rare case of a patient exhibiting both these conditions, discuss the clinical management of the patient in a long-term real-life setting, and also discuss the possible association between the two based on the findings of the present case and those of the systematic literature review.

## Case report

A 72-year-old male patient who was previously diagnosed with polyostotic PDB associated with megaloblastic anemia, spine osteoarthritis, hypertension and type II diabetes, was admitted in February 2021 at the Department of Internal Medicine and Rheumatology of 'St. Maria' Clinical Hospital (Bucharest, Romania). The patient complained of low back pain, chronic pain in the left calf and knee, with genu varus deformation, asthenia and fatigue (Fig. 1).

The patient was initially diagnosed in 2010 at another medical facility, at the age of 62 years, with macrocytic anemia [hemoglobin (Hb)=11.4 g/dl (normal range, 13.0-17.5 g/dl) and mean corpuscular volume (MCV)=130 fl, which was 30% above the upper limit of normal (ULN)] due to hypovitaminosis B12 ( $< 150$  pg/ml), hyperostotic disease and hyperemic gastritis. The patient's symptoms at the time of diagnosis were left knee pain, epigastric pain and fatigue. The fecal occult blood test was positive and the radiological examination revealed a thickening of the left femoral bone and distal epiphysis, with non-homogeneous osteocondensation and distal lamellar periosteal reaction of the femoral shaft. Endoscopic examination revealed diffuse hyperemic gastritis with a single gastric polyp; the biopsy

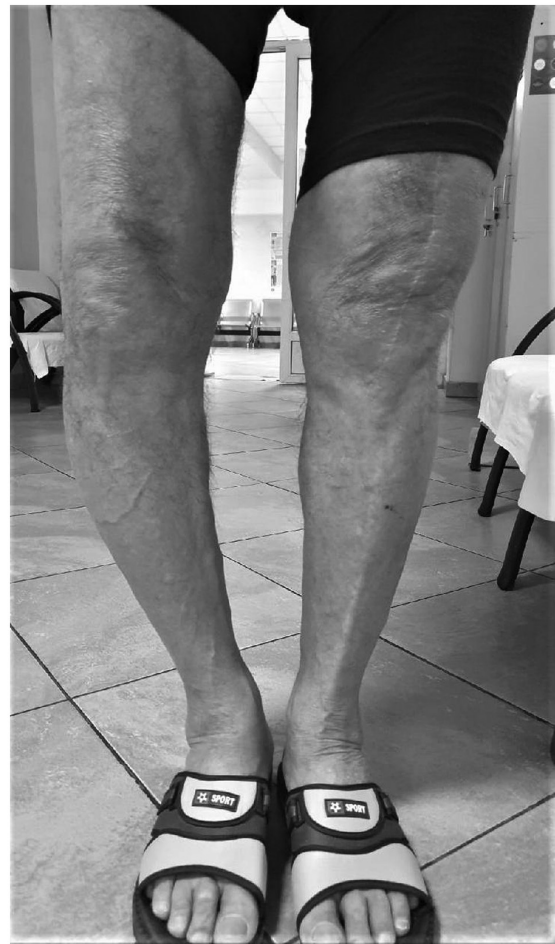

Figure 1. Clinical presentation upon hospital admission in 2021, 10 years after the initial diagnosis. The image demonstrates bowlegs with stiffness of both knees. The patient also experiences bone pain at the lumbar and calf level.

and subsequent histological examination revealed epithelial tissue without dysplasia.

The patient was then referred to The Department of Internal Medicine and Rheumatology of 'Sf. Maria' Clinical Hospital in Bucharest (Romania) for further investigations. There was no evidence of the mechanism underlying the megaloblastic anemia with vitamin B12 deficiency (parietal cell antibodies or intrinsic factor determination). After the confirmation of the diagnosis, the patient was started on vitamin B12 supplementation therapy, pamidronic acid and calcitonin nasal spray. The serum alkaline phosphatase (ALP) level at diagnosis was 2,743 UI/l (normal reference range, 40-150 U/l), and it decreased to 1,553 UI/l after the first course of therapy with pamidronate 30 mg IV infused over 4 h for 2 consecutive days. At 1 year after the diagnosis and after two courses of pamidronate, the ALP level had decreased to 394.03 UI/l and the clinical symptomatology related to PDB had diminished.

Due to aggravation of the left knee functional impairment with severe pain, the patient was subjected to arthroplasty 3 years after PDB was first diagnosed (March 2014).

Radiological images obtained during a medical evaluation in 2014 revealed progressive bone disease at the cranial level [two osteocondensation zones of the skull cap and flattening of the skull base with increased dimensions of the sella turcica

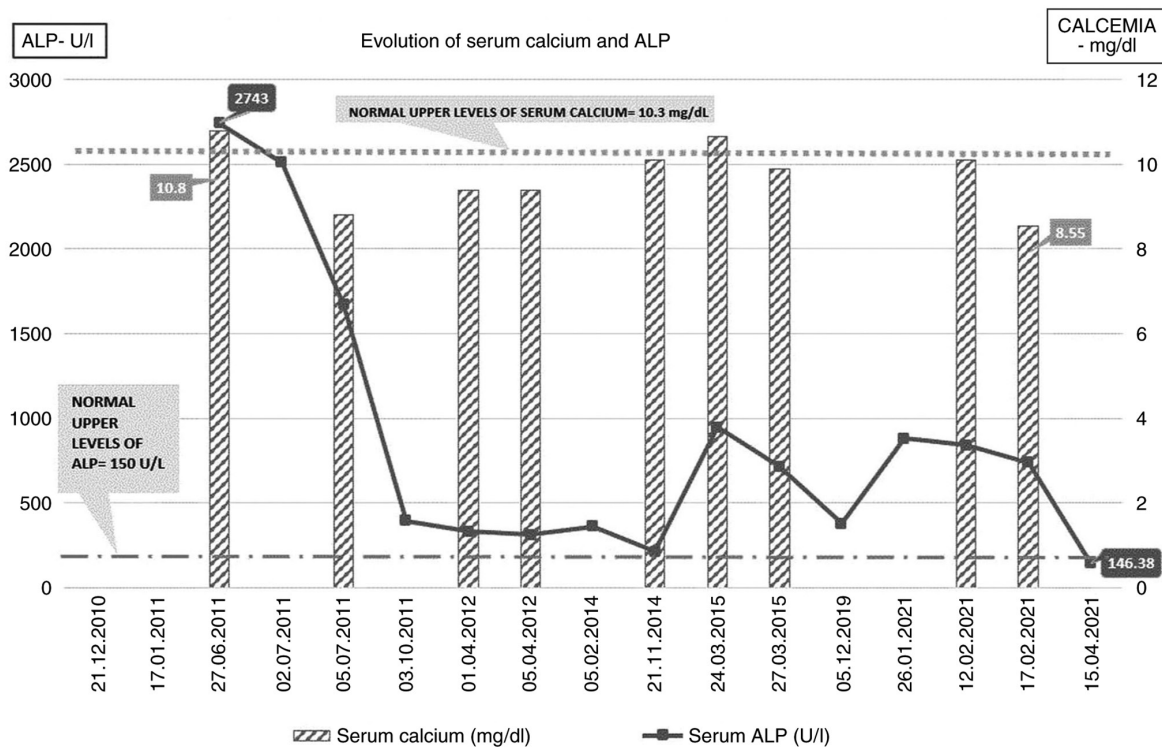


Figure 2. Serum calcium and ALP levels of the patient over the course of Paget's disease of bone. ALP, alkaline phosphatase.

(antero-posterior diameter of 15 mm)] and in the right femur and fibula. The Hb levels were normal (14.1 g/dl), but macrocytosis was present (MCV=112.8 fl). Another pamidronic acid course was administered and the continuation of vitamin B12 supplementation was recommended. Repeated superior digestive endoscopy revealed persistence of hyperemic gastritis and two sessile gastric polyps (no dysplasia was observed following biopsy and histological examination). The patient was referred for a cardiological examination due to a systolic murmur, which revealed moderate aortic stenosis.

In March 2015, the patient had only mild macrocytosis, but the ALP levels had increased again to 947 U/l (>3 times the ULN) and the serum calcium level was also increased (10.66 mg/dl; normal range 8.1-10.4 mg/dl). The patient received another infusion of pamidronate, after which the ALP level decreased to 715 U/l.

Due to personal reasons, the patient did not attend the scheduled follow-up visits until December 2019 (intermittent vitamin B12 supplementation and two courses of pamidronate therapy were administered between 2015 and 2019), at which time the laboratory findings revealed macrocytic anemia [Hb=12 g/dl; MCV=142 fl; mean corpuscular Hb (MCH)=47.1 pg (normal range, 27-34 pg)] with vitamin B12 deficiency (serum level of 95 pg/ml), normal plasma level of folic acid (23.97 ng/ml) and active PDB, with ALP=380 U/l (normal range, 40-150 U/l). As regards the cardiovascular status, the degree of the aortic stenosis had progressed to 'severe', and the patient also suffered from recurrent chest pain (spontaneous and related to physical effort) (Fig. 2).

In January 2021, the patient was again admitted to 'St. Maria' Clinical Hospital (Bucharest, Romania) at the age of 72 years, with complaints of back pain and bilateral knee pain,

with a significant gait deficit. The laboratory parameters were as follows: Serum ALP=840 U/l, with normal calcium and Hb levels and mild macrocytosis (MCV=103.8 fl, MCH=36.4 pg) (Fig. 3).

The radiological assessment revealed progression of the skull osteolytic lesions, as well as specific coarsening of the trabeculae and cortical thickening of the femoral and fibular bones, with the most notable lesions observed in the right calf. There was also posterior vertebral osteophytosis at L3-L4 and L5-S1, slight retrolisthesis at L2, alterations of the bone structure in the sacrum significant for PDB, with condensation of trabeculae at the periphery (Fig. 4).

The left knee prosthesis was well-positioned and functional, despite the significant deterioration of the leg bones (Fig. 5).

Following an infusion course of zoledronic acid (a single 4 mg intravenous infusion) and analgesics (paracetamol 1 g daily for 5 days), the ALP level slightly decreased to 739 U/l and the symptoms improved, so the patient was discharged with recommendations for specific therapy (iron supplement 100 mg daily, vitamin D 2000 IU daily, metoprolol 50 mg daily) at home for anemia and hypertension, as well as vitamin B12 supplementation. After 3 months, the patient underwent laboratory tests with the family physician, and the serum ALP level was 146.38 U/l (~20% over the ULN), while he reported improvement of the bone-related symptoms (Fig. 6).

## Discussion

PDB is usually diagnosed in patients aged >50 years, most of whom are asymptomatic (1,2,17). The prevalence of PDB exhibits notable geographic variability, with the highest

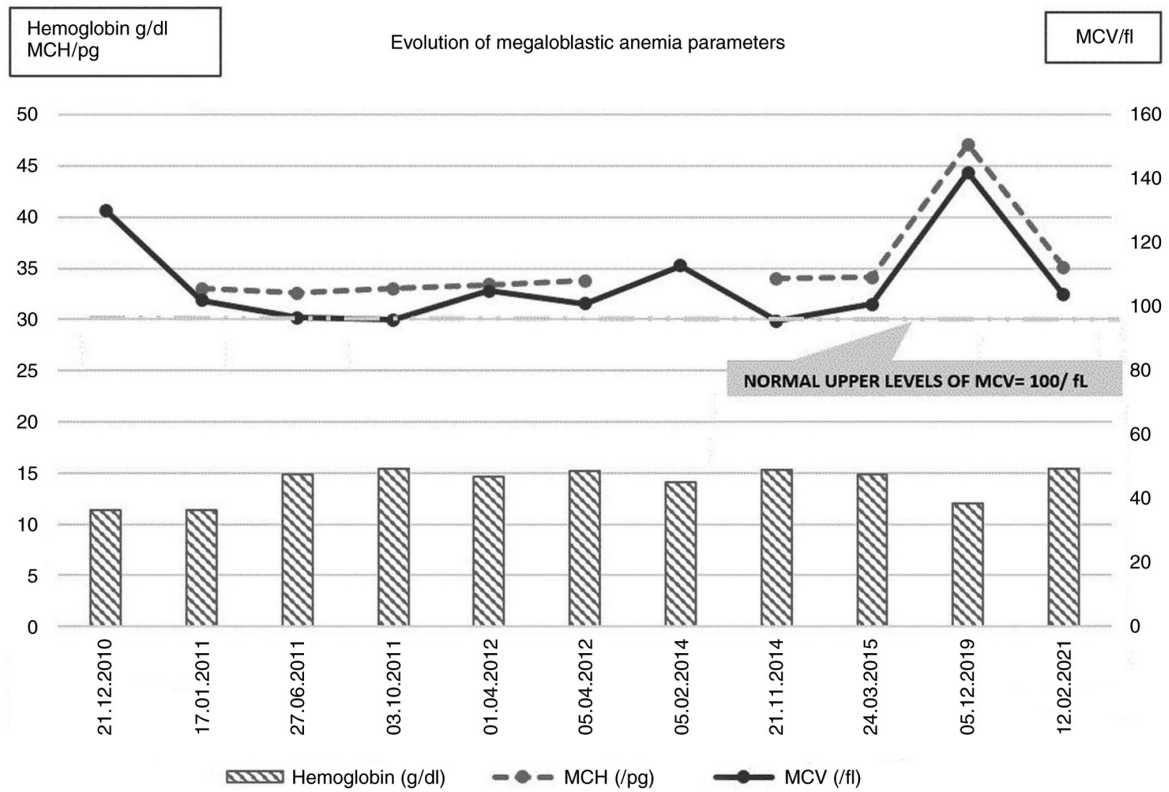


Figure 3. Levels of hemoglobin, MCV and MCH of the patient over the course of megaloblastic anemia. MCH, mean corpuscular hemoglobin; MCV, mean corpuscular volume.

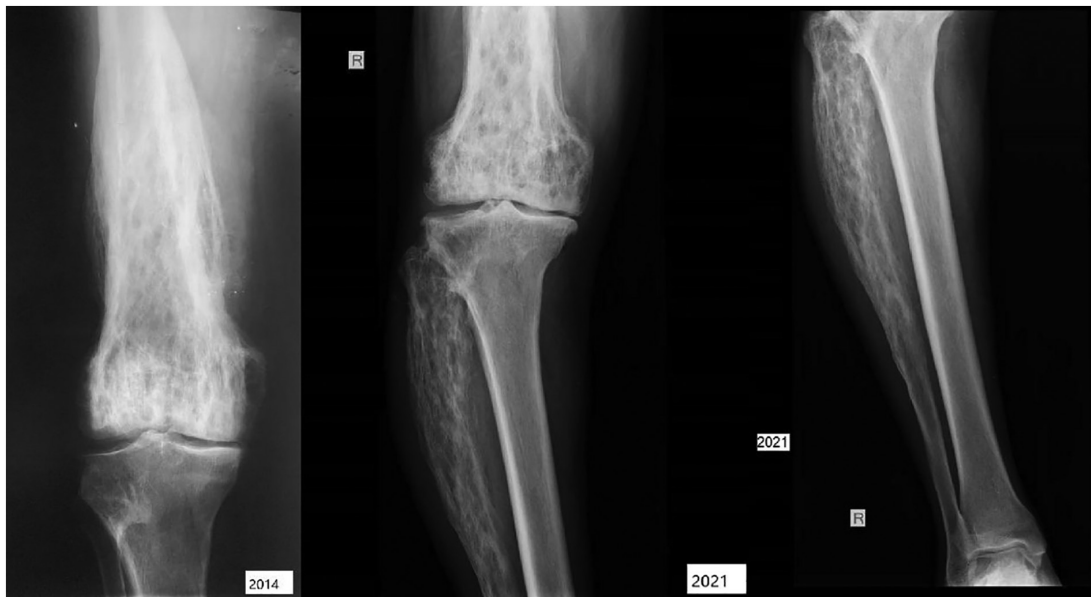

Figure 4. Radiological imaging of the right leg showing an appearance specific to Paget's disease of bone. The scan demonstrates wedge area of osteolysis in diaphysis, coarsened trabeculae, osteolysis and blade-of-grass appearance of tibia. Comparison of examinations between 2014 (left panel) and 2021 (right panel).

prevalence documented in Europe (predominantly England, France and Germany) (7-9,17,18). The geographic distribution of the disease may be explained by genetic transmission and dissemination by population migration. Studies have reported a positive family history in 12.3-22.8% of the cases (7,9). In addition, a 7- to 10-fold increase in the incidence of PDB was

observed in relatives of patients diagnosed with this condition compared with control groups (10). Numerous studies have described families exhibiting autosomal dominant inheritance (2,12). Studies of potential genetic markers for PDB have identified an association between human leukocyte antigen (HLA)-A, HLA-B and HLA-C (class I) and clinical evidence

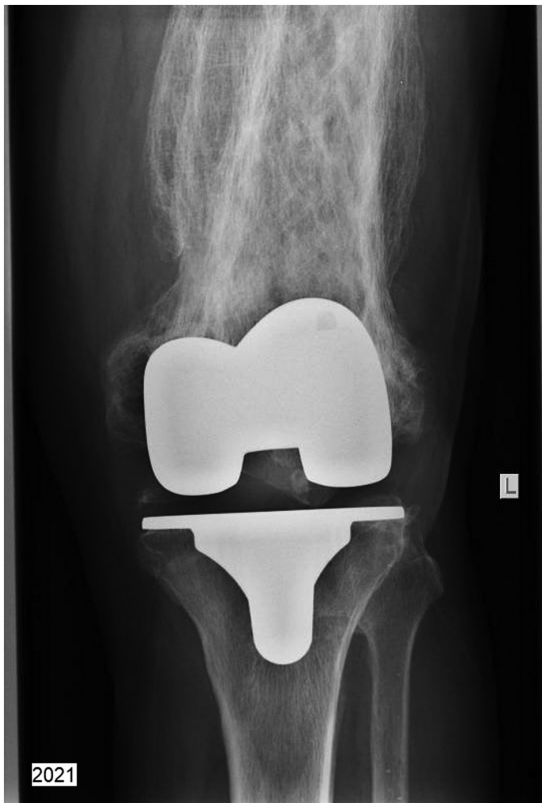

Figure 5. Radiological imaging of the left knee 7 years after a functional arthroplasty on pagetic bone.

of the disease, but other trials reported an increased frequency of DQW1 and DR2 antigens (class II HLA) (2,19-22). Genome-wide association studies (GWAS) have identified several loci involved in the development of the disease, with two regions studied in detail: The optineurin and Ras and Rab interactor 3 genes (10,19,23).

It has been proven that environmental factors play an important role in PDB (10,12). Altered cytokine expression was identified in cases of PDB (19,23). One hypothesis is based on an unidentified viral infection that acts through upregulation of IL-6 and the IL-6 receptor genes (19,20,23); however, this has not been shown conclusively. The slow virus theory is the most widely accepted hypothesis for an infectious etiology in PDB (21,22). According to this theory, progenitors of osteoclasts from the bone marrow are infected by a virus, resulting in abnormal activation of osteoclast growth (21,22,24).

Osteoclast precursors in patients with PDB also appear to be hyperresponsive to vitamin D and calcitonin (11). The treatment efficacy of bisphosphonates in PDB appears to be associated with suppression of receptor activator of NF- $\kappa$ B ligand (RANKL)-induced bone resorption (1,11), with lower RANKL levels and increased production of osteoprotegerin (22,25).

Other suggested etiologies, based on strong clinical and research evidence, include an inflammatory cause, which is also supported by evidence of clinical improvement after treatment with anti-inflammatory agents (21,22). Elevated parathyroid hormone levels have been observed in PDB (26), while autoimmune, connective tissue and vascular disorders or an osteogenic mechanism have been also proposed (3,12,22).

Case reports of PDB in the literature have presented other associated pathologies (16,26-28), including vitiligo, chronic kidney disease (29), rheumatoid arthritis (16), tumor and tumor-like conditions; specifically, <5% of patients with PDB will undergo malignant transformation to sarcoma (30), but more extensive disease and a more prolonged course are associated with higher risk of eventually developing a sarcoma (31) (Fig. 7).

During the course of PDB the patients may develop complications and comorbidities (12), such as fractures, neuromuscular syndromes, autoimmune thyroiditis (28), Dupuytren contracture, chondrocalcinosis, hyperparathyroidism (26), cardiovascular abnormalities (22), hypoacusia (2) and osteosarcoma (30). The patient presented herein developed several of those over time as follows: i) Dupuytren contracture in both hands was noted at diagnosis in 2011, with the severity progressing from the 5th finger to grade 2-3 in fingers 2-5 bilaterally; ii) the patient reported progressive hearing loss over the last 6 years; iii) severe gonarthrosis, particularly in the left knee, requiring an arthroplasty 3 years after diagnosis; and iv) cardiovascular symptoms that became progressively more severe, particularly stage II hypertension preexisting to the PDB diagnosis in 2010; in 2019 a moderate aortic stenosis was documented, together with a mild left ventricular hypertrophy; the latter is commonly seen in PDB (2) and is associated with increased cardiac output.

Megaloblastic anemia was also present at the time of PDB diagnosis in 2010, documented by a complete blood count revealing anemia with macrocytosis and megaloblasts in the peripheral blood due to a deficit of vitamin B12; due to intermittent cyanocobalamin supplementation, the vitamin B12 deficiency was recurrent. Vitamin B12 and folic acid deficiency is the leading cause of megaloblastic anemia (13), but dietary deficiency due to decreased intake did not appear to be the case for our patient. Specific medical evaluation after the initial diagnosis revealed diffuse hyperemic gastritis with the presence of benign gastric polyps, and several years later a hiatal hernia was identified during routine endoscopy. It was therefore hypothesized that impaired absorption of vitamin B12 may have been the cause of this chronic deficit.

A systematic literature review was performed using the key words 'Paget's disease of bone', 'macrocytic anemia', 'megaloblastic anemia' and 'vitamin B12' using PubMed/MEDLINE and Google Scholar. A total of 4,651 articles were identified, which were analyzed following PRISMA criteria (32) with focus on those referring to anemia associated with PDB. There is limited available evidence on the association between PDB and megaloblastic anemia, with <20 cases in total cited in the literature to date, including an 8-case series report published in 1968 (33). The authors of this 1968 article aimed to draw attention to the malabsorption syndrome associated with PDB and introduced an interesting theory of impaired folate absorption due to reduced splanchnic blood flow with relative ischemia of the bowel, in the context of the significant increase of the bone blood flow during extensively active PDB (33). Prevalent comorbidities reported in PDB are associated with the manifestations of the disease in elderly patients, with the most frequent associations being with cardiovascular pathologies, such as hypertension, atrial fibrillation and other arrhythmias, ischemic heart disease and stroke (12,22), and

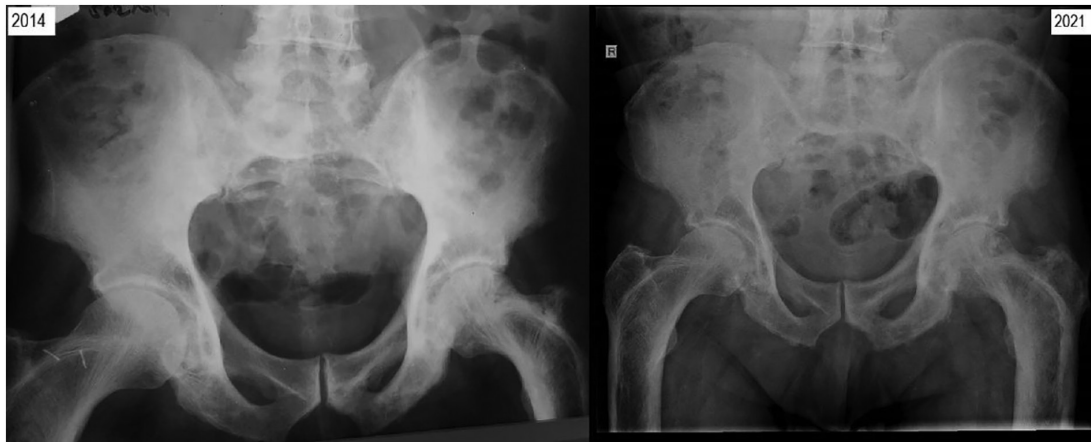


Figure 6. Radiological imaging of the pelvic bones showing findings specific to Paget's disease. The scans demonstrate coarsening of the trabeculae and cortical thickening, osteolytic and osteosclerotic lesions, loss of the joint space, especially in the left hip of the 2021 image (right panel). Comparison of examinations between 2014 (left panel) and 2021 (right panel).

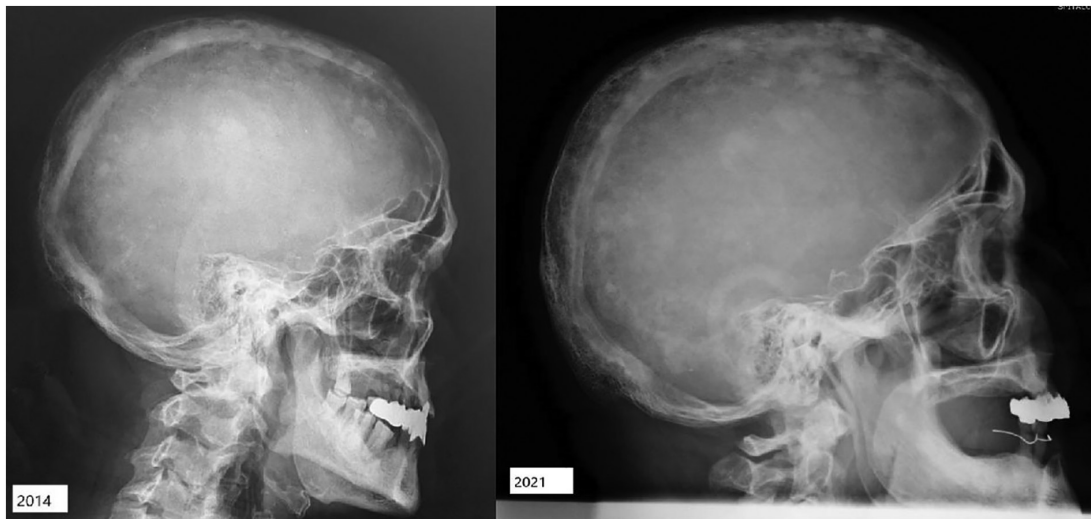

Figure 7. Radiological imaging of the skull showing findings specific to Paget's disease. The scans show focal sclerosis with cotton-wool appearance and calvarial thickening. Comparison of examinations between 2014 (left panel) and 2021 (right panel).

neurodegenerative disorders, such as Parkinson's Disease, cranial nerve palsies and frontotemporal dementia (11).

Evidence regarding the rare comorbidity of Biermer's anemia and PDB also comes from a short list of relevant publications: A case report of an icteroedematous form of pernicious anemia and PDB in 1951 (27), a review of the available literature at the time of publication of a possible association of PDB and pernicious anemia in 1970 (13), as well as a case report of a patient with PDB, pernicious anemia and vitiligo in 1986 (14). All these reports promote the hypothesis that PDB may be an autoimmune disease sharing some common underlying mechanisms with other immune-mediated disorders (13,14,34-36).

A literature review showed evidence of the association among vitamin B12 and/or folate, homocysteine (HCY) and osteoblastic and osteoclastic activity, and suggested the use of these biomarkers to assess bone metabolism (e.g., in osteosarcoma) (37-39). An analysis published in 1964 (40) focused on the decrease in ALP serum levels following vitamin B12

supplementation therapy in patients with pernicious anemia, based on the case of a patient suffering from both pernicious anemia and PDB. The authors noted that the patient had normal serum levels of ALP, which increased after the initiation of the cyanocobalamin therapy, while vitamin B12 supplementation suppressed osteoblastic activity (40).

Vitamin B12 deficiency is more prevalent in elderly patients (37,38,41,42), causing an increase in the serum levels of HCY and methylmalonic acid (37). An interesting study published in 2010 (43) evaluated the serum levels of HCY, folate and vitamin B12 in patients with PDB, and examined the effect of zoledronic acid on these serum levels. Existing data suggest that hyperhomocysteinemia (and, indirectly, deficiency of folate and vitamin B12 through increased serum HCY levels) may constitute an important risk factor for osteoporosis and associated fractures, as it adversely affects bone quality by stimulating bone resorption and affecting the physiology of collagen crosslinking (24,43). In the aforementioned study (42), higher serum HCY and folate

levels were observed in the patients with PDB compared with the control group.

In the present case, no genetic tests were available and the patient was unable to recall any relevant family history. The literature review showed that, to date, 7 loci have been associated with PDB, with SQSTM1 mutations found by GWAS in 20-50% of the patients (22). Vitamin B12 deficiency may also lead to increased osteoclast formation indirectly through increasing HCY levels (37). It has been demonstrated that combined treatment with folate and vitamin B12 was effective in reducing serum HCY and the risk of hip fractures in elderly patients after stroke, without affecting bone mineral density (24). Hyperhomocysteinemia is a common age-related finding (24). The main causes of hyperhomocysteinemia in elderly individuals include folate and vitamin B12 deficiency, as well as deterioration of renal function (37,38). HCY is known to modulate this process via several known mechanisms, such as increase in osteoclast activity, decrease in osteoblast activity and direct action on bone matrix (43-45). The patient in the present case exhibited no renal impairment and the onset of both anemia and bone-related symptoms was dated to before the initiation of bisphosphonate therapy.

As regards PDB, research should focus on in-depth analysis of the mechanisms underlying this disorder, identifying any possible correlations with other comorbidities, immune-related or other (21,43), and broadening the opportunities of identifying a possible adjuvant therapy beyond bisphosphonates (44-46). There is a pressing need to fully elucidate the pathogenesis of this illness and to find modalities to prevent long-term complications.

PDB is the second most common metabolic bone disorder after osteoporosis, with a high prevalence among elderly patients (12). Due to the limited and non-specific symptoms that may not appear until late in the course of the disease, it remains underdiagnosed and undertreated (11,17). Although a significant proportion of patients who present with the pathognomonic features related to PDB are asymptomatic (1,17), we herein present a case of a symptomatic patient with associated macrocytic anemia, both manifesting specific characteristics at the time of initial diagnosis. The primary cause of the anemia was identified as hypovitaminosis B12, but with no proven underlying cause. A trigger for PDB onset or a relevant family history was not reported for this patient. Common underlying mechanisms linking these two disorders have yet to be definitively determined, but possible associations have been suggested and hypotheses have been made based on similar case reports in the literature (13-16,27,43,44). Special attention should be paid to associated anemia in elderly patients diagnosed with PDB, irrespective of the presence or absence of bone-related symptoms. The 10-year-long real-life medical history of the present case is indicative of the significance of the adherence of patients with chronic conditions to medical follow-up in association with symptomatology, and the impact on their quality of life. Further research focused on the etiopathogenesis of both PDB and megaloblastic anemia may help improve therapy outcomes for such patients.

#### Acknowledgements

Not applicable.

#### Funding

No funding was received.

#### Availability of data and materials

The datasets used and/or analyzed during the current study are available from the corresponding author on reasonable request.

#### Authors' contributions

VDO, VCB, MB and ALT wrote the case report, diagnosed and monitored the patient, and conceived the work. VDO, VCB and ARB confirm the authenticity of the raw data. VCB, ARB and AR interpreted the data and critically revised the manuscript for important intellectual content. All the authors have read and approved the final manuscript and agree to be accountable for all aspects of the work.

#### Ethics approval and consent to participate

Not applicable.

#### Patient consent for publication

Written informed consent was obtained from the patient for the publication of anonymized data and any accompanying images.

#### Competing interests

The authors declare that they have no competing interests.

#### References

- Shaker JL: Paget's disease of bone: A review of epidemiology, pathophysiology and management. *Ther Adv Musculoskelet Dis* 1: 107-125, 2009.
- Ralston SH, Corral-Gudino L, Cooper C, Francis RM, Fraser WD, Gennari L, Guañabens N, Javaid MK, Layfield R, O'Neill TW, *et al*: Diagnosis and management of Paget's disease of bone in adults: A clinical guideline. *J Bone Miner Res* 34: 579-604, 2019.
- Appelman-Dijkstra NM and Papapoulos SE: Paget's disease of bone. *Best Pract Res Clin Endocrinol Metab* 32: 657-668, 2018.
- Mohamed M, Thio J, Thomas RS and Phillips J: Pernicious anaemia. *BMJ* 369: m1319, 2020.
- Aslinia F, Mazza JJ and Yale SH: Megaloblastic anemia and other causes of macrocytosis. *Clin Med Res* 4: 236-241, 2006.
- Doyle T, Gunn J, Anderson G, Gill M and Cundy T: Paget's disease in New Zealand: Evidence for declining prevalence. *Bone* 31: 616-619, 2002.
- Poór G, Donáth J, Fornet B and Cooper C: Epidemiology of Paget's disease in Europe: The prevalence is decreasing. *J Bone Miner Res* 21: 1545-1549, 2006.
- Abdulla O, Naqvi MJ, Shamshuddin S, Bukhari M and Proctor R: Prevalence of Paget's disease of bone in Lancaster: Time for an update. *Rheumatology (Oxford)* 57: 931-932, 2018.
- Michou L and Orsel P: Has Paget's bone disease become rare? *Joint Bone Spine* 86: 538-541, 2019.
- Singer FR: Paget's disease of bone-genetic and environmental factors. *Nat Rev Endocrinol* 11: 662-671, 2015.
- Cook SJ and Wall C: Paget's disease of bone: A clinical update. *Aust J Gen Pract* 50: 23-29, 2021.
- Paul Tuck S, Layfield R, Walker J, Mekkayil B and Francis R: Adult Paget's disease of bone: A review. *Rheumatology (Oxford)* 56: 2050-2059, 2017.

13. Govindaraj M and Krishnan MU: Possible association of Paget's disease of bone and pernicious anaemia. *Gerontol Clin (Basel)* 12: 94-98, 1970.
14. Mavrikakis ME, Athanassiades P, Baltopoulos G, Rassidakis A and Rokas S: Paget's bone disease, anaemia and vitiligo: A case report. *Clin Exp Rheumatol* 4: 57-59, 1986.
15. Beickert A and Heinicke HJ: Simultaneous occurrence of Biermer's disease and Paget's disease. Observations of 5 associated cases. 1 Of them with vitiligo. *Dtsch Gesundheitsw* 26: 579-583, 1971 (In German).
16. Borz-Baba C, Sachan Y, Sapers B and Georgescu L: A case of rheumatoid arthritis and Paget disease of bone. *Am J Case Rep* 20: 764-769, 2019.
17. Hadjipavlou AG, Gaitanis IN and Kontakis GM: Paget's disease of the bone and its management. *J Bone Joint Surg Br* 84: 160-169, 2002.
18. Menéndez-Bueyes LR and Soler Fernández MC: Paget's disease of bone: Approach to its historical origins. *Reumatol Clin* 13: 66-72, 2017 (In English, Spanish).
19. Hughes AE, Shearman AM, Weber JL, Barr RJ, Wallace RG, Osterberg PH, Nevin NC and Mollan RA: Genetic linkage of familial expansile osteolysis to chromosome 18q. *Hum Mol Genet* 3: 359-361, 1994.
20. Niculet E, Chioncel V, Elisei AM, Miulescu M, Buzia OD, Nwabudike LC, Craescu M, Draganescu M, Bujoreanu F, Marinescu E, *et al*: Multifactorial expression of IL-6 with update on COVID-19 and the therapeutic strategies of its blockade (Review). *Exp Ther Med* 21: 263, 2021.
21. Galson DL and Roodman GD: Pathobiology of Paget's disease of bone. *J Bone Metab* 21: 85-98, 2014.
22. Alonso N, Calero-Paniagua I and Del Pino-Montes J: Clinical and genetic advances in Paget's disease of bone: A review. *Clin Rev Bone Miner Metab* 15: 37-48, 2017.
23. Hoyland JA, Freemont AJ and Sharpe PT: Interleukin-6, IL-6 receptor, and IL-6 nuclear factor gene expression in Paget's disease. *J Bone Miner Res* 9: 75-80, 1994.
24. Van Wijngaarden JP, Doets EL, Szczecińska A, Souverein OW, Duffy ME, Dullemeijer C, Cavelaars AE, Pietruszka B, Van't Veer P, Brzozowska A, *et al*: Vitamin B12, folate, homocysteine, and bone health in adults and elderly people: A systematic review with meta-analyses. *J Nutr Metab* 2013: 486186, 2013.
25. Drake MT, Clarke BL and Khosla S: Bisphosphonates: Mechanism of action and role in clinical practice. *Mayo Clin Proc* 83: 1032-1045, 2008.
26. Panuccio VA and Tripepi R: Paget's disease and secondary hyperparathyroidism: Is healing possible? *Front Cell Dev Biol* 8: 399, 2020.
27. Malamud T and Rosenfeld I: Icteroedematous form of pernicious anemia in Paget's disease of the bone. *Prensa Med Argent* 38: 1164-1166, 1951 (In Undetermined Language).
28. Punzi L, Avossa M, De Zambiasi P, Volpe A, Cesaro G, Schiavon F and Todesco S: Paget's disease of bone associated with autoimmune thyroiditis and joint chondrocalcinosis. *Rev Rhum Ed Fr* 61: 354-356, 1994 (In French).
29. Chan PK, Lyu SY and Lu CC: Paget disease of bone in an elderly patient with chronic renal disease and weight loss: A case report. *Medicine (Baltimore)* 98: e17458, 2019.
30. Bojincă V and Janta I: Rheumatic diseases and malignancies. *Maedica (Bucur)* 7: 364-371, 2012.
31. Davies A, Pluot E and James S: Tumour and tumour-like conditions associated with Paget's disease of bone. In: *Imaging of Bone Tumors and Tumor-Like Lesions*. Davies A, Sundaram M and James S (eds). Springer, Berlin, Heidelberg, pp515-530, 2009.
32. Page MJ, McKenzie JE, Bossuyt PM, Boutron I, Hoffmann TC, Mulrow CD, Shamseer L, Tetzlaff JM, Akl EA, Brennan SE, *et al*: The PRISMA 2020 statement: An updated guideline for reporting systematic reviews. *BMJ* 372: n71, 2021.
33. Somayaji BN: Malabsorption syndrome in Paget's disease of bone. *Br Med J* 4: 278-280, 1968.
34. Tatu AL and Ionescu MA: Multiple autoimmune syndrome type 3-thyroiditis, vitiligo and alopecia areata. *Acta Endocrinol (Buchar)* 13: 124-125, 2017.
35. Mihăilă B, Dinică RM, Tatu AL and Buzia OD: New insights in vitiligo treatments using bioactive compounds from *Piper nigrum*. *Exp Ther Med* 17: 1039-1044, 2019.
36. Tatu AL and Nwabudike LC: Male genital lichen sclerosus-a permanent therapeutic challenge. *J Am Acad Dermatol* 79 (Suppl 1): AB185, 2018.
37. Vaes BL, Lute C, Blom HJ, Bravenboer N, de Vries TJ, Everts V, Dhonukshe-Rutten RA, Muller M, de Groot LC and Steegenga WT: Vitamin B(12) deficiency stimulates osteoclastogenesis via increased homocysteine and methylmalonic acid. *Calcif Tissue Int* 84: 413-422, 2009.
38. Toh BH: Pathophysiology and laboratory diagnosis of pernicious anemia. *Immunol Res* 65: 326-330, 2017.
39. Kharb S, Kumar S and Kundu ZS: Homocysteine, a biomarker of osteosarcoma. *J Can Res Ther* 11: 51-53, 2015.
40. Van Dommelen CKV and Klaassen CHL: Cyanocobalamin-dependent depression of the serum alkaline phosphatase level in patients with pernicious anemia. *N Engl J Med* 271: 541-544, 1964.
41. Hanna S, Lachover L and Rajarethinam RP: Vitamin B12 deficiency and depression in the elderly: Review and case report. *Prim Care Companion J Clin Psychiatry* 11: 269-270, 2009.
42. Wolters M, Ströhle A and Hahn A: Age-associated changes in the metabolism of vitamin B(12) and folic acid: Prevalence, aetio-pathogenesis and pathophysiological consequences. *Z Gerontol Geriatr* 37: 109-135, 2004 (In German).
43. Polyzos SA, Anastasilakis AD, Efstathiadou Z, Litsas I, Kita M, Panagiotou A, Papatheodorou A, Arsos G, Moralidis E, Barmaliotis G, *et al*: Serum homocysteine, folate and vitamin B12 in patients with Paget's disease of bone: The effect of zoledronic acid. *J Bone Miner Metab* 28: 314-319, 2010.
44. Căruntu C, Zurac SA, Jugulete G and Boda D: Extramammary Paget's disease in an HIV-positive patient. *Rom J Morphol Embryol* 58: 1009-1015, 2017.
45. Rabjohns EM, Hurst K, Ghosh A, Cuellar MC, Rampersad RR and Tarrant TK: Paget's disease of bone: Osteoimmunology and osteoclast pathology. *Curr Allergy Asthma Rep* 21: 23, 2021.
46. Roodman GD and Windle JJ: Paget disease of bone. *J Clin Invest* 115: 200-208, 2005.



This work is licensed under a Creative Commons Attribution-NonCommercial-NoDerivatives 4.0 International (CC BY-NC-ND 4.0) License.