



Ototoxicity of povidone-iodine – A case report

Patorn Piroomchai

Department of Otorhinolaryngology, Faculty of Medicine, Khon Kaen University, Khon Kaen, Thailand

ARTICLE INFO

Keywords:
Povidone-iodine
Ototoxicity

ABSTRACT

Objective: The ototoxicity of povidone-iodine has been documented in animal studies. However, there is limited evidence of these ototoxic effects in humans. This is the first report to show the ototoxic effects of povidone-iodine in a human subject.

Patient: A 36-year-old woman came to our hospital complaining of left unilateral persistent hearing loss. One month before presentation, her child had accidentally struck her on her left ear. She applied approximately three drops of povidone-iodine (10% weight/volume) into her left auditory canal. Immediately after application, she felt severe pain and vertigo. An audiogram revealed severe left unilateral sensorineural hearing loss. Magnetic resonance imaging showed mild enhancement of the left vestibule and basal turn of the left cochlea.

Conclusions: Even a single application of povidone-iodine could cause significant hearing loss and disequilibrium. It should, therefore, be used with caution.

1. Introduction

The ototoxicity of antiseptics was suspected in a report published over 40 years ago, in which chlorhexidine gluconate was used for skin preparation before myringoplasty (Bicknell, 1971). Povidone-iodine is an antiseptic and antifungal agent that is commonly used for skin preparation and in external ear conditions (e.g., laceration of the pinna or fungal infection in the external auditory canal).

Although ototoxicity from povidone-iodine has been reported in animal studies, there is lack of evidence regarding this phenomenon in humans. This is due to the fact that human toxicity studies may be unethical given the accompanying risks to the safety of the subject.

Various studies have shown ototoxicity after the application of povidone-iodine to the middle ear of rats (Yagiz et al., 2003; Ichibangase et al., 2011; Ozkiris et al., 2013). The concentration of the povidone-iodine solution used might account for the severity of the hearing loss. Povidone-iodine is currently available in concentrations of 5, 7.5, and 10% weight/volume (w/v). One study found that the ototoxic effects were significantly greater in animals that had 10% povidone-iodine applied to the middle ear (Ozkiris et al., 2013).

The solvents contained in the antiseptic may also cause ototoxicity. There are two forms of povidone-iodine: 1) povidone-iodine aqueous solution and 2) povidone-iodine alcoholic solution. Povidone-iodine alcoholic solution has significantly higher antimicrobial efficacy (Arata et al., 1993). However, as alcohol has been reported to have an ototoxic effect (Perez et al., 2000), the ototoxicity of povidone-iodine alcoholic

solution might be higher.

The objective of this study is to report the ototoxic effect of povidone-iodine in a human subject.

2. Case presentation

Written informed consent was obtained from the patient who participated in this study. Approval was also granted by the institutional review board (HE591444).

A 36-year-old woman came to our hospital complaining of left unilateral persistent hearing loss. One month prior to presentation, she had been struck on the left ear by her child's open palm, after which she was not able to hear clearly. There was minimal pain and some bloody discharge from her left ear. She described the hearing loss as being akin to having water in her ear.

The hearing loss persisted for one day following the accident, and she felt the need to use medication. In her household, she had a 15 milliliter (ml) container of povidone-iodine (10% w/v) first aid aqueous (non-alcoholic) solution, with a label indicating that it be applied directly to the wound. She decided to apply approximately three drops of this solution into her left auditory canal.

Immediately after application, she felt severe pain and vertigo. She described the vertigo as a spinning sensation. The pain dissipated after a few minutes, but the vertigo and hearing loss persisted. She obtained antivertiginous medication (dimenhydrinate) over the counter, and the vertigo gradually decreased in intensity. However, she could barely

Peer review under responsibility of PLA General Hospital Department of Otolaryngology Head and Neck Surgery.

E-mail address: patorn@gmail.com.

<https://doi.org/10.1016/j.joto.2018.11.005>

Received 1 October 2018; Received in revised form 5 November 2018; Accepted 12 November 2018

1672-2930/© 2019 PLA General Hospital Department of Otolaryngology Head and Neck Surgery. Production and hosting by Elsevier (Singapore) Pte Ltd This is an open access article under the CC BY-NC-ND license (<http://creativecommons.org/licenses/by-nc-nd/4.0/>).

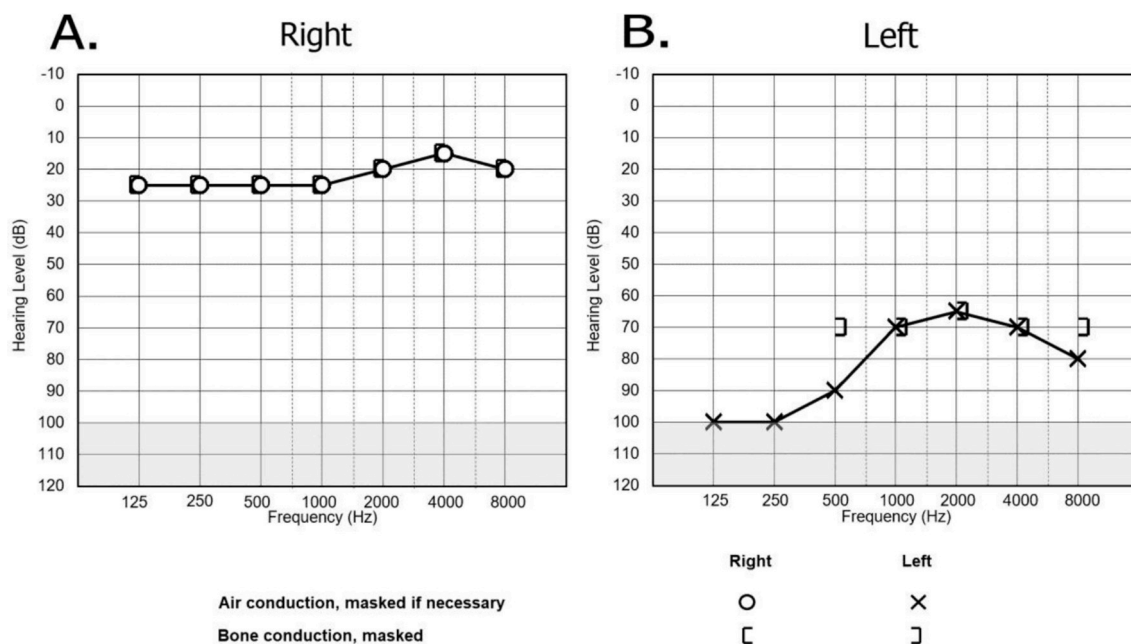


Fig. 1. The audiometry result at one month after povidone-iodine instillation. A) normal audiogram on the right side; B) severe sensorineural hearing loss on the left side.

hear out of her left ear.

The patient had neither a personal nor a family history of otologic disease. No one in her household had recently had any symptoms of illness, such as fever, and she was not taking any other medications.

One month after the accident, her hearing loss and mild vertigo had persisted, and she decided to come to our hospital. On arrival, her vital signs were normal. Otoscopy revealed a normal tympanic membrane and external auditory canal. An audiogram revealed severe left unilateral sensorineural hearing loss, with the mean hearing level of the left ear being 75 dB HL (Fig. 1). Magnetic resonance imaging (MRI) of the temporal bone with gadolinium showed mild enhancement of the left vestibule and basal turn of the left cochlea and enhanced hyper signal intensity of the left mastoid on a T2-weighted image. The MRI revealed no other abnormalities (Fig. 2).

The patient was diagnosed with toxic labyrinthitis. She was prescribed oral prednisolone at a dosage of 1 mg/kilogram for one week (after which the dosage would be tapered off) and betahistine for three months. The follow-up audiometry at three months showed improvement of the unilateral sensorineural hearing loss from severe to moderately severe, with the mean hearing level of the left ear to be 65 dB HL. The vertigo had completely resolved.

3. Discussion

Povidone-iodine is commonly used as an antiseptic and antifungal

agent. It comes in many forms, e.g., sprays, drops, and in bottles. Povidone-iodine is available both over the counter and in medical facilities. Otolologists commonly use povidone-iodine to sterilize the surgical field and for treatment of external ear and pinna diseases.

Application of povidone-iodine to the middle ear is less frequent due to the risk of the solution having an ototoxic effect. Currently, there have been no studies that have addressed this risk in humans.

All evidence of povidone-iodine-related ototoxicity has come from a small number of animal studies. Most of these studies found damage in the cochlea using histologic sectioning or electrophysiological tests (Perez et al., 2000; Ichibangase et al., 2011; Ozkiris et al., 2013). Cochlea damage was found histologically in guinea pigs after 30 min of exposure to povidone-iodine alcoholic solution, but vestibular damage required longer exposure times (Aursnes, 1982). A study of cochlear compound action potential in animals also found a significant threshold elevation after application of povidone-iodine (Morizono and Sikora, 1982).

The basal turn has been found to be the most susceptible part of cochlea (Aursnes, 1982), which is consistent with the fact that an MRI showed enhancement of the basal turn in our study.

Although there was no evidence in our case report of tympanic membrane perforation at one month after the accident, the history of ear trauma combined with blood oozing from the auditory canal was highly suggestive of tympanic membrane or auditory canal injury. We hypothesized that some amount of povidone-iodine had entered the

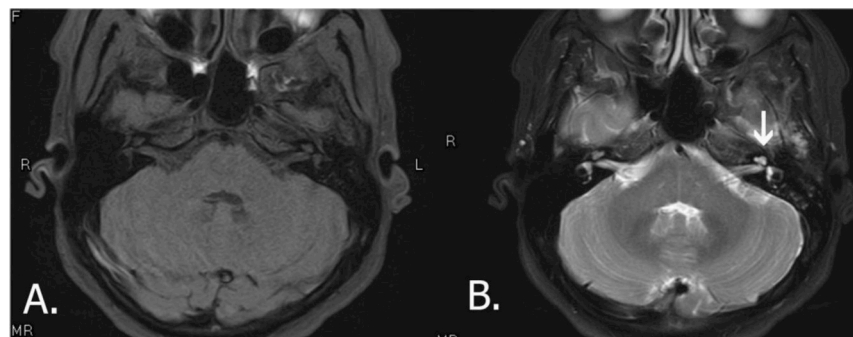


Fig. 2. MRI with contrast of the temporal bone. A) T1 weighted axial view; B) T2 weighted axial view, fat suppression. There was mild enhancement of the left vestibule and basal turn of the left cochlea (arrow) and enhanced hyper signal intensity of the left mastoid. No additional abnormalities were found in the post-contrast image.

middle ear and been absorbed there.

The permeability of the round window membrane plays a crucial role in the toxicity of ototopical drugs. The round window membrane has been found to be significantly thicker in patients with chronic otitis media than in the normal population (Sahni et al., 1987). This reduction in permeability would act as a protective factor against ototoxicity from ototopical drugs. In a previous study, a series of 19 chronic otitis media patients were treated with 5% w/v povidone-iodine without hearing deterioration as assessed by pure tone audiometry (Jaya et al., 2003). However, there has yet been no study that has used electro-physical measurement tools that are more sensitive to cochlear damage than pure tone audiometry such as those that measure cochlear compound action potential.

Other factors that could contribute to sensorineural hearing loss are an infection, temporal bone trauma, cerebellopontine angle tumors, and idiopathic sensorineural hearing loss. However, in this case, there was evidence of a causal relationship with povidone-iodine, and there was no fever or pus discharge nor evidence of tumor or fracture in the imaging. Thus, ototoxicity from povidone-iodine was the most likely diagnosis.

We propose that the patient's initial vertigo could be attributed to the instillation of a cold liquid into the ear, and the decreased hearing she experienced immediately post-instillation could be due to conductive hearing loss. This initial vertigo and hearing loss should have been temporary. Later, the povidone-iodine was absorbed into the inner ear, causing cochlea damage and vestibular damage. This kind of inner ear damage may be detectable 30 min after instillation (Aursnes, 1982). However, there is no previous data available with regard to this in humans.

To our knowledge, this is the first report of ototoxicity from povidone-iodine in a human subject. This case report found that even a single application of commercially available povidone-iodine solution could cause significant ototoxicity. However, whether or not povidone-iodine exposure leads to ototoxicity depends on whether the patient has penetrating trauma to the ear canal or tympanic membrane, a past medical history of otologic disease (such as chronic otitis media) or has been exposed to other substances associated with ototoxicity such as alcohol.

4. Conclusion

This study is the first to report povidone-iodine ototoxicity in a human subject. It showed that even a single application of povidone-iodine might cause significant hearing loss and disequilibrium. It should, therefore, be used with caution.

Informed consent

Written informed consent was obtained from the patient who participated in this study.

Author contribution

PP: Conception and design, interpretation of data, drafting and critical revision of the manuscript, and final approval of the version to be published. PP is accountable for all aspects of this work and ensuring that questions related to its accuracy or integrity are appropriately investigated and resolved.

Conflicts of interest

The author has no conflict of interest to declare.

Financial disclosure

This study has received no financial support.

Funding and conflict of interests

None.

Appendix A. Supplementary data

Supplementary data to this article can be found online at <https://doi.org/10.1016/j.joto.2018.11.005>.

References

- Arata, T., Murakami, T., Hirai, Y., 1993. Evaluation of povidone-iodine alcoholic solution for operative site disinfection. *Postgrad. Med.* 69 (Suppl. 3), S93–S96.
- Aursnes, J., 1982. Ototoxic effect of iodine disinfectants. *Acta Otolaryngol.* 93 (1–6), 219–226.
- Bicknell, P.G., 1971. Sensorineural deafness following myringoplasty operations. *J. Laryngol. Otol.* 85 (9), 957–961.
- Ichibangase, T., Yamano, T., Miyagi, M., Nakagawa, T., Morizono, T., 2011. Ototoxicity of Povidone-Iodine applied to the middle ear cavity of Guinea pigs. *Int. J. Pediatr. Otorhinolaryngol.* 75 (9), 1078–1081.
- Jaya, C., Job, A., Mathai, E., Antonisamy, B., 2003. Evaluation of topical povidone-iodine in chronic suppurative otitis media. *Arch. Otolaryngol. Head Neck Surg.* 129 (10), 1098–1100.
- Morizono, T., Sikora, M.A., 1982. The ototoxicity of topically applied povidone-iodine preparations. *Arch. Otolaryngol.* 108 (4), 210–213.
- Ozkiris, M., Kapusuz, Z., Saydam, L., 2013. Ototoxicity of different concentrations povidone-iodine solution applied to the middle ear cavity of rats. *Indian J. Otolaryngol. Head Neck Surg.* 65 (2), 168–172.
- Perez, R., Freeman, S., Sohmer, H., Sichel, J.Y., 2000. Vestibular and cochlear ototoxicity of topical antiseptics assessed by evoked potentials. *Laryngoscope* 110 (9), 1522–1527.
- Sahni, R.S., Paparella, M.M., Schachern, P.A., Goycoolea, M.V., Le, C.T., 1987. Thickness of the human round window membrane in different forms of otitis media. *Arch. Otolaryngol. Head Neck Surg.* 113 (6), 630–634.
- Yagiz, R., Tas, A., Uzun, C., Adali, M.K., Koten, M., Karasalihoglu, A.R., 2003. Effect of topically applied povidone-iodine on transient evoked otoacoustic emissions in Guinea pigs. *J. Laryngol. Otol.* 117 (9), 700–703.