

Binder's phenotype with ankyloglossia: Report of a rare inherited association in an Indian female

Shalini R. Gupta¹, B. Rajiv², Anuradha Yadav¹, Sheetal Sharma¹

¹Department of Oral Medicine and Radiology, Centre for Dental Education and Research, All India Institute of Medical Sciences,

²Department of Orthodontics and Dentofacial Orthopedics, University College of Medical Sciences, New Delhi, India

Abstract

Binder's syndrome, a rare congenital malformation of nasomaxillary complex, first described in 1962, has a hexad of characteristic clinical and radiographic features consisting of arhinoid face, intermaxillary hypoplasia with malocclusion, abnormal position of nasal bones, atrophy of nasal mucosa, reduced or absent anterior nasal spine and hypoplastic/absent frontal sinus. The typical facies due to mid-face hypoplasia may also be accompanied by other midline malformations such as cleft palate, spinal, skeletal and cardiac abnormalities. It is usually sporadic, of unknown etiology although various environmental and genetic mechanisms are implicated due to few familial cases predominantly in the Swedish population. A case of inherited Binder's syndrome is presented in an Indian female patient with an unusual finding of ankyloglossia (AG). The development of the anterior nasal spine and AG are chronologically related as they both occur during the 5th–6th weeks of gestation. The possible etiopathogenetic mechanisms for this rare association are reviewed.

Keywords: Ankyloglossia, Binder's syndrome, familial, nasomaxillary hypoplasia

Address for correspondence: Dr. Shalini R. Gupta, Department of Oral Medicine and Radiology, Centre for Dental Education and Research, All India Institute of Medical Sciences, New Delhi, India.

E-mail: shalinigupta@hotmail.com

Submitted: 13-May-2021, **Accepted:** 16-Nov-2021, **Published:** 28-Feb-2022

INTRODUCTION

Binder syndrome (BS) is a congenital malformation of the nasomaxillary complex consisting of a hexad of characteristic clinical and radiographic findings first described by Noyes (1939) and defined by Binder in 1962.^[1] The essential features are arhinoid face, intermaxillary hypoplasia with malocclusion, abnormal position of nasal bones, atrophy of nasal mucosa, reduced or absent anterior nasal spine and hypoplastic/absent frontal sinus (not obligatory).^[1,2] The syndrome has been classified into mild, moderate and severe depending on the severity of the essential facial features involving the nose, maxilla, eyes, ears, lips, and additional features involving the

cervicospinal, skeletal, cardiac and central nervous system have also been described [Table 1].^[1-4] Mild cases may go undiagnosed but moderate and severe cases may present with nasal obstruction, difficulty in breathing, difficulty in feeding, failure to thrive, delayed milestones in children and unesthetic facial appearance in adolescents.^[2] It is a rare condition infrequently described in literature with unknown prevalence, incidence 1/18,000 with no sexual predilection.^[4] The etiology is unknown, but heterogeneous factors both environmental and chromosomal/genetic may be involved.^[4] Although most of the cases are sporadic, genetic factors have been implicated due to few reports of familial occurrence (16%–36% in the Swedish

This is an open access journal, and articles are distributed under the terms of the Creative Commons Attribution-NonCommercial-ShareAlike 4.0 License, which allows others to remix, tweak, and build upon the work non-commercially, as long as appropriate credit is given and the new creations are licensed under the identical terms.

For reprints contact: WKHLRPMedknow_reprints@wolterskluwer.com

How to cite this article: Gupta SR, Rajiv B, Yadav A, Sharma S. Binder's phenotype with ankyloglossia: Report of a rare inherited association in an Indian female. *J Oral Maxillofac Pathol* 2022;26:S5-11.

Access this article online

Quick Response Code:



Website:

www.jomfp.in

DOI:

10.4103/jomfp.jomfp_143_21

Table 1: Clinical and radiological features in Binder's syndrome^[1-9]

	Features
Binder's syndrome	Rhinoid face
Hexad	Abnormal position of nasal bones Intermaxillary hypoplasia with malocclusion Absent/hypoplastic anterior nasal spine Atrophy of nasal mucosa Hypoplastic/absent frontal sinus (40%–50%)
Additional features	
Face	Hypoplastic concave midface profile Wide frontonasal angle (180°) Acute naso-labial angle (76–88°) Orofacial clefting Macrostomia
Eyes	Hypertelorism Strabismus Mongolism
Nose	Sparse hair in eye brows Flat, long, vertical nose Depressed nasal bridge Flattened tip and alar wings Columella/lip junction short and retracted Nostrils semilunar/crescent/half-moon shaped Scaphoid depression (sulcus prenasalis) in anterior nasal floor Nasal obstruction Narrow airway space Nasal twang in speech Difficulty in breathing
Lips	Convex everted lips Deep fold/fossa between nose and upper lip Flat philtrum with poorly developed philtral crests
Ears	Small pinnae Absent acoustic reflex
Dental/oral	Type C immittance on audiometry Severe/moderate/no malocclusion Angles Class I/Class III Pseudo Class III malocclusion Increased mandibular length and gonial angle Cleft palate High arched palate Microdontia maxillary central incisors Missing lateral incisor Hypodontia Amelogenesis imperfecta
Cervical spine (50%)	C1, C2 affected commonly Separate odontoid process Short posterior arch Persistence of chorda dorsalis Spina bifida occulta Blocked, patchy distorted vertebrae Scoliosis, kyphosis
Skeletal	Short stature Polydactyly Terminal phalangeal hypoplasia of the hand Decreased anterior cranial base length
Central nervous system	Arhinencephaly Decreased intelligence/mental retardation Anosmia Decreased hearing (5%)
Others	Downs syndrome Congenital heart disease (5%)

Synonyms: Dish face, fossae prenasalis, facies scaphoidea, dysostosis maxillonasalis, congenital flat nose syndrome, nasomaxillary dysplasia

population) and consanguineous families with affected siblings.^[5,6] A global review revealed 40 familial cases

since 1963 [Table 2].^[1,2,4-9] A review of PUBMED indexed literature from 2008 did not reveal any report of familial BS in the Indian population. Ankyloglossia (AG), another rare midline developmental defect, seen in 1%–10% of the population is mostly seen as an isolated anomaly predominantly in males. It however may also be genetic in origin and familial, associated with X-linked inheritance and other rare genetic disorders and syndromes but not reported in familial BS [Table 3].^[10] This is a rare case of inherited BS associated with AG in a mother and daughter of Indian origin.

CASE REPORT

A 15-year-old girl reported with a chief complaint of irregular teeth, nasal obstruction and unaesthetic facial appearance. She was to undergo rhinoplasty in ENT and was referred for correction of malocclusion. She had been reviewed by the Geneticist and undergone multisystem evaluation for other abnormalities. Written informed consent was obtained before the further examination.

The ante-natal, natal or medical history was nonsignificant except for delayed milestones. Her mother (45 years) had the same facial features and both were of short stature. The elder female sibling had no such facies and was of average height. There was no history of consanguinity or similar facial appearance in any other family member and first- and second-degree relatives. There was no history of birth trauma, prenatal exposure to warfarin, alcohol and phenytoin in this patient. There was no mental retardation with good performance in academics. There was no loss of hearing/smell or any history of systemic diseases. Menarche was at 13 years with normal bone chemistry and hormonal profile (thyroid, reproductive, growth).

On extra-oral examination, both the patient and her mother had a small narrow face, concave facial profile due to midfacial hypoplasia, hypertelorism, flattened nasal bridge, short columella, wide alar wings flattened tip of the nose, acute nasolabial angle and wide frontonasal angle [Figure 1a and b]. The nostrils were triangular in shape when observed from below. The upper lip was slightly everted with a short philtrum. The tongue on protrusion showed a central groove and heart-shaped appearance at the tip [Figure 1c and d]. The free tongue available from the insertion of the lingual frenum into the base of the tongue to the tip of the tongue was 11 mm and classified as Class II (Moderate AG) as per Kotlow's assessment for tongue function. Hazelbaker's assessment for the appearance of the tongue gave a score of 9.^[11] There was however no history of difficulty while breast-feeding or

Table 2: Familial Binder's syndrome^[1,2,4-9]

Authors	Country	Number of cases	Age (sex)	Family history	Additional features
Ragnell (1952)	Sweden	One	17 (female)	Grandfather	Large occiput
Hopkins (1963)	United Kingdom	One	NA (female)	Aunt	Short second toes
Rival (1974)	France	Three	NA	Grandmother	NA
Fergusson (1985)	United Kingdom	One	11 years (NA)	Aunt	Thin labial plate of bone in proclined anterior teeth
Holstrom (1986)	Sweden	Eight	8-34 years (NA)	Brother Sister Parents	Prenasal fossae
Gross- Kieselstein <i>et al.</i> (1986)	Israel	One	NA (NA)	Mother	-
Horsewell (1987)	Australia	Five	NA	Father Mother Brother Sister Uncle	Cervicospinal abnormalities
Olow-Nordenram (1988)	Sweden	Eighteen	NA	Father Mother Brother Sister	Relative mandibular prognathism Cervical abnormalities
Roy-Doray <i>et al.</i> (1997)	France	One	NA (male)	Mother	Hypertelorism
Kepler (2010)	USA	One	21 months (male)	Brother	Bilateral epicanthal folds, short palpebral fissures, extremities with proximal thumb placement
Present report (2020)	India	One	15 years (female)	Mother	Ankyloglossia Hypertelorism Malposed maxillary incisors Missing maxillary lateral incisor High arched palate Retained maxillary deciduous teeth

NA: Not applicable

difficulty in speech, but there was a nasal twang to the voice. Intra-orally, there were retained deciduous teeth (55, 53, 52, 63, 65, 73), high arched V-shaped palate, rotated malposed 11, 22 and missing 12, 18, 28, 38 [Figure 2a and b].

Cephalometric analysis [Table 4] revealed CVMI Stage 5, short cranial base (61.82 mm) and absence of anterior nasal spine and frontal sinus. The maxilla was retrognathic (ANB angle of -3.66° , maxillary base length 36.3 mm, SNO angle 49.81°) with average mandibular plane angle, acute nasolabial angle, increased overjet (10 mm) and proclined upper incisors (U1-SN - 120.3°) [Figure 3a and b]. The cephalometric evaluation showed Class III skeletal pattern due to hypoplastic maxilla with dental compensation. The sella turcica, orbits, nasal bones and oropharyngeal airway space were not affected. There were no other skeletal, digital or cervical abnormalities.

Management will involve a multidisciplinary team including orthodontist, ENT specialist and plastic surgeon for orthodontic management and nasal reconstruction. The camouflage treatment was planned for this patient due to borderline skeletal discrepancy with severe dental compensation. The extraction of left upper first premolar followed by dental decompensation. This will be achieved by retracting the proclined maxillary incisors without creating midline deviation as maximum anchorage case. This will be followed by reshaping of right upper canine

Table 3: Syndromes associated with Ankyloglossia^[10,18-20]

X-linked cleft palate
Van der woude syndrome
Robinow syndrome Ror2
Smith - lemli opitz syndrome
Oro facial digital syndrome Type I
Simpson golabi behmel syndrome
Ehlers danlos syndrome
Beckwith weidman syndrome
Ellis van creveld syndrome
Kindler syndrome
Dystrophic epidermolysis bullosa

Table 4: Cephalometric parameters

Parameter	Value
Cranial base length (SN) (mm)	61.82
ANB ($^\circ$)	-3.66
Maxillary base length (mm)	36.3
SNO ($^\circ$)	49.81
Facial angle	90.98
FMA	21.76
U1-SN ($^\circ$)	121.4
U1-NA (mm)	15.5
IMPA	88.95
H angle	8.43
Nasolabial angle	84.93

IMPA: Incisor mandibular plane angle, FMA: Frankfort mandibular plane angle, SN: Sella/Nasion

and first premolar as lateral incisors and canine respectively. The case will be evaluated after the orthodontic treatment for improvement in nasolabial angle and profile. The nasal dorsum reconstruction will be performed postorthodontic treatment. As the speech was not affected, no intervention for AG was required.

DISCUSSION

Binder had suggested the syndrome to be arhinencephalic in origin with birth trauma or disturbance in growth of the pros-encephalic induction center that affects nose formation in the 3rd month of pregnancy.^[6,12] The absence of anomalies in eyes, orbits, forehead, brain or sense of smell however makes it less probable. The association of cervicospinal abnormalities seen in 50% of cases with maxillonasal defects in BS has been suggested to be due to the concurrent induction process of both the structures during the 5th–6th week of gestation.^[4,12] Environmental factors like birth injury, prenatal exposure to warfarin and phenytoin that interfere with Vitamin K synthesis and inhibition of Vitamin K reductase activity may also play a role as they affect the development of nasal cartilages that are rich in vitamin K-dependent protein matrix gla protein. The etiologic role of Vitamin K deficiency is further exemplified by similar facial features in other conditions affected by Vitamin K like autosomal recessive Vitamin K epoxide reductase deficiency, some forms of chondrodysplasia punctata (CDP), Keutel syndrome and Fetal warfarin syndrome. The mutant transthyretin (TTR)

gene which has been found to cause apoptosis of the nasal placodes during development in animal studies may also contribute to the typical features of Binder's phenotype.^[4]

The etiology of BS is unknown but combining human morphological studies in craniofacial syndromes that find an association between cranial development and the central and peripheral nervous system and experimental studies on migration of cells from different regions of the neural tube to different parts of the cranial face and dentition, have given rise to the concept of different developmental fields. Spranger *et al.* defined a developmental field as "A region or part of an embryo which responds as a coordinated unit to embryonic interaction and results in complex or multiple anatomical structures."^[13] Inger has proposed a dental approach for the evaluation of pathogenesis of craniofacial syndromes and has suggested three bilateral developmental fields innervated by different nerves. Frontonasal field by the nasopalatine, maxillary field by the maxillary and palatal field in the maxilla by the palatine nerves. Similar three developmental fields in the mandible are proposed that are innervated by different nerve branches of the inferior alveolar nerve and are connected during development [Figure 4].^[14,15]

"An intrinsic, nondisruptive disturbance of a developmental field will lead to a field defect."^[13,14] A craniofacial syndrome could be due to disruption in a single field like Single median maxillary central incisor syndrome or several fields like Trisomy 21. The genes responsible for the craniofacial syndromes and migration of neural tube cells have been identified in some like Treacher Collins syndrome. According to this hypothesis, the anomalies seen in BS could therefore be due to disruption in frontonasal and maxillary developmental fields but the underlying genetic mechanisms need further investigation.^[14]

The anterior nasal spine which separates the nasal floor from the anterior surface of the maxilla is either absent or hypoplastic and the alveolar bone slopes into the nasal cavity. The crest of the spine can usually be palpated at the base of the nostril when present. A scaphoid depression

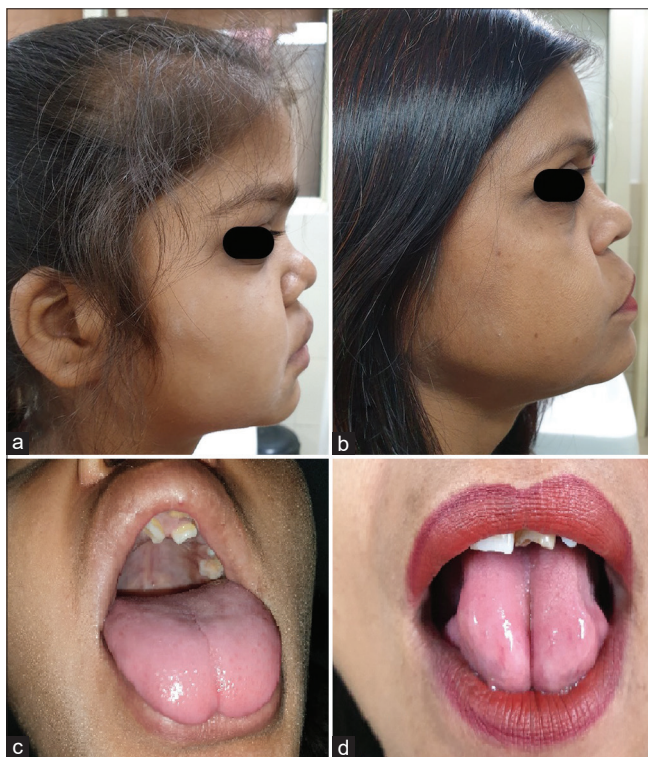

Figure 1: (a) Short flattened nose, concave profile, wide frontonasal angle, acute nasolabial angle in daughter, (b) Short flattened nose, concave profile, wide frontonasal angle, acute nasolabial angle in mother, (c) Shallow central groove on the dorsum and heart-shaped tongue on protrusion due to ankyloglossia in daughter (d) Deep central groove on dorsum and inability to protrude tongue beyond vermilion border of lower lip due to ankyloglossia in mother

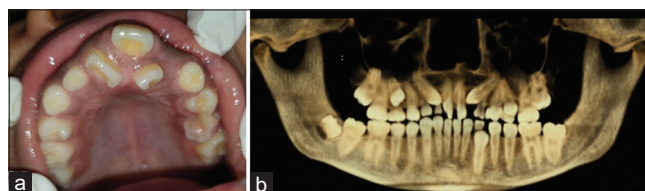


Figure 2: (a) Intra-orally, there were retained deciduous teeth (55, 53, 52, 63, 65), high arched V-shaped palate, rotated malposed 11, 22 and missing 12. (b) Orthopantomogram shows retained deciduous teeth (55, 53, 52, 63, 65, 73 malposed 11, 22 impacted 13, 23 and missing 12, 18, 28, 38

or small pit called the fossa prenasalis, demarcated by two low transverse ridges in the floor of the nasal cavity, first described by Zuckerkandl in 1882 was found to be present in 6% of the patients and bears resemblance to the nasoalveolar clivus of some apes, hominids and non-Caucasians.^[5] The intermaxillary hypoplasia is found to be both in the anteroposterior and vertical dimension in early childhood but can improve with age and is associated with true/pseudo Angles Class III malocclusion.

The inheritance pattern has been variously described as autosomal dominant with reduced penetrance, autosomal recessive with reduced penetrance or multifactorial.^[4,6] The recurrence in families has been found to be common in the Swedish population (16%, 36%).^[5,6] The recurrence is found to be more common in affected parent and child or sibling than recurrence in siblings with unaffected parents and is less common in second- and third-degree relatives. Since the majority of the cases are sporadic and inherited BS is rare with a heterogeneous inheritance pattern, there are no reliable recurrence risks factors available for genetic counseling.^[16]

The term “Syndrome” as defined by Spranger *et al.* has been found to be a misnomer in association with BS as the pattern of abnormalities found are not causally defined as yet. The term dysplasia/dysostosis as in Maxillonasal/Nasomaxillary dysplasia/dysostosis is also considered inappropriate as histological abnormalities have not been found in the affected regions. Quarrel has proposed that the characteristic features seen in BS are a phenotype and be considered as an association which principally affects the nose and maxilla with other additional features that may be seen occasionally.^[16]

BS has to be differentiated from other conditions that share features of nasomaxillary hypoplasia [Table 5] the most significant being milder form of CDP which in addition to characteristic Binder phenotype also shows punctate stippling of epiphyses that disappear in adolescence making it difficult to differentiate it from BS diagnosed later on in life.^[1,2,4]

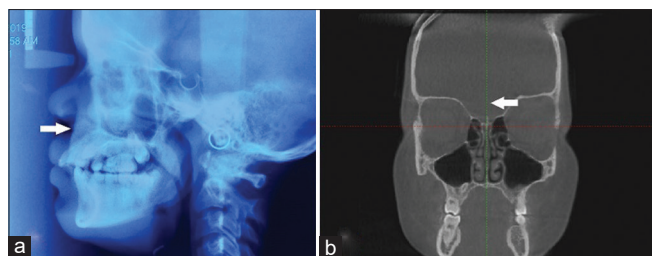


Figure 3: (a) Absence of anterior nasal spine (white arrow) and cervical spine abnormalities in lateral cephalogram (b) Absence of frontal sinus (white arrow) in cone beam computed tomography coronal section

A patient with Binder’s phenotype will have to undergo multisystem evaluation for neurological, endocrine, skeletal, cervicospinal, cardiac, auditory and dental anomalies. The management and its timing depend on the severity of the condition and age at diagnosis. The facial aesthetics and dental defects will require multidisciplinary approaches like orthodontic treatment to correct malocclusion, plastic surgery for nasal deformities and orthognathic surgery for correction of skeletal maxillary hypoplasia may be required. Orthodontic treatment can start early on to minimize the defect of maxillary hypoplasia while nasal correction may be done when the child becomes aware of the facial defects. Orthognathic surgery like Le Fort I or II osteotomy be carried out after the growth has stopped. Distraction osteogenesis using rigid external devices and intraoral anterior maxillary devices have also been tried. Autologous and alloplastic cartilage and bone grafts are used to correct the deficiencies in nasomaxillary complex.^[3] Prosthetic rehabilitation for missing teeth may be required in some cases. Three-dimensional facial scans can highlight the

Table 5: Differential diagnosis of Binder’s syndrome^[1,2,4-9,12]

CDPR type
Fetal alcohol syndrome
Fetal warfarin syndrome
Sequelae of cleft lip and palate
Down syndrome
Apert syndrome
Crouzon syndrome
Stickler syndrome
Keutel syndrome
Acrodysostosis
Bimler microrrhine dysplasia
Oro-digital-facial syndrome
Robinow syndrome
Marshall syndrome
Kniest syndrome
Posttraumatic nasomaxillary retrusion
CDPR: Chondrodysplasia punctata, rhizomelic

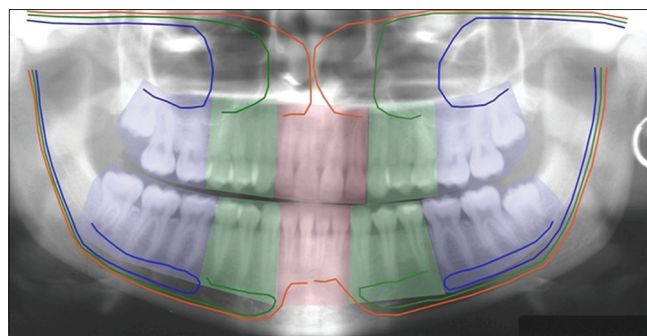


Figure 4: Orthopantomogram illustrating the developmental fields in the maxilla and mandible with different innervation, surrounded by different ectomesenchyme. In the maxilla, Red colour: bilateral frontonasal field, Green colour: bilateral maxillary field, Blue colour: bilateral palatal fields. Similar fields in the mandible are illustrated.^[15] This figure is reprinted with permission from Orthodontic Waves 2012;71:1-16. DOI: 10.1016/j.odw.2011.10.001 www.tandfonline.com

severity of the defect and serve as a soft-tissue template for treatment planning.^[4] Psychological counseling to affected children should be considered. Early detection of this condition and intervention can minimize the psychological effects of this condition in the minds of growing children. Prenatal diagnosis with ultrasonography during 11–14 weeks of gestation can help in better management of respiratory distress if any at birth. Preconception counseling for women on phenytoin/warfarin therapy may also be considered.

AG is a developmental anomaly characterized by short thick lingual frenum resulting in limitation of tongue movement. In the 4th week of intrauterine life during tongue development, a U-shaped sulcus develops in front and on both sides of the tongue except at the base of the lingual frenum in the midline, which remains attached, while the rest of the tongue is freed for movement. The frenum forming cells undergo apoptosis during the 6th week and move away from the tip of the tongue thus increasing the range of tongue mobility. A disruption in this process could lead to persistence of the attached lingual frenum causing AG.^[17]

AG may cause difficulty in breastfeeding in infancy and speech (consonants “h,” “l,” “r,” “t,” “d,” “n,” “th,” “sh,” “w” and “z” affected) during childhood. The limitation in tongue function also causes difficulty in protrusion outside the mouth resulting in clefting/heart-shaped tongue, inability to sweep the upper and lower lips easily or touch the palate with tip of tongue and blanching of the tissues lingual to anterior teeth.^[18] Severe AG can also cause the gingival recession, diastema or be associated with missing mandibular central incisors.^[19] Assessment for function using Kotlow classification and Hazelbaker’s tool for appearance and function of the tongue are done to determine the need for frenectomy (function score is <11 and appearance score is <8).^[11] Frenotomy and frenuloplasty are other techniques for less severe cases that can be done by lasers/conventional surgery followed by speech therapy when required.^[18] It has been hypothesized that the low position of the tongue in AG causes downward and forward pressure causing mandibular prognathism and maxillary hypoplasia but there is limited evidence at present to substantiate its role in the development of malocclusion.^[18] Maternal cocaine use, mutations in TBX22, LGR5, autosomal dominant with incomplete penetrance and X-linked inheritance have been implicated as etiological factors of AG.^[10,19,20] Since AG has been sometimes reported with Cleft lip, Cleft palate, mandibular symphyseal clefts, other orofacial clefts and missing mandibular central incisors, applying Inger’s hypothesis, the

anomalies seen with AG could be due to developmental field defects in the mandible.^[14]

AG was seen in both mother and daughter in this inherited case of BS and has only been reported once before in a sporadic type of BS in a neonate.^[4] The occurrence of BS with AG appears to be sporadic in the mother while an autosomal dominant mode of inheritance is indicated in the daughter.

Both BS and AG are developmental congenital anomalies occurring in midline structures of the face and rarely inherited. Both share common features like maxillary hypoplasia, pseudo prognathism of the mandible and are sometimes associated with other midline defects like cleft palate, dental anomalies and other craniofacial syndromes. With the current lack of knowledge of exact pathogenetic mechanisms for simultaneous occurrence of BS and AG, they can best be described as associations.^[13] This rare association of inherited BS with AG suggests that these primary malformations could have a genetic etiology, but the involvement of developmental field defects affecting the midline structures of maxilla and mandible during 5th–6th weeks of gestation is also possible. Further observational studies of similar findings with chromosomal and genetic analysis can clarify the etiopathogenesis of this rare association.

Declaration of patient consent

The authors certify that they have obtained all appropriate patient consent forms. In the form the patient (s) has/have given his/her/their consent for his/her/their images and other clinical information to be reported in the journal. The patients understand that their names and initials will not be published and due efforts will be made to conceal their identity, but anonymity cannot be guaranteed.

Financial support and sponsorship

Nil.

Conflicts of interest

There are no conflicts of interest.

REFERENCES

1. Ferguson JW, Thompson RP. Maxillofacial dysostosis (Binder syndrome); a review of the literature and case reports. *Eur J Orthod* 1985;7:145-8.
2. Horswell BB, Holmes AD, Barnett JS, Levant BA. Maxillofacial dysplasia (Binder’s syndrome): A critical review and case study. *J Oral Maxillofac Surg* 1987;45:114-22.
3. Yamani VR, Ghosh S, Tirunagari S. Nasal correction in nasomaxillary hypoplasia (Binder’s syndrome): An optimised classification and treatment. *Indian J Plast Surg* 2016;49:314-21.
4. Keppler-Noreuil KM, Wenzel TJ. Binder phenotype: Associated findings and etiologic mechanisms. *J Craniofac Surg* 2010;21:1339-45.
5. Holmström H. Clinical and pathologic features of maxillofacial

- dysplasia (Binder's syndrome): Significance of the prenasal fossa on etiology. *Plast Reconstr Surg* 1986;78:559-67.
6. Olow-Nordenram M, Valentin J. An etiologic study of maxillonasal dysplasia--Binder's syndrome. *Scand J Dent Res* 1988;96:69-74.
 7. Hopkin GB. Hypoplasia of the middle third of the face associated with congenital absence of the anterior nasal spine, depression of the nasal bones, and angle class III malocclusion. *Br J Plast Surg* 1963;16:146-53.
 8. Roy-Doray B, Geraudel A, Alembik Y, Stoll C. Binder syndrome in a mother and her son. *Genet Couns* 1997;8:227-33.
 9. Ragnell A. A simple method of reconstruction in some cases of dish-face deformity. *Plast Reconstr Surg (1946)* 1952;10:227-37.
 10. Han SH, Kim MC, Choi YS, Lim JS, Han KT. A study on the genetic inheritance of ankyloglossia based on pedigree analysis. *Arch Plast Surg* 2012;39:329-32.
 11. Bhattad MS, Baliga MS, Kriplani R. Clinical guidelines and management of ankyloglossia with 1-year followup: Report of 3 cases. *Case Rep Dent* 2013;2013:185803.
 12. Olow-Nordenram MA, Rådberg CT. Maxillo-nasal dysplasia (Binder syndrome) and associated malformations of the cervical spine. *Acta Radiol Diagn (Stockh)* 1984;25:353-60.
 13. Spranger J, Benirschke K, Hall JG, Lenz W, Lowry RB, Opitz JM, *et al.* Errors of morphogenesis: Concepts and terms: Recommendations of an international working group. *J Pediatr* 1982;100:160-5.
 14. Kjær I. Dental approach to craniofacial syndromes: How can developmental fields show us a new way to understand pathogenesis? *Int J Dent* 2012;2012:145749.
 15. Kjær I. New diagnostics of the dentition on panoramic radiographs focusing on the peripheral nervous system as an important aetiological factor behind dental anomalies. *Orthod Waves* 2012;71:1-16.
 16. Quarrell OW, Koch M, Hughes HE. Maxillonasal dysplasia (Binder's syndrome). *J Med Genet* 1990;27:384-7.
 17. Parada C, Chai Y. Mandible and tongue development. *Curr Top Dev Biol* 2015;115:31-58.
 18. Chaubal TV, Dixit MB. Ankyloglossia and its management. *J Indian Soc Periodontol* 2011;15:270-2.
 19. Lenormand A, Khonsari R, Corre P, Perrin JP, Boscher C, Nizon M, *et al.* Familial autosomal dominant severe ankyloglossia with tooth abnormalities. *Am J Med Genet A* 2018;176:1614-7.
 20. Klockars T. Familial ankyloglossia (tongue-tie). *Int J Pediatr Otorhinolaryngol* 2007;71:1321-4.