

Rupture rudimentary horn pregnancy at 31 week

Abdullah A. Al Qarni, MD, Nawal Al- Braikan, MD, PhD, Moh'd M. Al-Hanbali, MD, PhD, Abdullah H. Albarmaly, MD.

ABSTRACT

الرحم ذو القرن الإضافي من التشوهات الخلقية النادرة في الرحم، نتيجة عدم التحام قناتي مولر خلال التطور الجنيني . الحمل في الرحم ذو القرن الإضافي نادر جداً قد يؤدي إلى تمزق أو انفجار في أواخر الثلث الأول أو الثاني من فترة الحمل . هذه حالة نادرة لحبلتي حضرت للمستشفى في الثلث الأخير من الحمل (31 أسبوعاً) تشكوا من آلام في البطن وغثيان وفيء لمدة 3 أيام . عند حضورها كانت المريضة شاحبة وغير مستقرة . الفحص بالموجات فوق الصوتية للجنين كان (30 اسبوعاً) مع وجود نبض القلب للجنين . أثناء العملية القيصرية تبين الحمل في القرن اليسر مع تمزق وانفجار في جدار الرحم . تم استخراج الجنين وهو على قيد الحياة ثم استئصال القرن اليسر . ونصحت المريضة بعدم الحمل لمدة 3 سنوات . بعد سنة واحدة حضرت المريضة الى المستشفى حامل في (37 أسبوعاً) في دورالولادة النشط . هذه الحالة تؤكد على أهمية الرعاية والفحص قبل الحمل والولادة لتجنب المضاعفات الخطيرة والوفاة .

Rudimentary horn could be a rare congenital uterine anomalies result from incomplete fusion of the 2 Müllerian ducts throughout embryo-genesis. Pregnancy in an exceedingly rudimentary horn is rare and typically terminates in rupture throughout the late of first or second trimester of pregnancy. We tend to present a rare case of a gravida within the trimester (31 weeks) presented with complain of abdominal pain, nausea, and vomit for 3 days. On presentation, the patient was pale and irritable. Ultrasound scan showed fetus at (30 weeks) with cardiac activity. Cardiotocography reactive. Incision showed horned uterus with pregnancy in rudimentary left horn that was ruptured. Alive fetus was delivered. The rudimentary left horn was excised. The patient was advised to not get pregnant for 3 years. Within one year, the patient came to hospital in active labor at (37 weeks). This case emphasizes the importance of fine antepartum care to avoid morbidity and mortality.

*Saudi Med J 2017; Vol. 38 (2): 201-203
doi: 10.15537/smj.2017.2.16016*

From the Department of Obstetrics and Gynecology, Al Yamamah Hospital, Riyadh, Kingdom of Saudi Arabia.

Received 28th July 2016. Accepted 2nd November 2016.

Address correspondence and reprint request to: Dr. Abdullah A. Al Qarni, Department of Obstetrics and Gynecology, Al Yamamah Hospital, Riyadh, Kingdom of Saudi Arabia. E-mail: dr.abdullah22@gmail.com

Pregnancy in an exceedingly rudimentary horn was first represented by Mauriceau and liege in 1669.¹ The reported incident is (1 in 100,000 to 140,000) gestation.^{3,10} the feminine reproductive organs develop from the fusion of the bilateral paramesonephric (Müllerian) ducts to create the uterus.¹ Bicornuate womb could be a rare uterine anomaly resulting from incomplete fusion of the 2 Müllerian ducts throughout embryo-genesis. This results in varied degrees of separation between 2 symmetrical uterine cavities starting from partial separation to complete separation with no communication between the 2 cavities.¹ Gestation in an exceedingly non-communicating rudimentary horn is incredibly difficult to diagnose before it ruptures, resulting in life threatening intra-peritoneal hemorrhage, though rupture might not occur until up to 16 weeks.⁶ Within the extreme case of gestation in an exceedingly rupture rudimentary horn of bicornuate womb, safe gestation management depends upon early and correct diagnosis to forestall complications such as uterine rupture.⁸ We present a case of a patient with a third trimester a live fetus in an exceedingly ruptured rudimentary horn of bicornuate womb.

Case Report. An 18-year-old Saudi female married for one year, primigravida in the third trimester (31 weeks) gestation, unbooked. Presented to the Emergency Department complaining of severe progressive abdominal pain, nausea, and vomiting for 3 days. There was no history of bleeding per vagina. Her menstruation began at age 14, she bleeds for 5 days with moderate flow each 28 days. There was no history of irregularity or dysmenorrhea. She had no method of contraception and was poorly followed during a health care center and was told to have bicornuate uterus in private clinic (no report). Her medical, surgical, and social past history was unremarkable. Clinical

Disclosure. Authors have no conflict of interest, and the work was not supported or funded by any drug company.

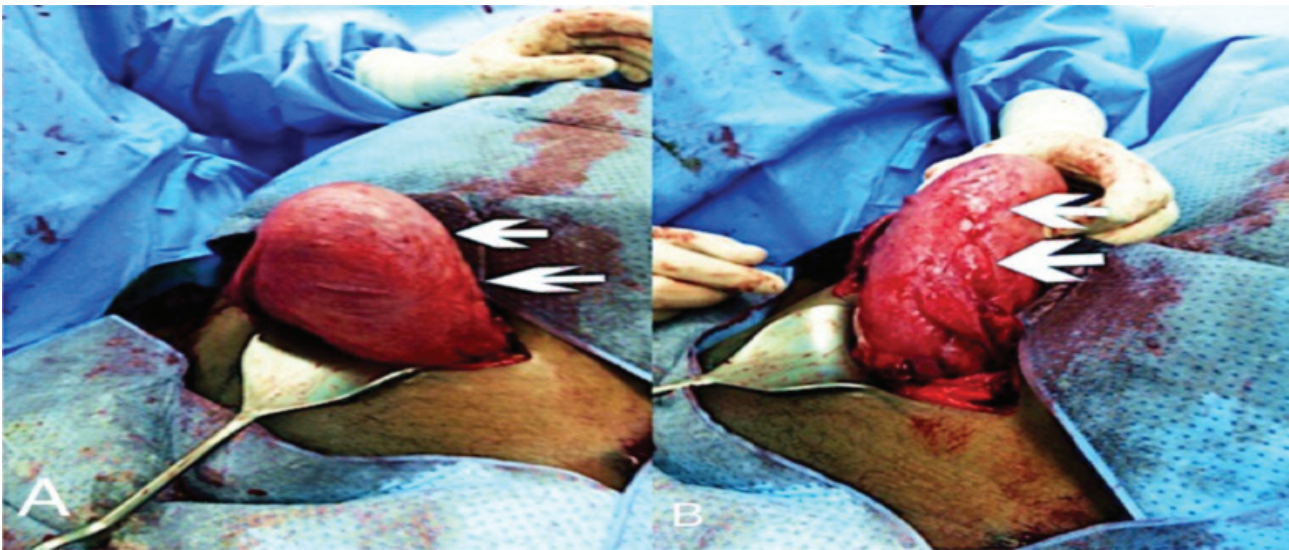


Figure 1 - Intra-operative cesarean section showing A) lower segment delivery and previous scar after excision of left ruptured rudimentary horn and B) left excision of rudimentary horn not heal.

assessment on admission the patient was irritable. She was afebrile, her pulse rate was 127 bpm, blood pressure 118/90 mm Hg, and respiratory rate was 20/min. Abdominal examination showed distension with generalized tenderness. The uterus was palpable at 32 weeks gestation. The preoperative investigation showed a hematocrit (Hct) of 35%, hemoglobin of 11 g/dl. She was taken for an exploratory laparotomy (ex-lab) under general anesthesia. Intraoperatively, there was a mild hemoperitoneum with a ruptured left rudimentary horn, with approximately 350 ml of blood within the greater peritoneal sac, a bicornuate womb with a ruptured left rudimentary horn containing a fetus weighing 1400 grams alive. Left rudimentary horn has its tube and ovary with a corpus luteum like structure, which horn was not communicating with the cervix or other horn, extensive fusion between the 2 horns was found. Excision of the rudimentary horn with ipsilateral salpingectomy was carried out, (Figure 1) after delivery of fetus through the rupture within the horn, which was extended. The patient made uneventful recovery, discharged in good condition, asked to follow up in outpatient clinic, but defaulted and failed to return for follow-up. The patient was advised to not get pregnant for at least 3 years, after one year, the patient came to the hospital in active labor at 37 weeks. Histopathology report revealed ruptured gravid uterine horn measuring 19, 9.5, 6 cm with small cavity and no cervix, and cut section revealed normal villi and decidua within a thick ended smooth muscle cavity. Placenta was normal.

Discussion. A rudimentary horn with a bicornuate uterus (complete type) occurs as a result of incomplete development of at least one of the Mullerian ducts, besides to the failure in fusion with the contralateral side.¹ Incidence rate of pregnancy in a rudimentary horn with a bicornuate uterus was estimated as 1 case per 100.000 up to 140.000 pregnancies.^{1,10} Pregnancy in a bicornuate rudimentary horn occurs through the transperitoneal migration of the sperm or the fertilized ovum.¹⁰ Studies indicated to a vast variation in rupture period, ranging from 5 to 35 weeks, and that was attributed to the ability of the horn musculature to hypertrophy and dilate, but it has been identified that around 70 to 90% occur before 20 weeks and these lead to catastrophic results.⁹ Hemoperitoneum in case of rudimentary horn pregnancy rupture due to the remarkable thickness of uterus wall that is characterized by being more vascular, in a study conducted by Kadan and Romano,⁷ they have stated that the most high threatening to pregnancy is the rudimentary horn rupture.⁸ Death rate at the beginning of the 20th century was reported as 47.6%.⁷ Several diagnostic tools are available to be utilized to identify the rupture, such as ultrasound, laparoscopy, MRI, and hysteroscopy.⁸

Studies have revealed that as pregnancy advances, the sensitivity decreases. Yet, there is no single determinant criterion that could detect ruptured rudimentary horn pregnancy in case of emergency, besides difficulty in diagnosis due to enlargement of the horn characterized by a thin myometrium obscuring surrounding anatomic structures.

Tsafir et al⁸ had reported 2 cases of ruptured rudimentary horn pregnancy in the first trimester that was diagnosed by sonography, and confirmed by MRI, they had pointed several diagnostic criteria for rudimentary horn pregnancy, such as the pseudo pattern of asymmetrical bicornuate uterus, the absence of visual continuity tissue surrounding the gestation sac and the uterine cervix, and The presence of myometrial tissue surrounding the gestational sac.¹⁰ It has been reported that pregnancy termination by labor induction agents is unsuccessful and leads finally to horn rupture. Main management strategy of rudimentary horn is the surgical removal. There are several examples of laparoscopic excision of rudimentary horn. Dicker et al.¹¹ had removed a small rudimentary horn through the suprapubic laparoscopic part. Moreover, Yoo et al¹² resected a pregnant horn of 5x5 cm laparoscopically. Yahata et al¹³ had used endoscopic stapler to transect a fibrous band connecting the rudimentary horn to uterus.^{10,5} Immediate surgery is highly recommended after the diagnosis even in unruptured cases.⁹ Furthermore, horn removal is advised before pregnancy occurrence to prevent future complications. Medical screen of another congenital abnormality such as urinary tract anomalies, as 38% have coexisting renal abnormalities.² Medical management with methotrexate is also reported, but no role in late gestational and alternative approaches in early gestational to abort the fetus.

In conclusion, Though rare, rudimentary horn pregnancy should be included in differential diagnosis of every practitioner facing an acute abdominal pain in pregnant woman. This case emphasizes the importance of good quality antenatal care in first trimester can reduce morbidity and mortality.

References

1. Moore KL, Persaud TVN, Torchia MG, editors. The Urogenital System. In *Before We Are Born: Essentials of Embryology and Birth Defects*. 7th ed. Philadelphia (PA): Saunders/Elsevier; 2008. p. 162-189.
2. Grimbizis GF, Camus M, Tarlatzis BC, Bontis JN, Devroey P. Clinical implications of uterine malformations and hysteroscopic treatment results. *Hum Reprod Update* 2001; 7: 161-174.
3. Jain R, Gami N, Puri M, Trivedi S. A rare case of intact rudimentary horn pregnancy presenting as hemoperitoneum. *J Hum Reprod Sci* 2010; 3: 113-115.
4. Panayotidis C, Abdel-Fattah M, Leggott M. Rupture of rudimentary horn of a unicornuate uterus at 15 weeks gestation. *J Obstet Gynaecol* 2004; 24: 323-324.
5. Reichman DE, Laufer MR. Congenital uterine anomalies affecting reproduction. *Best Pract Res Clin Obstet Gynaecol* 2010; 24: 193-208.
6. Siwath S, Mehra R, Pandher DK, Huria A. Rudimentary horn pregnancy: a 10-year experience and review of literature. *Arch Gynecol Obstet* 2013; 287: 687-695.
7. Kadan Y, Romano S. Rudimentary horn pregnancy diagnosed by ultrasound and treated by laparoscopy--a case report and review of the literature. *J Minim Invasive Gynecol* 2008; 15: 527-530.
8. Tsafir A, Rojansky N, Sela HY, Gomori JM, Nadjari M. Rudimentary horn pregnancy: first trimester pre-rupture sonographic diagnosis and confirmation by magnetic resonance imaging. *J Ultrasound Med* 2005; 24: 219-223.
9. Buntugu K, Ntumu M, Ameh E, Obed S. "Rudimentary horn pregnancy: pre-rupture diagnosis and management." *Ghana Med J* 2008; 42: 92-94.
10. Kanagal DV, Hanumanalu LC. Hanumanalu, "Ruptured Rudimentary Horn Pregnancy at 25 Weeks with Previous Vaginal Delivery: A Case Report," *Case Reports. Case Rep Obstet Gynecol* 2012; 2012: 985076.
11. Dicker D, Nitke S, Shoenfeld A, Fish B, Meizner I, Ben-Rafael Z. Laparoscopic management of rudimentary horn pregnancy. *Human Reproduction* 1998; 13: 2643-2644.
12. Yoo EH, Chun SH, Woo BH. Laparoscopic resection of a rudimentary horn pregnancy. *Acta Obstet Gynecol Scand* 1999; 78: 167-168.
13. Yahata T, Kurabayashi T, Ueda H, Kodama S, Chihara T, Tanaka K. Laparoscopic management of rudimentary horn pregnancy: a case report. *J Reprod Med* 1998; 43: 223-226.