

Received: 2020.03.05

Accepted: 2020.03.18

Available online: 2020.04.02

Published: 2020.05.05

Eosinophilic Angiocentric Fibrosis in Bilateral Upper Eyelid Conjunctivas: A First Case Report

Authors' Contribution:
Study Design A
Data Collection B
Statistical Analysis C
Data Interpretation D
Manuscript Preparation E
Literature Search F
Funds Collection G

ABEF 1,2 **Sho Okuyama**
ABCDEF 1,2,3 **Hiroyuki Yazu**
CDEF 4 **Yumi Ito**
CDE 5 **Hiroshi Minato**
ABEG 1,2,3 **Hiroshi Fujishima**

1 Department of Ophthalmology, Keio University Hospital School of Medicine, Tokyo, Japan
2 Department of Ophthalmology, Tsurumi University School of Dental Medicine, Yokohama, Kanagawa, Japan
3 Keio Allergy Center, Keio University Hospital, Tokyo, Japan
4 Division of Diagnostic Pathology, Tsurumi University Dental Hospital, Yokohama, Kanagawa, Japan
5 Department of Diagnostic Pathology, Ishikawa Prefectural Central Hospital, Kanazawa, Ishikawa, Japan

Corresponding Author: Hiroyuki Yazu, e-mail: g.h.yazu@gmail.com
Conflict of interest: None declared

Patient: Female, 55-year-old
Final Diagnosis: Eosinophilic angiocentric fibrosis
Symptoms: Lid swelling
Medication: Topical eye drops
Clinical Procedure: Resection of conjunctivas
Specialty: Ophthalmology

Objective: Rare disease

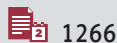
Background: Eosinophilic angiocentric fibrosis (EAF) is an extremely rare disease with characteristic histopathological findings of fibrotic onion-skin appearance and eosinophils. The lesion primarily affects the nasal cavity, paranasal sinus, and orbit. Although there have been approximately 78 cases of EAF reported in the literature to date, no cases of EAF in the eyelid conjunctiva have ever been reported.

Case Report: Herein, we describe the case of a 55-year-old Japanese woman with a history of eosinophilic sinusitis and EAF in bilateral upper eyelid conjunctivas who underwent surgical resection of the affected tissue. Histopathological examination revealed collagen bundles winding around the vessels in an onion-skin pattern, and the presence of eosinophils, lymphocytes, and plasma cells.

Conclusions: We describe the first reported case of EAF in bilateral upper eyelid conjunctivas. It can be successfully treated by surgical resection, and with no recurrence within 6 months postoperatively.

MeSH Keywords: Conjunctiva • Eosinophils • Immunohistochemistry • Lymphocytes • Plasma Cells

Full-text PDF: <https://www.amjcaserep.com/abstract/index/idArt/924042>




1266



2



6



23



Background

Eosinophilic angiocentric fibrosis (EAF) is an uncommon clinical condition that usually affects the nasal cavity, paranasal sinus, orbit, and, in rarer cases, it can affect the lacrimal gland, respiratory tract, retro orbit, and gingiva [1–5]. It was first described by Holmes and Panje [6] in 1983 as “intranasal granuloma faciale”. The histopathology of EAF typically involves concentric fibrosis surrounding arterioles, and the presence of numerous eosinophils [2]. In 1985, Roberts and McCann [7] described 3 similar cases and coined the histologically descriptive name [2]. There is no established treatment for EAF, but commonly used treatments include surgical resection, systemic and topical corticosteroids, and a combination of these 2 methods [2]. It has also been reported that rituximab improved serology test results and the lesions in a few cases of EAF.

To date, 78 cases of EAF have been reported in the scientific literature worldwide, including 61 in the nasal cavity, 23 in the paranasal sinus, 13 in the orbit, 4 in the respiratory tract, 3 in the lacrimal gland, 1 in the gingiva, and 1 behind the orbit [2,8–14]. Notably, however, no cases of EAF in the eyelid conjunctiva have ever been reported. Herein, we describe a case of bilateral EAF involving the upper eyelid conjunctivas.

Case Report

The patient was a 55-year-old Japanese woman with a history of sinusitis who had undergone endoscopic resection 2 years prior and was histologically diagnosed with eosinophilic sinusitis. Six months later, she exhibited bilateral upper eyelid conjunctival swelling without pain. The lesions were resistant to treatment with 0.05% epinastine hydrochloride ophthalmic solution (ALESION®, Santen Pharmaceutical, Osaka, Japan), 0.1% fluorometholone ophthalmic suspension (Flumetholon®, Santen Pharmaceutical, Osaka, Japan), and 0.1% tacrolimus ophthalmic suspension (TALYMUS®, Senju Pharmaceutical Co., Osaka, Japan) 4 times a day, so she was referred to our outpatient

clinic. The preoperative appearances of the conjunctival upper eyelids are shown in Figure 1.

The patient had a history of eosinophilic sinusitis but no history of drug allergies. The results of routine blood examinations and blood biochemistry were all within normal ranges. Levels of total IgG and other subtypes were normal, with the exception of serum IgG4, which was 179 mg/dL (normal range 11–121 mg/dL). Other autoimmune screening tests, including anti-Sjogren’s syndrome A antibody, anti-Sjogren’s syndrome B antibody, anti-PR3 antibody, anti-myeloperoxidase antibody, and antinuclear body, were all negative (Table 1). Magnetic resonance imaging of the head did not reveal any major complications or swelling in the lacrimal gland, salivary gland, or infraorbital nerve (Figure 2).

Treatment and follow-up

The patient underwent surgical resection without complications (Figure 3) and was treated with fluorometholone eye drop 4 times a day. Her postoperative course was uneventful. She was followed up every 2 months for approximately 6 months, during which there was no evidence of recurrence of the disease.

Pathologic findings

The specimens resected from both eyelid conjunctivas were characterized by hard lesions with a homogeneous yellowish-white solid and a macroscopically rough surface. Histological examination of the conjunctival mucosa showed marked chronic inflammation of submucosa and stromal fibrosis (Figure 4). The inflammatory infiltrate was composed of mature lymphocytes, plasma cells, and numerous eosinophils (Figure 5A). The conjunctival epithelium was characterized by the irregular growth of limbal epithelial cells due to inflammation. The stromal fibrosis showed concentric lamellar deposition of collagen/onion-skin-like appearance with scattered eosinophils around the blood vessels and focal storiform fibrosis (Figure 5B). There was no true granulomatous reaction,

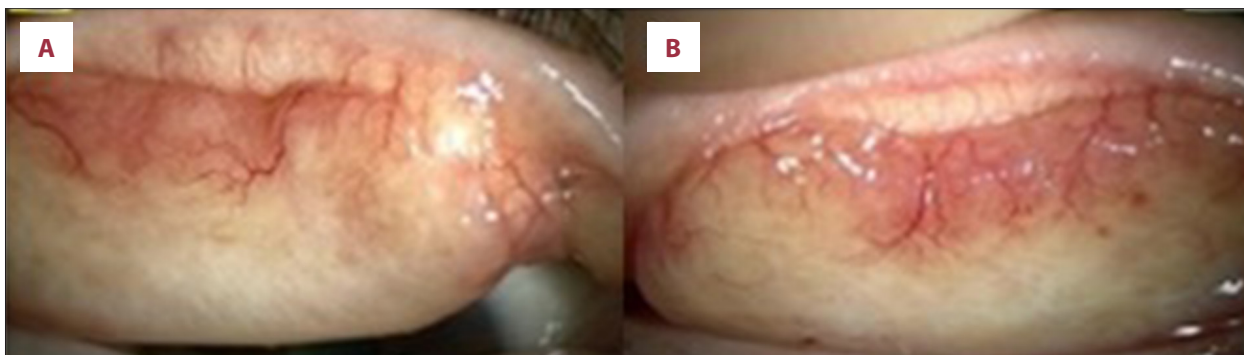

Figure 1. Preoperative upper eyelid conjunctiva findings. (A) Right and (B) left upper eyelid conjunctiva swelling involving pale lesions.

Table 1. Blood examination results.

Tests	Results	Units	Reference range
WBC	5.5	×10 ³ /μL	3.0–7.8
RBC	3.95	×10 ⁶ /μL	3.53–4.66
Plt	282	×10 ³ /μL	138–309
Bun	12.8	mg/dL	7–24
Cr	0.70	mg/dL	≤0.70
Na	141	mEq/L	135–147
CL	105	mEq/L	98–108
AST	20	U/L	8–38
ALT	13	U/L	4–44
CRP	0.09	mg/dL	≤0.3
Free T3	2.4	pg/mL	1.71–3.71
Free T4	1.3	ng/dL	0.70–1.48
TSH	1.51	μIU/mL	0.36–3.67
IgA	261	mg/dL	110–410
IgG	1241	mg/dL	870–1700

Tests	Results	Units	Reference range
IgG2	542	mg/dL	239–838
IgG4	179	mg/dL	11–121
IgM	73	mg/dL	52–270
C3	118	U/mL	80–140
C4	35	U/mL	17–45
RF	11	IU/mL	≤15
Anti-SSA antibody	(–)		
Anti-SSB antibody	(–)		
C-ANCA	(–)		
P-ANCA	(–)		
ANA	(–)		
C-ANCA	(–)		
P-ANCA	(–)		
ANA	(–)		

RF – rheumatoid factor; SSA – Sjogren’s syndrome A; SSB – Sjogren’s syndrome B; C-ANCA – anti-PR3 antibody; P-ANCA – anti-myeloperoxidase antibody; ANA – anti-nuclear antibody.

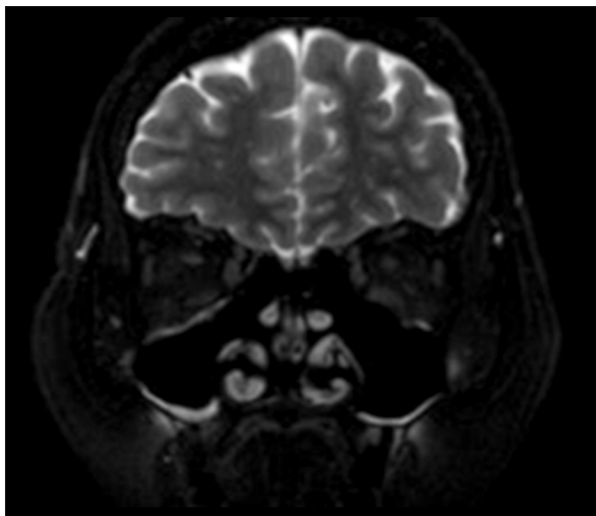


Figure 2. Magnetic resonance imaging (MRI) of the head, indicating that the lacrimal gland, salivary gland, and infraorbital nerve were intact.

cytologic atypia, or mitotic activity. Immunohistochemical staining for IgG4 showed that 68 plasma cells were positive for the IgG4/high-power field, and the IgG4/IgG ratio was 45% (Patholoscope, Mitani Co.). These findings are consistent with

IgG4-related diseases, which increase the number of IgG4-positive plasma cells and the IgG4/IgG ratio (Table 2). These histological features, such as eosinophilic vasculitis and angiocentric fibrosis with the onion-skin pattern, led us to diagnose this case as eosinophilic angiocentric fibrosis. In addition, fibrosis was pronounced in the left-side lesions, suggesting a more advanced stage.

Discussion

EAF is considered a benign disorder, and the diagnosis of EAF is based on histopathological findings characterized by inflammatory infiltration of eosinophils, fibrotic bundles around vessels, and an onion-skin pattern accompanied by fibrotic stroma [7,15]. These characteristic changes were evident in the present case. Seventy-eight cases of EAF have been described to date [2,8–14], and while the involvement of “neoplasms” or “inflammatory lesions” has been variously described, the exact pathology of EAF remains unclear. In the present case, fibrous inflammatory lesions were observed in the absence of any indications of malignancy.

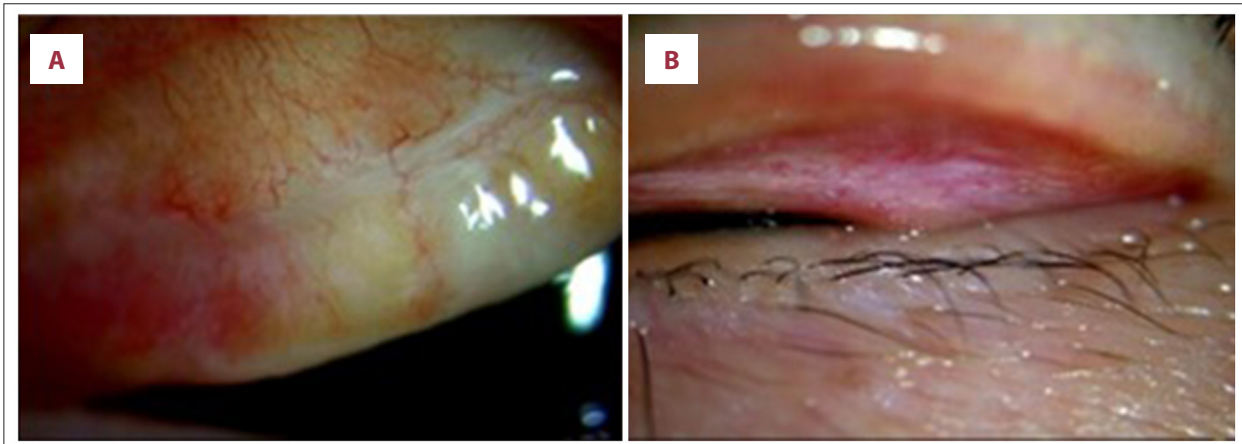


Figure 3. Postoperative observations in the upper eyelid conjunctivas. (A) Right and (B) left upper eyelid conjunctivas 2 months after surgery. Fibrotic lesions were surgically resected in both eyes.

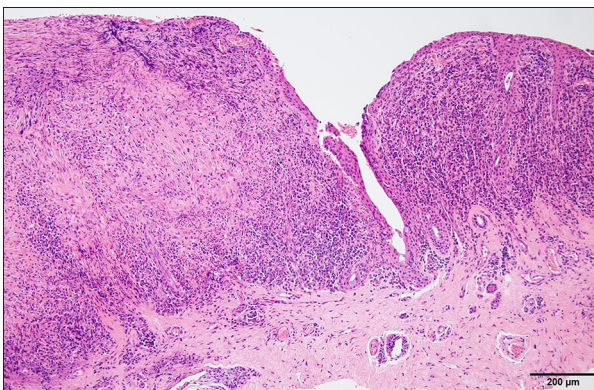


Figure 4. Histopathology image of a tissue sample from the upper conjunctiva of the left eye (hematoxylin and eosin staining, ×40 magnification). Infiltration of numerous inflammatory cells and fibrous connective tissue are evident.

During the early phase of EAF, the lesion consists of eosinophilic vasculitis with a mixture of lymphocytes and plasma cells. Inflammatory infiltration gradually becomes hypocellular, with increasing fibrosis [15]. The late phase of EAF is characterized by dense fibrous thickening of the stroma and perivascular onion-skin fibrotic changes [15]. Histopathological findings typical of

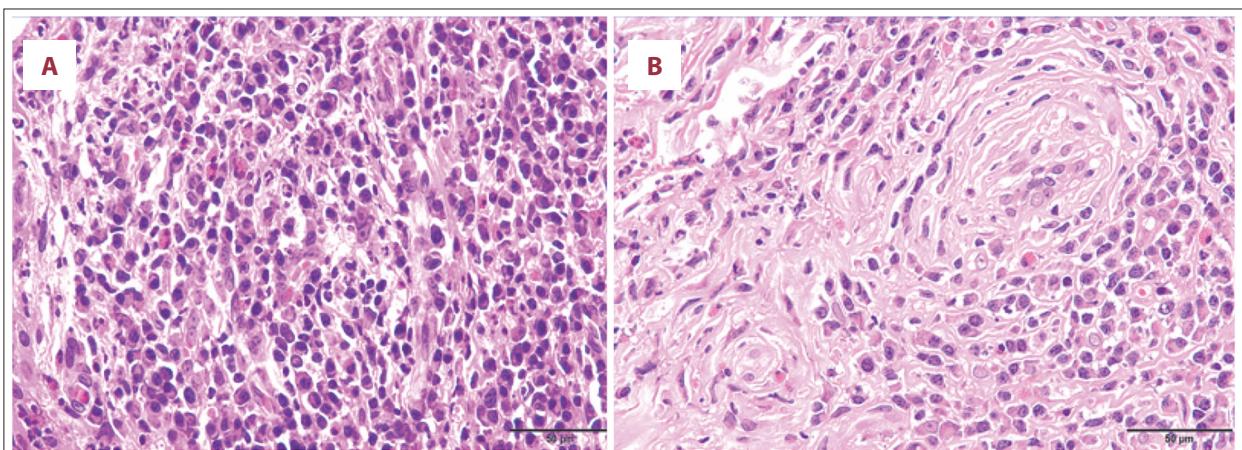


Figure 5. Histopathology images of tissue samples from the upper conjunctiva of the left eye (hematoxylin and eosin staining, ×200 magnification). (A) Inflammatory infiltration composed of mature eosinophils, lymphocytes, and plasma cells. (B) The conjunctival epithelium was characterized by the irregular growth of limbal epithelial cells due to inflammation. The stromal fibrosis showed concentric lamellar deposition of collagen/onion-skin-like appearance with scattered eosinophils around the blood vessels and focal storiform fibrosis.

Table 2. Diagnostic criteria.

Diagnosis of immunoglobulin G4 (IgG4)-related diseases
1. Clinical findings
Prominent or nodule-like lesion
2. Serological findings
IgG4 \geq 135 mg/dL
3. Histopathological findings
a. Infiltration with lymphocytes and plasma cells
b. IgG4-positive plasma cells \geq 10/high power field
c. Lesional IgG4: IgG ratio \geq 40%

both early phase (Figure 5A) and late phase (Figure 5B) EAF were observed in the present patient.

Though there is currently no consensus on the etiology of EAF. In 2011, Deshpande et al. [16] concluded that it belongs to the spectrum of IgG4-related diseases, which are characterized by a “tumefactive” or nodule-like lesion, large numbers of IgG4 positive plasma cells, and an elevated IgG4-positive to total IgG-positive cell ratio [2,8,16,17]. Criteria for the diagnosis of IgG4-related diseases are summarized in Table 2, and all findings in the present patient were concordant with items 1–3 therein. Prominent lesions in bilateral upper eyelids, swelling, and raised serum IgG4 (179 mg/dL) were observed. Histopathological examinations revealed lymphocytes and plasma cell infiltration, increased IgG4-positive plasma cells, and a 45% proportion of IgG4-positive cells.

The differential diagnosis of EAF includes the consideration of Churg-Strauss syndrome, granulomatosis with polyangiitis,

Kimura’s disease, Sjogren’s syndrome, and sarcoidosis [2,3]. Churg-Strauss syndrome and granulomatosis with polyangiitis are reactive conditions characterized by eosinophilic infiltration with systemic symptoms.

The lack of histologic features such as giant cells and necrosis aids in distinguishing EAF [2]. In this case, a negative blood test for ANCA helps exclude these diagnoses. Kimura’s disease reveals histologically inflammatory cells and fibrosis; however, it shows a prominent germinal center, not fibrotic stroma, around vessels. Sjogren’s syndrome is an autoimmune disease that affects the body’s moisture-producing glands. Primary symptoms are dry mouth and dry eyes. Sarcoidosis is a disease involving abnormal collections of inflammatory cells that form lumps known as granulomas. The disease usually begins in the lungs, skin, or lymph nodes and sometimes affects the eyes. However, the lack of systemic signs, negative autoimmune serology, and nonspecific MRI help exclude Sjogren’s syndrome and sarcoidosis. Furthermore, the well-developed angiocentric fibrosis in our case is highly characteristic of EAF.

No definitive treatment has been identified, but most cases are treated with surgical resection alone or combined with medication [1,18–21]. In 62% of surgeries, patients underwent complete resection, with a recurrence rate of 20% [10]. The recurrence rate is high and multiple excisions are frequently required [1,2]. The present case was considered IgG4-related disease, which was steroid-reactive, so we provided therapy with triamcinolone acetonide subconjunctival injection and 0.1% fluorometholone eye drop 4 times a day after surgery. The eye drops were gradually reduced, and she has been symptom-free for half a year after the resection.

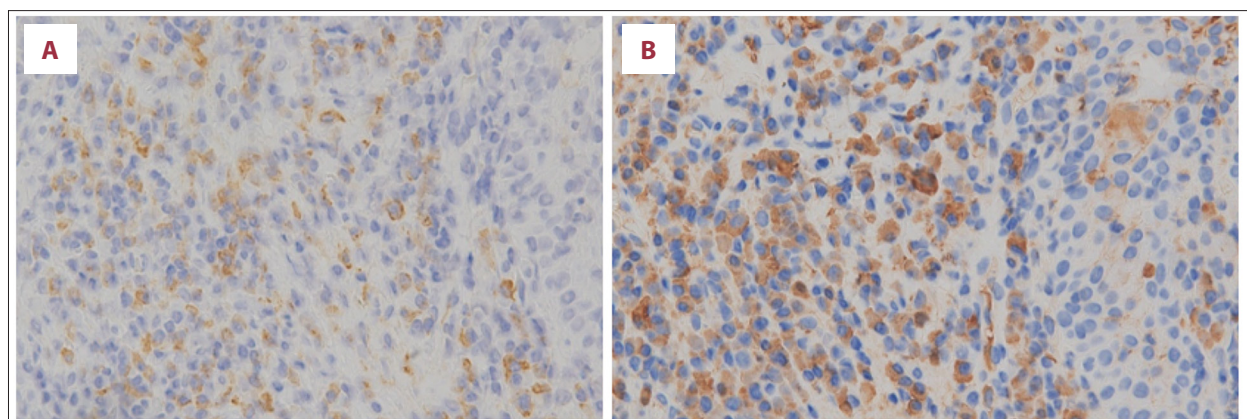


Figure 6. Immunohistochemical staining in the upper conjunctiva (high-power magnification). (A) Immunohistochemical staining for IgG4. A large number of IgG4-positive cells are evident (89–99 per high-power field). (B) Immunohistochemical staining for total IgG. A large number of IgG-positive cells are evident (approximately 205 cells per high-power field). Of all IgG-positive cells, 45% were IgG4-positive cells.

Although some studies reported that systemic rituximab administration was effective in treating EAF [22,23], we used only topically in this case, which had no sign of general symptoms.

Conclusions

Herein, we have described the first reported case of EAF involving bilateral upper eyelid conjunctivas. Surgical resection was successful, and no recurrence has occurred within 6 months after surgery.

References:

1. Jain R, Robblee JV, O'Sullivan-Mejia E et al: Sinonasal eosinophilic angiocentric fibrosis: A report of four cases and review of literature. *Head Neck Pathol*, 2008; 2(4): 309–15
2. Ahn J, Flanagan M: Eosinophilic angiocentric fibrosis: a review and update of its association with immunoglobulin G4-related disease. *Arch Pathol Lab Med*, 2018; 142(12): 1560–63
3. Keogh I, O'Connell R, Hynes S, Lang J et al: Eosinophilic angiocentric fibrosis as a stenosing lesion in the subglottis. *Case Rep Otolaryngol*, 2017; 2017: 42381786
4. Paun S, Lund V, Gallimore A et al: Nasal fibrosis: Long-term follow up of four cases of eosinophilic angiocentric fibrosis. *J Laryngol Otol*, 2005; 119(2): 119–24
5. Nigar E, Dhillon R, Carr E, Matin RN et al: Eosinophilic angiocentric fibrosis and extrafacial granuloma faciale. *Histopathology*, 2007; 51(5): 729–31
6. Holmes DK, Panje WR: Intranasal granuloma faciale. *Am J Otolaryngol*, 1983; 4(3): 184–86
7. Roberts PF, McCann BG: Eosinophilic angiocentric fibrosis of the upper respiratory tract: A mucosal variant of granuloma faciale? A report of three cases. *Histopathology*, 1985; 9(11): 1217–25
8. Hardman J, Toon C, Nirmalananda A et al: An unusual presentation of eosinophilic angiocentric fibrosis. *J Surg Case Rep*, 2017; 2017(12): rjx234
9. Fang CH, Mady LJ, Mirani NM et al: Sinonasal eosinophilic angiocentric fibrosis: A systematic review. *Int Forum Allergy Rhinol*, 2014; 4(9): 745–52
10. Heft Neal ME, Rowan NR, Willson TJ et al: A case report and systematic review of eosinophilic angiocentric fibrosis of the paranasal sinuses. *Ann Otol Rhinol Laryngol*, 2017; 126(5): 415–23
11. Bastaninejad S, Karimi E, Saeedi N, Amirizad E et al: Endoscopic pericranial flap design for the restoration of nasal mid-vault lining defects. *Int J Oral Maxillofac Surg*, 2018; 47(7): 865–68
12. Legare N, Frosh S, Vasquez JB, Ho ST: Eosinophilic angiocentric fibrosis: A sino-orbital masquerader. *BMJ Case Rep*, 2018; 2018: pii: bcr-2017-223675
13. Suárez AR, Capote AC, Barrientos Y et al: Ocular involvement in idiopathic hypertrophic pachymeningitis associated with eosinophilic angiocentric fibrosis: A case report. *Arq Bras Oftalmol*, 2018; 81(3): 250–53
14. Sazgar AA, Kia S, Akbari A et al: Nasal framework reconstruction in patient with eosinophilic angiocentric fibrosis. *Indian J Otolaryngol Head Neck Surg*, 2019; 71(Suppl. 3): 2031-2035
15. Okamoto K, Motoishi M, Kaku R et al: A surgical case of eosinophilic angiocentric fibrosis of the lung. *Surg Case Rep*, 2015; 1(1): 52
16. Deshpande V, Khosroshahi A, Nielsen GP et al: Eosinophilic angiocentric fibrosis is a form of IgG4-related systemic disease. *Am J Surg Pathol*, 2011; 35(5): 701–6
17. Deshpande V: IgG4 related disease of the head and neck. *Head Neck Pathol*, 2015; 9(1): 24–31
18. Nguyen DB, Alex JC, Calhoun B et al: Eosinophilic angiocentric fibrosis in a patient with nasal obstruction. *Ear Nose Throat J*, 2004; 83(3): 183–84, 186
19. Kiratli H, Onder S, Yildiz S, Ozşeker H et al: Eosinophilic angiocentric fibrosis of the orbit. *Clin Exp Ophthalmol*, 2008; 36(3): 274–76
20. Thompson LD, Heffner DK: Sinonasal tract eosinophilic angiocentric fibrosis. A report of three cases. *Am J Clin Pathol*, 2001; 115(2): 243–48
21. Li Y, Liu H, Han D et al: Eosinophilic angiocentric fibrosis of the nasal septum. *Case Rep Otolaryngol*, 2013; 2013: 267285
22. Stone JH, Zen Y, Deshpande V: IgG4-related disease. *N Engl J Med*, 2012; 366(6): 539–51
23. Gorostis S, Bacha M, Gravier S, Raguin T: Right ethmoid eosinophilic angiocentric fibrosis with orbital extension. *Eur Ann Otorhinolaryngol Head Neck Dis*, 2017; 134(5): 351–54

Acknowledgements

The authors thank Editage Company for English language editing.

Conflicts of interest

None.