

Performance status of targeted biopsy alone versus Sydney protocol by non-NBI expert gastroenterologist in gastric intestinal metaplasia diagnosis



Authors

Natee Faknak¹, Rapat Pittayanon¹, Kasenee Tiankanon¹, Nathawadee Lerttanatum², Anapat Sanpavat², Naruemon Klaikaew², Rungsun Rerknimitr¹

Institutions

- 1 Division of Gastroenterology, Department of Medicine, Faculty of Medicine, Chulalongkorn University and King Chulalongkorn Memorial Hospital, The Thai red Cross Society, Bangkok, Thailand
- 2 Department of pathology, Faculty of Medicine, Chulalongkorn University and King Chulalongkorn Memorial Hospital, The Thai Red Cross Society, Bangkok, Thailand

submitted 16.6.2021

accepted after revision 29.11.2021

Bibliography

Endosc Int Open 2022; 10: E273–E279

DOI 10.1055/a-1783-9081

ISSN 2364-3722

© 2022. The Author(s).

This is an open access article published by Thieme under the terms of the Creative Commons Attribution-NonDerivative-NonCommercial License, permitting copying and reproduction so long as the original work is given appropriate credit. Contents may not be used for commercial purposes, or adapted, remixed, transformed or built upon. (<https://creativecommons.org/licenses/by-nc-nd/4.0/>)

Georg Thieme Verlag KG, Rüdigerstraße 14,
70469 Stuttgart, Germany

Corresponding author

Rapat Pittayanon, MD, M.Sc., Associate Professor of Medicine, Division of Gastroenterology, Department of Medicine, Faculty of Medicine, Chulalongkorn University and King Chulalongkorn Memorial Hospital, Rama 4 Road, Patumwan, Bangkok, Thailand 10330
Fax: +087 200 6828
Rapat125@gmail.com

ABSTRACT

Background and study aims According to a recent guideline, patients with gastric intestinal metaplasia (GIM) should have at least five biopsies performed under the Sydney protocol to evaluate for risk of extensive GIM. However, only narrow-band imaging (NBI)-targeted biopsy may be adequate to diagnose extensive GIM.

Patients and methods A cross-sectional study was conducted between November 2019 and October 2020. Patients with histology-proven GIM were enrolled. All patients underwent standard esophagogastroduodenoscopy performed by a gastroenterology trainee. The performing endoscopists took biopsies from either a suspected GIM area (NBI-targeted biopsy) or randomly (if negative for GIM read by NBI) to complete five areas of the stomach as per the Sydney protocol. The gold standard for GIM diagnosis was pathology read by two gastrointestinal pathologists with unanimous agreement.

Results A total of 95 patients with GIM were enrolled and 50 (52.6%) were men with a mean age of 64 years. Extensive GIM was diagnosed in 43 patients (45.3%). The sensitivity, specificity, positive predictive value, negative predictive value, and accuracy of NBI-targeted biopsy vs. the Sydney protocol were 88.4% vs. 100%, 90.3% vs. 90.3%, 88.4% vs. 89.6%, 90.3% vs. 100%, and 89.5% vs. 94.7%, respectively. The number of specimens from NBI-targeted biopsy was significantly lower than that from Sydney protocol (311 vs. 475, $P < 0.001$).

Conclusions Both NBI-targeted biopsy and Sydney protocol by a gastroenterologist who was not an expert in NBI and who has experience with diagnosis of at least 60 cases of GIM provided an NPV higher than 90%. Thus, targeted biopsy alone with NBI, which requires fewer specimens, is an alternative option for extensive GIM diagnosis.

Introduction

Gastric cancer is the third leading cause of cancer-related death worldwide [1]. The well-known precancerous stage of gastric cancer is gastric intestinal metaplasia (GIM) [2]. The progres-

sion of GIM to gastric cancer over 5 years ranges from 0.25% to 42%, depending on risk factors [3, 4]. One of the major risk factors for gastric cancer development is extensive GIM involvement, defined as GIM involving the corpus of stomach [5]. When compared to GIM at the antrum only, the gastric cancer

risk is doubled, from 5.3% to 9.8%, in patients with extensive GIM during 5-year follow-up [6,7]. Thus, extensive GIM requires more frequent surveillance endoscopy [5].

Diagnosis of GIM needs close attention from an endoscopist for subtle mucosal changes, which can be easily overlooked [8]. Because white light endoscopy (WLE) alone is not sufficient to diagnose these changes, various techniques have been developed to enhance the sensitivity of detection, such as image-enhanced endoscopy (IEE) with or without magnification [9–11], otherwise an additional random biopsy (Sydney protocol) to cover the potential missing lesions is recommended for implementation [12]. In 2019, British Society of Gastroenterology guidelines recommended the use of IEE, e.g. narrow band imaging (NBI) plus five more biopsies under the Sydney protocol (two areas at antrum, two areas at body, and one at incisura) to ensure complete GIM evaluation [5]. However, previous studies [9] reported that the sensitivity, specificity, and negative predictive value (NPV) of GIM diagnosis by experts performing targeted biopsy under NBI was excellent at 92%, 94%, and 94%, respectively. According to the Preservation and Incorporation of Valuable endoscopic Innovations (PIVI), the acceptable screening protocol threshold should exceed 90% of NPV [13]. This may imply that NBI-targeted biopsy alone may be adequate to diagnose extensive GIM.

To date, there has been no direct comparison of the performance status of targeted biopsy with NBI and NBI-targeted biopsy plus random biopsies under the Sydney protocol in patients with GIM. Moreover, all previous studies related to the benefit of targeted biopsy involved experts in NBI [9–11]. Therefore, this study aimed to compare the performance status of these two strategies for diagnosis of extensive GIM, performed gastroenterologists who were not expert at NBI.

Patients and methods

We conducted a cross-sectional single-center study at tertiary care hospital, King Chulalongkorn Memorial Hospital (KCMH), Bangkok, Thailand between November 2019 and October 2020. Eligible participants were patients with at least one histology-proven GIM regardless of GIM extension, aged 18 years or older between 2010 and 2019.

Study patients were called back for surveillance esophago-gastroduodenoscopy between November 2019 and October 2020 by a third-year gastrointestinal fellow. Patients were excluded from the study if they: 1) underwent upper gastrointestinal surgery; 2) had uncontrolled bleeding tendencies, defined by platelet count <50,000 or international normalized ratio >2.5 after corrections; 3) could not stop taking anticoagulants for at least 7 days before the procedure; or 4) were pregnant at the time of enrollment. Baseline characteristics, gastrointestinal symptoms, *Helicobacter pylori* infection status, and endoscopic findings were collected. Rapid urease test (Clo test: Lencomm Trade International, Warschau, Poland) was performed in every patient prior to application of the biopsy protocol for GIM diagnosis. Verbal and written informed consent for protocol enrollment were obtained before the procedures.

Procedure

All patients underwent esophagogastroduodenoscopy (EGD) by one endoscopist (third-year gastroenterology fellow), who had performed EGD with WLE in more than 600 cases a year but who had only performed NBI under supervision for GIM diagnosis in fewer than 20 cases during the 2-year training program. There was no extra course for NBI training. In this study, the assigned endoscopist was blinded to the previous EGD and pathology results of all enrolled patients. Other endoscopists were not allowed to come into the endoscopy suite during the procedure. This study used the Olympus EVIS EXERA III GIF-HQ190 (Olympus Medical System Corps, Tokyo, Japan) gastro-scope with dual magnification in all procedures.

During the procedure, all patients were in the left lateral decubitus position and received propofol with a 0.5- to 1-mg/kg bolus, followed by 0.25- to 0.5-mg/kg/hr continuous infusion until moderate sedation level was achieved. The endoscopist (KT) performed standard WLE to inspect the entire upper gastrointestinal mucosa, as is standard procedure. After completion of the standard procedure, NBI mode with magnification was used to enhance visualization of GIM in five areas according to the Sydney protocol; 1) lesser curvature at 2 to 3 cm above the pylorus; 2) greater curvature at 2 to 3 cm above the pylorus; 3) lesser curvature at 4 cm above from the incisura; 4) greater curvature at 8 cm below the cardia; and 5) incisura. NBI with magnification criteria for GIM diagnosis included: 1) large long crest; 2) light blue crest; or 3) villous pattern [14]. Although extensive GIM in this study was defined as presentation of GIM in the body of the stomach [5], the endoscopist performed five biopsies in every patient to confirm the diagnosis of GIM because the previous study showed that approximately 30% of patients with GIM regressed to chronic atrophic gastritis [15]. The endoscopist recorded the presence of GIM in each area and performed a targeted biopsy of the suspected GIM under NBI guidance (NBI-targeted biopsy). In areas in which GIM could not be detected by NBI guidance, a random biopsy was taken to complete five specimens (one each from five areas recommended by the Sydney protocol) [5]. The biopsy tissue from each different area was placed in a separate container and interpreted independently by two gastrointestinal pathologists. In addition, the assigned endoscopist reported the confidence (low or high) for extensive GIM diagnosis in each patient. After completion of gastroscopy, patients were transferred to the recovery room and monitored as a standard post-procedure protocol until discharge with assistance of their designated caretaker.

Histopathological analysis

The gold standard for GIM diagnosis is current histopathology under the Sydney protocol. Each biopsy specimen was separately preserved in a 10% formalin solution, and was subsequently processed with hematoxylin-eosin (H&E) staining. Two experienced gastrointestinal pathologists (AS, NL) who were blinded to the clinical, previous pathology and endoscopic findings reviewed all biopsy specimens independently. World Health Organization Classification [16] was referred to as the

standard criteria for identifying presence of GIM and other findings. Disagreement between the two gastrointestinal pathologists was solved by the additional opinion of another senior gastrointestinal pathologist (NW). The presence of GIM, *H. Pylori*, and other conditions was reported after reaching a consensus among the three pathologists.

Study outcomes

The primary outcomes of this study were validity scores including: sensitivity, specificity, positive predictive value (PPV), NPV, positive likelihood ratio (PLR), negative likelihood ratio (NLR), and accuracy of NBI-targeted endoscopic biopsy alone, compared to the Sydney protocol for extensive GIM diagnosis. The secondary outcomes were: 1) the learning curve for extensive GIM diagnosis by using NBI; and 2) comparison of the number of specimens for extensive GIM diagnosis between NBI-targeted biopsy alone and Sydney protocol.

Statistical analysis

Based on data from a previous study, the sensitivity of NBI-guided biopsy was 92% [9]. The prevalence of extensive GIM in our population was 30% and the sample size was calculated to be 95 participants by using α -error of 0.08 with a 95% level of confidence. Categorical variables were expressed as frequencies and percentages. Continuous variables were expressed as means and standard deviations. Data between the two groups were compared using Chi-squared test and unpaired *t*-test where appropriate. The validity of diagnosis of GIM was expressed in terms of sensitivity, specificity, PPV, NPV, PLR, NLR, and accuracy. The sensitivity and specificity were displayed as a receiver operating characteristic curve (ROC). The area under curve of the two biopsy techniques was compared using binomial confidence interval for the area under the ROC (AUROC). A two-sided $P < 0.05$ was considered statistically significant. Analyses were performed using SPSS version 22.0 (SPSS, Chicago, Illinois, United States).

The protocol was approved by the Chulalongkorn Medical Institutional Review Board (IRB No. 644/62) and registered in ClinicalTrials.gov, NCT04331951.

Results

A total of 95 patients (50 men and 45 women) with mean age of 64.7 ± 10.8 years were enrolled in the study. Current smoking was noted in 19 patients (20%). Antiplatelet therapy and use of proton-pump inhibitors (PPIs) were noted in 10 (10.5%) and 15 patients (15.8%), respectively. The majority of included patients had mild dyspeptic and/or gastroesophageal reflux symptoms (78 of 95; 82.1%). The remaining patients (17 of 95; 17.9%) had no gastrointestinal symptoms and came in for surveillance. A current *H. pylori* infection was diagnosed in 13 patients (13.7%) patients (► **Table 1**).

Among 95 patients, 43 (45.3%) had histologically proven GIM at the corpus of the stomach and were diagnosed with extensive GIM, while 52 patients (54.7%) were diagnosed with non-extensive GIM. Baseline characteristics in terms of gender, smoking, use of antiplatelet and PPI medications, and *H. pylori*

► **Table 1** Baseline characteristics of all included patients.

Characteristics	Total (n=95)
Patient demographics	
▪ Male, n (%)	50 (52.6)
▪ Age, years (SD)	64.7 (10.8)
▪ Smoking, n (%)	19 (20.0)
▪ Antiplatelet use, n (%)	10 (10.5)
▪ PPI use, n (%)	15 (15.8)
Symptom	
▪ Dyspepsia, n (%)	58 (61.1)
▪ Gastroesophageal reflux symptom, n (%)	10 (10.5)
▪ Dyspepsia and gastroesophageal reflux symptom, n (%)	10 (10.5)
▪ No gastrointestinal symptoms, n (%)	17 (17.9)
Current <i>H. pylori</i> status	
▪ Positive, n (%)	13 (13.7)
▪ Eradicated, n (%)	25 (26.3)
▪ uninfected status, n (%)	57 (60)
SD, standard deviation; PPI, proton pump inhibitor.	

status did not differ between groups. However, in the extensive GIM group, fewer patients had no gastrointestinal symptoms (dyspepsia and/or gastroesophageal reflux disease) than in the non-extensive GIM group (4 (9.3%) vs 13 (25%), $P = 0.04$) (► **Table 2**). The technical success rate was 100% with no complications.

When compared to the gold standard, NBI-targeted biopsy alone demonstrated a sensitivity of 88.4%, specificity of 90.3%, PPV of 88.4%, and NPV of 90.3%. These were calculated as PLR of 9.1, NLR of 0.09, and accuracy of 89.5% (► **Table 3**). On the other hand, NBI-targeted biopsy plus random biopsy with the Sydney protocol provided sensitivity of 100%, specificity of 90.3%, PPV of 89.6%, NPV of 100%, and an accuracy of 94.7%. These also were calculated as PLR of 10.3 (► **Table 3**). NBI-targeted biopsy alone missed extensive GIM in five of 95 patients (5.2%).

The AUROC curve of the NBI-targeted biopsy alone was 0.882, which was significantly lower than that of the Sydney protocol (0.882 vs. 0.952, $P < 0.001$) (► **Fig. 1**). The two gastrointestinal pathologists (NT and AS) provided 100% agreement on the GIM diagnosis; therefore, none required the third pathologist (NW).

The assigned endoscopist reported high confidence in 50 from 95 cases (52.6%) and low confidence in 45 from 95 cases (47.4%) for extensive GIM diagnosis. Importantly, all last 35 cases were diagnosed extensive GIM with high confidence. So, she needed only 60 cases of GIM to achieve competency of $> 90\%$ NPV for extensive GIM diagnosis by using NBI with high

► **Table 2** Baseline characteristics in the extensive and non-extensive intestinal metaplasia groups.

Characteristics	Extensive (n = 43)	Non-extensive (n = 52)	P value
Patient demographics			
▪ Male, n (%)	24 (55.8)	26 (50.0)	0.57
▪ Age, years (SD)	65.9 (9.8)	64.1 (11.4)	0.43
▪ Smoking, n (%)	10 (23.3)	9 (17.3)	0.47
▪ Antiplatelet use, n (%)	5 (11.6)	5 (9.6)	0.75
▪ PPI use, n (%)	8 (18.6)	7 (13.5)	0.49
Symptom			
▪ Dyspepsia, n (%)	30 (69.8)	28 (53.8)	0.12
▪ Gastroesophageal reflux symptom, n (%)	7 (16.3)	3 (5.8)	0.09
▪ Dyspepsia and gastroesophageal reflux symptom, n (%)	2 (4.6)	8 (15.4)	0.08
▪ No gastrointestinal symptoms, n (%)	4 (9.3)	13 (25.0)	0.04
Current <i>H. pylori</i> status			
▪ Positive, n (%)	4 (9.3)	9 (17.3)	0.51
▪ Eradicated, n (%)	13 (30.2)	12 (23.1)	0.53
▪ uninfected status, n (%)	26 (60.5)	31 (59.6)	0.48

SD, standard deviation; PPI, proton pump inhibitor.

► **Table 3** Validity scores of NBI-targeted biopsy and Sydney protocol for extensive GIM diagnosis.

Validity scores of extensive gastric intestinal metaplasia GIM diagnosis	NBI-targeted biopsy alone	Sydney protocol (NBI-targeted biopsy plus random biopsy)
Sensitivity (%)	88.4 (38/43)	100 (43/43)
Specificity (%)	90.3 (47/52)	90.3 (47/52)
PPV (%)	88.4 (38/43)	89.6 (43/48)
NPV (%)	90.3 (47/52)	100 (52/52)
Likelihood ratio		
▪ PLR	9.1 (0.884/0.097)	10.3 (1/0.097)
▪ NLR	0.13 (0.116/0.903)	-(0/0.903)
Accuracy (%)	89.5 (85/95)	94.7 (90/95)

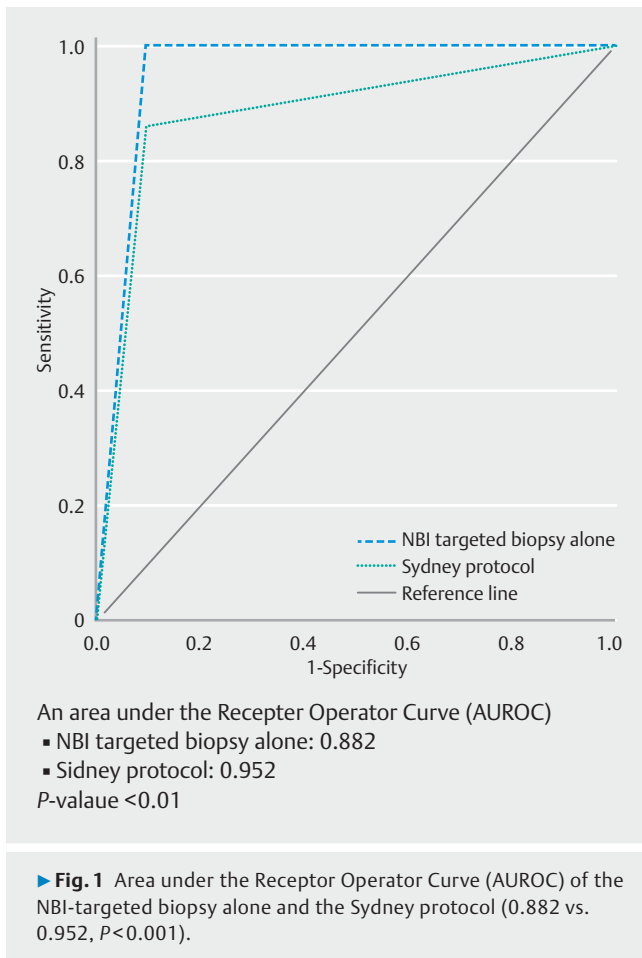
NBI, narrow-band imaging; GIM, gastrointestinal metaplasia; PPV, positive predictive value; NPV, negative predictive value; PLR, positive likelihood ratio; NLR, negative likelihood ratio.

level of confidence (► **Fig. 2**). The number of specimens from NBI-targeted biopsy protocol was significantly lower than that from Sydney protocol (311 vs. 475, $P < 0.001$) for extensive GIM diagnosis.

Discussion

According to the 2019 recommendation by the British Society of Gastroenterology, GIM surveillance to establish a diagnosis of extensive GIM should be based on targeted biopsy under IEE plus random biopsy within the Sydney protocol to reach five

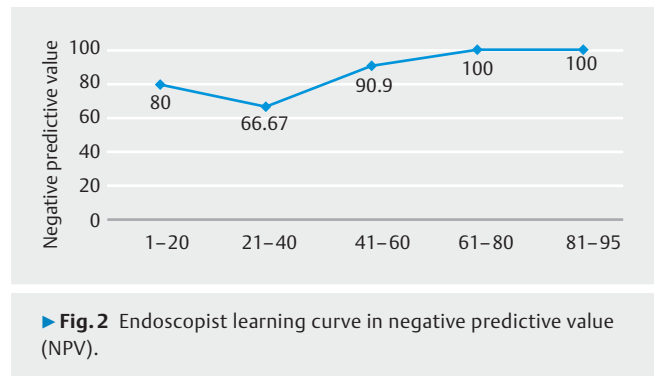
biopsies in total [5]. However, the concept of random biopsy under the Sydney protocol was initiated more than two decades ago [12]. At that time, random biopsy might be necessary to increase the chance of diagnosing premalignant lesions and early gastric cancer because those lesions, including GIM, were difficult to visualize with old-fashioned WLE plus IEE technology was lacking. For example, up to 22% of patients (23 of 103) who were diagnosed with chronic gastritis or benign gastric polyps using an Olympus H260 or PENTAX EPK-i-scan were subsequently diagnosed with high-grade dysplasia and early gastric cancers at 3-month follow-up EGD [17]. This showed the high



miss rate for gastric cancer detection by using the former endoscope.

In the past decade, however, IEE technology has evolved rapidly from a suboptimal tool for experimental use only to the recommended tool for standard practice in diagnosing early gastrointestinal malignancies and precancerous lesions including GIM. Historically, Xirouchakis et al [18] used the second-generation IEE endoscope (Olympus EXERA II, CV-180) to diagnose GIM and showed a lower sensitivity of NBI-targeted biopsy compared to random biopsy (72% vs. 80%). Two years later, the third-generation endoscope with better image definition and brighter IEE technology was launched (Olympus EVIS EXERA III GIF-HQ190). Our group adopted this newly-released endoscope for assessment of gastric lesions including GIM and found that NBI-targeted biopsy had significantly higher sensitivity than targeted biopsy with high-definition WLE (92% vs. 59% $P<0.01$) [9]. This supported the hypothesis that the current IEE endoscope may have achieved an acceptable PIVI threshold (NPV >90%) for targeting GIM lesions.

In the present study, we also used EVIS EXERA III GIF-HQ190, which revealed that targeted biopsy with NBI alone is adequate for extensive GIM diagnosis with a high NPV of 90.3%. This exceeded the acceptable performance threshold outlined by the American Society for Gastrointestinal Endoscopy (ASGE) and PIVI threshold for a screening endoscopy tool, which indicated



the acceptable NPV for an endoscopic test at $\geq 90\%$ when assessments are made with high confidence [13]. Although the targeted biopsy protocol had a lower AUROC curve compared to the Sydney protocol (0.882 vs 0.952), both were acceptable in clinical practice. Moreover, NBI-targeted biopsy requires fewer specimens, consequently diminishing the total expense for GIM evaluation. We found that under the NBI-targeted biopsy protocol, the number of specimens submitted to a pathologist decreased to only 65%, compared with the original Sydney protocol (311 specimens vs. 465 specimens, $P<0.001$). This minimal endoscopic approach has been proposed in the long-term follow-up study in patients with GIM led by our group [15]. We could reduce the number of “unnecessary” biopsies and identified six patients with high-grade dysplasia or early gastric cancer from 91 patients with a history of GIM in the 5-year follow-up (6.6%) [15]. Importantly, we did not miss any high-grade dysplasia or gastric cancer diagnoses in those GIM patients during 1 to 3 years of follow-up with EGD by an endoscopist who was expert at NBI. Recently, a multicenter study in Europe demonstrated the limitation of the random biopsy protocol, as 32% of patients with premalignant gastric cancer lesions were “misclassified” as low risk for gastric cancer development when following the Sydney protocol [19]. In fact, these patients were classified as “low risk” and would have been discharged from the gastric cancer surveillance program. However, they called these “low-risk” patients back a year later for additional EGD and found that one-third of them needed to be reclassified to that of “high-risk” patients. Compared to our study, only 5.2% of the targeted biopsy protocol by trainee missed the “high-risk” patients for gastric cancer development. Thus, improvement in endoscopic diagnosis for gastric premalignant lesion is much more important than continuing to perform random biopsies.

Our study raised another important point, which is that a gastroenterologist who is not an expert in NBI expert may be able to optimally diagnose GIM by using an NBI-targeted biopsy alone, as its NPV can pass the PIVI threshold after performing EGD in 60 GIM cases. The objective of assigning an endoscopist who was not an expert in NBI to perform EGD was to generalize the study outcomes to all levels of medical care. In fact, GIM diagnosis by IEE requires only a short learning curve to reach excellent sensitivity and high accuracy [20]. This study showed a trend that a trainee can achieve high diagnostic accuracy for

extensive GIM diagnosis when using NBI-targeted biopsy with a short learning curve. However, this hypothesis should be confirmed by further study that includes more endoscopists. Nevertheless, a gastroenterology training curriculum should provide training in IEE for premalignant and early gastric cancer detection instead of implementing random biopsy for surveillance of many early gastrointestinal malignancies, such as GIM [5, 21] and Barrett's esophagus (BE) [22, 23]. For instance, in 2016, a guideline from the American College of Gastroenterology (ACG) strongly suggested that at least eight biopsies be taken in patients with BE during EGD surveillance [22]. In addition, the 2020 guideline from the American Gastroenterological Association (AGA) recommended that in patients with BE undergoing complete endoscopic resection and that random biopsy under a four-quadrant protocol should be performed during the follow-up period [23].

Our study has limitations. First, we included only one trainee as the performing endoscopist. Although this minimized inter-observer bias, repetitive EGD under NBI for GIM diagnosis might have improved the skill of the trainee in GIM diagnosis under NBI over time. Despite that, the trainee was blinded to pathological reports of all included patients until the end of the study to decrease the effect of feedback from reading results. Second, the outcome of the study might have been influenced by the Hawthorne effect, which means that the endoscopists may have put forth a higher effort to detect GIM during the study than in their daily practice. Because this was a prospective study and the endoscopist had to know and understand the protocol prior for performing procedures, the Hawthorne effect was inevitable. Nevertheless, this implies that best practice standards that we expect from them are possible to achieve during daily clinical practice. Third, this study was at risk of incorporation bias, which occurs when the gold standard is used to determine the result of the diagnostic study [24]. The Sydney protocol contained both endoscopic findings and the result of pathology, which is the gold standard for GIM diagnosis. Thus, the Sydney protocol always has 100% sensitivity. However, we demonstrated a comparable NPV, which is the most important indicator for diagnostic tests including an NBI-targeted biopsy protocol and the Sydney protocol for extensive GIM diagnosis. Fourth, this study did not include patients without GIM; consequently, it may be difficult to apply the results to daily clinical practice. Finally, this study was conducted in a single center. A multicenter trial is warranted to prove generalizability.

Conclusions

Although NBI-targeted biopsy for diagnosis of extensive performed by a gastroenterology trainee had a slightly lower AUR-OC value than with the Sydney protocol, both achieved a NPV >90% and passed the PIVI threshold. Thus, when a trainee has experience with ≥ 60 cases of GIM, targeted biopsy alone with NBI, which requires fewer specimens, is an alternative option for diagnosis of extensive GIM.

Acknowledgements

The authors thank the English editing service, Research Affairs, Faculty of Medicine, Chulalongkorn University for English editing.

Competing interests

The authors declare that they have no conflict of interest.

Funding

Research grant GAT 2019, the Gastroenterological Association of Thailand.

Ratchadapiseksompotch Fund, Chulalongkorn University (grant number RA 63/033).

This study is supported in part by matching fund 2020 from the Royal College of Physicians of Thailand.

Clinical trial

clinicaltrials.gov

NCT04331951

TRIAL REGISTRATION: single-center, cross-sectional study at clinicaltrials.gov

References

- Bray F, Ferlay J, Soerjomataram I et al. Global cancer statistics 2018: GLOBOCAN estimates of incidence and mortality worldwide for 36 cancers in 185 countries. *CA Cancer J Clin* 2018; 68: 394–424
- Correa P, Piazuelo MB. The gastric precancerous cascade. *J Dig Dis* 2012; 13: 2–9
- Rokkas T, Filipe MI, Sladen GE. Detection of an increased incidence of early gastric cancer in patients with intestinal metaplasia type III who are closely followed up. *Gut* 1991; 32: 1110–1113
- de Vries AC, van Grieken NC, Looman CW et al. Gastric cancer risk in patients with premalignant gastric lesions: a nationwide cohort study in the Netherlands. *Gastroenterology* 2008; 134: 945–952
- Banks M, Graham D, Jansen M et al. British Society of Gastroenterology guidelines on the diagnosis and management of patients at risk of gastric adenocarcinoma. *Gut* 2019; 68: 1545–1575
- Shichijo S, Hirata Y, Niikura R et al. Histologic intestinal metaplasia and endoscopic atrophy are predictors of gastric cancer development after *Helicobacter pylori* eradication. *Gastrointest Endosc* 2016; 84: 618–624
- Zali H, Rezaei-Tavirani M, Azodi M. Gastric cancer: prevention, risk factors and treatment. *Gastroenterol Hepatol Bed Bench* 2011; 4: 175–185
- Menon S, Trudgill N. How commonly is upper gastrointestinal cancer missed at endoscopy? A meta-analysis. *Endosc Int Open* 2014; 2: E46–E50
- Ang TL, Pittayanon R, Lau JY et al. A multicenter randomized comparison between high-definition white light endoscopy and narrow band imaging for detection of gastric lesions. *Eur J Gastroenterol Hepatol* 2015; 27: 1473–1478
- Wu C, Namasivayam V, Li JW et al. A prospective randomized tandem gastroscopy pilot study of linked color imaging vs white light imaging

- for detection of upper gastrointestinal lesions. *J Gastroenterol Hepatol* 2021; 36: 2562–2567
- [11] Savarino E, Corbo M, Dulbecco P et al. Narrow-band imaging with magnifying endoscopy is accurate for detecting gastric intestinal metaplasia. *World J Gastroenterol* 2013; 19: 2668–2675
- [12] Dixon MF, Genta RM, Yardley JH et al. Classification and grading of gastritis. The updated Sydney System. International Workshop on the Histopathology of Gastritis, Houston 1994. *Am J Surg Pathol* 1996; 20: 1161–1181
- [13] Abu Dayyeh BK, Thosani N, Konda V et al. ASGE Technology Committee systematic review and meta-analysis assessing the ASGE PIVI thresholds for adopting real-time endoscopic assessment of the histology of diminutive colorectal polyps. *Gastrointest Endosc* 2015; 81: 502 e1–e16
- [14] Rerknimitr R, Imraporn B, Klaikeaw N et al. Non-sequential narrow band imaging for targeted biopsy and monitoring of gastric intestinal metaplasia. *World J Gastroenterol* 2011; 17: 1336–1342
- [15] Pittayanon R, Rerknimitr R, Klaikeaw N et al. The risk of gastric cancer in patients with gastric intestinal metaplasia in 5-year follow-up. *Aliment Pharmacol Ther* 2017; 46: 40–45
- [16] Yakirevich E, Resnick MB. Pathology of gastric cancer and its precursor lesions. *Gastroenterol Clin North Am* 2013; 42: 261–284
- [17] Ren W, Yu J, Zhang ZM et al. Missed diagnosis of early gastric cancer or high-grade intraepithelial neoplasia. *World J Gastroenterol* 2013; 19: 2092–2096
- [18] Xirouchakis E, Laoudi F, Tsartsali L et al. Screening for gastric premalignant lesions with narrow band imaging, white light and updated Sydney protocol or both? *Dig Dis Sci* 2013; 58: 1084–1090
- [19] Mommersteeg MC, Nieuwenburg SAV, den Hollander WJ et al. Accuracy of upper endoscopies with random biopsies to identify patients with gastric premalignant lesions who can safely be exempt from surveillance. *Gastric Cancer* 2021; 24: 680–690
- [20] Pittayanon R, Rerknimitr R, Wisedopas N et al. Flexible spectral imaging color enhancement plus probe-based confocal laser endomicroscopy for gastric intestinal metaplasia detection. *J Gastroenterol Hepatol* 2013; 28: 1004–1009
- [21] Dinis-Ribeiro M, Areia M, de Vries AC et al. Management of precancerous conditions and lesions in the stomach (MAPS): guideline from the European Society of Gastrointestinal Endoscopy (ESGE), European Helicobacter Study Group (EHS), European Society of Pathology (ESP), and the Sociedade Portuguesa de Endoscopia Digestiva (SPED). *Endoscopy* 2012; 44: 74–94
- [22] Shaheen NJ, Falk GW, Iyer PG et al. American College of G. ACG Clinical Guideline: Diagnosis and Management of Barrett's Esophagus. *Am J Gastroenterol* 2016; 111: 30–50; quiz 1
- [23] Sharma P, Shaheen NJ, Katzka D et al. AGA Clinical Practice Update on Endoscopic Treatment of Barrett's Esophagus With Dysplasia and/or Early Cancer: Expert Review. *Gastroenterol* 2020; 158: 760–769
- [24] Lijmer JG, Mol BW, Heisterkamp S et al. Empirical evidence of design-related bias in studies of diagnostic tests. *JAMA* 1999; 282: 1061–1066