

Penumbra aspiration thrombectomy of the superior mesenteric artery for mesenteric ischemia

Brandon A. Creisher, BS, Prashanth Palvannan, MD, MPH, Dawn M. Salvatore, MD, Paul J. DiMuzio, MD, Babak Abai, MD, and Michael J. Nooromid, MD, Philadelphia, PA

ABSTRACT

Acute mesenteric ischemia from thromboembolic occlusion is a life-threatening emergency associated with a high mortality rate. Prompt diagnosis and intervention are vital to preserve viable bowel and prevent mortality. In the past decade, a shift has occurred toward minimally invasive alternatives such as endovascular therapies. We present a case of acute mesenteric ischemia from superior mesenteric artery thrombosis treated promptly with the Penumbra suction thrombectomy device (Penumbra Inc). (J Vasc Surg Cases Innov Tech 2023;9:101278.)

Keywords: Acute mesenteric ischemia; Aspiration thrombectomy; Penumbra system; Superior mesenteric artery thromboembolic occlusion

Acute mesenteric ischemia (AMI) from thromboembolic occlusion is a potentially fatal vascular emergency with an overall mortality rate as high as 80%.¹ Early diagnosis and intervention are vital to restore mesenteric blood flow and preserve viable bowel. Before the past decade, laparotomy was the standard of care to assess and treat bowel ischemia. The diagnostic evaluation has significantly improved with the development of multidetector computed tomography angiography (CTA) and has led to decreased bowel ischemia times. In addition to better diagnostics, the increase in endovascular therapies and minimally invasive alternatives has improved outcomes, such as a shorter average length of resected bowel and lower 30-day mortality compared with open surgical treatment.²⁻⁴ We present a case of AMI from superior mesenteric artery (SMA) thrombosis treated by aspiration thrombectomy, followed by diagnostic laparoscopy. The patient provided written informed consent for the report of her case details and imaging studies.

CASE REPORT

The patient is a 63-year-old woman with a history of newly identified SARS-CoV-2 (severe acute respiratory syndrome coronavirus 2) infection, coronary artery disease requiring quadruple vessel bypass, aortoiliac disease with prior end-to-side aortobifemoral bypass, hypertension, hyperlipidemia, and chronic obstructive pulmonary disease. She presented to our institution with a 1-day history of abdominal pain,

diarrhea, and hematochezia. The laboratory test results on admission included arterial blood gas, pH 7.46; bicarbonate, 23 mmol/L; anion gap, 15 mEq/L; lactate, 1.4 mmol/L; creatinine, 0.6 mg/dL; white blood cell count, $23.5 \times 10^9/L$ hemoglobin, 14.6 g/dL; and COVID-19 (coronavirus disease 2019) positivity.

Her presentation prompted CTA of the abdomen and pelvis, which revealed a heavily calcified SMA with distal, long segment, completely occlusive thrombus (Fig 1). Her CTA findings were also notable for a stenotic right common femoral artery (CFA), a patent celiac axis, a patent aortobifemoral bypass, and complete occlusion of her native aorta, inferior mesenteric artery, and bilateral common, external, and internal iliac arteries. Although her SMA changes appeared chronic and no evidence of bowel infarction was found, her persistent symptoms and leukocytosis prompted urgent surgical intervention ~6 hours after her presentation to the emergency department. Given her comorbidities and previous abdominal surgery, we opted for an endovascular-first approach. Access was obtained through the left CFA because both brachial arteries were not adequate for mesenteric intervention at ~3 to 4 mm, and her right CFA was stenotic and calcified at 4.5 mm in size. We chose to cannulate the left CFA because minimal plaque was present and the vessel was ~8 mm in diameter, with a 1.75-cm distance between the distal anastomosis and femoral bifurcation (Fig 2). Once access was achieved, we successfully traversed the bypass graft and achieved wire access to the SMA with an Aptus Tour Guide (Medtronic) steerable sheath. Initial angiography showed a distal SMA thrombus with no flow to the right colon. Using the CAT6 Penumbra suction thrombectomy device (Penumbra Inc), we significantly improved the perfusion, as seen on the pre- and post-thrombectomy images (Fig 3). Finally, we addressed a stenotic left aortobifemoral to CFA anastomosis via angioplasty with a 6 × 40 mm Advance 35LP low-profile PTA balloon (Cook Medical; Fig 2). Next, diagnostic laparoscopy, performed by acute care surgery, ensured no bowel ischemia was present. Postoperatively, the patient did well and was eventually discharged with clopidogrel 75 mg once daily (Plavix; Bristol-Myers Squibb – Sanofi Pharmaceuticals partnership) and apixaban 5 mg twice daily

From the Division of Vascular Surgery, Department of Surgery, Thomas Jefferson University Hospital.

Author conflict of interest: none.

Correspondence: Michael J. Nooromid, MD, Division of Vascular Surgery, Department of Surgery, Thomas Jefferson University Hospital, 111 S 11th St, Ste 6210, Philadelphia, PA 19107 (e-mail: Michael.Nooromid@jefferson.edu).

The editors and reviewers of this article have no relevant financial relationships to disclose per the Journal policy that requires reviewers to decline review of any manuscript for which they may have a conflict of interest.

2468-4287

© 2023 The Authors. Published by Elsevier Inc. on behalf of Society for Vascular Surgery. This is an open access article under the CC BY-NC-ND license (<http://creativecommons.org/licenses/by-nc-nd/4.0/>).

<https://doi.org/10.1016/j.jvscit.2023.101278>

(Eliquis; Bristol-Myers Squibb) on postoperative day 10 after receiving SARS-CoV-2 treatment.

DISCUSSION

This case report demonstrates the benefit of minimally invasive treatment of AMI in a patient with low physiologic reserve due to multiple comorbidities. AMI commonly presents in the elderly at high risk of open surgical complications.^{1,5} In these patients with a low suspicion of necrotic bowel, we suggest the fully minimally invasive option of AMI endovascular treatment, followed by diagnostic laparoscopy.

Open revascularization, followed by explorative laparotomy, remains the gold standard for the management of AMI. However, endovascular therapy has been increasingly used as a revascularization strategy. In addition to our case report, others have reported technical success with the Penumbra suction thrombectomy system for AMI.^{6,7} In recent years, an endovascular-first approach has become more popular owing to the improved 30-day mortality and decreased length of stay with endovascular strategies.²⁻⁴ A large analysis from the National Surgery Quality Improvement Program showed a 2.5-fold decrease in the risk of death associated with endovascular-first therapy.⁸ The endovascular-first approach is best suited for patients with multiple comorbidities and no signs of bowel necrosis (leukocytosis [white blood cell count $>10,000/\text{mm}^3$], elevated lactate, pneumatosis intestinalis, bowel dilation or free intraperitoneal fluid on computed tomography).⁹⁻¹¹ For these patients, the benefits to avoiding open revascularization and explorative laparotomy include reduced morbidity and mortality associated with entering the peritoneum and a shorter length of stay.¹² However, these studies are subject to selection bias, and a randomized controlled trial is needed to determine the superiority of the interventions.

Open bowel resection is required for the management of bowel infarction. Patients with an acute abdomen on examination or signs of bowel necrosis and/perforation on imaging are brought emergently to the operating room for laparotomy, bowel resection, and revascularization with SMA embolectomy. For the present patient, laparotomy and open embolectomy were considered; however, given her body habitus, the reoperative nature of her abdomen, multiple comorbidities, including COVID-19 positivity with chronic obstructive pulmonary disease and coronary artery disease, and evidence of distal anastomotic stenosis of the left limb of the aortobifemoral graft, we believed endovascular intervention would be more expeditious and less morbid. Open vs endovascular revascularization should be determined on a case-by-case basis, and consideration should be given to the patient's condition, imaging findings, and the

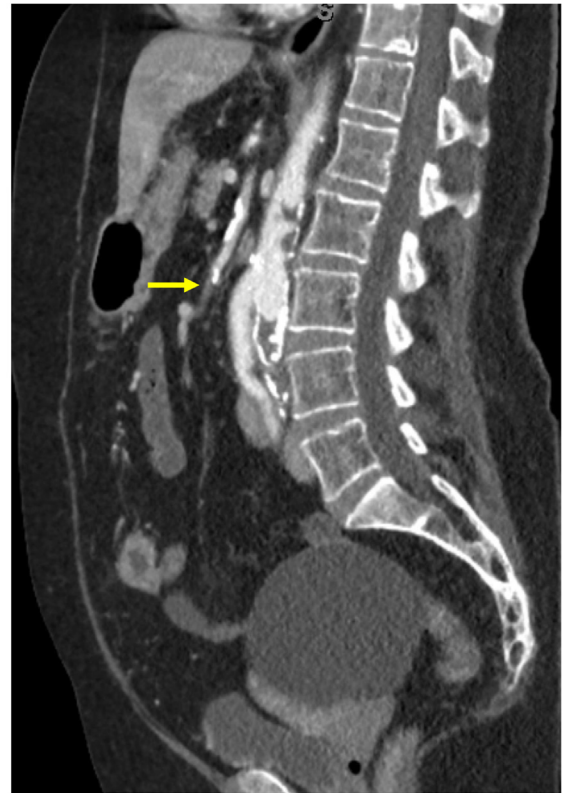

Fig 1. Sagittal computed tomography angiography (CTA) image showing superior mesenteric artery (SMA) occlusion (arrow).

surgeon's skill set and available tools. If eventual conversion to laparotomy is necessary, the benefit of endovascular revascularization is not completely lost because it has the added advantage of not leaving behind prosthetic material, such as Prolene suture or graft material, which can be necessary with open repair.

This case report is an important example of a medically and surgically complex patient who benefited from an endovascular-first approach to treat AMI. Even with suboptimal lower extremity access and difficult SMA cannulation through a previous aortobifemoral bypass, we believe this challenging endovascular procedure was ultimately beneficial to the patient compared with an open surgical approach.

CONCLUSIONS

Patients with multiple comorbidities presenting with AMI without signs of necrotic bowel are good candidates for minimally invasive management with an endovascular-first approach, followed by diagnostic laparoscopy. The Penumbra aspiration thrombectomy system was an effective option for this patient presenting with AMI.

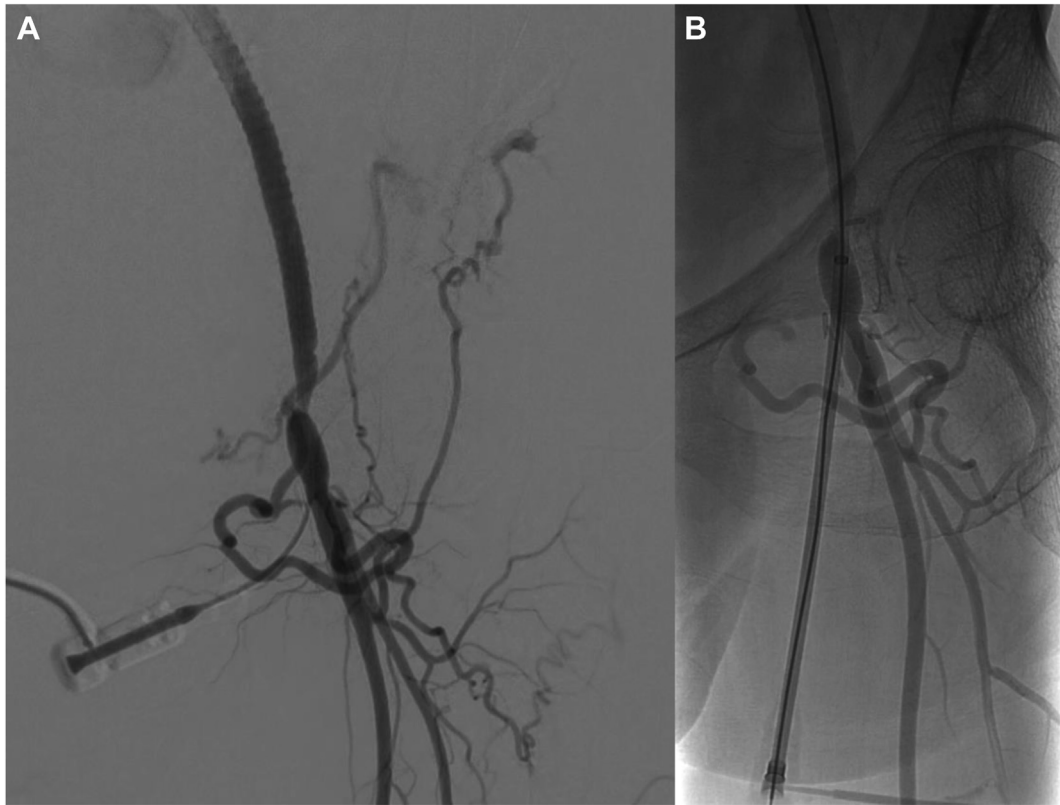


Fig 2. Angiographic images from before (A) and after (B) angioplasty of the left common femoral artery (CFA) access site showing left aortobifemoral stenotic anastomosis with improvement after angioplasty.

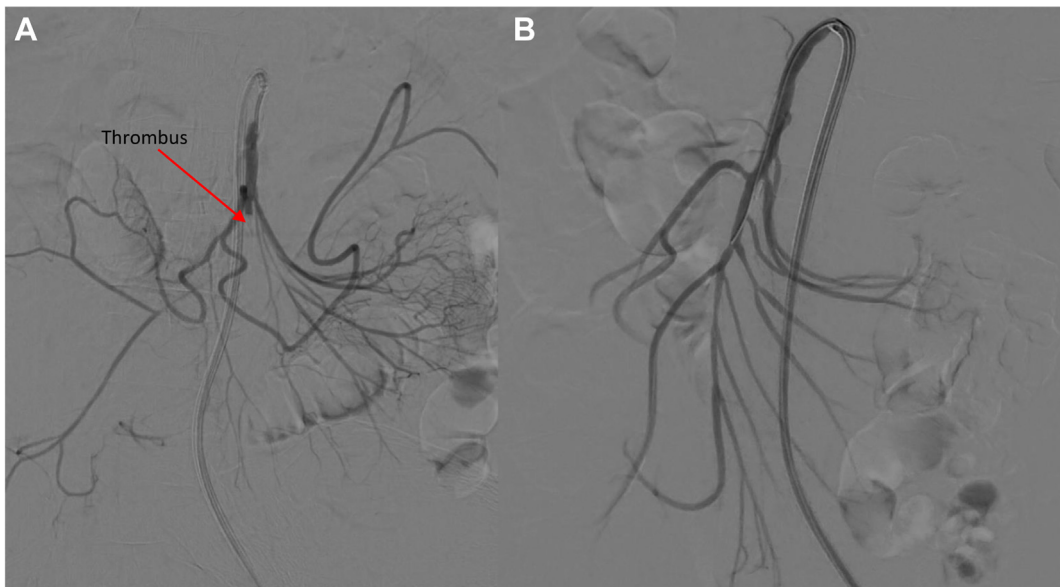


Fig 3. Angiographic images from before (A) and after (B) thrombectomy of the superior mesenteric artery (SMA) showing improved blood flow and perfusion to the right colon with restored distal branch.

REFERENCES

1. Oldenburg WA, Lau LL, Rodenberg TJ, Edmonds HJ, Burger CD. Acute mesenteric ischemia: a clinical review. *Arch Intern Med* 2004;164:1054-62.
2. Arthurs ZM, Titus J, Bannazadeh M, et al. A comparison of endovascular revascularization with traditional therapy for the treatment of acute mesenteric ischemia. *J Vasc Surg* 2011;53:698-704; discussion: 704-5.
3. Beaulieu RJ, Arnaoutakis KD, Abularrage CJ, Efron DT, Schneider E, Black JH 3rd. Comparison of open and endovascular treatment of acute mesenteric ischemia. *J Vasc Surg* 2014;59:159-64. Erratum in: *J Vasc Surg*. 2014 Jul;60(1):273.
4. Zhang Z, Wang D, Li G, et al. Endovascular treatment for acute thromboembolic occlusion of the superior mesenteric artery and the outcome comparison between endovascular and open surgical treatments: a retrospective study. *Biomed Res Int* 2017;2017:1964765.
5. Kärkkäinen JM, Acosta S. Acute mesenteric ischemia (part I) – incidence, etiologies, and how to improve early diagnosis. *Best Pract Res Clin Gastroenterol* 2017;31:15-25.
6. Mak AK, Andraska EA, Reitz KM, Chaer R, Eslami MH, Avgerinos E. A single institutional experience with suction thrombectomy in acute mesenteric ischemia. *Ann Vasc Surg Brief Rep Innov* 2022;2:100070.
7. Genzel P, Van Dijk LC, Veger HTC, et al. Case report: direct revascularization in acute mesenteric ischemia by an endovascular approach. *CVIR Endovasc* 2019;2:31.
8. Branco BC, Montero-Baker MF, Aziz H, Taylor Z, Mills JL. Endovascular therapy for acute mesenteric ischemia: an NSQIP analysis. *Am Surg* 2015;81:1170-6.
9. Canfora A, Ferronetti A, Marte C, et al. Predictive factors of intestinal necrosis in acute mesenteric ischemia. *Open Med* 2019;14:883-9.
10. Nuzzo A, Maggiori L, Ronot M, et al. Predictive factors of intestinal necrosis in acute mesenteric ischemia: prospective study from an intestinal stroke center. *Am J Gastroenterol* 2017;112:597-605.
11. Emile SH. Predictive factors for intestinal transmural necrosis in patients with acute mesenteric ischemia. *World J Surg* 2018;42:2364-72.
12. Lim S, Halandras PM, Bechara C, Aulivola B, Crisostomo P. Contemporary management of acute mesenteric ischemia in the endovascular era. *Vasc Endovasc Surg* 2019;53:42-50.

Submitted Mar 12, 2023; accepted Jul 3, 2023.