

ORIGINAL CONTRIBUTION

Histological and immunohistochemical changes in facial skin treated with combined ablative and non-ablative laser therapy

Natalia A. Shanina MD¹ | Alexander V. Patrushev MD¹ | Anže Zorman MD² 

¹S. M. Kirov Military Medical Academy, Sankt Petersburg, Russian Federation

²Medilase, Ljubljana, Slovenia

Correspondence

Anže Zorman, Medilase, Ljubljana, Slovenia.

Email: zormanze@gmail.com

Abstract

Background: Facial skin rejuvenation is a highly sought after procedure. Different materials, energy-based devices and techniques have been shown to offer good results in facial rejuvenation.

Aims: The aim of this study was to evaluate the macroscopic and histological and immunohistochemical changes in facial skin treated with a combined laser therapy.

Patients/Methods: Fourteen patients aged from 38 to 59 years were included in the study. Two different wavelengths (2940 and 1064 nm) were used in this four-step procedure.

Results: Significant improvement according to classification for age-related changes in all areas of the face was achieved. There were also significant structural changes in the epidermis and dermis, confirmed with histology and immunohistochemistry.

Conclusion: The dual-wavelength protocol has been found to provide excellent results for facial rejuvenation.

KEYWORDS

4D, Er:YAG, facial rejuvenation, histology, Nd:YAG

1 | INTRODUCTION

The appearance of one's skin reflects a person's general health and is one of the main indicators of human age.¹ As skin ages, it tends to become uneven in color, roughened, lax, and wrinkled due to intrinsic and extrinsic factors (eg, photodamage). A major feature of aged skin is fragmentation of the dermal collagen matrix. Fragmentation results from the actions of specific enzymes (matrix metalloproteinases) and impairs the structural integrity of the dermis. Fibroblasts that produce and organize the collagen matrix cannot attach to fragmented collagen. Loss of attachment prevents fibroblasts from receiving mechanical information from their support, and they collapse.² Stretch is critical for normal balanced production of collagen and collagen-degrading enzymes. In aged skin, collapsed fibroblasts produce low levels of collagen and high levels of collagen-degrading

enzymes. This imbalance advances the aging process in a self-perpetuating, never-ending deleterious cycle.²

Many different materials, energy-based devices, and techniques have been shown to offer good results in facial rejuvenation.³ Ablative techniques are still considered the most effective methods for improving photodamaged skin, but are associated with a prolonged recovery time and high risk of side effects.⁴ The CO₂ and Er:YAG (2940 nm) wavelengths are ablative wavelengths used for many different applications including facial skin resurfacing. Ablative lasers vaporize the epidermis and part of the dermis, leaving a zone of thermal injury responsible for collagen shrinkage and remodeling.⁵⁻⁷ Post-procedure, the epidermis has to heal, requiring at least some recovery time. Non-invasive and minimally/non-ablative methods without downtime are therefore gaining popularity in modern dermatological laser therapy. Recently, a non-ablative mode of

This is an open access article under the terms of the Creative Commons Attribution-NonCommercial-NoDerivs License, which permits use and distribution in any medium, provided the original work is properly cited, the use is non-commercial and no modifications or adaptations are made.

© 2021 The Authors. *Journal of Cosmetic Dermatology* published by Wiley Periodicals LLC.

using an Er:YAG (2940 nm) wavelength was introduced, where laser energy is delivered onto the tissue in a fast sequence of low-fluence laser pulses, producing a larger degree of thermal effect compared with conventional Er:YAG laser settings.⁸⁻¹⁵ The mechanism of non-ablative dermal remodeling is the minimal trauma and/or heating of (epi)dermis caused by laser, including the microcirculatory complex, that leads to the changes, stimulating the activity of fibroblasts and restructuring of collagen.^{12,16}

In order to be able to offer minimal to zero recovery time while maintaining high effectiveness, a combined approach using different wavelengths and/or different pulse durations is usually needed and produces better results.¹⁷⁻¹⁹ Marini²⁰ previously used a combination of two laser wavelengths: 0.3 and 35 ms Nd:YAG laser pulses, followed by fractional Er:YAG laser with 600 μ s pulse duration. He reported improved skin texture and wrinkle depth reduction, which remained or continued to improve for 2 months after treatment. There were no side effects.

The objective of this study was to evaluate the macroscopic and histological and immunohistochemical changes in the skin of the face treated with a combined ablative (2940 nm) and non-ablative laser therapy (2940 and 1064 nm).

2 | MATERIALS AND METHODS

2.1 | Patients

Fourteen patients aged from 38 to 59 years were included in the study. There were two males and 12 females with Fitzpatrick skin type I-III. We previously developed an index (IOVIKL) for assessing the age-related changes of the facial skin. Four qualities of the skin are taken into account: age spots (size and intensity), number of wrinkles, depth of wrinkles, and pores (size and severity). Each of these is graded on a four point system (0-no, 1-little, 2-average, and 3-many), and each third of the face is evaluated and graded separately. The points are then summed up; the maximum score is 36, the minimum is 0; a score of 1-12 determines mild, 13-24 moderate, and 25-36 severe changes. According to this classification, the average value of the index of age-related changes in the skin of the 14 enrolled patients was 29.5 points (23-35, median 27).

Subjects were excluded if they: had undergone any other anti-aging procedure within 2 months, had an active localized or systemic infection, had a history of photosensitivity to laser, or were pregnant or nursing. All subjects read and signed an informed consent form, which was approved by the independent local ethical Committee of the Military Medical Academy in Saint Petersburg, Russia (No 189 from May 23, 2017).

2.2 | Laser treatment procedure

The procedure, commercially referred to as Fotona 4D[®], was carried out using an SP Dynamis laser system (Fotona).

Two different wavelengths were used in this four-step procedure. The first step was performed using an Er:YAG patterned handpiece with a 5-7 mm spot size, 7-10 J/cm², and frequency of 1.6 Hz. The non-ablative mode (Fotona SMOOTH[®]) was used. For the second and third steps, 1064 nm Nd:YAG was used; the second step was performed using a 4 mm spot, fluence of 25-50 J/cm², 0.3 ms pulse duration, and frequency of 2-5 Hz; the third step used a 9 mm spot, 100 J/cm² fluence, and 2 s pulse duration in order to achieve deep and homogeneous bulk heating. The last step is superficial, light-ablative polishing of the skin using Er:YAG laser, with a fluence of 1.5 J/cm², 8-30 Hz frequency, 4-7 mm spot size, and 0.1 ms pulse duration. Oral mucosa was treated in the first step, and all of the face was treated homogeneously in the second, third, and fourth steps. Two procedures were performed with a 1-month interval. No anesthesia was needed; cold air cooling using Cryo 6 (Zimmer) was used to increase the patient's comfort. Patients were encouraged to use topical sun protection (SPF-50 Anthelios XL, La Roche-Posay) and topical regenerating cream (Cicaplast BAUME B5, La Roche-Posay) for at least 2 weeks after each therapy.

2.3 | Histology

Excision biopsy of the skin in the chin area was performed before and at 2 months after the final treatment. Biopsies with dimensions of 5 × 9 mm were prepared in accordance with standard procedure. The sections were stained with hematoxylin and eosin and with van Gieson's stain and subjected to microscopic examination using a ZEISS Axio Imager 1 (Zeiss). Immunohistochemical detection of collagen fibers and endothelial cells of newly formed capillaries was also carried out using anti-human mouse monoclonal antibodies. The polymer immunohistochemical detection systems REAL EnVision (Dako Inc.) was used for cell detection, where diaminobenzidine (DAB) (Dako Inc.) was used as a chromogen. Digital images were obtained using a Leica DC 500 camera (Leica, Microsystem).

Five different methods were undertaken. Analysis of morphological changes was carried out using light microscopy examination of the sections. Secondly, epidermal thickness was measured. It was determined from the level of basal cells to the upper boundary of the stratum lucidum. The exclusion of the stratum corneum from the measurement was due to the wide variability of its thickness. We also measured microvessel density by applying a point grid with 200 equidistant points, followed by marking and counting the number of microvessels that coincided with the point grid. According to the principle of M. Delesse (1847), the fraction of the substance in the heterogeneous system corresponds to the fraction in the cross section. Finally, we used Morphology 5.2 to determine the number of collagen fibers in the specimens stained by van Gieson's stain and the amount of CD34 or collagen IV antigen by immunohistochemistry using specific antibodies (QBEND-10 and COL-94).

2.4 | Statistics

We used the following software packages: Statistica for Windows 6.0—for statistical analysis, the specialized program SkinXPPro (South Korea)—for the formation, grouping, and analysis of sample sets of objects according to specific physiological parameters of the skin; the VideoTest-Morphology 5.2 program for digital processing of immunohistochemical images and calculation of descriptive statistics of the sample. The following procedures and methods of statistical analysis were used: check for normality of distribution using the Kolmogorov–Smirnov test, assessment of the significance of differences in quantitative variables in related samples according to the nonparametric Wilcoxon test, and correlation analysis using Spearman's nonparametric correlation coefficient. The conclusion about the static significance was given at $\alpha = 0.05$.

3 | RESULTS

All 14 patients were assessed before the procedure and then 1 and 2 months after the second procedure. The IOVIKL index was used

TABLE 1 Median scores of age-related skin changes according to IOVIKL index measured before laser treatments and at 1- and 2-month follow-up sessions

	Before	After 1 month	After 2 months
IOVIKL median score (range)	27.0 (23–35)	20.5 (19–22)	12.0 (11–15)

to assess age-related changes to the skin. The results are shown in Table 1 and Figures 1 and 2. Results 1 and 2 months after are statistically significantly different from the baseline ($p < 0.001$).

Twenty-eight tissue samples (14 biopsied before and 14 biopsied 2 months after second laser treatment) were examined with all five methods described in Section 2.

Histological appearance consistent with aging skin, such as thinning of the basal membrane of the epidermis, cell atrophy, and lower cell count, was observed in samples taken before the laser therapy. Samples taken after laser therapy showed an increase in the number and activity of fibroblasts, an increase in the density of connective tissue after laser treatment, and more eosinophilic ground substance of connective tissue as a manifestation of the fibroblasts' activity (Figure 3). The average epidermal thickness before was $38.03 \mu\text{m} \pm 0.59$ and $59.4 \mu\text{m} \pm 0.53$ after two laser treatment (Figure 4).

Light microscopy evaluation also revealed glomeruloid angiogenesis, referring to the highly complex vascular aggregates that resemble glomeruli of the kidney, which was activated in response to tissue alteration by laser light (Figure 5). A secondary finding was an accompanying increase in the cellularity of the epithelial layer (Figure 6) 2 months after the second laser procedure.

The point grid method showed higher microvessel density (18.83 ± 1.50) in the tissue 2 months after the second combined laser treatment in comparison with before (12.33 ± 1.74). The increase in microvessel density correlated with the activation of neoangiogenesis in the tissue after the procedure (Figure 7).

Light microscopy examination of specimens stained with van Gieson's stain confirmed the activation of neocollagenesis after second combined laser treatment with a more intense eosinophilic color and an increase in the number of collagen fibers (Figure 8).

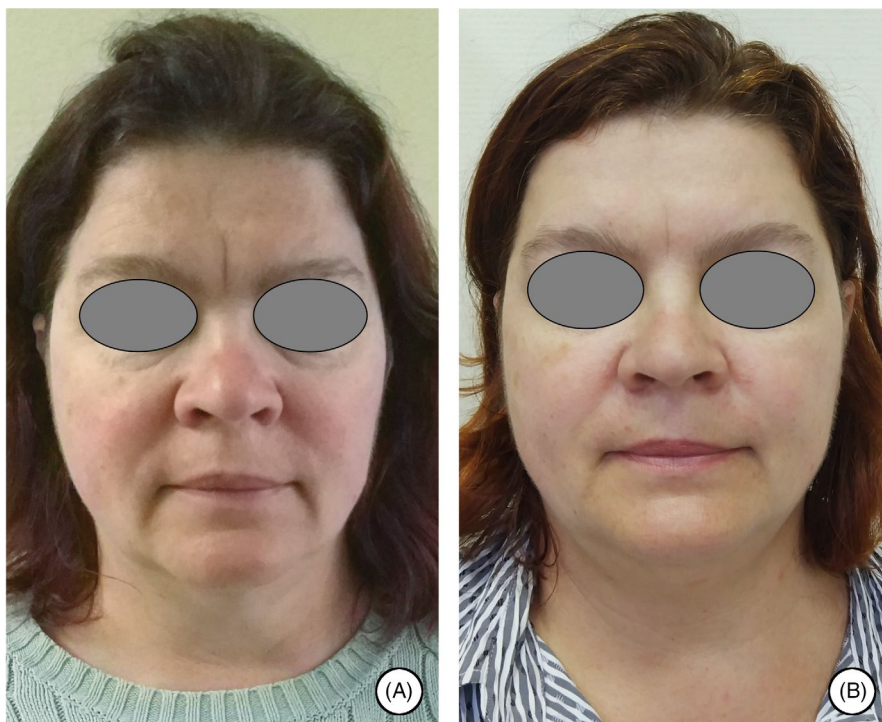

FIGURE 1 Patient number 2—before the procedure (A), 1 month after second procedure (B)

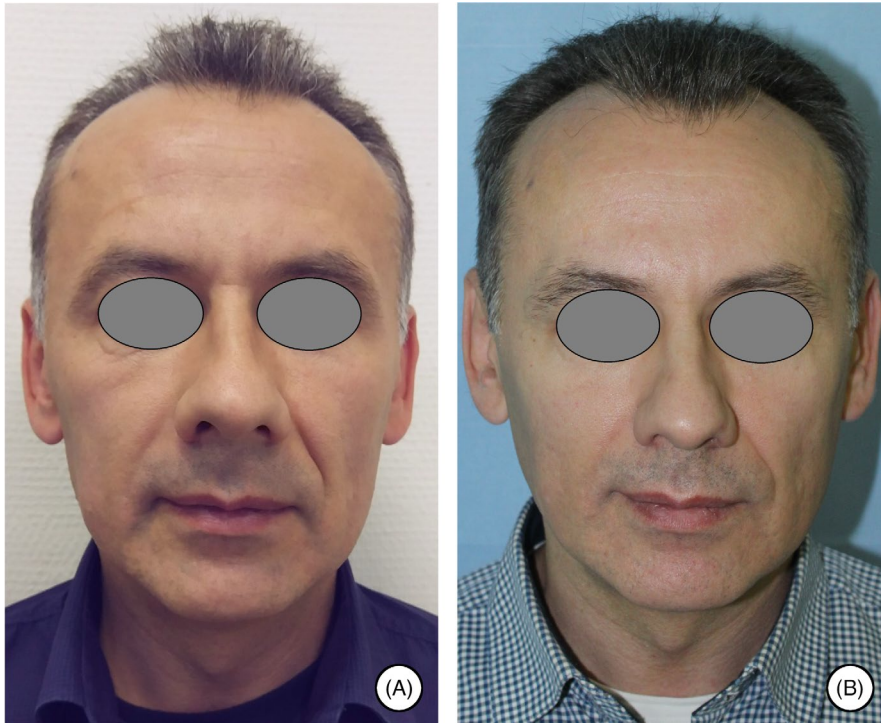

FIGURE 2 Patient number 2—before the procedure (A), 1 month after second procedure (B)

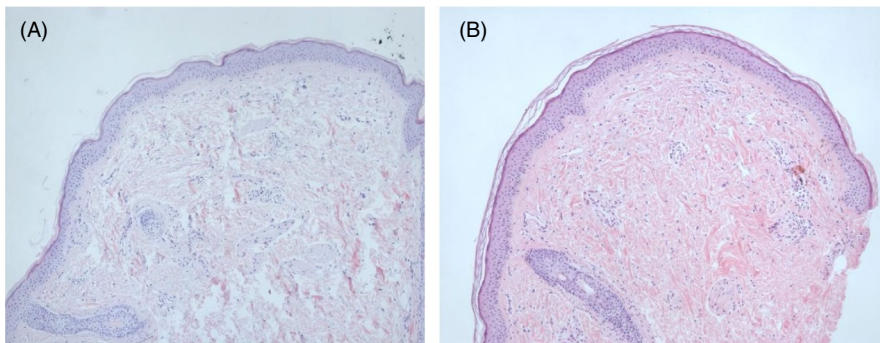


FIGURE 3 Female patient D. Light microscopy before (A) and after (B) laser treatment with more eosinophilic ground substance with increased connective tissue density (hematoxylin/eosin, 100× magnification)

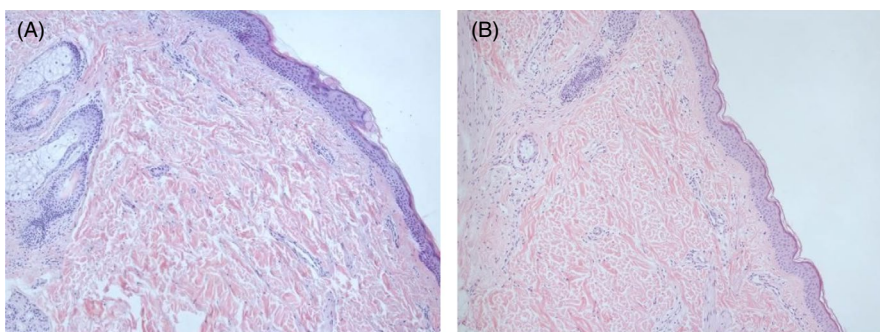


FIGURE 4 Female Patient L. Light microscopy before (A) and after (B) combined laser treatment with an increase in the number of fibroblasts and evidence of glomeruloid angiogenesis (hematoxylin/eosin, 100× magnification)

The increase in the number of collagen fibers was also shown through immunohistochemical analysis using specific collagen IV antigen antibodies (Figure 9).

The immunohistochemical analysis showed an increased expression of CD34 antigen (predominantly present in endothelial cell membranes), which is consistent with the formation of new blood vessels—angiogenesis (Figures 10 and 11). The same specimens were also processed with Morphology 5.2 (Table 2).

4 | DISCUSSION

The dual-wavelength protocol that was used in this study consists of four different steps; each of these steps has been used before either as a monotherapy or in combinations with others. Non-ablative rejuvenation with intraoral SMOOTH mode (Fotona, Slovenia) has previously been shown to improve nasolabial folds,^{12,21} reduce wrinkles in the general periorbital area,¹⁶ and

FIGURE 5 Female Patient A. Light microscopy before (A) and after (B) combined laser treatment showing an increased cellularity of the epithelial layer (hematoxylin/eosin, 100× magnification)

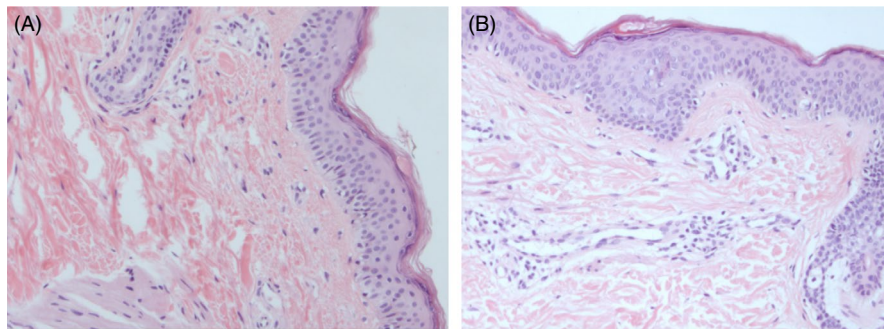


FIGURE 6 Female Patient D. Light microscopy before (A) and after (B) combined laser treatment showing increased epithelial thickness (hematoxylin/eosin, 100× magnification)

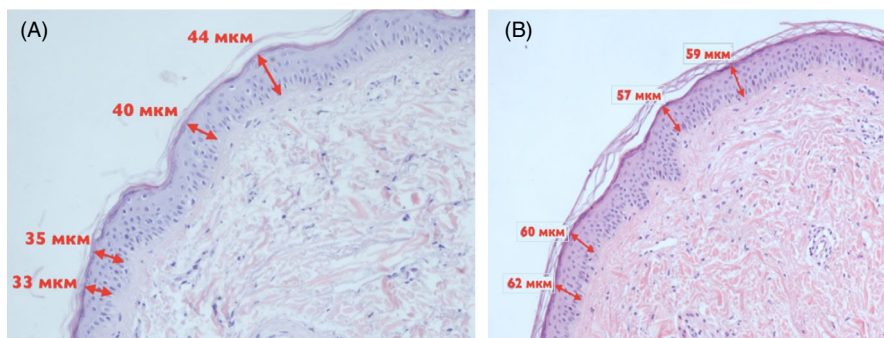


FIGURE 7 Female patient D. Light microscopy before (A) and after (B) combined laser treatment showing application of the point grid method (hematoxylin/eosin, 200× magnification)

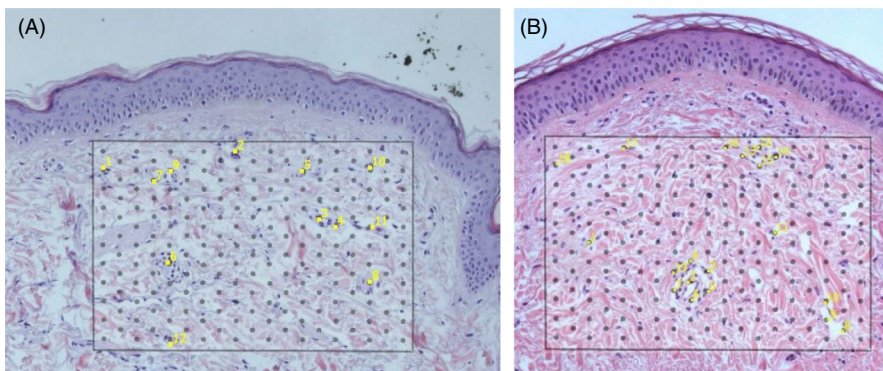
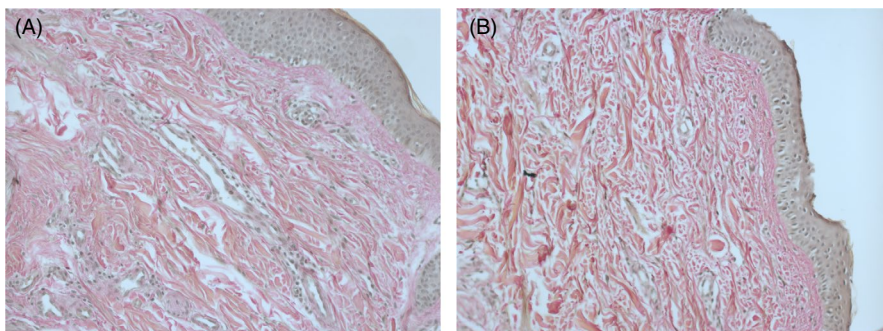


FIGURE 8 Male patient C. Light microscopy before (A) and after (B) laser treatment with an increase in the number and intensity of collagen fibers (Van Gieson's stain, 200× magnification)



cause a significant increase in dermal thickness¹³ and contraction of mucosa¹⁴ as a monotherapy.

Different authors have used sub-millisecond Nd:YAG in order to rejuvenate the skin in the last two decades. Trelles et al.²² and Koh et al.²³ demonstrated enhanced skin rejuvenation, Schmults et al.²⁴ reported on formation of new collagen after the treatment, and Groot and Smith²⁵ showed improvement in pore size, texture, and color after sub-millisecond Nd:YAG treatment. The third step of our protocol utilizes

super-long Nd:YAG pulses (PIANO, Fotona, Slovenia), which previously showed improvement in aging skin²⁶ and skin tightening.^{17,27-29}

The last step in our protocol, ablative laser resurfacing, has been used since its introduction in the 1980s in order to rejuvenate the skin.^{30,31} All of the previously mentioned methods have been used as a monotherapy or in combination with other modalities and have shown even better results in skin rejuvenation^{17,20,28,29} in comparison with monotherapy. Patients treated with our four-step combined

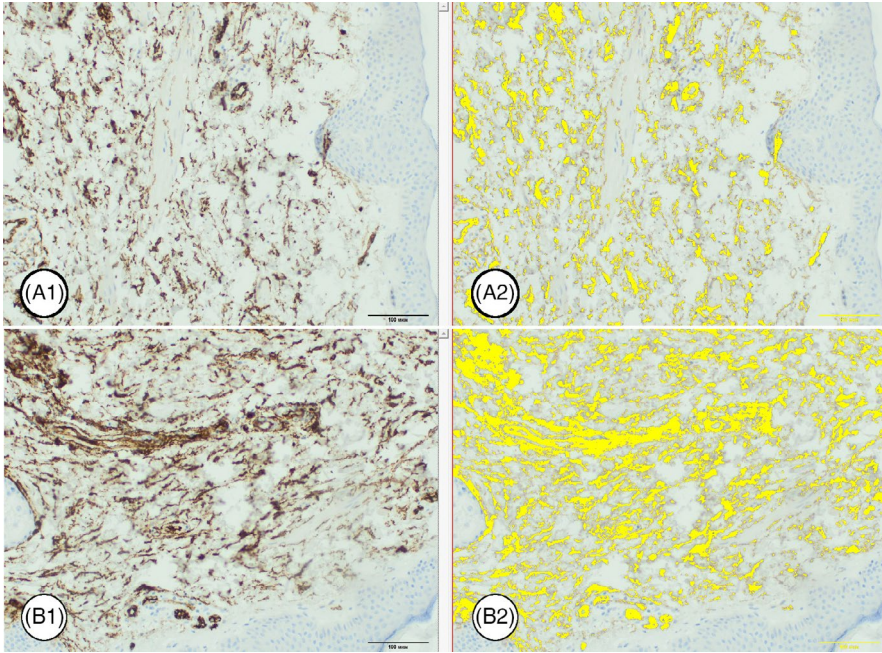


FIGURE 9 Male patient C. Immunohistochemical analysis of collagen expression before (A) and after (B) the course of combined laser exposure. A1, B1—without computer processing; A2, B2—after computer image processing (200× magnification)

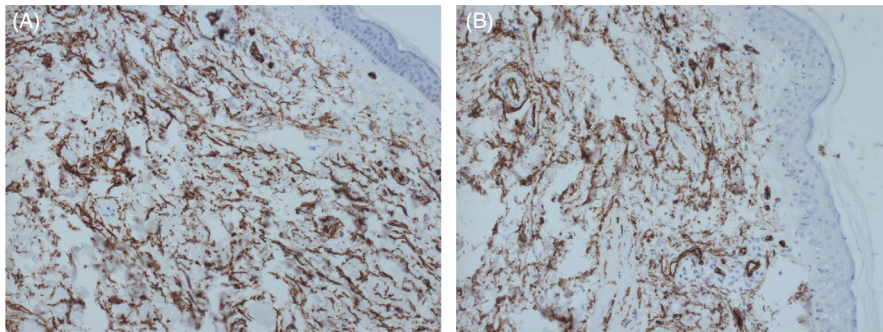


FIGURE 10 Female patient D. Immunohistochemical analysis of CD34 expression before (A) and after (B) combined laser treatment (200× magnification)

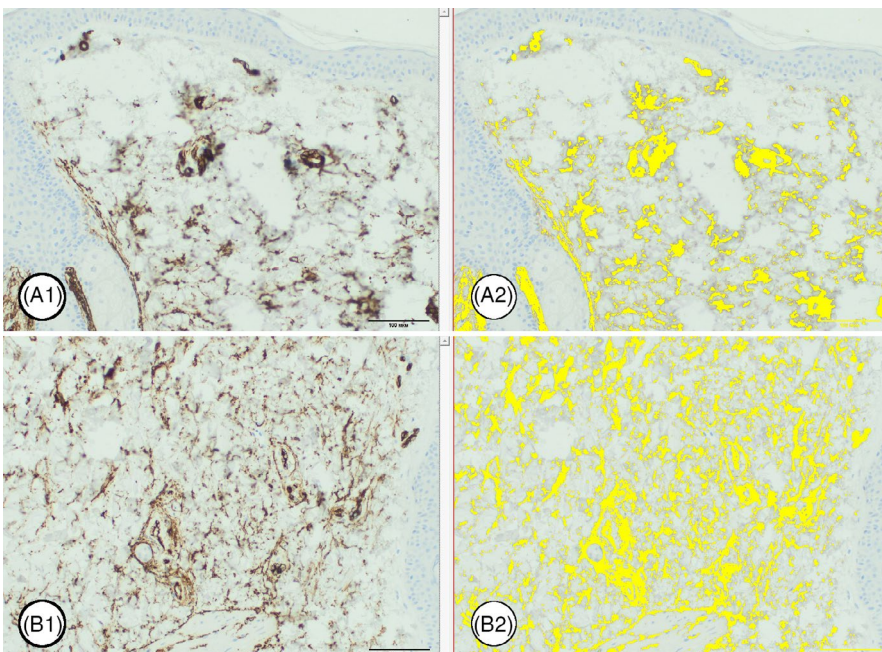


FIGURE 11 Male patient C. Immunohistochemical analysis of CD34 expression before (A) and after (B) the course of combined laser treatment. A1, B1—without computer processing; A2, B2—after computer image processing (200× magnification)

TABLE 2 Quantitative results of histological and immunohistochemical analysis

	Epidermal thickness [μm]	Microvessel density [%]	Collagen [% of the area]	CD34 [% of the area]
Before	38.03 \pm 0.59	12.33 \pm 1.74	3.4 (2.7, 5.2)	10.5 (8.8, 12.2)
After 8 weeks	59.4 \pm 0.53	18.83 \pm 1.50	4.7 (3.8, 7.6)	17.7 (15.9, 19.5)

Note: Epidermal thickness is presented in $\mu\text{m} \pm \text{SD}$. Microvessel density is presented in $\% \pm \text{SD}$. Collagen and CD34 are presented as median value of the percentage of the area (25%, 75%) ($N = 14$).

approach had a significant improvement according to the IOVIKL index for age-related changes in all areas of the face: reduction in the number and size of age spots, severity and depth of wrinkles, smaller and thinner pores, and tightening of the skin. The effectiveness of this dual-wavelength four-step approach in general facial skin improvement was also confirmed with histology, which has not been done before to the best of our knowledge. There were significant structural changes in the epidermis with increased thickness and cellularity, and in the dermis, where neoangiogenesis and an increased number of collagen fibers were confirmed. This compares favorably with previous studies.^{18,20} All of the histological changes reported in this study are a summation of previously reported histological changes after each of these steps used as monotherapy and contributes to a general improvement in the patients' appearance and perceived age.

One obvious limitation to this study is the small number of patients included, but the main point of this study is the histological data that nevertheless show apparent beneficial changes after laser procedure that also correlate with clinical presentation. The use of combined Er:YAG and Nd:YAG laser treatment is in our experience one of the most promising methods for improvement of age-related skin, as was previously proposed.²⁰

5 | CONCLUSION

With minimal recovery time, and no adverse sequelae to date, this dual-wavelength protocol has been found to provide excellent results for facial rejuvenation. These histological results should be considered preliminary until our results can be reproduced by others with long-term follow-up.

CONFLICT OF INTEREST

All authors state that they have no conflicts of interest regarding this article.

ETHICAL APPROVAL

All subjects read and signed an informed consent form, which was approved by the independent local ethical Committee of the Military Medical Academy in Saint Petersburg, Russia (No 189 from 23.05.2017).

DATA AVAILABILITY STATEMENT

The data that support the findings of this study are not available automatically. Upon reasonable request, the data can be accessed through the corresponding author, A.Z.

ORCID

Anže Zorman  <https://orcid.org/0000-0003-3777-6497>

REFERENCES

- Matts PJ, Fink B, Grammer K, Burquest M. Color homogeneity and visual perception of age, health, and attractiveness of female facial skin. *J Am Acad Dermatol*. 2007;57(6):977-984.
- Fisher GJ, Varani J, Voorhees JJ. Looking older: fibroblast collapse and therapeutic implications. *Arch Dermatol*. 2008;144(5):666-672.
- Zachary CB. Facial rejuvenation: 40th anniversary review. *Semin Cutan Med Surg*. 2016;35(6 Suppl):S122-S124. <https://doi.org/10.12788/j.sder.2016.039>
- Sadick NS, Cardona A. Laser treatment for facial acne scars: a review. *J Cosmet Laser Ther*. 2018;20(7-8):424-435.
- Fitzpatrick RE, Rostan EF, Marchell N. Collagen tightening induced by carbon dioxide laser versus erbium: YAG laser. *Lasers Surg Med*. 2000;27(5):395-403.
- Chwaleka J, Goldberg DJ. Ablative skin resurfacing. *Curr Probl Dermatol*. 2011;42:40-47.
- Riggs K, Keller M, Humphreys TR. Ablative laser resurfacing: high-energy pulsed carbon dioxide and erbium:yttrium-aluminum-garnet. *Clin Dermatol*. 2007;25(5):462-473.
- Lukac M, Perhavec T, Nemes K, Ahcan U. Ablation and thermal depths in VSP Er:YAG laser skin resurfacing. *J Laser Health Acad*. 2010;1(1):56-71.
- Majaron B, Srinivas SM, Huang HEL, Nelson JS. Deep coagulation of dermal collagen with repetitive Er:YAG laser irradiation. *Lasers Surg Med*. 2000;26(2):215-222.
- Lukač M, Sult TMD, Sult RRN. New options and treatment strategies with the VSP erbium YAG aesthetics lasers. *J Laser Health Acad*. 2007;1(1):1-9.
- Huth L, Huth S, Marquardt Y, et al. Deciphering the molecular effects of non-ablative Er:YAG laser treatment in an in vitro model of the non-keratinized mucous membrane. *Lasers Med Sci*. 2020. <https://doi.org/10.1007/s10103-020-03149-1>
- Ebrahim HM, Gharib K. Correction of nasolabial folds wrinkle using intraoral non-ablative Er:YAG laser. *J Cosmet Laser Ther*. 2018;20(6):364-368.
- Moftah N, Samy N, Allam RSHM, El Tagy SAH, Abdelghani R. Optical coherence tomographic (OCT) evaluation of intraoral non-ablative erbium: YAG laser (SMOOTH mode) in rejuvenation of nasolabial folds; a prospective randomized split face comparative pilot study. *Ski Res Technol*. 2020;26(3):405-412.
- Unver T, Usumez A, Aytugar E, Kiran T, Üşümez A. Histological effects of NightLase® in the soft palate of rats: a pilot study. *J Laser Health Acad*. 2015;2015:1-3.
- Lukac M, Gaspar A, Bajd F. Dual tissue regeneration: non-ablative resurfacing of soft tissues with FotonaSmooth® Mode Er:YAG laser. *J Laser Health Acad*. 2018;2018(1):1-15.
- Gaspar A, Gasti GA. Tightening of facial skin using intraoral 2940 nm Er:YAG SMOOTH mode. *J Laser Health Acad*. 2013;2013(2):1-5.
- Nghi P. Safety and effectiveness of the combined Nd:YAG and Er:YAG laser-assisted TightSculpting® body contouring procedure. *J Laser Health Acad*. 2019;2019(1):1-5.

18. Goldman MP, Marchell N, Fitzpatrick RE. Laser skin resurfacing of the face with a combined CO₂/Er:YAG laser. *Dermatol Surg.* 2000;26(2):102-104.
19. Tan MH, Dover JS, Hsu TS, Arndt KA, Stewart B. Clinical evaluation of enhanced nonablative skin rejuvenation using a combination of a 532 and a 1,064 nm laser. *Lasers Surg Med.* 2004;34(5):439-445.
20. Marini L. SPF-RR sequential photothermal fractional resurfacing and remodeling with the variable pulse Er:YAG laser and scanner-assisted Nd:YAG laser. *J Cosmet Laser Ther.* 2009;11(4):202-211.
21. Gaón NQ, Binfa F. The effect of intraoral 2,940nm non-ablative Erbium:YAG laser on the rejuvenation of the upper lip: a pilot study. *Surg Cosmet Dermatol.* 2017;9(1):56-8.
22. Trelles MA, Álvarez X, Martín-Vázquez MJ, et al. Assessment of the efficacy of nonablative long-pulsed 1064-nm Nd:YAG laser treatment of wrinkles compared at 2, 4, and 6 months. *Facial Plast Surg.* 2005;21(2):145-153.
23. Koh BK, Lee CK, Chae K. Photorejuvenation with submillisecond neodymium-doped yttrium aluminum garnet (1,064 nm) laser: a 24-week follow-up. *Dermatol Surg.* 2010;36(3):355-362.
24. Schmults CD, Phelps R, Goldberg DJ. Nonablative facial remodeling. *Arch Dermatol.* 2004;140:11.
25. Groot D, Smith K. Non-ablative skin therapy with CoolGlide van-tage sub-millisecond 1064 nm laser. *Treatments.* 2000;26:915-918.
26. Marini L, Alexiou A. Photo-thermal hormetic rejuvenation with 1064 nm Nd:YAG PIANO pulse laser. *J Laser Health Acad.* 2012;1:75-79.
27. Taylor MB. PIANO mode Nd:YAG laser skin tightening. *J Laser Health Acad.* 2013;2:CN03.
28. Strickland M. Treatment of Striae Gravidarum and skin tightening of the abdomen. *J Laser Health Acad.* 2017;2017:CN03.
29. Piroshenko M. Combined Er:YAG and Nd:YAG laser skin tightening treatment. *J Laser Health Acad.* 2020;1:CN13.
30. Chen KH, Tam KW, Chen I, et al. A systematic review of comparative studies of CO₂ and erbium:YAG lasers in resurfacing facial rhytides (wrinkles). *J Cosmet Laser Ther.* 2017;19(4):199-204.
31. Verma N, Yumeen S, Raggio BS. *Ablative Laser Resurfacing.* Treasure Island (FL): StatPearls Publishing; 2020.

How to cite this article: Shanina NA, Patrushev AV, Zorman A. Histological and immunohistochemical changes in facial skin treated with combined ablative and non-ablative laser therapy. *J Cosmet Dermatol.* 2021;20:3509–3516. <https://doi.org/10.1111/jocd.14023>