

Longitudinal Assessment of Retinal Structure in Achromatopsia Patients With Long-Term Follow-up

Nashila Hirji,^{1,2} Michalis Georgiou,^{1,2} Angelos Kalitzeos,^{1,2} James W. Bainbridge,^{1,2} Neruban Kumaran,^{1,2} Jonathan Aboshiha,^{1,2} Joseph Carroll,³ and Michel Michaelides^{1,2}

¹UCL Institute of Ophthalmology, University College London, London, United Kingdom

²Moorfields Eye Hospital, London, United Kingdom

³Department of Ophthalmology and Visual Sciences, Medical College of Wisconsin, Milwaukee, Wisconsin, United States

Correspondence: Michel Michaelides, UCL Institute of Ophthalmology, 11-43 Bath Street, London EC1V 9EL, UK; michel.michaelides@ucl.ac.uk.

NH and MG contributed equally to the work presented here and should therefore be regarded as equivalent authors.

Submitted: August 4, 2018

Accepted: October 26, 2018

Citation: Hirji N, Georgiou M, Kalitzeos A, et al. Longitudinal assessment of retinal structure in achromatopsia patients with long-term follow-up. *Invest Ophthalmol Vis Sci*. 2018;59:5735-5744. <https://doi.org/10.1167/iovs.18-25452>

PURPOSE. To longitudinally characterize structural retinal changes in achromatopsia (ACHM) over extended follow-up.

METHODS. Fifty molecularly confirmed ACHM subjects underwent serial spectral-domain optical coherence tomography (SD-OCT) and fundus autofluorescence (FAF) imaging. Foveal structure on SD-OCT was graded and compared for evidence of progression, and foveal total retinal thickness (FTRT) and outer nuclear layer (ONL) thickness were serially measured. FAF patterns were characterized and compared over time.

RESULTS. Mean SD-OCT follow-up was 61.6 months (age range at baseline, 6-52 years). Forty-five of the subjects had serial FAF (mean follow-up: 48.5 months). Only 6 (12%) of the subjects demonstrated qualitative change on serial foveal SD-OCT scans. Among the entire cohort, there was no statistically significant change over time in FTRT ($P = 0.2459$) or hyporeflective zone (HRZ) diameter ($P = 0.3737$). There was a small—but statistically significant—increase in ONL thickness ($P = 0.0084$). Three different FAF patterns were observed: centrally increased FAF (13/45), normal FAF (14/45), and well-demarcated reduced FAF (18/45), with the latter group displaying a small gradual increase in the area of reduced FAF of 0.055 mm^2 over 43.4 months ($P = 0.0011$).

CONCLUSIONS. This longitudinal study of retinal structure in ACHM represents the largest cohort and longest follow-up period to date. Our findings support the presiding notion that ACHM is essentially a stationary condition regarding retinal structure, and any change over time is likely to be small, slow, and variable across patients. This may potentially afford a wider window for therapeutic intervention.

Keywords: achromatopsia, gene therapy, optical coherence tomography, retinal dystrophy

Achromatopsia (ACHM) is an autosomal recessive cone dysfunction disorder affecting approximately one in 30,000 live births worldwide^{1,2} and is characterized by lack of function of all three classes of cone photoreceptor. Six causative genes are considered responsible for over 90% of cases: *CNGA3*, *CNGB3*, *GNAT2*, *PDE6H*, *PDE6C*, and *ATF6*.³ Affected individuals display marked photophobia and pendular nystagmus from birth or early infancy, associated with reduced visual acuity, deficient or absent color vision, and central scotomata.⁴ At present, there are no curative treatments available, with current management aiming to minimize the effects of symptoms and optimize residual visual function. However, promising results from studies investigating gene-replacement therapy to restore cone function in animal models with ACHM has led to the recent establishment of a number of human clinical trials, evaluating the safety and efficacy of gene supplementation in ACHM.⁴ Assessment of retinal structure and knowledge of the natural history of ACHM is key to identifying subjects potentially suitable for this intervention and also for subsequently monitoring the effects of treatment.

ACHM has classically been described as a stationary condition. Sundaram et al.⁵ evaluated 40 individuals with ACHM aged between 6 and 52 years, and found no significant

correlation of deterioration in visual acuity, contrast sensitivity, or reading acuity with advancing age. Optical coherence tomography (OCT) has demonstrated variable outer retinal structure at the central macula, including at the level of the photoreceptor inner segment ellipsoid layer (ISe) and retinal pigment epithelium (RPE).⁵⁻⁸ In their study, Sundaram et al.⁵ found that the variable spectral-domain OCT (SD-OCT) appearances did not correlate with age or genotype and that total foveal retinal thickness (FTRT), foveal outer nuclear layer (ONL) thickness, and ISe intensity were not age-dependent. Given these results supporting a stationary natural history, the authors purported that there may potentially be a wide window of opportunity for therapeutic intervention. In contrast, other work has alluded to progressive cone photoreceptor loss in ACHM.⁶⁻⁸ However, these studies have often been limited by their cross-sectional nature and small sample size. To address this, a larger prospective structural and functional ACHM study ($n = 38$) has been conducted by Aboshiha et al.⁹ with the aim of performing statistical analysis on the data acquired to draw more definitive conclusions about the frequency and rate of any disease progression. The authors reported essentially stable SD-OCT findings over time. There is a relative paucity of studies investigating fundus autofluorescence (FAF) in ACHM and, in



particular, over time.¹⁰ Therefore, Aboshiha et al.⁹ additionally investigated this parameter. The authors concluded that the retinal parameters they assessed either remained stable or changed minimally in a small proportion of patients. However, it is not inconceivable that monitoring patients over a longer period may identify a greater proportion of individuals who develop progressive changes. Since an understanding of the natural history of ACHM is key to the planning and selection of appropriate candidates for such therapeutic interventions as gene therapy, we have performed serial assessment of SD-OCT and FAF in a longitudinal study of subjects with molecularly proven ACHM, with a larger cohort size and longer follow-up duration than previously conducted.⁹ Our aim was to further examine structural progression in ACHM, thereby making inferences about the optimal timing for treatment.

METHODS

Subjects

Fifty subjects with ACHM, characterized phenotypically and genotypically, were prospectively seen between 32 and 86 months after baseline assessment. All subjects were participants of the ACHM natural history study conducted at Moorfields Eye Hospital. The study protocol adhered to the tenets of the Declaration of Helsinki and was approved by the Moorfields Eye Hospital Ethics Committee. Informed consent was obtained from all subjects prior to their entry to the study.

Clinical Assessments

Best-corrected visual acuity (BCVA) and contrast sensitivity were measured at baseline and follow-up assessments using an Early Treatment Diabetic Retinopathy Study chart and Pelli-Robson chart at 1 meter, respectively.

Spectral-Domain OCT (SD-OCT)

SD-OCT imaging was performed on both eyes following pupillary dilation with tropicamide 1% and phenylephrine 2.5% eye drops. Line and volume scans were acquired with the Spectralis device (Heidelberg Engineering, Inc., Heidelberg, Germany) using the same protocol as that employed by Aboshiha et al.⁹ At follow-up visits, the device was switched to follow-up mode so the same scanning location was used both at baseline and follow-up. This enabled comparable measurements to be made between the two visits for a given subject but may not have been entirely possible in individuals with significant nystagmus. The transverse scale of each image was calculated using the axial length of the corresponding eye. This was measured using the Zeiss IOL Master (Carl Zeiss Meditec, Inc., Jena, Germany).

Qualitative assessment of foveal structure was performed by grading SD-OCT images into one of five categories: (1) continuous ISe, (2) ISe disruption, (3) ISe absence, (4) presence of an HRZ, or (5) outer retinal atrophy. For each subject, both right and left eyes were graded at baseline and follow-up. Consensus grading was established by three independent observers (NH, MG, and MM). Measurements of FTFT (internal limiting membrane to RPE distance), foveal ONL thickness and, where applicable, HRZ diameter at baseline and follow-up were made, as in the previous longitudinal study.⁹ All measurements were made by a single examiner (NH) using the digital calipers built into the software (Heidelberg Eye Explorer; Heidelberg Engineering), and a 1-pixel:1- μ m display with maximum magnification. Where appropriate, measurements were corrected for axial length by normalizing relative to the average axial length of a healthy

adult human eye. The mean of three measurements was calculated and recorded for each parameter in each subject and at each visit. The presence/absence of foveal hypoplasia was also noted, defined as the persistence of one or more inner retinal layers (outer plexiform layer, inner nuclear layer, inner plexiform layer or ganglion cell layer) through the fovea.⁵

Fundus Autofluorescence (FAF)

FAF imaging was performed bilaterally at baseline and follow-up, as per the protocol utilized by Aboshiha et al.⁹ Briefly, assessments were performed using the AF mode on the Spectralis device (Heidelberg Engineering) following pupillary dilation as previously described and after SD-OCT image acquisition. In subjects displaying a well-demarcated region of reduced autofluorescence at both visits, the area was measured by tracing around the circumference of the hypo-autofluorescent region with a mouse-driven cursor and recording the area within, as calculated by the in-built image analysis software (Heidelberg Eye Explorer; Heidelberg Engineering). All FAF measurements were made by the same examiner (NH). For each FAF image, the mean of three area measurements was calculated and used for further analysis.

Data Analysis Methods

The D'Agostino-Pearson Omnibus Test was used to verify the normality of data before using any parametric tests. The distribution of FTFT, ONL thickness, and HRZ diameter values did not demonstrate normality; therefore, nonparametric tests were used throughout for statistical analysis. Statistical tests were performed using GraphPad Prism, version 5 (GraphPad Software, Inc., La Jolla, CA, USA). Qualitative changes in foveal structure on SD-OCT were evaluated in both eyes for each subject. Sundaram et al.⁵ found no significant differences in measured parameters between the two eyes of subjects in their cross-sectional study of ACHM, and therefore selected the left eye for further quantitative analysis; this was replicated by Aboshiha et al.⁹ in their subsequent longitudinal study. In keeping with these previous studies, we also utilized the left eye for more detailed analysis of quantitative parameters.

RESULTS

Fifty patients with greater than 24 months follow-up who had interpretable transfoveal SD-OCT scans at baseline and follow-up were included in the study. Twenty-six patients were male (52%) and 24 were female (48%). The mean age of the cohort at baseline was 23.9 years (range, 7–52 years). Forty-five subjects (90%) had baseline and follow-up FAF. Of these 50 subjects, 32 had previously been described by Sundaram et al.⁵ Table 1 summarizes the age at baseline, follow-up interval, and structural parameters in our cohort over time. Supplementary Table S1 cross-references our subjects to those included in the study by Sundaram et al.⁵ and demonstrates the detailed genotype of each patient. Supplementary Table S2 shows the absolute FTFT and ONL measurements for the left eye of each subject, at baseline and follow-up.

SD-OCT

Comparable foveal SD-OCT scans were obtained at baseline and follow-up in all 50 subjects. Six of these subjects (12%) showed qualitative progression bilaterally on SD-OCT between baseline and follow-up. Patients 2, 24, 37, and 38 progressed from category 1 (continuous ISe layer) at baseline to category 2

TABLE 1. Summary of Patient Characteristics and Clinical Findings

Patient No.	Age at Baseline, y	Genotype	SD-OCT f/u Interval, mo	SD-OCT Category	Change in FTRT Between Assessments, μm	Change in ONL Thickness Between Assessments, μm	Change in HRZ Diameter Between Assessments, μm	FAF f/u Interval, mo	Central FAF Pattern at Both Assessments	Change in Area of Reduced FAF, mm^2	Foveal Hypoplasia?	
1	10	CNGA3	39	3	3	+3	+2	n/a	no f/u	n/a	n/a	Yes
2	10	CNGA3	64	1	2	+7	+5	n/a	37	Normal	n/a	Yes
3	11	CNGA3	58	1	1	+9	+8	n/a	54	Reduced	0	Yes
4	11	CNGA3	55	2	2	-6	-7	n/a	55	Increased	n/a	No
5	17	CNGA3	63	4	4	-7	-7	+237	51	Reduced	+0.01	Yes
6	19	CNGA3	68	2	2	0	-2	n/a	14	Reduced	0	No
7	22	CNGA3	66	2	2	-3	-4	n/a	14	Normal	n/a	Yes
8	21	CNGA3	67	4	4	-2	-4	+150	51	Normal	n/a	Yes
9	24	CNGA3	74	4	4	-2	-1	+25	74	Normal	n/a	Yes
10	25	CNGA3	60	5	5	-5	n/a	n/a	60	Reduced	+0.2	Yes
11	30	CNGA3	53	3	3	+4	-3	n/a	53	Reduced	+0.02	Yes
12	29	CNGA3	67	4	4	-4	-7	-140	36	Reduced	+0.03	Yes
13	31	CNGA3	73	4	4	+4	+4	+43	62	Increased	n/a	Yes
14	34	CNGA3	73	2	2	+5	+3	n/a	no f/u	n/a	n/a	Yes
15	35	CNGA3	69	2	4	-10	-8	n/a	45	Normal	n/a	No
16	8	CNGA3	55	2	2	-1	-2	n/a	45	Increased	n/a	No
17	32	CNGA3	76	2	2	-6	-6	n/a	19	Reduced	+0.01	Yes
18	46	CNGA3	57	4	4	+2	+2	+4	58	Reduced	+0.01	Yes
19	30	CNGA3	86	4	4	-7	-5	+21	76	Normal	n/a	No
20	8	CNGA3	62	1	1	-10	-10	n/a	62	Increased	n/a	No
21	10	CNGB3	81	4	4	+5	+6	+59	38	Reduced	+0.03	Yes
22	11	CNGB3	54	2	2	-1	-3	n/a	54	Increased	n/a	Yes
23	12	CNGB3	66	3	3	-3	-2	n/a	66	Increased	n/a	Yes
24	12	CNGB3	70	2	2	+1	-2	n/a	70	Normal	n/a	Yes
25	13	CNGB3	68	1	1	+2	-1	n/a	54	Increased	n/a	No
26	18	CNGB3	71	4	4	+3	+2	-91	36	Reduced	+0.01	Yes
27	18	CNGB3	66	4	4	+1	-3	-22	59	Increased	n/a	Yes
28	22	CNGB3	74	5	5	-9	n/a	n/a	23	Reduced	+0.06	Yes
29	26	CNGB3	48	1	1	-4	-3	n/a	48	Increased	n/a	No
30	33	CNGB3	66	2	4	+9	-8	n/a	19	Reduced	+0.01	Yes
31	47	CNGB3	63	4	4	-2	-4	-4	31	Reduced	+0.02	No
32	15	CNGB3	32	2	2	+5	+4	n/a	32	Normal	n/a	Yes
33	23	CNGB3	62	3	3	-3	-4	n/a	no f/u	n/a	n/a	Yes
34	26	CNGB3	42	1	2	+3	+5	n/a	42	Reduced	+0.06	Yes
35	26	CNGB3	43	2	2	0	+4	n/a	43	Reduced	0	Yes
36	29	CNGB3	38	2	2	-4	-1	n/a	26	Normal	n/a	No
37	25	CNGB3	52	1	2	+2	-2	n/a	52	Increased	n/a	Yes
38	7	CNGB3	59	1	2	-4	-5	n/a	no f/u	n/a	n/a	No
39	35	CNGB3	73	2	2	-4	-4	n/a	73	Increased	n/a	Yes
40	7	CNGB3	57	2	2	+4	+1	n/a	5	Normal	n/a	Yes
41	29	CNGB3	39	2	2	0	-1	n/a	39	Normal	n/a	Yes
42	18	CNGB3	42	1	1	+1	-3	n/a	42	Normal	n/a	Yes
43	12	CNGB3	48	3	3	-3	-1	n/a	14	Normal	n/a	Yes
44	43	GNAT2	79	1	1	-4	-3	n/a	79	Reduced	+0.05	No
45	52	GNAT2	79	1	1	-3	-3	n/a	129	Normal	n/a	No
46	43	PDE6C	79	5	5	-3	n/a	n/a	104	Reduced	+0.47	Yes
47	19	ATF6	75	3	3	-1	-5	n/a	46	Increased	n/a	Yes
48	23	ATF6	70	3	3	0	-6	n/a	70	Increased	n/a	Yes
49	44	ATF6	54	3	3	-9	-5	n/a	21	Reduced	0	Yes
50	44	ATF6	44	4	4	+3	-4	+54	no f/u	n/a	n/a	Yes

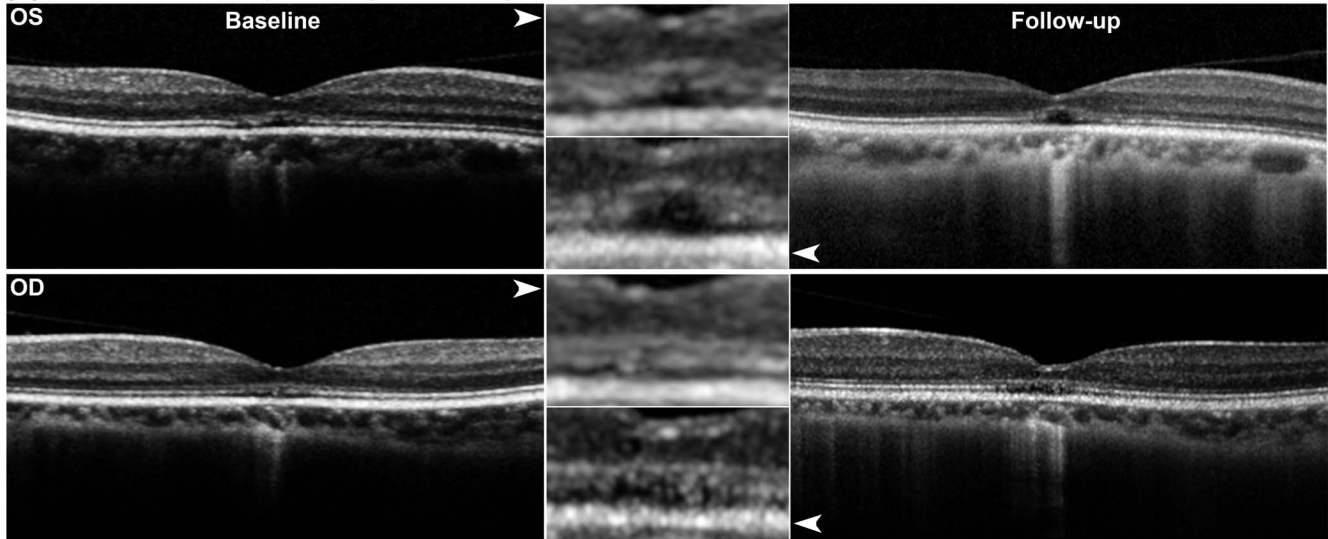
n/a, not applicable; +, increase in metric over time; -, decrease in metric over time.

(ISe disruption) over 64-, 42-, 52-, and 59-month follow-up periods, respectively. Patients 15 and 30 progressed from category 2 (ISe disruption) at baseline to category 4 (HRZ) at follow-up, over 69- and 66-month periods, respectively (Fig. 1). In the remaining 44 subjects, SD-OCT grade was identical bilaterally at baseline and remained unchanged in both eyes at

follow-up. Thus, there was no evidence of qualitative progression in these subjects (Fig. 2).

Thirty-seven subjects (74%) showed foveal hypoplasia bilaterally at baseline, and no change in the presence or absence of this feature in either eye was found between baseline and follow-up in any patient.

(A) CNGA3-ACHM (Subject 15, Age at BS: 35 yo, FU: 69 months)



(B) CNGB3-ACHM (Subject 30, Age at BS: 33 yo, FU: 66 months)

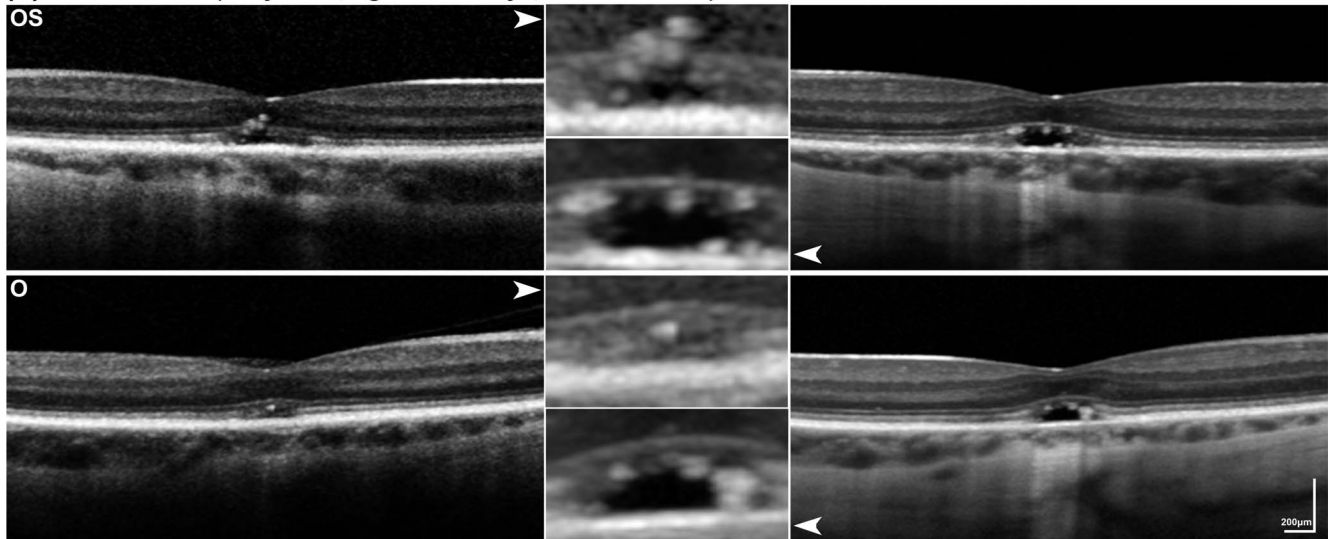


FIGURE 1. Longitudinal SD-OCT imaging of ACHM cases with structural changes. The *left column* shows baseline transfoveal SD-OCT imaging and the *right column* shows follow-up images over the same location. The *middle column* depicts $\times 3$ magnification of the foveal ellipsoid zone from the corresponding SD-OCT (*white arrows*). Both subjects (A) and (B), with 69 and 66 months of follow-up, respectively, progressed from category 2 (disrupted ISe layer) to category 4 (presence of HRZ) bilaterally. BS, baseline; FU, follow-up; yo, years old. Scale bar: 200 μ m.

FTRT, ONL Thickness and HRZ Diameter

FTRT was measured in all 50 subjects at baseline and follow-up. Mean change in absolute FTRT (i.e., FTRT at follow-up minus FTRT at baseline) was $-0.94 \mu\text{m}$ (range, -10 to $+9 \mu\text{m}$). The change in absolute FTRT between visits in the cohort was not statistically significant (Wilcoxon signed-rank test; $P = 0.2459$). Mean percentage change in FTRT between baseline and follow-up was -0.98% (range, -8.55% to $+6.12\%$). The percentage change in FTRT within the cohort was also not statistically significant (Wilcoxon signed-rank test; $P = 0.0732$). There was no significant correlation between age and change in FTRT (Spearman's correlation coefficient = -0.17 ; $P = 0.2336$). There was, however, a positive correlation between starting FTRT and change in FTRT, where subjects with a lower FTRT at baseline showed greater reduction over time (Spearman's correlation coefficient = 0.41 ; $P = 0.0029$). This suggests that the less the initial FTRT, the greater the degree of central retinal thinning over time.

Three (8%) of the 37 subjects with foveal hypoplasia (patients 10, 28, and 46) did not have a structurally distinct ONL that could be accurately measured and were excluded from ONL thickness analysis. The mean change in absolute ONL thickness in the remaining 47 subjects (i.e., ONL thickness at follow-up minus ONL thickness at baseline) was $+1.98 \mu\text{m}$ (range, -10 to $+8 \mu\text{m}$). This change was statistically significant between assessments (Wilcoxon signed-rank test; $P = 0.0084$). Mean percentage change in ONL thickness between baseline and follow-up was $+2.19\%$ (range, -14.29% to $+8.08\%$). The percentage change in ONL thickness within the cohort was also statistically significant (Wilcoxon signed-rank test; $P = 0.0031$).

Five of the 12 patients who had an HRZ at both baseline and follow-up had a starting absolute FTRT greater than the average of the entire cohort. There was no statistically significant change in the diameter of the HRZ over a mean follow-up interval of 67 months among these 12 patients (Wilcoxon signed-rank test; $P = 0.3737$). Mean change in absolute FTRT

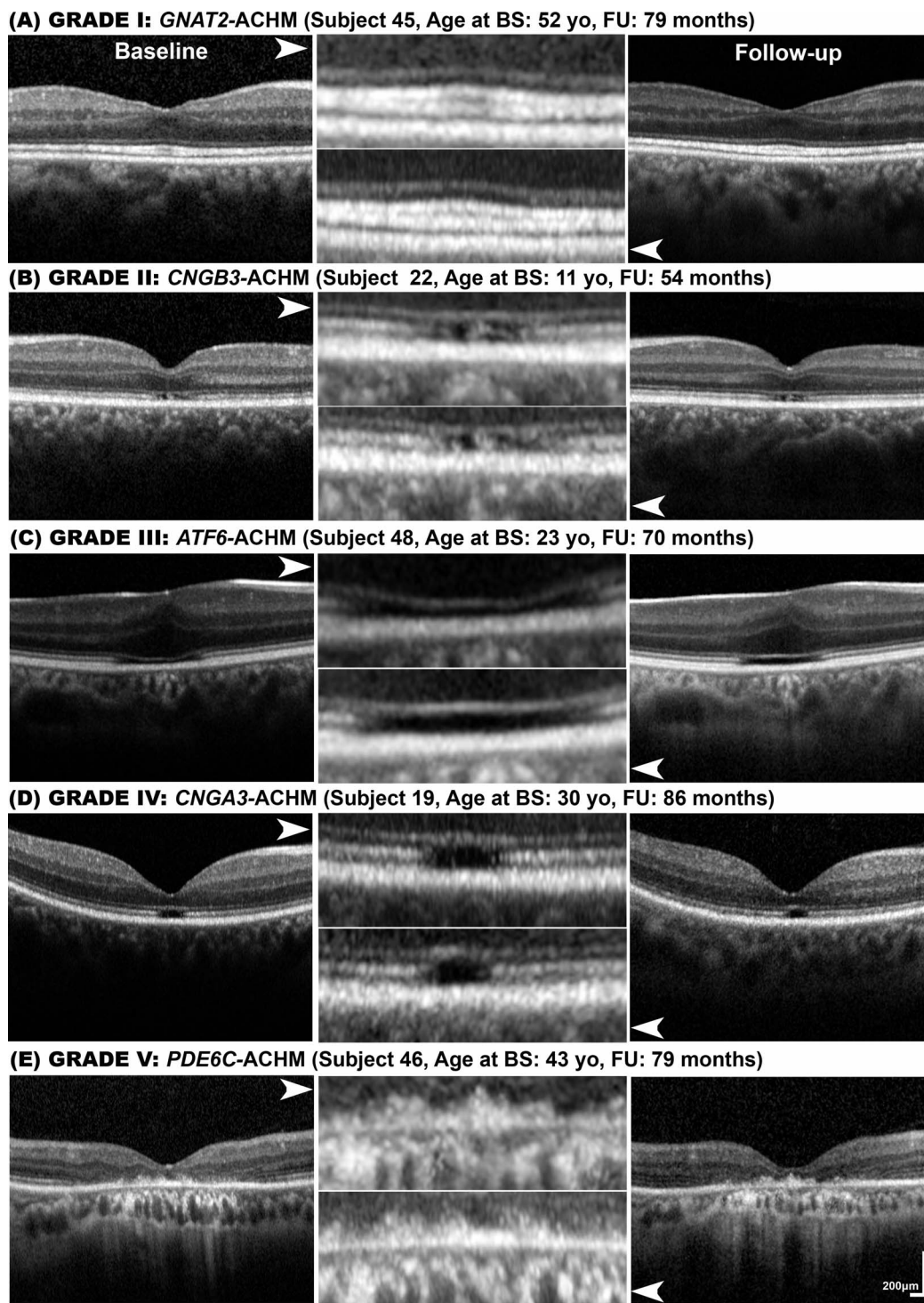


FIGURE 2. Longitudinal SD-OCT imaging of stationary ACHM cases. The *left column* shows baseline transfoveal SD-OCT imaging and the *right column* shows follow-up images over the same location. The *middle column* depicts $\times 3$ magnification of the foveal ellipsoid zone from the corresponding SD-OCT (*white arrows*). Five subjects (A–E) with five different ACHM genotypes (*GNAT2*, *CNGA3*, *CNGB3*, *ATF6*, *PDE6C*) and five different categories of SD-OCT, respectively, showed no structural change over a follow-up period of 54 to 86 months, with an age range at baseline of 11 to 52 years old. *Scale bar*: 200 μm .

within this smaller cohort was $-0.50 \mu\text{m}$ (range, -7 to $+5 \mu\text{m}$), that is, smaller than the mean reduction in absolute FTRT noted in the entire cohort over time.

Figure 3 demonstrates the range of changes in structural parameters, observed over time within our cohort.

FAF

Forty-five subjects (90%) had baseline and follow-up FAF (Table 1). As in the study by Aboshiha et al.,⁹ three distinct FAF patterns were observed in our subjects at baseline: (1) a normal FAF pattern, seen in 14 patients (31%); (2) an abnormal

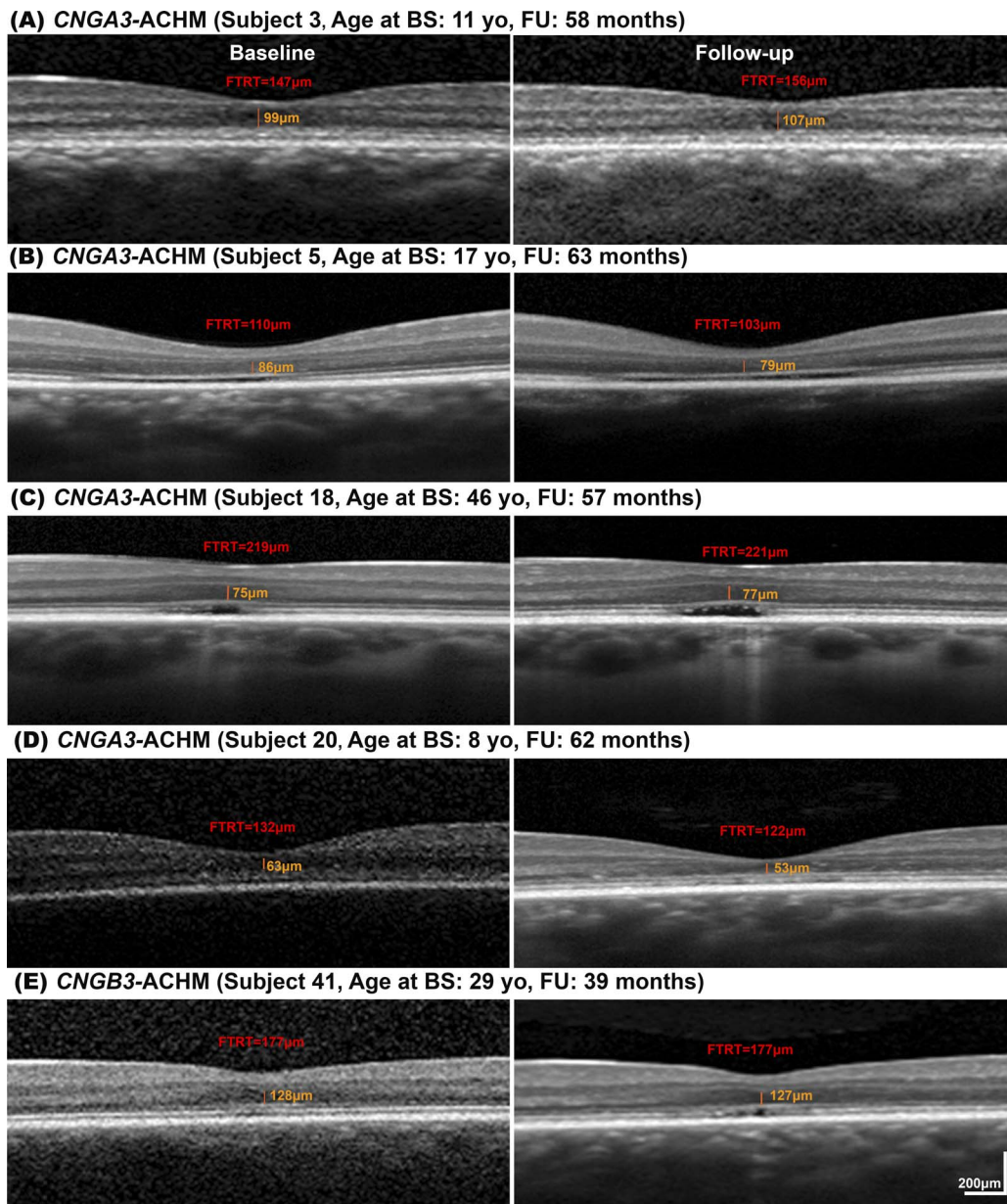


FIGURE 3. Longitudinal SD-OCT imaging and retinal structure measurements. The *left column* shows baseline transfoveal SD-OCT imaging and the *right column* shows follow-up images over the same location for five subjects (A–E). ONL thickness is marked with orange lines. Subject (B) had the greatest HRZ width increase in the cohort. Subject (C) had a minimal change in HRZ width. In (A, B, D), a change was identified in the ONL thickness (7–10 µm); in contrast with (C, E) in whom there was no significant difference. Scale bar: 200 µm.

central increase in FAF, seen in 13 patients (29%); and (3) a well-demarcated central reduction in FAF, seen in 18 patients (40%). No subject demonstrated a change in FAF pattern over time. The area of reduced FAF was measured at baseline and follow-up in those individuals demonstrating this phenotype, since this feature was amenable to quantification. Ten of these subjects had a starting absolute FTRT smaller than the average of the entire cohort. Mean increase in the area of reduced FAF was 0.055 mm², over a mean follow-up interval of 43 months. The change in FAF between baseline and follow-up was statistically significant (Wilcoxon signed-rank test; $P = 0.0011$). Mean change in absolute FTRT within the 18 subjects demonstrating reduced FAF was $-0.78 \mu\text{m}$ (range, -9 to $+9$

μm), smaller than the mean reduction in absolute FTRT noted in the entire cohort over time.

Genotype-Phenotype Correlation

CNGA3 and *CNGB3* subgroups were analyzed separately, and no statistically significant difference was noted between the two cohorts regarding change in FTRT (Mann-Whitney U test; $P = 0.5187$) or change in ONL thickness (Mann-Whitney U test; $P = 0.5986$). Comparisons could not be made with *GNAT2*, *PDE6C*, and *ATF6* subgroups, given the small numbers of individuals within these groups. Similarly, statistical comparisons could not be made between *CNGA3* and *CNGB3*

TABLE 2. Summary of BCVA and Contrast Sensitivity at Baseline and Follow-up

Patient No.	Age at Baseline, y	Genotype	SD-OCT f/u Interval, mo	BCVA, logMAR b f/u		Contrast Sensitivity, logCS b f/u	
1	10	CNGA3	39	0.86	0.72	1.40	1.35
2	10	CNGA3	64	0.80	0.78	1.25	1.35
3	11	CNGA3	58	1.08	0.96	0.90	1.30
4	11	CNGA3	55	0.94	0.90	1.05	n/a
5	17	CNGA3	63	0.88	0.76	1.20	1.20
6	19	CNGA3	68	0.80	1.02	0.65	0.25
7	22	CNGA3	66	1.16	1.16	1.05	0.90
8	21	CNGA3	67	0.92	0.84	1.35	1.30
9	24	CNGA3	74	0.86	0.90	1.35	1.30
10	25	CNGA3	60	0.84	0.80	1.35	n/a
11	30	CNGA3	53	0.76	0.72	1.55	1.30
12	29	CNGA3	67	0.74	0.76	1.20	1.35
13	31	CNGA3	73	0.90	0.90	1.45	1.15
14	34	CNGA3	73	0.90	0.82	1.20	1.40
15	35	CNGA3	69	0.96	0.96	1.00	1.05
16	8	CNGA3	55	1.00	0.90	1.05	n/a
17	32	CNGA3	76	0.84	0.74	1.25	1.35
18	46	CNGA3	57	0.80	0.70	1.30	1.45
19	30	CNGA3	86	1.00	0.80	n/a	1.20
20	8	CNGA3	62	1.00	1.02	n/a	1.05
21	10	CNGB3	81	0.82	0.82	1.05	0.85
22	11	CNGB3	54	0.90	0.82	1.35	1.35
23	12	CNGB3	66	0.90	0.92	1.00	1.05
24	12	CNGB3	70	0.76	0.76	1.30	1.45
25	13	CNGB3	68	0.90	0.84	1.30	1.35
26	18	CNGB3	71	0.74	0.70	1.25	1.20
27	18	CNGB3	66	0.86	0.76	1.35	1.35
28	22	CNGB3	74	0.76	0.86	1.25	1.05
29	26	CNGB3	48	0.90	0.82	1.45	1.40
30	33	CNGB3	66	0.96	0.84	0.90	1.00
31	47	CNGB3	63	0.96	0.98	1.10	0.95
32	15	CNGB3	32	0.84	0.60	1.55	1.40
33	23	CNGB3	62	0.96	1.06	1.00	0.95
34	26	CNGB3	42	1.00	1.04	0.70	0.30
35	26	CNGB3	43	0.84	0.92	1.10	1.00
36	29	CNGB3	38	0.84	0.76	1.35	1.20
37	25	CNGB3	52	0.92	0.94	1.20	1.40
38	7	CNGB3	59	1.04	1.02	0.90	1.10
39	35	CNGB3	73	1.10	1.08	1.10	0.85
40	7	CNGB3	57	1.04	0.92	0.80	1.15
41	29	CNGB3	39	0.92	0.88	1.35	1.35
42	18	CNGB3	42	0.68	0.82	1.40	1.00
43	12	CNGB3	48	0.88	0.88	1.30	1.00
44	43	GNAT2	79	1.10	1.04	0.70	0.85
45	52	GNAT2	79	1.00	1.20	0.50	0.75
46	43	PDE6C	79	1.32	0.94	1.05	1.10
47	19	ATF6	75	0.96	0.90	1.45	1.35
48	23	ATF6	70	0.86	0.74	1.20	1.35
49	44	ATF6	54	1.04	0.94	1.10	1.15
50	44	ATF6	44	0.70	0.74	1.30	1.65

subgroups regarding change in HRZ diameter and area of reduced FAF, again due to small sample sizes.

BCVA and Contrast Sensitivity

Table 2 displays the BCVA and contrast sensitivities of the subjects at baseline and follow-up. For consistency, only data from the left eye were analyzed. The mean BCVA at baseline was 0.91 logMAR (range, 0.68-1.32 logMAR), and this was significantly different from the mean BCVA at follow-up, which measured 0.87 logMAR (range, 0.60-1.20 logMAR; paired *t*-test;

P = 0.014). However, the mean of the logarithm of contrast sensitivity (logCS) at baseline of 1.16 logCS (range, 0.5-1.55 logCS) was not significantly different from that measured at follow-up of 1.15 logCS (range, 0.25-1.65 logCS; paired *t*-test; *P* = 0.681), where higher logCS values indicate better contrast sensitivity.

DISCUSSION

The natural history of ACHM has been the center of some debate, with several studies suggesting it is a progressive

condition. Thiadens et al.⁶ investigated 40 subjects with achromatopsia cross-sectionally with SD-OCT and proposed that cone cell decay began in early childhood, with retinal thinning correlating with age. Thomas et al.⁸ found in their study of 13 individuals with ACHM that the presence of a HRZ and ONL thinning were also age-dependent. However, a significant limitation of these studies is their cross-sectional nature. To identify cone loss over time, there is a need for longitudinal assessment.

Thomas et al. followed 8 subjects with ACHM over a mean period of 16 months.⁷ They found that the 5 younger subjects (<10 years) showed progressive morphological ISe changes between visits 1 and 2. However, the three older subjects (aged over 40 years) did not show any changes. They concluded that dynamic retinal changes in younger patients provided evidence that ACHM is a progressive disorder. However, due to the small sample size, the group was unable to statistically evaluate the significance of the reported changes. Aboshiha et al.⁹ sought to address this with their longitudinal investigation of 38 subjects with ACHM. They reported retinal structure to be largely stable over time regarding SD-OCT. Only 2 subjects showed qualitative evidence of progression, as evidenced by advancing OCT grade bilaterally. There was no statistically significant change in the quantitative SD-OCT parameters assessed, for instance, FTRT and ONL thickness. Furthermore, there was no statistically significant change in HRZ diameter in the 9 subjects with an HRZ at baseline and follow-up visits. With regard to FAF, Aboshiha and colleagues did not observe a change in FAF pattern between baseline and follow-up visits, or between eyes, in the 30 subjects for whom this parameter could be assessed.⁹ In those subjects with a reduced FAF pattern at baseline and follow-up ($n = 15$), a small but statistically significant reduction in the median area of reduced FAF was noted between visits. However, the mean follow-up period of their cohort was 19.5 months (range, 13–24 months), and it is possible that retinal change may occur over longer periods.

More recently, and consistent with our data, Triantafylla et al. reported no changes in FTRT and only minor changes in ONL thickness in their study of 10 subjects with ACHM, with a mean follow-up period of 65.9 months (Triantafylla et al., *IOVS* 2018;59:ARVO E-Abstract 5205). However, they reported a 2.5-fold increase in HRZ width, which we did not observe in our data. Interestingly, 6 of their 10 patients were children under the age of 10, while 7 of our 50 subjects were 10 years old or younger. Thus, we cannot rule out the idea that there is some progression very early in the disease that stabilizes later in the first decade. Consistent with this, the 2 subjects in our study with the greatest ONL thickness change were 10 and 11 years of age. This highlights the need to begin natural history studies in even younger populations as well as the availability of handheld OCT as useful in these efforts.¹¹

To our knowledge, our work represents the largest longitudinal study of retinal structure in ACHM. The large patient sample size allows for statistical analysis of the significance of any change over time. Our cohort showed no statistically significant change in FTRT over time nor in HRZ diameter in those subjects where this feature was present at the baseline assessment. This is consistent with the results of the longitudinal study undertaken by Aboshiha et al.⁹ and supports the notion that ACHM is a predominantly stable condition with regard to retinal structure. The increase in ONL thickness over time was statistically significant. However, this change was small (less than 2 μm on average). Thus, while the change in this parameter may be statistically significant, its clinical relevance is questionable. Indeed, retinal thickness has been shown to change with age. Nieves-Moreno et al.¹² reported a reduction in retinal thickness for each year of

increased age in healthy subjects, concluding that the thickness of most retinal layers varies with age. Our measurements of change in retinal thickness are within those expected for normal aging, suggesting that they do not represent true disease progression.

With regard to qualitative analysis, 6 subjects (12%) showed evidence of progression to higher (i.e., worse) SD-OCT grades. Similar changes were noted in both eyes, suggesting that this likely represented real disease progression. Two of these subjects were of the *CNGA3* genotype and 4 were *CNGB3*, suggesting that qualitative progression may be an uncommon feature of both these most frequent genotypes. The mean age of these subjects was 20.3 years (range, 7–35 years), and mean SD-OCT follow-up interval was 63.6 months (range, 52–70 months). These values are not dissimilar to those of the entire cohort, which had a mean age at baseline of 23.9 years and mean SD-OCT follow-up interval of 61.6 months. Therefore, it would seem unlikely that age at baseline and duration of follow-up are factors that influence any qualitative progression observed on SD-OCT. Interestingly however, these subjects displaying qualitative category progression did not display a reduction in FTRT or ONL thickness of greater than 10 μm , and indeed some subjects who demonstrated more thinning quantitatively did not show change in SD-OCT category over time. Thus, there appears to be a discordance between quantitative change in terms of retinal thickness and qualitative change in terms of foveal morphology on SD-OCT. In part, this may be attributable to a limitation of this study: There are often difficulties in scanning exactly the same location through the fovea at each visit for a given patient. The Spectralis SD-OCT device (Heidelberg Engineering) sets the baseline scan as the reference scan, and the in-built software attempts to direct the SD-OCT fixation target to a position that corresponds to the same retinal location during subsequent image acquisition. However, this is not always possible in ACHM patients with severe nystagmus and poor fixation. A follow-up scan may therefore be centered at a slightly different position, and this may contribute subtle variations in the quantitative and qualitative results recorded compared to baseline. This suggests that there may be a role for collecting multiple representative scans at baseline.

In showing qualitative change, we reported a higher proportion of subjects (12%) than did the work of Aboshiha et al.,⁹ who described this in 5% of their cohort. However, their study had a mean follow-up period of only 19.5 months and fewer subjects (38 compared to our 50). By contrast, the subjects in our study showing qualitative change all had follow-up periods of greater than 40 months. Therefore, it may be that foveal appearances do gradually deteriorate in a small proportion of patients, given sufficient time. Further work assessing retinal function in patients who have been followed-up over extended periods may shed light on any potential functional consequences of such changes. Aboshiha et al.⁹ found that patients demonstrating qualitative change did not show significant associated changes in functional parameters. SD-OCT changes, however, may predate change in visual function, and extended follow-up could allow these delayed functional changes to manifest.

With regard to FAF, we identified three distinct patterns in our cohort, as per previous work.^{9,10} The three patterns were present in relatively equal proportions among our cohort and did not change in any subject between baseline and follow-up. In those patients with reduced FAF at baseline, there was a statistically significant increase in the area of reduced signal over time; however, this rate of increase was very small (0.015 mm^2 per year). This is very similar to the rate of 0.02 mm^2 per year identified by Aboshiha et al.⁹ A range of retinal mechanisms can result in variations in the observed FAF

pattern. Of note, our results show no particular relationship between the observed pattern of FAF and qualitative SD-OCT appearances for subjects with SD-OCT categories 1 through 4. Thus, all three FAF patterns were observed across these categories. However, all 3 subjects with SD-OCT category 5 scans at baseline and follow-up demonstrated a pattern of reduced FAF. This is because of the atrophic retinal changes seen in this SD-OCT phenotype, which in turn are associated with a reduced density of the fluorophore lipofuscin in the affected regions. Finer quantitative methods of FAF analysis are available,^{13,14} and it may be that further work using these techniques may identify more subtle changes in FAF patterns. However, the clinical significance of FAF in ACHM remains poorly established, and we would predict that any progression in this parameter is likely to be slow and small in magnitude. Interestingly, recent work by Matet et al.¹⁵ has advocated the role of near-infrared autofluorescence (NIR-AF) in the investigation of ACHM. While the Spectralis device performs short-wavelength autofluorescence (SW-AF) imaging, NIR-AF is a less frequently used imaging modality. In subjects with ACHM, the authors correlated NIR-AF with SW-AF features and structural alterations on SD-OCT. Patients with a central hypo-autofluorescence on NIR-AF were older and displayed more advanced structural abnormalities at the fovea than did those with normal NIR-AF, while SW-AF was not correlated to other multimodal findings. This suggests a potential role for NIR-AF as an imaging biomarker in ACHM.¹⁵

In summary, our findings from a larger cohort and longer follow-up of individuals with ACHM provide further support to the presiding notion that this is essentially a stable condition regarding retinal structure and that any change over time is likely to be small, slow, and occur in only a limited proportion of patients. Of note, Zein et al.¹⁶ recently studied the effect of ciliary neurotrophic factor (CNTF) in 5 subjects with *CNGB3*-ACHM, all of whom had an HRZ on SD-OCT at baseline. CNTF is thought to have a neurotrophic effect on human cone photoreceptors. The group demonstrated a sustained filling or collapse of the HRZ in all treated eyes. They proposed that CNTF was responsible for the changes in retinal foveal morphology since they were not seen in untreated eyes. Our findings lend support to the idea that marked changes in retinal morphology observed following the therapeutic interventions tested to date can be attributed to the treatment rather than to disease progression since we have demonstrated that structural changes in the natural history are negligible and very slow.

Further work using more detailed imaging techniques, such as adaptive optics scanning light ophthalmoscopy (AOSLO), may better demonstrate the earliest indicators of any structural progression in ACHM.¹⁷ AOSLO allows visualization of individual rod and cone cells in vivo^{18,19} and has confirmed the presence of cone photoreceptors in all patients with ACHM, albeit reduced in number compared to the unaffected retina, with a wide range of cone densities, and often a disconnect with SD-OCT appearance.²⁰ With regard to assessing progression of ACHM with AOSLO, Langlo et al.²¹ demonstrated that foveal cone structure showed little or no change in their cohort of patients with *CNGB3*-ACHM over a follow-up period of 6 to 26 months. However, extending follow-up (as in our study of SD-OCT and FAF imaging) may provide new insights into very gradual retinal changes occurring at the microscopic level.

Interestingly, while Aboshiha et al.⁹ demonstrated stability of functional parameters in conjunction with structural stability, the results from our cohort show a small but clinically significant improvement in mean BCVA over time, though no significant change in contrast sensitivity. The change in BCVA may partially be explained by the fact that 7 subjects within our cohort were age 10 years or younger at presentation. In

these individuals, the transition from childhood toward adulthood over prolonged follow-up may have enabled more accurate assessment of visual acuity at follow-up, thus leading to an apparent improvement in this parameter. Furthermore, nystagmus in children with ACHM may lessen with age.²² The improved fixation associated with this could potentially lead to a mild improvement in visual acuity. Nevertheless, while the increase in BCVA within our cohort over time was statistically significant, it was small in magnitude and thus likely to be of minimal clinical significance.

For now, our work suggests that disease progression for the majority of our cohort is negligible. Thus, there may potentially be a wide window for therapeutic intervention, and gene replacement therapy may be a viable option for affected adults as well as children. However, the functional benefit derived by older individuals may be limited by abnormal organization of the visual cortex. Baseler et al.²³ described reorganization of the visual cortex from birth onward in ACHM in response to abnormal visual experience. The authors attributed this to visual system plasticity, postulating that this may result from a range of mechanisms, including reorganization of neural connectivity and changes in the efficacy of established connections. Plasticity of the brain is maximal in the first few years of life, reducing with advancing years.²⁴ Thus, while it is conceivable that older subjects may show some improvement following treatment, it is likely that earlier intervention in children, when anomalous visual processing pathways are less developed, may yield optimal results. Our work supporting the largely nonprogressive nature of ACHM is also valuable when evaluating the effects of potential interventions in a clinical trial setting. Knowledge of the condition's relative stability enables structural and functional changes occurring post-treatment to be attributed to the intervention rather than to the natural disease process, allowing for better recognition of the specific effects of the treatment itself. Indeed, trial regulatory bodies will often seek evidence confirming the disease's stationary nature prior to approving a study, and our results may aid in the establishment of future interventional studies for ACHM.

Acknowledgments

The authors thank Alexander Smith, PhD, for his assistance with statistical analysis of the data, and all the patients and their families for their participation in this study.

Supported by grants from the National Institute for Health Research, the Biomedical Research Centre at Moorfields Eye Hospital NHS Foundation Trust and UCL Institute of Ophthalmology, MeiraGTx, Medical Research Council, Fight for Sight, Moorfields Eye Hospital Special Trustees, Moorfields Eye Charity, The Wellcome Trust (099173/Z/12/Z), Retinitis Pigmentosa Fighting Blindness, and the Foundation Fighting Blindness (USA). Research in this publication was supported in part by the National Eye Institute of the National Institutes of Health (NIH) under award numbers R01EY017607 and P30EY001931. The content is solely the responsibility of the authors and does not necessarily represent the official views of the NIH.

Disclosure: **N. Hirji**, None; **M. Georgiou**, None; **A. Kalitzeos**, None; **J.W. Bainbridge**, MeiraGTx (C); **N. Kumaran**, None; **J. Aboshiha**, None; **J. Carroll**, MeiraGTx (C); **M. Michaelides**, MeiraGTx (C)

References

1. Aboshiha J, Dubis AM, Carroll J, Hardcastle AJ, Michaelides M. The cone dysfunction syndromes. *Br J Ophthalmol*. 2016; 100:115–121.

2. Michaelides M, Hunt DM, Moore AT. The cone dysfunction syndromes. *Br J Ophthalmol*. 2004;88:291-297.
3. Johnson S, Michaelides M, Aligianis IA, et al. Achromatopsia caused by novel mutations in both *CNGA3* and *CNGB3*. *J Med Genet*. 2004;41:e20.
4. Hirji N, Aboshiha J, Georgiou M, Bainbridge J, Michaelides M. Achromatopsia: clinical features, molecular genetics, animal models and therapeutic options. *Ophthalmic Genet*. 2018;39:149-157.
5. Sundaram V, Wilde C, Aboshiha J. Retinal structure and function in achromatopsia: implications for gene therapy. *Ophthalmology*. 2014;121:234-245.
6. Thiadens AA, Somervuo V, van den Born LI, et al. Progressive loss of cones in achromatopsia: an imaging study using spectral-domain optical coherence tomography. *Invest Ophthalmol Vis Sci*. 2010;51:5952-5957.
7. Thomas MG, McLean RJ, Kohl S, Sheth V, Gottlob I. Early signs of longitudinal progressive cone photoreceptor degeneration in achromatopsia. *Br J Ophthalmol*. 2012;96:1232-1236.
8. Thomas MG, Kumar A, Kohl S, Proudlock FA, Gottlob I. High-resolution in vivo imaging in achromatopsia. *Ophthalmology*. 2011;118:882-887.
9. Aboshiha J, Dubis AM, Cowing J, et al. A prospective longitudinal study of retinal structure and function in achromatopsia. *Invest Ophthalmol Vis Sci*. 2014;55:5733-5743.
10. Fahim AT, Khan NW, Zahid S, et al. Diagnostic fundus autofluorescence patterns in achromatopsia. *Am J Ophthalmol*. 2013;156:1211-1219.e2.
11. Yang P, Michaels KV, Courtney RJ, et al. Retinal morphology of patients with achromatopsia during early childhood: implications for gene therapy. *JAMA Ophthalmol*. 2014;132:823-831.
12. Nieves-Moreno M, Martínez-de-la-Casa JM, Morales-Fernández L, Sánchez-Jean R, Sáenz-Francés F, García-Feijó J. Impacts of age and sex on retinal layer thicknesses measured by spectral domain optical coherence tomography with Spectralis. *PLoS One*. 2018;13:e0194169.
13. Schachar IH, Zahid S, Comer GM, et al. Quantification of fundus autofluorescence to detect disease severity in nonexudative age-related macular degeneration. *JAMA Ophthalmol*. 2013;131:1009-1015.
14. Armenti ST, Greenberg JP, Smith RT. Quantitative fundus autofluorescence for the evaluation of retinal diseases. *J Vis Exp*. 2016;109:e53577.
15. Matet A, Kohl S, Baumann B, et al. Multimodal imaging including semiquantitative short-wavelength and near-infrared autofluorescence in achromatopsia. *Sci Rep*. 2018;8:5665.
16. Zein WM, Jeffrey BG, Wiley HE, et al. *CNGB3*-achromatopsia clinical trial with CNTF: diminished rod pathway responses with no evidence of improvement in cone function. *Invest Ophthalmol Vis Sci*. 2014;55:6301-6308.
17. Georgiou M, Kalitzeos A, Patterson EJ, Dubra A, Carroll J, Michaelides M. Adaptive optics imaging of inherited retinal diseases. *Br J Ophthalmol*. 2018;102:1028-1035.
18. Roorda A, Williams DR. The arrangement of the three cone classes in the living human eye. *Nature*. 1999;397:520-522.
19. Dubra A, Sulai Y, Norris JL, et al. Noninvasive imaging of the human rod photoreceptor mosaic using a confocal adaptive optics scanning ophthalmoscope. *Biomed Opt Express*. 2011;2:1864-1876.
20. Scoles D, Flatter JA, Cooper RF, et al. Assessing photoreceptor structure associated with ellipsoid zone disruptions visualized with optical coherence tomography. *Retina*. 2016;36:91-103.
21. Langlo CS, Erker LR, Parker M, et al. Repeatability and longitudinal assessment of foveal cone structure in *CNGB3*-associated achromatopsia. *Retina*. 2017;37:1956-1966.
22. Zobor D, Zobor G, Kohl S. Achromatopsia: on the doorstep of a possible gene therapy. *Ophthalmic Res*. 2015;54:103-108.
23. Baseler HA, Brewer AA, Sharpe LT, Morland AB, Jägle H, Wandell BA. Reorganization of human cortical maps caused by inherited photoreceptor abnormalities. *Nat Neurosci*. 2002;5:364-370.
24. Mundkur N. Neuroplasticity in children. *Indian J Pediatr*. 2005;72:855-857.