



Since January 2020 Elsevier has created a COVID-19 resource centre with free information in English and Mandarin on the novel coronavirus COVID-19. The COVID-19 resource centre is hosted on Elsevier Connect, the company's public news and information website.

Elsevier hereby grants permission to make all its COVID-19-related research that is available on the COVID-19 resource centre - including this research content - immediately available in PubMed Central and other publicly funded repositories, such as the WHO COVID database with rights for unrestricted research re-use and analyses in any form or by any means with acknowledgement of the original source. These permissions are granted for free by Elsevier for as long as the COVID-19 resource centre remains active.

Complex Regional Pain Syndrome as a sequela of COVID-19 pneumonia



We report the case of a 44-year-old male patient who presented to the emergency department with shortness of breath. He initially complained with a 2-day history of coughing, fever, and progressive dyspnea. He was obese, with

no known previous medical illness. On arrival, his vital signs showed an axillary temperature of 38.7 °C, pulse rate of 114 beats per minute, indicating sinus rhythm; respiratory rate of 22 per minute; non-invasive blood pressure of 140/86 mm Hg;

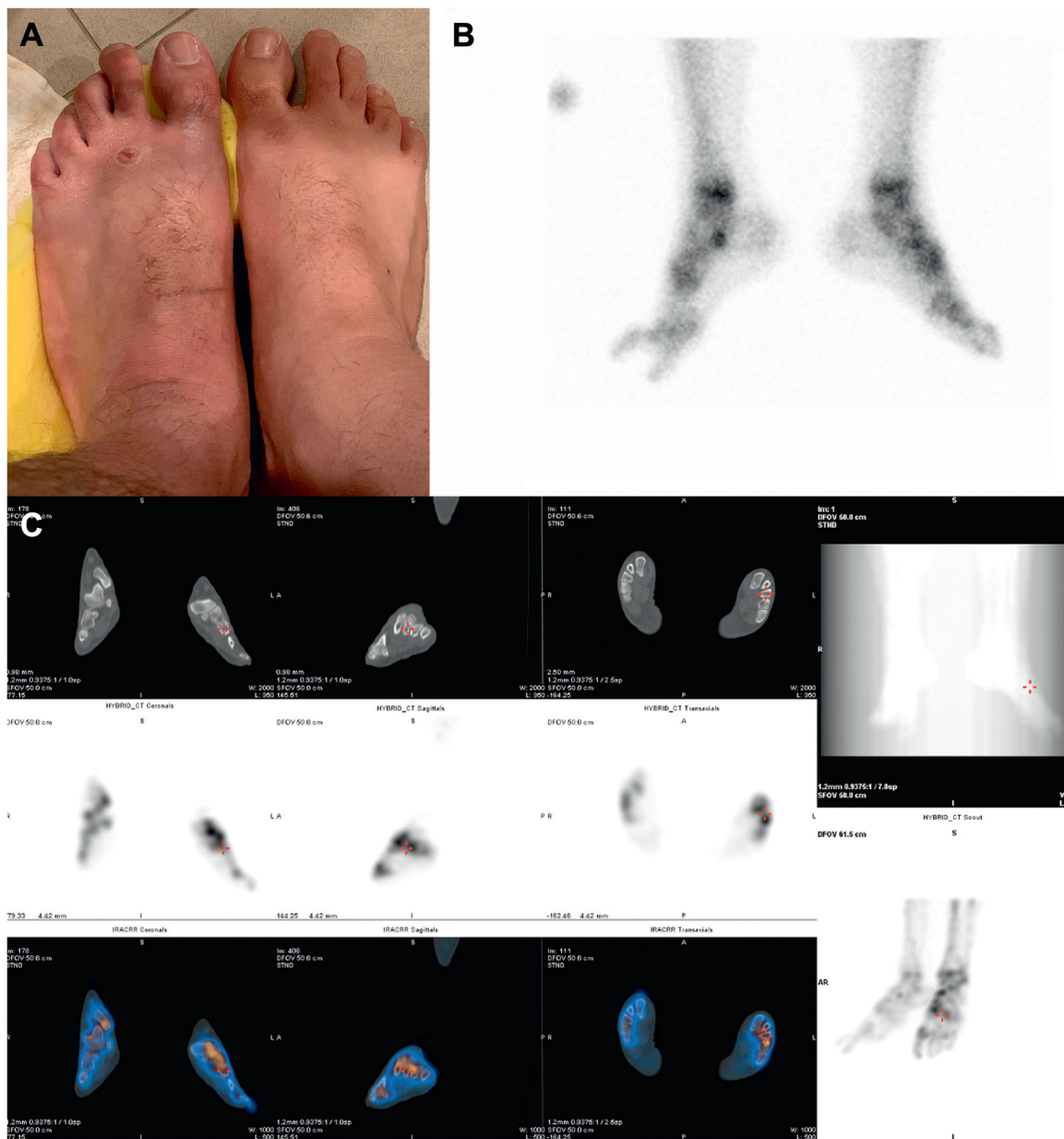


Fig. 1 – A: Complex regional syndrome. The left foot was presenting edema and burning pain, associated with hyperalgesia, allodynia, and abnormal temperature sensation; **B and C: Delayed Images and SPECT CT images** demonstrated increased periarticular tracer uptake in the left foot at the tibiotalar, fibulotalar, subtalar, talonavicular, naviculocuneiform, and the first and second tarsometatarsal joints.

and oxygen saturation of 88% (on room air). Laboratory analysis revealed lymphocytopenia (800 cells/mm³) with an elevated C-reactive protein level of 58.0 mg/L. The real-time polymerase chain reaction (RT-PCR) assay of the nasopharyngeal swab specimen obtained from the patient was positive for coronavirus disease (COVID-19). Thus, a diagnosis COVID-19 pneumonia was made.

Shortly after admission, the patient's condition deteriorated to severe respiratory distress, requiring intubation and mechanical ventilation; therefore, he was transferred to the intensive care unit. He received 4 days of lopinavir-ritonavir and hydroxychloroquine therapy, with mild clinical improvement during his 1-month stay in the intensive care unit. After attaining clinical improvement, he was weaned off mechanical ventilation. Two months after hospital discharge, the patient started complaining of left foot congestion, warmth, and throbbing pain, with change in color to red and purple (Fig. 1A). On the following day, he presented to the emergency department because of ongoing severe pain. On examination, the left foot had warmth, erythema, and edema, with hyperpigmented skin on the second toe. The capillary refill time and peripheral pulses were normal. The blood chemistries and left foot radiography result were unremarkable. He was misdiagnosed as having cellulitis and treated with intravenous ceftriaxone (2 g/day) and oral clindamycin (1800 mg/day) for 1 week.

He later sought a second opinion from the physical medicine and rehabilitation outpatient clinic. All laboratory test results (erythrocyte sedimentation rate and levels of C-reactive protein, parathormone, bone alkaline phosphatase, and serum and urinary calcium/phosphate and vitamin D) were normal. Electromyography and nerve conduction studies of the foot, and the erythrocyte sedimentation rate were normal. Magnetic resonance imaging of the foot revealed second and third metatarsal bone marrow edema. A three-phase bone scan showing the blood flow and whole-body blood pool was performed. Three hours later, whole body and spot views of the feet were obtained. Single-photon emission computed tomography (SPECT/CT) images of the feet were also acquired revealing mildly increased pooling in the left forefoot region. Delayed and SPECT/CT images demonstrated increased periarticular tracer uptake in multiple joints of the left foot. A multidisciplinary medical team diagnosed the patient with complex regional pain syndrome (CRPS) type 1 (with no associated nerve damage) on the basis of bone scan images and by the Budapest criteria [1]. Treatment with gabapentin (100–200 mg/day) was initiated for neuropathic pain. The patient underwent a focused rehabilitation program to help improve ankle range of motion as well as to strengthen ankle dorsiflexors, everters and plantarflexors. His CRPS symptoms and ankle range of motion significantly improved after 3 months of rehabilitation. As the symptoms had gradually resolved, the gabapentin dose was slowly reduced.

This case study describes a patient who abruptly developed CRPS type 1 after contracting COVID-19 infection. The diagnosis of CRPS is a composite of characteristic clinical signs [1]. CRPS is defined as continuous pain disproportional to the triggering trauma with the associated clinical signs (temperature asymmetry, skin color or trophic changes,

edema and sweating, muscular weakness, tremor, or dystonia) based on the Budapest criteria [1]. Since the beginning of the COVID-19 pandemic, several neurological manifestations have been reported in these patients, ranging from mild symptoms [2].

The involvement of the autonomic nervous system in SARS-CoV-2 infection has been rarely reported in the literature. Physicians involved in the treatment of SARS-CoV-2 are encountering patients with a wide spectrum of central and peripheral nervous system manifestation [3]. An explanation for the peripheral nervous system involvement could be “molecular mimicry,” that is, the cross-reactivity of natural immunoglobulins, formed in response to a bacterial or viral antigen with specific proteins on the myelin, axon, or neuromuscular junction [4]. Dysautonomia symptoms have also been observed in patients with COVID-19, including diarrhea and sweat dysfunction. This is similar to the dysautonomia reported with other viral infections. The presence of dysautonomia in patients with COVID-19 should be further studied to appropriately diagnose and manage post-COVID-19 patients.

To our knowledge, only one case of CRPS post COVID-19 is documented in the literature [5]. Although the respiratory manifestations of SARS-CoV-2 infection are well recognized, its neurological manifestations have not been adequately studied to date. Critically ill patients are at a greater risk of developing neurological symptoms during the course of the disease. Physicians should be aware of these symptoms and evaluate patients early so as to avoid the dissemination of the disease and improve patients' prognosis.

Disclosure of interest

The authors declare that they have no competing interest.

Acknowledgement

None.

REFERENCES

- [1] Dutton K, Littlejohn G. Terminology, criteria, and definitions in complex regional pain syndrome: challenges and solutions. *J Pain Res* 2015;8:871–7.
- [2] Eshak N, Abdelnabi M, Ball S. Dysautonomia: an overlooked neurological manifestation in a critically ill COVID-19 patient. *Am J Med Sci* 2020;360:427–9.
- [3] Guerrero JI, Barragán LA, Martínez JD, et al. Central and peripheral nervous system involvement by COVID-19: a systematic review of the pathophysiology, clinical manifestations, neuropathology, neuroimaging, electrophysiology, and cerebrospinal fluid findings. *BMC Infect Dis* 2021;21:515.
- [4] Fotuhi M, Mian A, Meysami S, Raji CA. Neurobiology of COVID19. *J Alzheimers Dis* 2020;76:3–19.
- [5] Vaz A, Costa A, Pinto A, et al. Complex regional pain syndrome after severe COVID-19—A case report. *Heliyon* 2021;7:e20846.

Diaa Shehab MD, FRCPC^{a,b}

Ahmad Jasem Abdulsalam MD, KBPMR^{a,*}

Rajiv N. Reebye MD, FRCPC^{c,d}

^aDepartment of Physical Medicine and Rehabilitation, Mubarak Al-Kabeer Hospital, 43753 Jabriya, Kuwait

^bDepartment of Medicine, Faculty of Medicine, Kuwait University, 43753 Jabriya, Kuwait

^cDivision of Physical Medicine and Rehabilitation, Faculty of Medicine, University of British Columbia, V6T 1Z3 Vancouver, British Columbia, Canada

^dGF Strong Rehabilitation Centre, Vancouver, V5Z 2G9 British Columbia, Canada

*Corresponding author.

E-mail address: dr.ahmad.j.abdulsalam@gmail.com

(A.J. Abdulsalam)

Received 13 March 2022

Accepted 25 March 2022

Available online 02 May 2022

<https://doi.org/10.1016/j.neurol.2022.03.013>

0035-3787/© 2022 Elsevier Masson SAS. All rights reserved.