

## Stealth Autoguide for robotic-assisted laser ablation for lesional epilepsy: illustrative case

David J. Mazur-Hart, MD, Nasser K. Yaghi, MD, Maryam N. Shahin, MD, and Ahmed M. Raslan, MD

Department of Neurological Surgery, Oregon Health & Science University, Portland, Oregon

**BACKGROUND** Laser interstitial thermal therapy has been used in tumor and epilepsy surgery to maximize clinical treatment impact while minimizing morbidity. This intervention places a premium on accuracy. With the advent of robotics, neurosurgery is entering a new age of improved accuracy. Here, the authors described the use of robotic-assisted laser placement for the treatment of epileptiform lesions.

**OBSERVATIONS** The authors presented a case of a 21-year-old woman with medically intractable epilepsy, localized to left mesial temporal sclerosis and left temporal encephalocele by way of stereotactic electroencephalography, who presented for consideration of surgical intervention. When presented with resection versus laser ablation, the patient opted for laser ablation. The patient received robotic-assisted stereotactic laser ablation (RASLA) using a Stealth Autoguide. The patient was seizure free (10 weeks) after surgical ablation.

**LESSONS** RASLA is an effective way to treat epilepsy. Here, the authors reported the first RASLA procedure with a Stealth Autoguide to treat epilepsy. The procedure can be performed effectively and efficiently for multiple epileptic foci without the need for bulkier robotic options or head frames that may interfere with the use of magnetic resonance imaging for heat mapping.

<https://thejns.org/doi/abs/10.3171/CASE21556>

**KEYWORDS** robot; laser; stereotactic; neurosurgery; epilepsy

The field of neurosurgery has spent decades attempting to maximize accuracy and minimize the approach vector. The advent of robotics in neurosurgery has opened up an array of new possibilities (Table 1).<sup>1-4</sup> One such possibility is increased accuracy during stereotactic procedures, allowing for a high degree of safety.<sup>3,5-9</sup> Laser interstitial thermal therapy (LITT) is an intervention that allows for minimally invasive tissue ablation for both tumor and epilepsy surgery.<sup>10-19</sup> Unfortunately, the added complexity of using magnetic resonance imaging (MRI) to monitor thermal ablations in real time has made procedure efficiency challenging.<sup>20</sup> The Stealth Autoguide (Medtronic) robot is a promising stereotactic robot that can increase accuracy and efficiency.<sup>21</sup> It is small and portable, which lends itself to MR-guided LITT. Here, we describe robotic-assisted stereotactic laser ablation (RASLA) using a Stealth Autoguide robot to safely and efficiently place fiberoptic cables in an intraoperative MRI (iMRI) suite for laser interstitial thermal ablation of seizure foci.

### Illustrative Case

A 21-year-old woman with medically intractable focal left temporal lobe epilepsy experienced her first seizure at 16 years of age. Scalp electroencephalogram was notable for left temporal ictal onset. Brain MRI revealed left mesial temporal sclerosis and a left temporal encephalocele (Fig. 1). Positron emission tomography revealed hypometabolism of the left temporal lobe. The case was presented at our institutional multidisciplinary Epilepsy Board. Stereotactic electroencephalogram for depth electrode seizure monitoring was recommended. The patient received robotic-assisted placement of stereotactic electroencephalography with placement of 15 electrodes. At this surgery, a robotic stereotactic assistance (ROSA; Zimmer Biomet) robot was used. This robot was selected because the procedure does not require iMRI and it uses a larger number of electrodes. Electrode recordings revealed left entorhinal/encephalocele and left hippocampal ictal onset regions. Wada testing revealed left language dominance and stronger

**ABBREVIATIONS** AED = antiepileptic drug; iMRI = intraoperative MRI; LITT = laser interstitial thermal therapy; MRI = magnetic resonance imaging; PACU = postanesthesia care unit; RASLA = robotic-assisted stereotactic laser ablation; ROSA = robotic stereotactic assistance.

**INCLUDE WHEN CITING** Published February 7, 2022; DOI: 10.3171/CASE21556.

**SUBMITTED** September 28, 2021. **ACCEPTED** December 9, 2021.

© 2022 The authors, CC BY-NC-ND 4.0 (<http://creativecommons.org/licenses/by-nc-nd/4.0/>).

**TABLE 1. Robotic systems used in neurosurgery for LITT**

System	Authors & Year	Pathology	Navigation System	Manufacturer
ROSA	Chan et al., 2016 <sup>1</sup>	Tumor, brainstem	ROSA built-in	Zimmer Biomet
NeuroBlate	Singh et al., 2017 <sup>2</sup>	Epilepsy, laser callosotomy	Brainlab	Monteris Medical
Neuromate	Kim et al., 2020 <sup>3</sup>	Tumor, simulation	Voxim	Renishaw
iSYS1	Casali et al., 2021 <sup>4</sup>	Tumor	Medtronic Stealth	Interventional Systems Medizintechnik GmbH
Stealth Autoguide	Mazur-Hart et al., 2021	Epilepsy, mesial temporal sclerosis, encephalocele	Medtronic Stealth	Medtronic

ROSA = robotic stereotactic assistance.

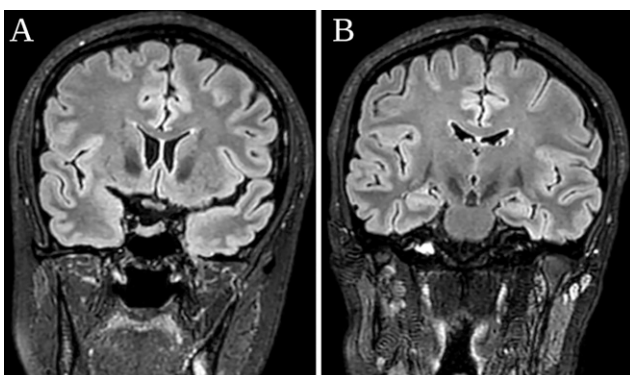
memory over the right hemisphere. Four months later, the patient's case was presented at Epilepsy Board again; surgical resection versus ablation of the left entorhinal cortex and encephalocele as well as the left hippocampus was recommended. The patient selected ablative therapy.

### Technical Note

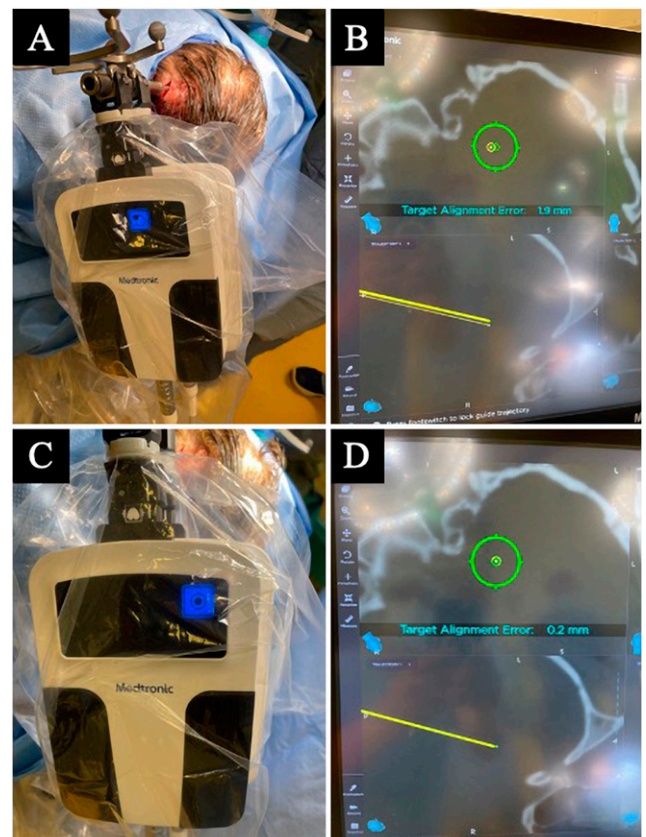
In this procedure, the anesthesia team induces general endotracheal anesthesia in a patient in the iMRI operative suite. The head is marked for six radiopaque bone fiducials. The hair is minimally clipped, and the head is prepared sterily with chlorhexidine. Six cranial fiducials are placed via small stab incisions and the use of a power screwdriver. A stereotactic quality head CT of the patient with fiducials in place is then obtained. The patient returns to the iMRI suite and is positioned on the operating table. The head is pinned with titanium pins and MRI-compatible cranial fixation clamp. The head is then registered to the Medtronic Stealth Station using the navigation frame and the cranial fiducials. Incisions are marked on the scalp using the navigation system to identify the planned entry points for the laser. Again, the hair is minimally clipped, and the head is reprepared sterily with chlorhexidine and ChlorPrep (BD). A Stealth Autoguide robot is attached to the cranial fixation frame using a universal adapter. The patient and robot are sterily draped.

Using the navigation system, the planned entry points are confirmed and infiltrated with local anesthesia with epinephrine. The target that has the longest trajectory, in this case the hippocampus, is the starting point, which allows maintenance of maximum accuracy over the longest distance to minimize error. The robot is placed near the

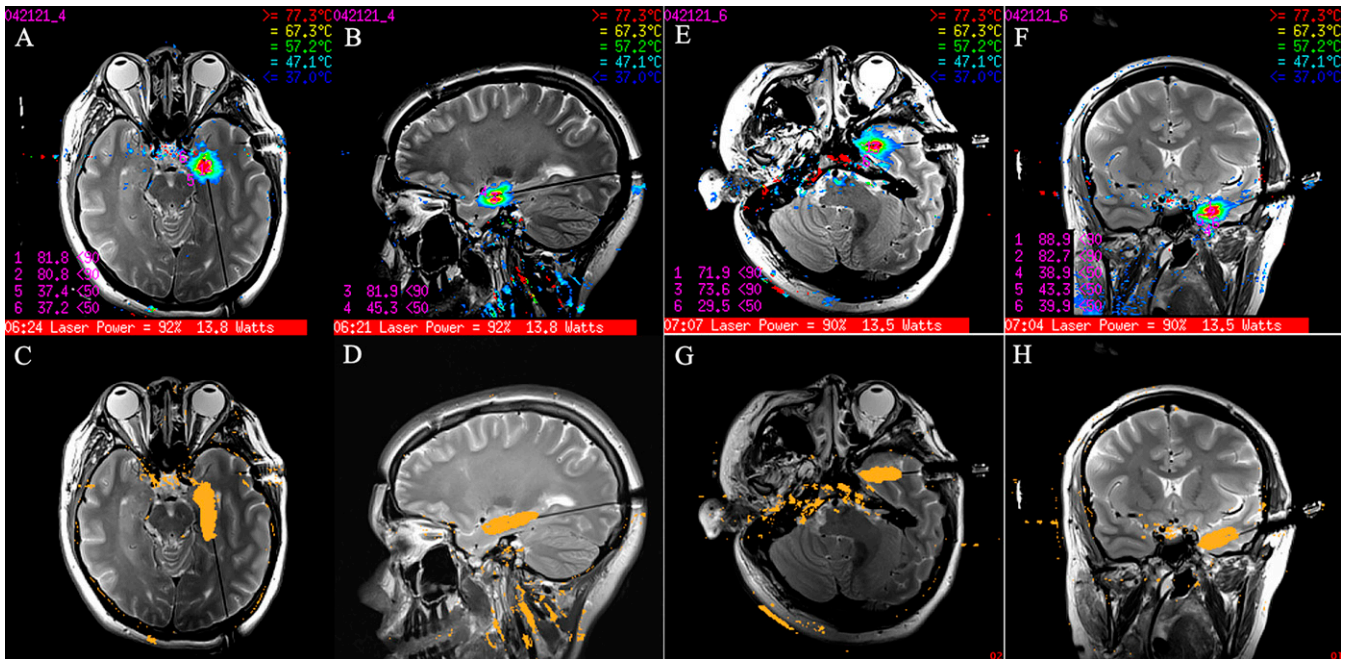
hippocampal entry site using manual adjustment of the robot sterily. The robot guides the surgeon to a suitable position during this manual adjustment by indicator lights on the device that notify the surgeon when the robot is within striking range to lock onto the target. The navigational arm is then assembled and attached to the robot. The robot, using the stereotactic navigation system, automatically makes fine adjustments to lock onto the planned trajectory. Skin incision and dissection are carried down to the level of the skull. The robot's navigational arm is exchanged for the drill guide. Accuracy is again finely



**FIG. 1.** Preoperative MRI of brain with and without gadolinium contrast. **A:** Coronal fluid-attenuated inversion recovery (FLAIR) depicting small left temporal encephalocele. **B:** Coronal FLAIR depicting left mesial temporal sclerosis.



**FIG. 2.** Intraoperative pictures of Medtronic Autoguide navigational robot. **A:** Navigational arm situated in entry incision after surgeon targeting, with display noting near target trajectory. **B:** Display of target alignment error after initial manual positioning. **C:** Autoguide display after robotic fine adjustments, with display noting accurate trajectory. **D:** Display of target alignment error after robotic adjustment.



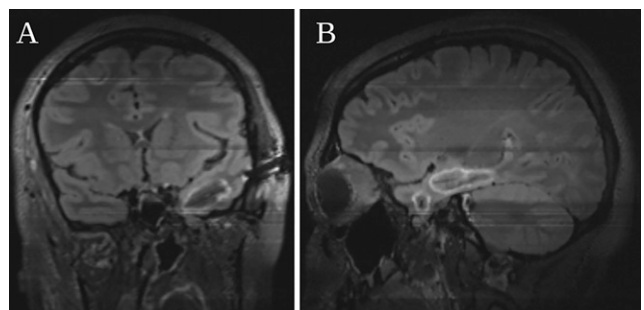
**FIG. 3.** Visualase thermal maps for left mesial temporal hippocampal sclerosis. Axial (A) and sagittal (B) T2-weighted noncontrast MRI of the brain demonstrating real-time laser probe in-plane views during laser thermal ablation. Laser power at 92% (13.8 W). Thermal temperature key in top right corner. Temperature safety limit set points 1 to 6 are in pink (bottom left). Axial (C) and sagittal (D) T2-weighted noncontrast MRI of the brain showing the final thermally ablated tissue area with excellent coverage of the left mesial temporal sclerosis as intended. Visualase thermal maps for left temporal encephalocele. Axial (E) and coronal (F) T2-weighted noncontrast MRI of the brain demonstrating real-time laser probe in-plane views during laser thermal ablation. Laser power at 90% (13.5 W). Thermal temperature key in top right corner. Temperature safety limit set points 1 to 6 are in pink (bottom left). Axial (G) and coronal (H) T2-weighted noncontrast MRI of the brain showing the final thermally ablated tissue area with good coverage of the left temporal encephalocele as intended.

adjusted by the robot (Fig. 2). A high-speed drill is passed down the drill guide, and a small burr hole is created using the robot to maintain the precise trajectory. Prior to drilling, it is important to confirm navigation accuracy and ensure proper final trajectory because this trajectory of the burr hole dictates the final trajectory of the laser. A bolt, designed to interface with the laser, is then passed over a stylet, with the stylet maintained in the robot navigation arm to preserve trajectory. The bolt is hand screwed into the burr hole until finger-tight pressure is reached. The stylet is removed, and the robot is moved out of the working field while remaining sterile. The intraparenchymal cannula is then advanced through the bolt to the premeasured target depth and secured in place with the bolt. We create a depth stop with a folded sticker along the cannula at the appropriate depth to reduce risk of iatrogenic injuries. These steps are repeated for the entorhinal/encephalocele target as well.

The drapes, robot, and navigational frame are all removed. The Medtronic Visualase thermal laser is assembled for both anchor bolts and placed within their respective cannulas. A pre-MRI safety pause with checklist is completed, and the MRI scanner is brought into the iMRI suite. Both lasers are confirmed to be on target with the initial MRI scan. Both lesions are thermally ablated in series, with interval sequential laser adjustments between MRI scans to obtain the desired thermal lesions. The thermal lesions are monitored in real time with MRI (Fig. 3). Once the ablation has been completed, final MRI sequences are obtained, and the scanner is removed (Fig. 4). The bolts are loosened, and cannulas are removed with the lasers.

The anchor bolts are removed and the incisions closed. The fiducials are removed and stab incisions closed.

Our patient was extubated in the iMRI suite and taken to the postanesthesia care unit (PACU). The patient had no new neurological deficits. The patient was transitioned to the neurosciences intensive care unit after recovery in the PACU. Antiepileptic drugs (AEDs) were continued and a short dexamethasone taper was given. The patient was transferred to the neurosurgery ward on postoperative day 1 and discharged home on postoperative day 2.



**FIG. 4.** Postoperative MRI of brain with and without gadolinium contrast. **A:** Coronal FLAIR section representation of entorhinal/encephalocele ablation. **B:** Sagittal FLAIR section representation of hippocampal ablation.



Both lesions were made on target without need for replacement of lasers. The patient has had no seizures and continues on AEDs at last known follow-up (10 weeks) after the procedure. The patient did not have to receive surgery for any reason during postoperative recovery.

This technique has been used for an additional patient with epilepsy. The patient had a single left hippocampal target, which was placed accurately and lesioned appropriately. This patient is also seizure free postoperatively and continues to take AEDs at last known follow-up (2 months) after the procedure.

## Discussion

### Observations

In this report, we describe the use of a navigational robot to precisely place two thermal lasers for lesional ablation using MRI guidance for the treatment of seizure foci causing epilepsy. Many techniques have been used to accurately target small intraparenchymal lesions. With the advent of robotics in neurosurgery, there has been significant improvements in accuracy, especially for reaching deep and small lesions in a minimally invasive fashion. Unfortunately, the use of robots in practice can be cumbersome and bulky. The use of MRI adds an extra degree of complexity to a case with the need to minimize bulk around the patient and remove ferromagnetic objects from the field. Use of the Stealth Autoguide robot has improved the ability to efficiently place LITT hardware. It is facile and diminutive compared to other navigational robots, which lends itself to an iMRI suite. It can be quickly adjusted with human-assisted movements, with the final trajectory finely tuned by the robot, quicker than could be accomplished by surgeon-aligned methods. It can also be used to efficiently target single or multiple trajectories with great accuracy. The Stealth Autoguide robot can then be removed by hand and removed from the iMRI suite before the magnet is used.

At our institution, we also use a ROSA robot. We have previously trialed the use of the ROSA robot for LITT procedures. However, bulkiness of the robot, need for extensive frame placement and positioning, and time-consuming registration process added a significant amount of time for the placement of one or two lasers, which did not support use at our institution. We have extensive experience using the ROSA robot for stereoelectroencephalography lead placement, and there likely is a specific number of leads that must be placed to make the ROSA process efficient, which we plan to study. The final six ROSA cases for LITT used the same operative workflow. Five patients received a single laser, and one patient received two lasers. Average operative time was 379 minutes (range, 343–430 minutes). In comparison, the last six Autoguide cases of LITT included five patients with a single laser and one patient with two lasers. The average operative time was 298 minutes (range, 250–372 minutes). At this time, we recommend the Stealth Autoguide robot for stereotactic lead placement of one to two leads.

### Lessons

Navigational assisted robots and robotic-assisted surgery are the future of neurosurgery. Certain facets of neurosurgery will be difficult to be replaced by the use of robots; however, robots are excellent for the accurate targeting of small intraparenchymal lesions that are located deep in the brain in a minimally invasive fashion. This makes them especially amenable for thermal ablation. Smaller robots with quicker movements appear more favorable for RASLA. We have changed our

practice to using the Stealth Autoguide robot for all LITT procedures, with overall improved efficiency and accuracy.

## Acknowledgments

We thank Shirley McCartney, PhD, for editorial assistance.

## References

1. Chan AY, Tran DK, Gill AS, Hsu FP, Vadera S. Stereotactic robot-assisted MRI-guided laser thermal ablation of radiation necrosis in the posterior cranial fossa: technical note. *Neurosurg Focus*. 2016;41(4):E5.
2. Singh H, Essayed WI, Deb S, Hoffman C, Schwartz TH. Minimally invasive robotic laser corpus callosotomy: a proof of concept. *Cureus*. 2017;9(2):e1021.
3. Kim LH, Feng AY, Ho AL, et al. Robot-assisted versus manual navigated stereoelectroencephalography in adult medically-refractory epilepsy patients. *Epilepsy Res*. 2020;159:106253.
4. Casali C, Del Bene M, Messina G, Legnani F, DiMeco F. Robot assisted laser-interstitial thermal therapy with iSYS1 and Visualase: how I do it. *Acta Neurochir (Wien)*. 2021;163(12):3465–3471.
5. De Benedictis A, Trezza A, Carai A, et al. Robot-assisted procedures in pediatric neurosurgery. *Neurosurg Focus*. 2017;42(5):E7.
6. Ahmed SI, Javed G, Mubeen B, et al. Robotics in neurosurgery: a literature review. *J Pak Med Assoc*. 2018;68(2):258–263.
7. Neudorfer C, Hunsche S, Hellmich M, El Majdoub F, Maarouf M. Comparative study of robot-assisted versus conventional frame-based deep brain stimulation stereotactic neurosurgery. *Stereotact Funct Neurosurg*. 2018;96(5):327–334.
8. Terrier L, Gilard V, Marguet F, Fontanilles M, Derrey S. Stereotactic brain biopsy: evaluation of robot-assisted procedure in 60 patients. *Acta Neurochir (Wien)*. 2019;161(3):545–552.
9. Fomenko A, Serletis D. Robotic stereotaxy in cranial neurosurgery: a qualitative systematic review. *Neurosurgery*. 2018;83(4):642–650.
10. Zeller S, Kaye J, Jumah F, et al. Current applications and safety profile of laser interstitial thermal therapy in the pediatric population: a systematic review of the literature. *J Neurosurg Pediatr*. Published online July 2, 2021. doi: 10.3171/2021.2.PEDS20721.
11. Munoz-Casabella A, Alvi MA, Rahman M, Burns TC, Brown DA. Laser interstitial thermal therapy for recurrent glioblastoma: pooled analyses of available literature. *World Neurosurg*. 2021;153:91–97.e1.
12. Fayed I, Sacino MF, Gaillard WD, Keating RF, Oluigbo CO. MR-guided laser interstitial thermal therapy for medically refractory lesional epilepsy in pediatric patients: experience and outcomes. *Pediatr Neurosurg*. 2018;53(5):322–329.
13. Torres-Reveron J, Tomasiewicz HC, Shetty A, Amankulor NM, Chiang VL. Stereotactic laser induced thermotherapy (LITT): a novel treatment for brain lesions regrowing after radiosurgery. *J Neurooncol*. 2013;113(3):495–503.
14. Zemmar A, Nelson BJ, Neimat JS. Laser thermal therapy for epilepsy surgery: current standing and future perspectives. *Int J Hyperthermia*. 2020;37(2):77–83.
15. Ross L, Naduvil AM, Bulacio JC, Najm IM, Gonzalez-Martinez JA. Stereoelectroencephalography-guided laser ablations in patients with neocortical pharmacoresistant focal epilepsy: concept and operative technique. *Oper Neurosurg (Hagerstown)*. 2018;15(6):656–663.
16. Youngerman BE, Save AV, McKhann GM. Magnetic resonance imaging-guided laser interstitial thermal therapy for epilepsy: systematic review of technique, indications, and outcomes. *Neurosurgery*. 2020;86(4):E366–E382.

17. Wicks RT, Jermakowicz WJ, Jagid JR, et al. Laser interstitial thermal therapy for mesial temporal lobe epilepsy. *Neurosurgery*. 2016;79(suppl 1):S83–S91.
18. Rennert RC, Khan U, Bartek J, et al. Laser ablation of abnormal neurological tissue using robotic neuroplate system (LAANTERN): procedural safety and hospitalization. *Neurosurgery*. 2020;86(4): 538–547.
19. Willie JT, Laxpati NG, Drane DL, et al. Real-time magnetic resonance-guided stereotactic laser amygdalohippocampotomy for mesial temporal lobe epilepsy. *Neurosurgery*. 2014;74(6): 569–585.
20. Guo Z, Leong MC, Su H, Kwok KW, Chan DT, Poon WS. Techniques for stereotactic neurosurgery: beyond the frame, toward the intraoperative magnetic resonance imaging-guided and robot-assisted approaches. *World Neurosurg*. 2018;116:77–87.
21. Brandman D, Hong M, Clarke DB. Preclinical evaluation of the Stealth Autoguide robotic guidance device for stereotactic cranial surgery: a human cadaveric study. *Stereotact Funct Neurosurg*. 2021;99(4):343–350.

## Disclosures

The Oregon Health & Science University Department of Neurological Surgery received industry education grant funding and kind support from Abbott, Biotronik, and Precision NeuroTek. Dr. Raslan is a consultant for Abbott and Biotronik and cofounder of Precision Neurotek, Inc.

## Author Contributions

Conception and design: Raslan, Mazur-Hart, Shahin. Acquisition of data: Mazur-Hart, Yaghi. Analysis and interpretation of data: Raslan, Mazur-Hart, Yaghi. Drafting the article: Raslan, Mazur-Hart, Yaghi. Critically revising the article: all authors. Reviewed submitted version of manuscript: all authors. Approved the final version of the manuscript on behalf of all authors: Raslan.

## Correspondence

Ahmed M. Raslan: Oregon Health & Science University, Portland, OR. [raslana@ohsu.edu](mailto:raslana@ohsu.edu).