

# Effects of a compound vitamin B mixture in combination with GeneTime<sup>®</sup> on radiation-induced oral mucositis

Hui Sun<sup>1,\*</sup>, Xiaoshuai Zhu<sup>2,\*</sup>, Dan Li<sup>1</sup> and Tao Cheng<sup>1</sup> 

## Abstract

**Objective:** Both compound vitamin B mixtures and GeneTime<sup>®</sup> have been used in treatment of oral inflammation. This study aimed to assess the therapeutic effects of a compound vitamin B mixture combined with GeneTime<sup>®</sup> on radiation-induced oral mucositis.

**Methods:** A total of 100 patients with radiation-induced oral mucositis were randomly divided into a control group (vitamin B alone; n = 50 patients) and an observation group (vitamin B plus GeneTime<sup>®</sup>, n = 50 patients). Clinical outcomes were compared between the two groups for the following 3 weeks.

**Results:** The observation group had a significantly greater number of grade 0–I patients and significantly fewer grade II–IV patients than the control group. Among patients in the observation group, a significantly greater number of ulcers healed within 1–2 weeks, compared with those in patients in the control group. Significantly fewer ulcers healed among patients in the observation group at 3 weeks; notably, there were fewer ulcers to heal in the observation group, compared with the control group.

**Conclusions:** Use of a compound vitamin B mixture combined with GeneTime<sup>®</sup> exerted obvious therapeutic effects on radiation-induced oral mucositis and markedly shortened ulcer healing time. Therefore, this strategy may be useful in clinical applications.

\*These authors contributed equally to this work.

## Corresponding author:

Tao Cheng, No. 28 Fuxing Road, Haidian District, Department of Stomatology, Chinese PLA General Hospital, Beijing 100853, P. R. China.  
Email: mbc381@163.com

<sup>1</sup>Department of Stomatology, Chinese PLA General Hospital, Beijing, P. R. China

<sup>2</sup>Department of Thoracic Surgery, Shandong Weifang Yi Du Central Hospital, Weifang, P. R. China



## Keywords

Compound vitamin B mixture, GeneTime<sup>®</sup>, radiation-induced oral mucositis, oral ulcers, radiotherapy, head and neck cancer, oral erythema

Date received: 19 September 2018; accepted: 21 January 2019

## Introduction

Radiation-induced oral mucositis is a common complication of radiotherapy in cancer patients, with an incidence rate of >40%.<sup>1</sup> Radiation-induced oral mucositis typically occurs after 2–3 weeks of conventional fractionated radiotherapy (radiation dose 20–30 Gy) and worsens in a progressive manner.<sup>2</sup> Modern radiotherapy technology is increasingly optimized to alleviate adverse reactions associated with radiotherapy; by enhancing the application of conformal radiotherapy or image-guided radiotherapy, the radiation dose administered to normal tissue can be reduced. Before radiotherapy, patients should receive necessary education, good oral hygiene habits, and a light diet during treatment, to delay the occurrence of oropharyngeal mucositis and reduce the degree of oropharyngeal mucositis.<sup>3</sup> However, such precautions cannot prevent the occurrence of oral mucositis.

Notably, the severity of oral mucositis is positively correlated with radiation dose.<sup>4</sup> The clinical symptoms of affected patients primarily include oral mucosal hyperemia, edema, and ulceration, which lead to loss of appetite and swallowing pain.<sup>5</sup> It is particularly important to take active and effective measures to prevent and treat radiation-induced oral mucositis during radiotherapy.<sup>6</sup> A variety of therapeutic methods can be used in the clinic, such as glucocorticoids, cell protective agents, antimicrobial gargle, oral mucosal protective agents, and biological response modifiers.<sup>7–11</sup>

Importantly, a compound vitamin B mixture, comprising a variety of metabolic

coenzymes, can participate in metabolic reactions in vivo, potentially repairing mucosal cell DNA molecules and promoting rapid healing of ulcers.<sup>9</sup> Multivitamin B can repair mucosal cell damage; form protective membrane vegetative cell tissue; prevent oral bacterial infection; and reduce glossitis, cheilitis, stomatitis, and oral ulcers caused by radiotherapy.<sup>12</sup> GeneTime<sup>®</sup> is a recombinant form of human epidermal growth factor, which has been successfully used in clinical applications involving wound healing and tissue repair.<sup>13,14</sup> Thus far, GeneTime<sup>®</sup> has clinical advantages in the treatment of radiation-induced oral mucositis, such as promotion of cell proliferation and positive influence regarding wound healing.<sup>13,15</sup> This study aimed to assess the clinical effects of multivitamin B combined with GeneTime<sup>®</sup> in the treatment of radiation-induced oral mucositis.

## Methods

### *Ethical approval*

The study was approved by the Institutional Ethics Committees of our hospitals, and written informed consent to participate in the study was obtained from all patients.

### *Patients*

Patients with radiation-induced oral mucositis were enrolled in this study, all of whom were admitted to our hospital during the period from January 2016 to January 2017, to receive targeted radiation therapy for head and neck tumors. The patients

were divided into a control group and an observation group by random lottery, and a double-blind method was used.

### **Experimental Treatment**

The control group received the compound vitamin B mixture with lidocaine, prepared as follows: 0.9% normal saline, 250 mL; compound vitamin B mixture, 250 mL; gentamicin, 160,000 U; 2% lidocaine, 25 mL. Patients were treated at the beginning of the study, as follows: warm salt water was used for cleansing the mouth, and the compound vitamin B mixture was used as mouthwash, 20 mL each time, 4 times per day. The mouthwash was used 10 minutes after each meal, as well as before bed; the mixture held in the mouth for 5 minutes, then swallowed slowly.

The observation group received the compound vitamin B mixture, combined with GeneTime<sup>®</sup>. The compound vitamin B mixture was prepared as described for the control group. GeneTime<sup>®</sup> (Shenzhen Huashengyuan Gene Engineering Development Co., Ltd., China; National Medicine Permit No. S20010038) was sprayed on oral erythema or ulcers, 4 times per day. Patients were instructed to refrain from drinking water within 30 minutes after use, to ensure that the liquid remained in the mouth as long as possible.

Similar irradiation methods were used in the two groups: a linear accelerator 6 MV X-ray with a face-and-neck combination for field penetration, or the front side of the cheek with a wedge plate. The neck was tangential or double-necked to the field, and the irradiation field was 10–14 cm<sup>2</sup>; 36–40 Gy was used to avoid the spinal cord, and 8–10 MeV electron line 14–24 Gy was used for the or upper neck. The total dose was 50–70 Gy; the median dose was 60 Gy.

### **Observation indices**

Oral mucositis after treatment was graded in accordance with the grading criteria for acute radiation injury established by the Radiation Therapy Oncology Group: 1) Grade 0: no mucosal change; 2) grade I: hyperemia and mild pain; 3) grade II: flaking mucositis, inflammatory serum, or blood secretions, as well as moderate pain; 4) grade III: confluent fibrous mucositis and severe pain; and 5) degree IV: necrosis, ulcers, and bleeding.<sup>16</sup> Oral mucositis was graded on the last day of radiation therapy. After treatment, the oral mucositis was assessed until it reached grade 0, which comprised ulcer healing. No change in grade after treatment, or a worse grade than the prior assessment was considered invalid—this was an outcome of the study, rather than an indicator for disqualification from the study. Ulcer healing times after treatment were compared on the basis of disappearance of mucositis, lack of pain, and resumption of a normal diet.<sup>17</sup> For each patient, ulcer area was measured as length × width (mm<sup>2</sup>) at 1, 2, and 3 weeks after treatment. The degree of pain was scored by using the visual analogue scale (VAS) (scale from 1–10, self-assessment) at 1, 2, and 3 weeks after treatment.

### **Statistical analysis**

According to the data of each indicator in the pre-survey, the sample size is estimated by 95% confidence interval, and the largest one is the sample size of the study. The sample size required for each group was >40 cases, on the basis of Fisher's exact probability.

All data were analyzed with SPSS 19.0 (IBM Corp., Armonk, NY, USA). The numerical data were expressed as %, and inter-group comparisons were performed using the  $\chi^2$  test. Categorical data were expressed as ( $\bar{x} \pm s$ ), and inter-group comparisons were performed using the independent

samples t-test. Differences with  $P < 0.05$  were considered to be statistically significant.

## Results

### Baseline clinical data

A total of 100 patients with radiation-induced oral mucositis were enrolled in this study, 50 patients per group, consistent with the sample size calculations. All had received targeted radiation therapy for head and neck tumors. The control group comprised 23 males and 27 females aged between 24 and 67 years (mean age,  $45.6 \pm 5.3$  years); the observation group comprised 24 males and 26 females aged between 22 and 68 years (mean age,  $45.3 \pm 5.4$  years). The groups did not significantly differ in sex, age, or types of cancer (Table 1). Other baseline clinical data, such as duration of disease and degree of oral mucositis, were similar between the two groups.

### Degree of oral mucositis

After treatment, the observation group had a significantly greater number of grade 0–I patients, but significantly fewer grade II–IV

patients, compared with the control group ( $P < 0.05$ ) (Table 2). The numbers of “invalid” outcomes were 10 (20%) in the control group and three (6%) in the observation group; this difference was statistically significant.

### Ulcer healing time

Among patients in the observation group, a significantly greater number of ulcers healed within 1–2 weeks, compared with those in patients in the control group. Significantly fewer ulcers healed among patients in the observation group at 3 weeks ( $P < 0.05$ ) (Table 3). Notably, there were fewer ulcers to heal in the observation group, compared with the control group, between 2 and 3 weeks. No adverse reactions occurred in any of the patients.

### Measurement of patient ulcer area

The areas of oral ulcers in the 2 groups were measured at 1 week, 2 weeks and 3 weeks ( $\text{mm}^2$ ) (Table 4). Patients in the observation group significantly showed smaller ulcer areas than in patients in the control group at all three timepoints ( $P < 0.001$ ) (Figure 1).

**Table 1.** Patient demographic and clinical data.

Group	Sex		Age, mean (SD)	Cancer type (%)			
	Male	Female		Nasopharyngeal carcinoma	Floor-of-mouth	Tongue	Tonsil
Control	23 (46)	27 (54)	45.6 (5.3)	36 (72)	7 (14)	4 (8)	3 (6)
Observation	24 (48)	26 (52)	45.3 (5.4)	35 (70)	7 (14)	5 (10)	3 (6)
P value	>0.05		>0.05	>0.05			

SD, standard deviation.

**Table 2.** Degree of oral mucositis after treatment [n (%)].

Group	Cases	Degree 0	Degree I	Degree II	Degree III	Degree IV
Control	50	1 (2.0)	10 (20.0)	22 (44.0)	13 (26.0)	4 (8.0)
Observation	50	6 (12.0)	21 (42.0)	13 (26.0)	9 (14.0)	1 (2.0)
P value		<0.05	<0.05	<0.05	<0.05	<0.05

**Table 3.** Ulcer healing time after treatment [n (%)].

Group	1 week	2 weeks	3 weeks
Control (n = 50)	11 (22.0)	17 (34.0)	22 (44.0)
Observation (n = 50)	23 (46.0)	25 (50.0)	2 (4.0)
P value	<0.05	<0.05	<0.05

**Table 4.** Ulcer area after treatment (mm<sup>2</sup>, mean ± standard deviation).

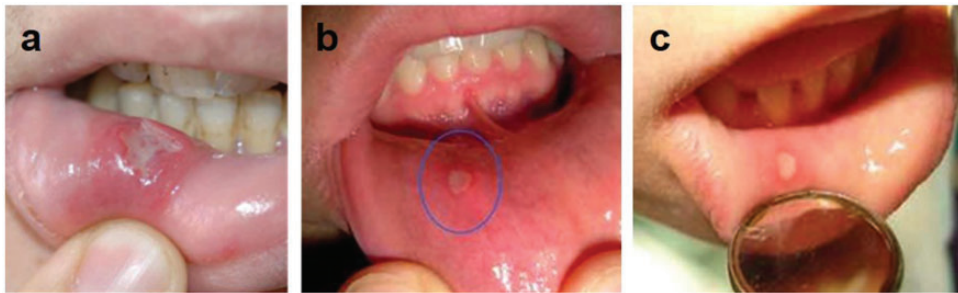
Group	1 week	2 weeks	3 weeks
Control	20.1 ± 1.2	13.3 ± 1.3	6.7 ± 1.1
Observation	15.3 ± 1.1	8.1 ± 1.1	2.7 ± 1.2
P value	<0.001	<0.001	<0.001

**Pain score**

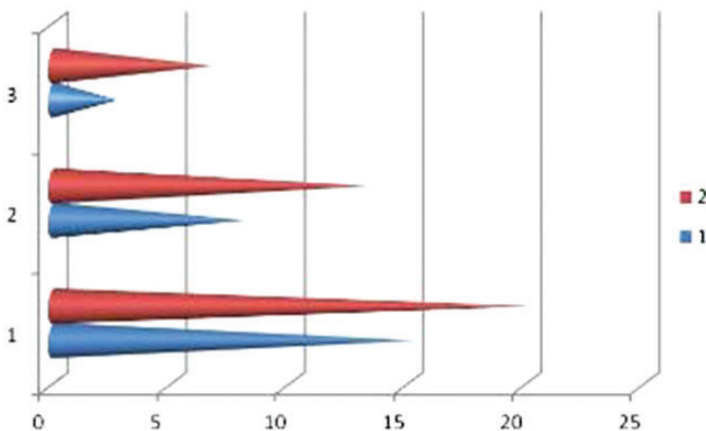
The VAS pain self-scoring results at 1 week, 2 weeks, and 3 weeks (1-10 self-assessment) were as follows (Figures 2, 3, Table 5). The degree of patient pain was gradually reduced over time in both two groups. Significantly less pain was observed in the observation group at each of the three assessments (P < 0.001).

**Discussion**

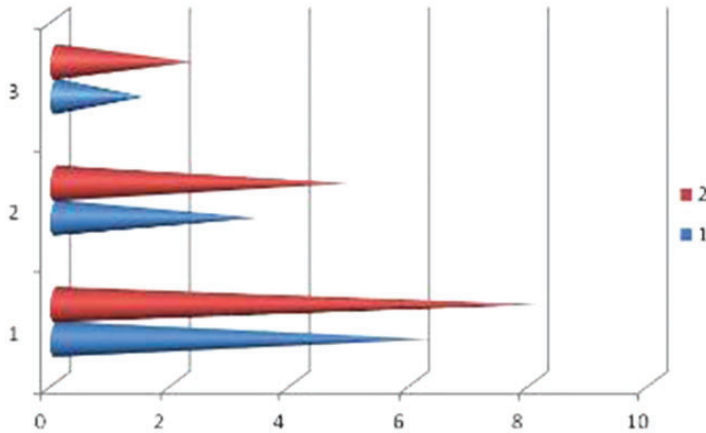
Patients with head and neck malignant tumors may experience an extremely high incidence of oral mucositis during



**Figure 1.** Photographs of improved ulcer area in a patient in the treatment group after (a) treatment for 1 week, (b) treatment for 2 weeks, and (c) treatment for 3 weeks.



**Figure 2.** Visual analogue scale (VAS) scores were improved at 1 and 2 (pain scores decreased significantly over time) following treatment. 1 represents observation group, 2 represents control group.



**Figure 3.** Visual analogue scale pain scores.

**Table 5.** Patient pain after treatment (visual analog score, mean  $\pm$  standard deviation).

Group	1 week	2 weeks	3 weeks
Control	8.1 $\pm$ 1.1	4.9 $\pm$ 0.9	2.3 $\pm$ 1.1
Observation	6.3 $\pm$ 0.9	3.4 $\pm$ 1.0	1.5 $\pm$ 1.0
P value	<0.001	<0.001	<0.001

radiotherapy, which may occasionally interfere with the treatment response due to severe oral damage. The surface layer of the oropharyngeal mucosa is a stratified flat epithelium with a fast renewal rate. In particular, the epithelial cells of the soft palate, ventral tongue, lateral margin of the tongue, and bottom of the oral cavity have a rapid differentiation and proliferation rate; thus, they are sensitive to radiation.<sup>4,18,19</sup> Therefore, it is easy to cause radiation-induced mucosal damage<sup>20–22</sup>; this includes increased oral mucus composition, decreased pH in the tissue, and decreased oral self-cleaning ability. Such conditions facilitate the reproduction of bacteria, fungi, and other microorganisms; leading to radiation caries, toothache, and halitosis, as well as chewing difficulties due to aggravated oral mucosa. In addition to its direct killing effect, radiation can cause

swelling, narrowing, or blockage of the microvascular walls within the field, as well as local mucosal edema, resulting in poor blood supply at the damaged site; these changes further promote the occurrence of oral mucositis.<sup>23–26</sup> Therefore, effective measures to prevent radiation-induced oral mucositis have become a key focus of clinical research.

In this study, we compared the effects of a compound vitamin B mixture (control group) and a compound vitamin B mixture combined with GeneTime<sup>®</sup> (observation group) in treatment of radiation-induced oral mucositis. The results showed that the severity of oral mucositis in the observation group was primarily grades I and II, whereas that of the control group was grades II and III. In addition, the healing times in the observation and control groups were 1–2 weeks and 2–3 weeks, respectively. The numbers of “invalid” outcomes significantly differed between the groups: 10 (20%) in the control group, and three (6%) in the observation group. These findings suggested that the treatment effect in the observation group was more robust than that in the control group; specifically, the compound vitamin B mixture combined with GeneTime<sup>®</sup> exhibited a better therapeutic effect for treatment

of oral mucositis, compared with the compound vitamin B mixture alone. Invalid outcomes involving individuals in the observation group may have been associated with lower treatment compliance or individual differences among patients.

A compound vitamin B mixture may contribute to the repair of mucosal cell DNA molecules and promote rapid healing of oral ulcers caused by radiotherapy.<sup>9</sup> GeneTime<sup>®</sup>, a recombinant form of human epidermal growth factor, comprises a micromolecule polypeptide that has shown a curative effect in treatment of burns and chronic wounds; moreover, it significantly reduces pain and promotes healing of radiotherapy injury.<sup>27</sup> GeneTime<sup>®</sup> can repair wound tissue and promote epithelial cell proliferation, thereby shortening the duration of wound healing.<sup>10,11,26</sup> It also promotes the growth of various cells such as squamous epithelium and vascular endothelium, and enables regulation of protein synthesis.<sup>15,28</sup> Epidermal growth factor is a polypeptide that is widely distributed in humans and animals and can regulate multi-cell growth. Early studies have demonstrated the effect of epidermal growth factor on oral ulcers:<sup>29</sup> it can provide anti-inflammatory support, relieve oral pain, increase the patient's appetite, promote wound healing, minimize the duration and severity of radiation-induced oral mucositis, improve quality of life, and ensure smooth completion of treatment.

In summary, application of a combination of a compound vitamin B mixture with GeneTime<sup>®</sup> significantly improves treatment of radiation-induced oral mucositis and can markedly shorten the healing time of ulcers; thus, it may be useful in clinical practice.

#### Declaration of conflicting interest

The authors declare that there is no conflict of interest.

#### Funding

This research received no specific grant from any funding agency in the public, commercial, or not-for-profit sectors.

#### ORCID iD

Tao Cheng  <http://orcid.org/0000-0002-8768-2846>

#### References

1. Maria OM, Eliopoulos N and Muanza T. Radiation-induced oral mucositis. *Front Oncol* 2017; 7: 89.
2. Naylor W and Mallett J. Management of acute radiotherapy induced skin reactions: a literature review. *Eur J Oncol Nursing* 2001; 5: 221–233.
3. Moslemi D, Nokhandani AM, Otaghsaraei MT, et al. Management of chemo/radiation-induced oral mucositis in patients with head and neck cancer: A review of the current literature. *Radiother Oncol* 2016; 120: 13–20.
4. Shih A, Miaskowski C, Dodd MJ, et al. Mechanisms for radiation-induced oral mucositis and the consequences. *Cancer Nurs* 2003; 26: 222–229.
5. Sonis ST, Eilers JP, Epstein JB, et al. Validation of a new scoring system for the assessment of clinical trial research of oral mucositis induced by radiation or chemotherapy. Mucositis Study Group. *Cancer* 1999; 85: 2103–2113.
6. Zhang HH and D'Souza WD. A treatment planning method for better management of radiation-induced oral mucositis in locally advanced head and neck cancer. *J Med Phys* 2018; 43: 9–15.
7. Bockel S, Vallard A, Lévy A, et al. Pharmacological modulation of radiation-induced oral mucosal complications. *Cancer Radiother* 2018; 22: 429–437.
8. Mills EE. The modifying effect of beta-carotene on radiation and chemotherapy induced oral mucositis. *Br J Cancer* 1988; 57: 416–417.
9. Hadjieva T, Cavallin-Ståhl E, Linden M, et al. Treatment of oral mucositis pain following radiation therapy for head-and-neck cancer using a bioadhesive barrier-forming

- lipid solution. *Support Care Cancer* 2014; 22: 1557–1562.
10. Chattopadhyay S, Saha A, Azam M, et al. Role of oral glutamine in alleviation and prevention of radiation-induced oral mucositis: a prospective randomized study. *South Asian J Cancer* 2014; 3: 8–12.
  11. Sheibani KM, Mafi AR, Moghaddam S, et al. Efficacy of benzydamine oral rinse in prevention and management of radiation-induced oral mucositis: a double-blind placebo-controlled randomized clinical trial. *Asia Pac J Clin Oncol* 2015; 11: 22–27.
  12. Rembe JD, Fromm-Dornieden C and Stuermer EK. Effects of vitamin B complex and vitamin C on human skin cells: is the perceived effect measurable? *Adv Skin Wound Care* 2018; 31: 225–233.
  13. Hong JP, Lee SW, Song SY, et al. Recombinant human epidermal growth factor treatment of radiation-induced severe oral mucositis in patients with head and neck malignancies. *Eur J Cancer Care* 2009; 18: 636–641.
  14. Acosta JB, Savigne W, Valdez C, et al. Epidermal growth factor intralesional infiltrations can prevent amputation in patients with advanced diabetic foot wounds. *Int Wound J* 2010; 3: 232–239.
  15. Wu HG, Song SY, Kim YS, et al. Therapeutic effect of recombinant human epidermal growth factor (RhEGF) on mucositis in patients undergoing radiotherapy, with or without chemotherapy, for head and neck cancer: a double-blind placebo-controlled prospective phase 2 multi-institutional clinical trial. *Cancer* 2009; 115: 3699–3708.
  16. Chen P, Mancini M, Sonis ST, et al. A novel peptide for simultaneously enhanced treatment of head and neck cancer and mitigation of oral mucositis. *PLoS One* 2016; 11: e0152995.
  17. Lalla RV, Saunders DP and Peterson DE. Chemotherapy or radiation-induced oral mucositis. *Dent Clin North Am* 2014; 58: 341–349.
  18. Farbman AI, Brunjes PC, Rentfro L, et al. The effect of unilateral naris occlusion on cell dynamics in the developing rat olfactory epithelium. *J Neurosci* 1988; 8: 3290–3295.
  19. Jham BC and da Silva Freire AR. Oral complications of radiotherapy in the head and neck. *Braz J Otorhinolaryngol* 2006; 72: 704–708.
  20. Hamstra DA, Lee KC, Eisbruch A, et al. Double-blind placebo-controlled multicenter phase II trial to evaluate D-methionine in preventing/reducing oral mucositis induced by radiation and chemotherapy for head and neck cancer. *Head Neck* 2018; 40: 1375–1388.
  21. Clemente AM, Rizzetto L, Castronovo G, et al. Effects of near-infrared laser radiation on the survival and inflammatory potential of *Candida* spp. involved in the pathogenesis of chemotherapy-induced oral mucositis. *Eur J Clin Microbiol Infect Dis* 2015; 34: 1999–2007.
  22. Elkerm Y and Tawashi R. Date palm pollen as a preventative intervention in radiation- and chemotherapy-induced oral mucositis: a pilot study. *Integr Cancer Ther* 2014; 13: 468–472.
  23. Volpato LE, Silva TC, Oliveira TM, et al. Radiation therapy and chemotherapy-induced oral mucositis. *Braz J Otorhinolaryngol* 2007; 73: 562–568.
  24. Alvarez E, Fey EG, Valax P, et al. Preclinical characterization of CG53135 (FGF-20) in radiation and concomitant chemotherapy/radiation-induced oral mucositis. *Clin Cancer Res* 2003; 9: 3454–3461.
  25. Sarode S and Sarode G. Radiation-induced oral mucositis and periodontitis—proposal for an inter-relationship. *Oral Dis* 2014; 20: 631–632.
  26. Gruber S, Bozsaky E, Roitinger E, et al. Early inflammatory changes in radiation-induced oral mucositis: effect of pentoxifylline in a mouse model. *Strahlenther Onkol* 2017; 193: 499–507.
  27. Shen Z, Wang J, Huang Q, et al. Genetic modification to induce CXCR2 overexpression in mesenchymal stem cells enhances treatment benefits in radiation-induced oral mucositis. *Cell Death Dis* 2018; 9: 229.
  28. Techapichetvanich T, Wanitphakdeedecha R, Iamphonrat T, et al. The effects of



recombinant human epidermal growth factor containing ointment on wound healing and post inflammatory hyperpigmentation prevention after fractional ablative skin resurfacing: A split-face randomized controlled study. *J Cosmet Dermatol* 2018; 17: 756–761.

29. Girdler NM, McGurk M, Aqual S, et al. The effect of epidermal growth factor mouthwash on cytotoxic-induced oral ulceration. A phase I clinical trial. *Am J Clin Oncol* 1995; 18: 403–406.