

Peritoneal inclusion cysts treated with a levonorgestrel-releasing intrauterine system: A case report

Hanako Tamai ^{*}, Masato Kinugasa, Miho Nishio, Mayu Miyake

Department of Obstetrics and Gynecology, Amagasaki Co-op Hospital, 12-16-1 Minamimukonosono, Amagasaki 661-0033, Japan.

ARTICLE INFO

Article history:

Received 12 February 2019

Received in revised form 15 March 2019

Accepted 27 March 2019

Available online xxxx

Keywords:

Peritoneal inclusion cysts

Levonorgestrel-releasing intrauterine system

ABSTRACT

Patients with peritoneal inclusion cysts (PICs) often suffer from progressive abdominal or pelvic pain. There is no established treatment. We present the case of a 42-year-old woman with PICs complaining of progressive abdominal pain and fullness who was initially treated with drainage and gonadotropin releasing hormone agonist (GnRHa). Despite the treatment, her symptoms worsened approximately one year later. She was again treated with drainage and GnRHa, and subsequently a levonorgestrel-releasing intrauterine system (LNG-IUS) was placed in her intrauterine cavity. Thereafter, her condition stabilized and no complications were reported. The LNG-IUS may be an effective management option for patients with PICs.

© 2019 Published by Elsevier B.V. This is an open access article under the CC BY-NC-ND license (<http://creativecommons.org/licenses/by-nc-nd/4.0/>).

1. Introduction

Peritoneal inclusion cysts (PICs) are benign multiple cysts formed in the abdomino-pelvic cavity. PICs typically occur in women of reproductive age who have a history of abdominal or pelvic surgery, pelvic inflammatory disease, inflammatory bowel disease or endometriosis. Patients often suffer from progressive abdominal or pelvic pain and fullness.

There is no established treatment for PICs. Reported management has included surgical excision, sclerotherapy, chemotherapy and hormonal treatment. Surgical management alone is associated with a 30–50% rate of recurrence, regardless of the procedure [1]. Hormonal treatment has been shown to decrease or at least stabilize the size of the cysts and to control symptoms, and this approach is sometimes used to prevent recurrence after size reduction through palliative drainage and surgical excision. Oral contraceptives (OCs), gonadotropin releasing hormone agonist (GnRHa), tamoxifen and megestrol have been used as hormonal therapy [1]. Hormonal treatment has the advantages of being less invasive, having fewer complications and being more convenient for outpatient treatment. The levonorgestrel-releasing intrauterine system (LNG-IUS) has been safely used for contraception and hormonal therapy for a variety of indications, but there are no published reports of its use for PICs.

Here, we report the case of a patient with PICs who was successfully treated with a LNG-IUS.

2. Case Report

A 42-year-old woman presented with lower abdominal pain and fullness, which had gradually developed over the preceding two months. She had **regular menstrual cycles** with abdominal pain from the second half of her menstrual cycle to menses. She had tried OCs but had been unable to continue the treatment due to adverse effects. She had undergone a left ovarian cystectomy 10 years previously. The tumor was benign but a more detailed pathological report was no longer available.

An intramural myoma measuring 6 cm with significant ascites in the pouch of Douglas was detected by ultrasonography. The right ovary was normal, but the left ovary could not be visualized due to the myoma. For the differential diagnosis of malignancy, the patient underwent magnetic resonance imaging of her pelvis. A chocolate cyst that measured 4 × 2 cm was identified in her left ovary, and loculated intraperitoneal fluid and adhesions that centered on the normal right ovary were detected (Fig. 1). No mural nodules were noted in the capsule or the septal walls. The fluid in the cavities had low signal intensity on T1-weighted imaging and high signal intensity on T2-weighted imaging. Furthermore, the fluid intensity was the same in each cavity. We attempted transvaginal puncture of the pouch of Douglas and drainage for cytologic evaluation and to resolve her symptoms. Aspiration obtained a clear, yellowish serous liquid that did not contain malignant cells. We diagnosed PICs, based on the test results and her history of pelvic surgery.

Because the patient's symptoms were relieved by drainage and she did not want to conceive, we initiated conservative hormonal therapy.

Abbreviations: GnRHa, gonadotropin releasing hormone agonist; LNG-IUS, levonorgestrel-releasing intrauterine system; OC(s), oral contraceptive(s); PICs, peritoneal inclusion cysts.

^{*} Corresponding author.

E-mail addresses: tamaimomushi@yahoo.co.jp (H. Tamai), dr-kinugasa@mwc.biglobe.ne.jp (M. Kinugasa).

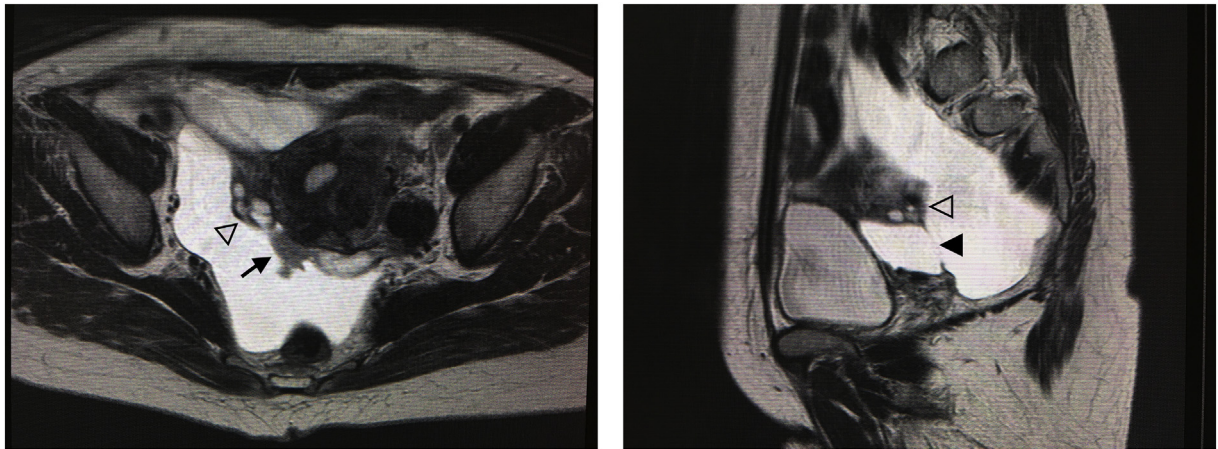


Fig. 1. Intrapelvic fluid and adhesion (▶□) around normal right ovary (▷). Note the mural nodule located posterior to uterus in the right fimbria of fallopian tube (◀◻).

As she was a smoker we selected GnRHa hormone therapy because of the thrombotic risk with combined oral contraceptives. Leuporelin acetate (3.75 mg) was administered subcutaneously, once every four weeks, on three occasions. Her symptoms were relieved by aspiration and did not worsen during hormone therapy, and the cavity gradually reduced in size (Fig. 2).

Approximately 12 months after the last administration of leuporelin acetate, her menstrual periods resumed regularly. During her second menstrual period, she experienced the same symptoms again, and an enlarged pelvic cyst was detected by ultrasonography. The fluid samples acquired by puncture of the pouch of Douglas were bloody; however, the cytology findings were negative. We speculated that the bloody fluid was derived from retrograde menstrual flow, because the sample was taken at the time of her period. Recurrent PICs was diagnosed. We administered the same dose of leuporelin acetate, six times. As observed during the previous treatment, her symptoms resolved and the cavity gradually reduced in size.

Although disease control might have been achieved by alternating the administration and cessation of leuporelin acetate every six months, we were concerned about exacerbation of her condition during the periods of cessation. We therefore decided to place a LNG-IUS (52 mg of levonorgestrel) into her uterus a month after the sixth administration of leuporelin acetate, before the resumption of menses. She did not have menses for 15 months after the treatment. We suspect that her long-term amenorrhea was not due to estrogen deficiency caused by GnRHa but, rather, was due to her anovulatory state, because her serum levels of follicle stimulating hormone, estradiol and progesterone at day 38 of the cycle were 2.6 mIU/mL, 478 pg/mL and

0.07 ng/mL, respectively. Her condition remained stable after the resumption of menses, the amount of menstrual blood loss was significantly reduced compared with pre-treatment, and PICs did not recur after LNG-IUS insertion (a 19-month observation period at the time of writing).

3. Discussion

Although the underlying mechanism is still under investigation, PICs are thought to be filled with serous fluid produced by the ovarian stroma, following intra-abdominal inflammation. Peritoneal fluid is mainly a product of the ovaries and is absorbed by the peritoneal surface. However, inflammation, infection, endometriosis and injury to the peritoneal surface retard its absorption and give rise to inflammatory exudate. Subsequently, adhesions due to inflammation develop on the septal walls, often around the normal ovary, and these spaces become filled with peritoneal fluid [1].

We believe that the success of treatment in this case might have been related to one or more of three factors. First, the decrease in peritoneal fluid could have been caused by suppression of ovulation by GnRHa and subsequent LNG-IUS insertion. A previous study that sampled peritoneal fluid laparoscopically reported that the amount increased gradually through the follicular phase, increased rapidly following ovulation and remained high during the luteal phase [2]. In this case, the patient complained of worsening symptoms during the second half of her menstrual cycle. This is the period in which increased physiological fluid produced by ovulation continues through the luteal phase. Increased peritoneal fluid could worsen PICs. The same study

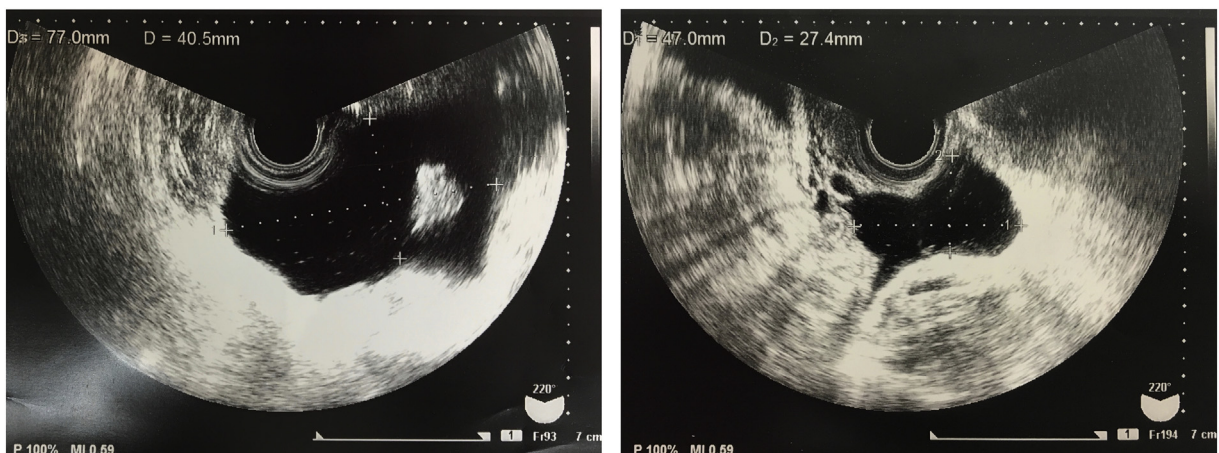


Fig. 2. 2-1. Douglas' pouch before administration. Fig. 2-2 Douglas' pouch 4 months after initial GnRHa administration.

also noted that anovulatory women taking OCs and postmenopausal women have consistently low volumes of peritoneal fluid [2]. This suggests that PICs can be controlled by reducing the production of peritoneal fluid through the suppression of ovulation. GnRHa suppresses ovulation, and the LNG-IUS inhibits ovulation in some women; in one report, approximately 25–55% of menstrual cycles showed inhibited ovulation among LNG-IUS (52 mg of levonorgestrel) users [3]. In this case, on the basis of her serum hormone levels, the patient was suspected to have anovulatory oligomenorrhea.

Second, retrograde flow of menstrual blood could have been reduced by GnRHa and subsequent LNG-IUS insertion. Her worsening symptoms during menses were presumed to be attributable to the increase in peritoneal fluid caused by retrograde menstrual flow. This was confirmed by the fact that the second sample of peritoneal fluid was bloody. She became amenorrhic with GnRHa, and subsequent LNG-IUS insertion significantly reduced the amount of menstrual blood loss. Retrograde menstrual flow would consequently be reduced.

Third, improving inflammation by treating the endometriosis with GnRHa and LNG-IUS could increase fluid absorption by the peritoneum and decrease the secretion of exudate.

Our patient was thought to have long-standing endometriosis, as she had a chocolate cyst and severe dysmenorrhea. In randomized controlled trials that investigated the LNG-IUS as a treatment for endometriosis and endometrioma following surgery, postoperative use of the device was found to significantly reduce the recurrence of painful periods [4,5]. One of these trials also reported that postoperative GnRHa and subsequent LNG-IUS therapy had a lower dysmenorrhea recurrence rate than GnRHa alone [4]. In another report, Gomes et al. [6] laparoscopically evaluated the effects of LNG-IUS therapy and those of GnRHa therapy for endometriosis. These investigators assessed endometriosis using the staging scores recommended by the American Society for Reproductive Medicine (ASRM) and found that the insertion of the LNG-IUS for six months improved ASRM scores as much as GnRHa therapy [6].

Endometriosis causes intraperitoneal inflammation, and some studies have demonstrated that this increases the amount of peritoneal fluid. Moreover, peritoneal fluid has higher levels of macrophages, prostaglandins, cytokines and growth factors in women with endometriosis [7]. The mechanism of action of the LNG-IUS on endometriosis is not known, although one study demonstrated that LNG-IUS insertion significantly reduced the amount of peritoneal fluid in women with endometriosis [7]. The authors suggested this might have been due to the device reducing inflammation. Similarly, another study reported that medroxyprogesterone acetate (MPA), a synthetic progestin, decreased peritoneal fluid volume in women with endometriosis and also decreased the levels of macrophages and inflammatory markers in the peritoneal fluid [8]. On the other hand, local action on the endometriotic implants or suppression of ovulation by levonorgestrel may be involved [7].

In summary, this case report supports the use of the LNG-IUS for conservative management of PICs in women who also require contraception.

Contributors

Hanako Tamai conceived of the case report, contributed to clinical care and case analysis, and drafted the paper.

Masato Kinugasa contributed to clinical care and case analysis.

Miho Nishio contributed to case analysis.

Mayu Miyake contributed to clinical care and case analysis.

Conflict of Interest

The authors declare that they have no conflict of interest regarding the publication of this case report.

Funding

No funding was sought or secured in relation to this case report.

Patient Consent

The patient provided written consent for the publication of this report.

Provenance and Peer Review

This case report was peer reviewed.

References

- [1] A.M. Vallerie, J.P. Lerner, J.D. Wright, L.V. Baxi, Peritoneal inclusion cysts: a review, *Obstet. Gynecol. Surv.* 64 (2009) 321–334.
- [2] P.R. Koninckx, M. Renaer, I.A. Brosens, Origin of peritoneal fluid in women: an ovarian exudation product, *Br. J. Obstet. Gynecol.* 87 (1980) 177–183.
- [3] Highlights of prescribing information, https://labeling.bayerhealthcare.com/html/products/pi/Mirena_PI.pdf (Accessed January 26, 2019).
- [4] Y.J. Chen, T.F. Hsu, B.S. Huang, H.W. Tsai, Y.H. Chang, P.H. Wang, Postoperative maintenance levonorgestrel-releasing intrauterine system and endometrioma recurrence: a randomized controlled study, *Am. J. Obstet. Gynecol.* 216 (2017) 582.e1–582.e9.
- [5] A.M. Abou-Setta, B. Houston, H.G. Al-Inany, C. Farquhar, Levonorgestrel-releasing intrauterine device (LNG-IUD) for symptomatic endometriosis following surgery, *Cochrane Database Syst. Rev.* 1 (2013) (CD005072).
- [6] M.K. Gomes, R.A. Ferriani, J.C. Rosa e Silva, A.C. Japur de Sá Rosa e Silva, C.S. Vieira, F.J. Cândido dos Reis, The levonorgestrel-releasing intrauterine system and endometriosis staging, *Fertil. Steril.* 87 (2007) 1231–1234.
- [7] F.B. Lockhat, J.E. Emembolu, J.C. Konje, Serum and peritoneal fluid levels of levonorgestrel in women with endometriosis who were treated with an intrauterine contraceptive device containing levonorgestrel, *Fertil. Steril.* 83 (2005) 398–404.
- [8] A.F. Haney, J.B. Weinberg, Reduction of the intraperitoneal inflammation associated with endometriosis by treatment with medroxyprogesterone acetate, *Am. J. Obstet. Gynecol.* 159 (1988) 450–454.