

# Transanal pullthrough Soave and Swenson techniques for pediatric patients with Hirschsprung disease

Xu Bing, MD\*, Chuancheng Sun, MD, Zhongrong Wang, MD, Yilin Su, MD, Hua Sun, MD, Liang Wang, MD, Xiyang Yu, MD

## Abstract

Both the Swenson and the Soave procedures have been adapted as transanal approaches. Our purpose is to compare the outcomes and complications between transanal Swenson and Soave procedures.

This clinical analysis involved a retrospective series of 148 pediatric patients with HD from Dec, 2001, to Dec, 2015. Perioperative/operative characteristics, postoperative complications, and outcomes between the 2 groups were analyzed. Students' *t*-test and chi-squared analysis were performed.

In total 148 patients (Soave 69, Swenson 79) were included in our study. Mean follow-up was 3.5 years. There are no significant differences in overall hospital stay and bowel function. We noted significant differences regarding mean operating time, blood loss, and overall complications. We noted significant differences in mean operating time, blood loss, and overall complications in favor of the Swenson group when compared to the Soave group ( $P < 0.05$ ).

According to our results, although transanal pullthrough Swenson cannot reduce overall hospital stay and improve bowel function compared with the Soave procedure, it results in less blood loss, shorter operation time, and a lower complication rate.

**Abbreviation:** HD = Hirschsprung disease.

**Keywords:** Hirschsprung disease, Soave, Swenson, transanal

## 1. Introduction

The surgical management of Hirschsprung disease (HD) has experienced great changes in the past 30 years. In the 1980s, the surgical procedure was reported by So et al.<sup>[1]</sup> Minimal access approaches were described in the 1990s and the laparoscopic procedure was reported by Georgeson et al.<sup>[2]</sup>

The transanal approach was first described by De la Torre-Mondragon and Ortega-Salgado.<sup>[3]</sup> Compared with the transabdominal approaches, the transanal pullthrough has been demonstrated to be associated with shorter hospital stay and fewer complications.<sup>[4,5]</sup> It has also been proposed to decrease the typical complications of a laparotomy such as adhesive bowel obstruction, wound complications, and inadvertent injury to the pelvic nerves.<sup>[6]</sup> The transanal pullthrough procedures have been

continuously improved. The modified Swenson procedure has been first reported and been modified in China by Xu et al.<sup>[7]</sup> in 2008. Now, the pullthrough Soave and Swenson procedures with or without laparoscopic assistance have become popular all over the world and both have many supporters.<sup>[8–10]</sup>

There have been very few studies directly comparing the transanal Soave and the transanal Swenson techniques.<sup>[11]</sup> At present, we report a retrospective study to compare the outcomes and complications after transanal Swenson and Soave procedures for HD.

## 2. Methods

### 2.1. Study population

We performed a retrospective chart analysis and identified all children who underwent transanal Soave and transanal Swenson pullthrough procedures in the Department of Pediatric Surgery of Anhui Provincial Hospital. All children who underwent transanal pullthrough from December, 2001, to December, 2015, were considered for this study. Research Ethics Board approval was obtained from Anhui Provincial Hospital.

### 2.2. Data collection

Data extracted from the chart reviews included details on patient demographics, comorbidities, age, operative time, blood loss, hospital stay, bowel function, complications, and duration of follow-up. The Rintala scale was used to evaluate the bowel function recovery.<sup>[13]</sup> All patients were clinically evaluated 6 months after the operation at the outpatient clinics or by telephone.

### 2.3. Inclusion/exclusion criteria

We included all children with HD who underwent transanal Swenson and Soave procedures between December, 2001, and December, 2015, in our institution. Since 2008 we started to

Editor: Johannes Mayr.

Funding: This project was funded by the Health Department of Anhui Province: 2009A042, 2010C034.

The authors have no conflicts of interest to disclose.

Department of Pediatric Surgery, Anhui Provincial Hospital, Affiliated to Anhui Medical University, Hefei, China.

\* Correspondence: Xu Bing, Department of Pediatric Surgery, Anhui Provincial Hospital Affiliated to Anhui Medical University, Hefei, Anhui, PR China (e-mail: xwh75520@sina.com).

Copyright © 2017 the Author(s). Published by Wolters Kluwer Health, Inc. This is an open access article distributed under the terms of the Creative Commons Attribution-Non Commercial-No Derivatives License 4.0 (CCBY-NC-ND), where it is permissible to download and share the work provided it is properly cited. The work cannot be changed in any way or used commercially without permission from the journal.

Medicine (2017) 96:10(e6209)

Received: 5 September 2016 / Received in final form: 2 February 2017 /

Accepted: 3 February 2017

<http://dx.doi.org/10.1097/MD.00000000000006209>

**Table 1**  
Patient characteristics.

	Soave	Swenson	Mean	P
Age, mean $\pm$ SD months	15.26 $\pm$ 2.71	13.55 $\pm$ 2.28	14.8 $\pm$ 2.51	>0.05
Weight, mean $\pm$ SD, kg	10.63 $\pm$ 2.14	9.3 $\pm$ 2.44	3.90 $\pm$ 2.35	>0.05
Level of aganglionosis				
Rectosigmoid	17	15		>0.05
Sigmoid	45	53		>0.05
Descending	7	11		>0.05

SD = standard deviation.

perform Swenson pullthrough procedures<sup>[7]</sup> and before 2008 all patients underwent Soave pullthrough procedures.<sup>[3]</sup> We excluded children suffering from long segment HD (defined as those with aganglionosis extending proximal to the splenic flexure) and children who underwent secondary surgery from the study. Children who underwent laparoscopic or transabdominal operations were also excluded from this study.

#### 2.4. Surgical technique

We routinely applied repeat cleansing enema once a day preoperatively for at least 5 days and bowel preparation 3 days before the operation. The Soave operations were performed according to the technique described by De la Torre-Mondragon and Ortega-Salgado.<sup>[3]</sup> The Swenson operations were carried out according to the modified Swenson technique described by Xu et al.<sup>[7]</sup> Although we did not perform a random controlled study, the antibiotic regiment and surgical procedures were not different between the 2 groups.

#### 2.5. Statistical analysis

Student's *t* test and chi-squared analysis were performed. A *P*-value < 0.05 was considered as significant.

### 3. Result

In total, 148 patients (Soave 69, Swenson 79) were included in our study. The mean follow-up interval was 3.5 years. The general information is shown in Table 1. There was no significant difference in age noted between the 2 groups. There was no significant difference regarding age at operation between the 2 groups. Table 2 shows the outcome variables. The mean operating time and blood loss were significantly lower in the Swenson group compared with the Soave group (*P* < 0.05). No significant difference was shown in the length of hospital stay and

**Table 2**  
Outcome measures.

	Soave	Swenson	Mean	P
Mean operating time $\pm$ SD, min	180.41 $\pm$ 30.12	153.96 $\pm$ 27.27	166.09 $\pm$ 27.29	<0.05
Mean blood loss $\pm$ SD, mL	51.24 $\pm$ 25.62	40.01 $\pm$ 14.41	45.22 $\pm$ 17.29	<0.05
Mean postoperative length of hospital stay $\pm$ SD, d	7.91 $\pm$ 3.13	7.84 $\pm$ 4.03	7.84 $\pm$ 3.69	>0.05
Mean defecation frequency $\pm$ SD at the last day of the hospital stay, d	10.21 $\pm$ 2.77	8.82 $\pm$ 3.23	9.45 $\pm$ 3.19	>0.05

SD = standard deviation

**Table 3**  
Effective rate and functions.

Bowel function score	Soave	Swenson	P
Total	15.54	16.60	>0.05
Rectosigmoid	17.42	18.14	>0.05
Sigmoid	15.03	14.96	>0.05
Descending	12.11	12.53	>0.05

the number of defecations per day at the last day of the hospital stay. The bowel function scales showed no difference between the 2 groups (Table 3). Three different types of HD were also analyzed and we noted similar trends between groups (Table 3). The postoperative complications of Soave and Swenson were compared in Table 4. The postoperative overall complications in the Soave group was 21/69 (30.4%) which was significantly higher when compared to the Swenson group (n = 12/79; 15.2%). The main complication we noted was perianal excoriation.

### 4. Discussion

Transanal Soave and Swenson operations (open, laparoscopic, or transanal) have emerged as the most commonly practiced procedures to treat short segment HD.<sup>[5]</sup> However, until now, the Soave approach which 1 of the 2 approaches should be applied in China's children in the future. However, no consensus has been reached regarding the best surgical method for treatment of HD.

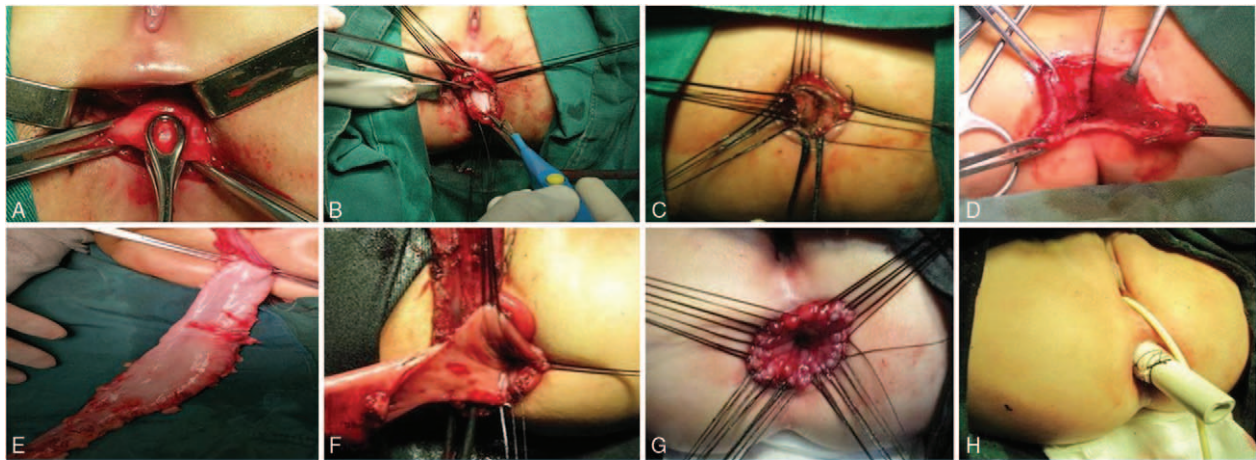
The rationale of the Soave operation is to decrease the risk of injury to pelvic structures, including autonomic nerves, urethra, prostate, or vagina, which can lead to devastating sequelae. The Swenson approach has the advantage of removing the affected rectal wall more thoroughly and inclines a lower risk of anastomotic strictures. The Swenson procedure reduces postoperative obstructive symptoms better than a Soave procedure.<sup>[12,14]</sup> The majority of patients underwent Swenson procedures would not suffer from constipation for a long period of time.<sup>[5]</sup> The transanal pullthrough Swenson procedure also has the advantage of a minimized surgical trauma thereby ensuring faster recovery.

The mean length of hospital stay (Soave group: 7.91  $\pm$  3.13 days; Swenson group: 7.84  $\pm$  4.03 days) and defecation frequency at the last day of the hospital stay (Soave group: 10.21  $\pm$  2.77 days; Swenson group: 8.82  $\pm$  3.23 days) in this study are similar to the intervals reported in the literature.<sup>[7,15]</sup> The mean operating time and blood loss are significantly lower in the Swenson group compared with the Soave group.

Reported series mentioned this complication and described improvement over time. It can also be relieved by traditional conservative treatment. The recurrence of constipation indicates that the treatment was not thorough and the effect is not as good

**Table 4**  
Postoperative complications.

	Soave	Swenson	P
Perianal excoriation	8	4	
Anastomotic stenosis	3	1	
Recurrent of constipation	1	1	
Fecal soiling	2	0	
Enterocolitis	5	4	
Total colon prolapsed	1	0	
Anastomotic fistula	1	2	
Overall	21 (30.43%)	12 (15.18%)	<0.05



**Figure 1.** Surgical procedures and techniques. (A) Forceps clamping the colon and pulling it out. (B) Cutting off the colon. (C) Closing the proximal colon. (D) Pulling the proximal colon into the abdominal cavity. (E) Dissection of the distal colon. Subsequently, the colon is pulled out. (F) Cutting the colon and starting the anastomosis of the colon. (G) Completing the suture line of the colon anastomosis. (H) Wrapping the rubber tube with vaseline gauze and inserting it into the neorectum.

as expected. Besides, many cases have functional constipation and this is not an indication of failure. Fortunately, its incidence rate is low in both procedures. Due to the small amount, the analysis did not take any specific complications into consideration in our study.<sup>[10,11]</sup> Although the pullthrough HD surgery has improved in the last decade, some complications of the abdominal operation are still unavoidable. The main complications include perianal excoriation, anastomotic stenosis, recurrent constipation, fecal soiling, enterocolitis, bowel prolapse, and anastomotic fistula.<sup>[14,15]</sup> In our study, the overall postoperative complication rate in the Swenson group was 15.2% and 30.4% in the Soave group ( $P=0.001$ ). The perianal excoriation rate in the Swenson group (17.4%) was much lower when compared to the Soave group (26.5%) ( $P=0.005$ ).

According to our experience, the success of transanal pullthrough Swenson group is closely related to some operative details (Fig. 1). (1) The insertion of forceps into the rectum must be as deep as the level of the symphysis pubis. This allows for a correct pull down of the anterior-rectal wall down to the anus. If it is difficult to pull out the anterior-rectal wall, the rectum can be cut off at the level of the peritoneal reflection. Then, the affected colon can be dissected upward and downward. (2) After excision of the rectum, the proximal part of the colon can be closed temporarily and pushed up into the abdominal cavity to make room for the dissection of the distal part of the rectum (3) When dissecting the proximal colon, the mesenteric vessel should be precisely ligated in case the mesenteric vessel retracts into the abdominal cavity. This prevents uncontrollable bleeding. The coagulation hemostasis can be used in the distal colon because petrolatum gauze compression can effectively control postsurgery bleeding. (4) When performing the incision of the rectum the location of the incision should be higher at the anterior wall and lower at the posterior circumference. The anterior rectal wall should be divided 3 to 5 cm lower than the level of peritoneal reflection. The posterior wall should be divided 0.5 to 1.0 cm above the dentate line. This helps to preserve more sensitivity of the bowel wall at the region close to the anus.<sup>[16]</sup> The enlargement of the anastomotic circumference is more convenient for suturing out the anus. (5) If it is difficult to pull out the proximal colon, open operation and laparoscopic assistance should be taken into consideration to make sure the affected colon can be resected adequately.

In some cases, a small abdominal incision or a laparoscopic procedure may be used to assist in the dissection of the colon in pullthrough Swenson procedures for thorough resection of the affected colon. Some researchers believe that laparoscopic dissection should become the routine procedure for pullthrough operations.<sup>[17]</sup> According to our experience, if the pullthrough procedure can be completed transanally, it represents a safer and more economical option especially for infants.<sup>[18,19]</sup> In our clinical practice, most (86.5%) patients underwent complete pullthrough procedure without laparoscopic or abdominal incision assistance. The prognosis of this group of patients was better when compared to the group of children who underwent transabdominal operations.

Previous researchers believe that the pullthrough Swenson procedure is more suitable for infants and young children suffering from the rectosigmoid subtype of HD. Recently, with the accumulation of experience and improvement of technology, it can also be completed in the older children and in HD extending to the descending colon.<sup>[20]</sup> For the older children suffering from massive dilatation of the intestine, the bowel dissection can be very difficult and demanding. This problem cannot be resolved even by using the transabdominal approach. The patience and carefulness of pediatric surgeons are critical to prevent incomplete resection in those children. We successfully performed the pullthrough Swenson approach in 58 cases older than 1 year and the oldest patient was 12 years old. However, we observed 1 total prolapse of the colon. This sign indicates that the mobility of the mesentery rather than the length of affected colon is the deciding factor for a successful pullthrough operation. We recommend to order a preoperative barium contrast enema study to assess the mobility of the mesentery of the colon. If the sigmoid colon appears tortuous, the colon would not be too hard to pull out.

Our study has the typical limitations of retrospective studies, including selection bias due to the preference of operating surgeon, and the relatively small study population that could decrease the statistical power. Next, the outcome and complications may be affected by the experience of surgeons and nursing team. Besides, we recruited our patients in a single center and more multicenter-controlled studies are needed in the future.

## 5. Conclusion

According to our results, although transanal Swenson pullthrough cannot reduce overall hospital stay or improve bowel function compared with the Soave procedure, it is associated with less blood loss, shorter operation time, and lower complication rate.

## References

- [1] So HB, Schwartz DL, Becker JM, et al. Endorectal “pull-through” without preliminary colostomy in neonates with Hirschsprung’s disease. *J Pediatr Surg* 1980;15:470–1.
- [2] Georgeson KE, Fuenfer MM, Hardin WD. Primary laparoscopic pull-through for Hirschsprung’s disease in infants and children. *J Pediatr Surg* 1995;30:1017–21.
- [3] De la Torre-Mondragon L, Ortega-Salgado JA. Transanal endorectal pull-through for Hirschsprung’s disease. *J Pediatr Surg* 1998;33:1283–6.
- [4] Langer JC, Minkes RK, Mazziotti MV, et al. Transanal one-stage Soave procedure for infants with Hirschsprung’s disease. *J Pediatr Surg* 1999;34:148–51.
- [5] Kim AC, Langer JC, Pastor AC, et al. Endorectal pull-through for Hirschsprung’s disease—a multicenter, long-term comparison of results: transanal vs transabdominal approach. *J Pediatr Surg* 2010;45:1213–20.
- [6] Langer JC, Durrant AC, de la Torre L, et al. One-stage transanal Soave pullthrough for Hirschsprung disease: a multicenter experience with 141 children. *Ann Surg* 2003;238:569–83.
- [7] Xu ZL, Zhao Z, Wang L. A new modification of transanal Swenson pull-through procedure for Hirschsprung’s disease. *Chin Med J* 2008;121:2420–3.
- [8] Chen Y, Nah SA, Laksmi NK, et al. Transanal endorectal pull-through versus transabdominal approach for Hirschsprung’s disease: a systematic review and meta-analysis. *J Pediatr Surg* 2013;48:642–51.
- [9] Singh R, Cameron BH, Walton JM, et al. Postoperative Hirschsprung’s enterocolitis after minimally invasive Swenson’s procedure. *J Pediatr Surg* 2007;42:885–9.
- [10] Weidner BC, Waldhausen JH. Swenson revisited: a one-stage, transanal pullthrough procedure for Hirschsprung’s disease. *J Pediatr Surg* 2003;38:1208–11.
- [11] Nasr A, Haricharan RN, Gamarnik J, et al. Transanal pullthrough for Hirschsprung disease: matched case-control comparison of Soave and Swenson techniques. *J Pediatr Surg* 2014;49:774–6.
- [12] De La Torre L, Langer JC. Transanal endorectal pull-through for Hirschsprung disease: technique, controversies, pearls, pitfalls, and an organized approach to the management of postoperative obstructive symptoms. *Semin Pediatr Surg* 2010;19:96–106.
- [13] Rintala RJ, Lindahl H. Is normal bowel function possible after repair of intermediate and high anorectal malformations? *J Pediatr Surg* 1995;30:491–4.
- [14] Weidner BC, Wadhausen JH. A one-stage transanal pull-through procedure for Hirschsprung’s disease. *J Pediatr Surg* 2003;38:1208–11.
- [15] Mousavi SR, Mehdikhah Z, Kavyani A. Fish mouth and parachute surgical technique for Hirschsprung’s disease: our experience in 254 cases with a modified form of Duhamel–Martin procedure. *Dis Colon Rectum* 2008;51:1559–61.
- [16] Gunnarsdottir A, Wester T. Modern treatment of Hirschsprung’s disease. *Scand J Surg* 2011;100:243–9.
- [17] Yamataka A, Kaneyama K, Fujiwara N, et al. Rectal mucosal dissection during transanal pull-through for Hirschsprung disease: the anorectal or the dentate line? *J Pediatr Surg* 2009;44:266–9.
- [18] Dutta HK. Clinical experience with a new modified transanal endorectal pull-through for Hirschsprung’s disease. *Pediatr Surg Int* 2010;26:747–51.
- [19] Gao Y, Li G, Zhang X, et al. Primary transanal rectosigmoidectomy for Hirschsprung’s disease: preliminary results in the initial 33 cases. *J Pediatr Surg* 2001;36:1816–9.
- [20] Mahajan JK, Rathod KK, Bawa M, et al. Transanal Swenson’s operation for rectosigmoid Hirschsprung’s disease. *Afr J Paediatr Surg* 2011;8:301–5.