

Original Article

Two Kampo Medicines, Jidabokuippo and Hachimijiogan Alleviate Sprains, Bruises and Arthritis

Yasuyo Hijikata¹, Yuko Miyamae², Hisako Takatsu³ and Seishiro Sentoh⁴¹Toyodo Hijikata Clinic, ²Miyamae Clinic, ³Umezawa Clinic and ⁴Sentoh Clinic

In traditional Chinese medicine theory (TCM), the affected parts of sprains, bruises and arthritis are considered to be under certain conditions of TCM concept. We administered two Kampo medicines with synergistic effects to promote quick recovery from these conditions. Jidabokuippo (Zhidapuyifang in Chinese), which means ‘decoction for contusions’ is expected to remove these conditions. Hachimijiogan (Baweidi Huangwan in Chinese), which translates as ‘eight-ingredient pill with *Rehmannia*’ is expected to restore presumed minute bone injury and regulates bone metabolism by changing such conditions based on TCM theory. We administered the two prescriptions to 10 patients (age range: 40–85 years; 1 male, 9 females) suffering from bruises, sprains, arthritis and spinal compression fracture without changing their routine intake of other drugs. Patients reported on changes in the pain of affected body parts by using the visual analog scale (VAS) before and after administration of Kampo medicine. In almost all cases, recovery began promptly after administration and the pain disappeared within ~2 weeks. Large doses for a short time brought about much quicker recovery than small doses. Administration of a combination of two Kampo medicines, Jidabokuippo and Hachimijiogan, quickly resolved the pain of bruises, sprains, arthritis and one spinal compression fracture.

Keywords: bruise – Kampo – pain – sprain

Introduction

Many patients suffering from bruises, sprains or arthritis require long periods of convalescence to achieve complete recovery. Daily routines may be disturbed during this period, and elderly patients also become bedridden. A number of Kampo prescriptions and their components have been reported to be effective to alleviate a wide variety of pain caused by different diseases (1–3). We hypothesized that pain in the patients of bruises, sprains and arthritis arises from minute injuries to bone as well as inflammation of bones, muscles and the connections between them. In traditional Chinese medicine (TCM) theory, the affected parts are considered to be under certain conditions of TCM concept.

To treat such conditions, two appropriate Kampo medicines were chosen based on the TCM theory. Jidabokuippo which

translates into English as ‘decoction for contusions’, has been used for hundreds of years in Japan to treat sprains and bruises (4–6). It was prescribed as used by Shaun Kagawa in the Edo era. Simultaneously, Hachimijiogan, which translates into English as ‘eight-ingredient pill with *Rehmannia*’, was administered to restore presumed minute bone injury and regulate bone metabolism (7,8). In addition, Hangeshashinto (Banxi Xiexintang: in Chinese) which is used in gastrointestinal dysfunction and translated as ‘Pinella decoction to drain the epigastrium’ was given to one patient (7).

Subjects and Methods

Subjects

The subjects (one male, nine females) included four with sprains, three with bruises, one with spinal compression fracture and two cases of chronic arthritis. They ranged in age from 40 to 85 years. The average age was 71.9 ± 7.9 years after one much younger patient (40 years old) with chronic

For reprints and all correspondence: Yasuyo Hijikata, Incorporated Toyodo Hijikata Clinic, 3-11-29, Kasuga, Ibaraki, Osaka 567-0031, Japan. Tel: +81-72-627-3756; Fax: +81-72-627-3991; E-mail: hijikata@osb.att.ne.jp

Table 1. Composition of Jidabokuippo

Name of herb	Dry weight (g) per day
<i>Cinnamomi Cassiae Cortex</i>	3.0
<i>Ligustici Chuanxiong Radix</i>	3.0
<i>Glycyrrhizae Uralensis Radix</i>	1.5
<i>Caryophylli Flos</i>	1.0
<i>Rhei Rhizoma</i>	1.0
<i>Nupharis Rhizoma</i>	3.0
<i>Quercus Cortex</i>	3.0

Table 2. Composition of Hachimijiogan

Name of herb	Dry weight (g) per day
<i>Rehmanniae Glutinosa Radix</i>	6.0
<i>Corni Officinalis Fructus</i>	3.0
<i>Dioscoreae Oppositae Radix</i>	3.0
<i>Alismatis Orientalis Rhizoma</i>	3.0
<i>Poriae Cocos Sclerotium</i>	3.0
<i>Moutan Radicis Cortex</i>	2.5
<i>Cinnamomi Cassiae Cortex</i>	1.0
prepared <i>Aconiti Carmichaeli</i>	0.5

ankle arthritis after hormone replenishment for amenorrhea was excluded.

Methods

About 7.5 g day⁻¹ of TJ-89 Jidabokuippo (Tsumura & Co.) and 7.5 g day⁻¹ of either EK-7 (Kanebo Ltd) or TJ-7 (Tsumura & Co.) Hachimijiogan were administered to all. The components of Jidabokuippo (9,10) and Hachimijiogan (9) are shown in Tables 1 and 2. Hachimijiogan alone was given to bruise case 1. In all cases, no changes were made to the patients' routine intake of drugs other than Kampo medicine. Kampo medicines were usually administered between meals or, after meals for patients with digestive trouble. Larger doses of the Kampo medicines were administered to sprain case 4, after obtaining informed consent, to see whether or not recovery would be expedited. In sprain case 4, EK-14 (Kanebo Ltd, Hangeshashinto) (Banxiexintang in Chinese) which protects the stomach, was added to the other Kampo medicines. The composition of Hangeshashinto (7) is shown in Table 3.

All herb mixtures were extracted with boiling water and spray-dried to generate granules by adding dextrose (7.5 g day⁻¹). We evaluated the effectiveness of these Kampo medicines based on each patient's self-assessment of pain using the visual analog scale (VAS) from 0 (no symptoms) to 10 (worst pain).

Results

Bruise

Case 1: (Fig. 1) A Japanese female (MW, 69 years old) fell and bruised her patella which resulted in difficulty walking.

Table 3. Composition of Hangeshashinto

Name of herb	Dry weight (g) per day
<i>Pinelliae Ternatae Rhizoma</i>	5.0
<i>Scutellariae Baicalensis Radix</i>	2.5
<i>Glycyrrhizae Uralensis Radix</i>	2.5
<i>Zizyphi Jujubae Fructus</i>	2.5
<i>Ginseng Radix</i>	2.5
<i>Coptidis Rhizoma</i>	1.0
<i>Zingiberis Officinalis Recens Rhizoma</i>	2.5

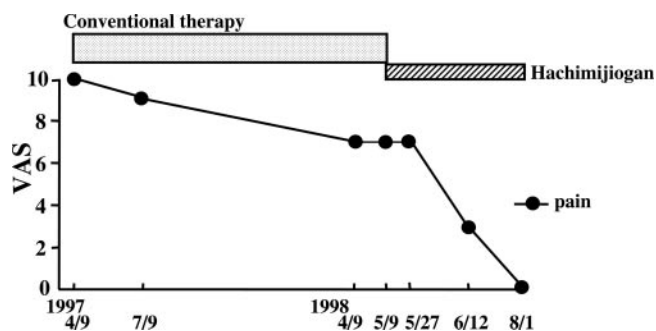


Figure 1. Pain Score (patella) with conventional therapies and Kampo medicine (bruise case 1: 69 years old female).

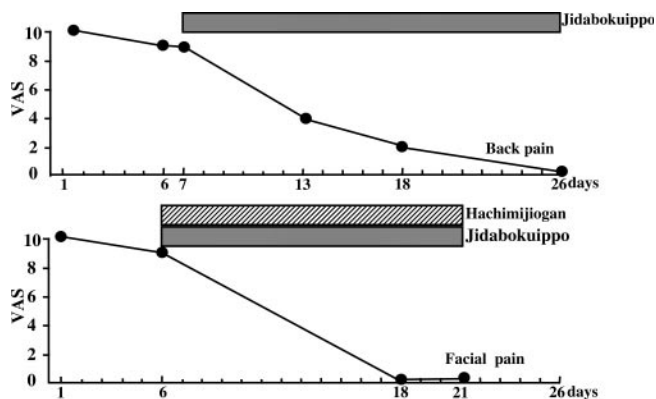


Figure 2. Pain Score (bruise) after administration of Kampo medicines (bruise case 2: up 54, down 58 years old female).

After 3 months of conventional therapies from her family doctor, she was able to walk; however, her pain when walking remained significant (VAS 8–9) for 7 months. Administration of Hachimijiogan reduced her pain slowly but steadily. She reached VAS 7 and 0 at 30 and 80 days, respectively, after the treatment began.

Case 2: (Fig. 2) A Japanese female (YW, 58 years old) with osteoporosis and frequent bruising used cold compresses to decrease her pain from VAS 10 to 9. As the upper figure shows, ~20 days of administration of Jidabokuippo was needed to relieve the pain of the bruises on her hip.

As shown in the lower figure, 4 years later at age 58, when Hachimijiogan was administered along with Jidabokuippo, the pain of a facial bruise resolved after only 12 days.

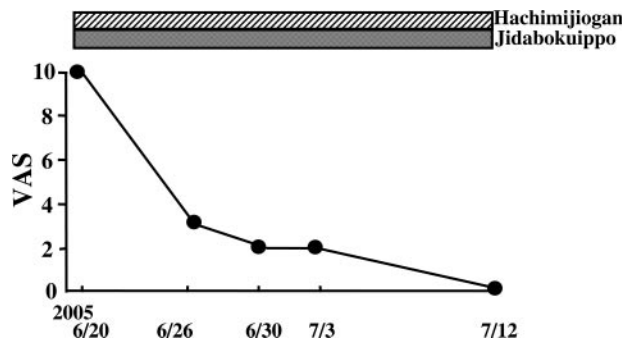


Figure 3. Pain Score after administration of Kampo medicines (bruise case 3: 67 years old female, after traffic accident).

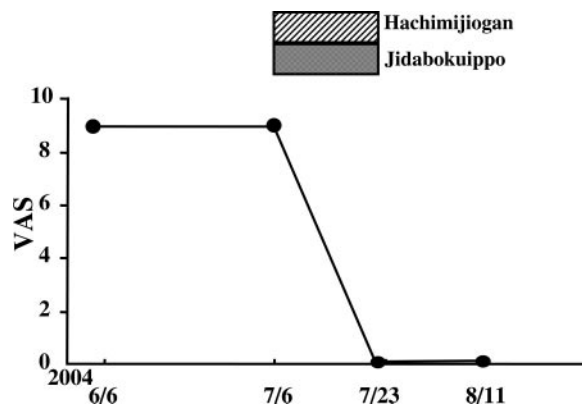


Figure 4. Pain Score (right ankle sprain) after administration of Kampo medicines (sprain case 1: 72 years old female).

Case 3: (Fig. 3) A Japanese female (SY, 67 years old) with mild osteoporosis was in a traffic accident and sustained severe bruising of the left hip without bone fracture. The same day, with a VAS of 10, she began taking two Kampo medicines. Seven days later her VAS was 2. Although her family doctor gave her an analgesic, she did not need to use it. She was completely pain free 28 days after the accident.

Sprain

Case 1: (Fig. 4) A Japanese female (TH, 72 years old) with osteoporosis and rheumatoid arthritis sprained her right ankle and was treated with conventional therapies for 1 month without any improvement in VAS 9. The two Kampo medicines were administered, and she was free from pain after 14 days of treatment.

Case 2: (Fig. 5) A Japanese female (FN, 85 years old) with osteoporosis, back pain and patellar arthritis sprained her right wrist in a fall. Two days after the fall, her pain level was VAS 10. After taking the two Kampo medicines for 8 days, her VAS fell to 3 and then, 6 days after stopping the treatment, to 1. One month after the initiation of treatment, she was pain-free.

Case 3: (Fig. 6) A Japanese male (MO, 77 years old) with osteoporosis and back pain sprained his right ankle while bathing. One day after the injury, his VAS was 9. After

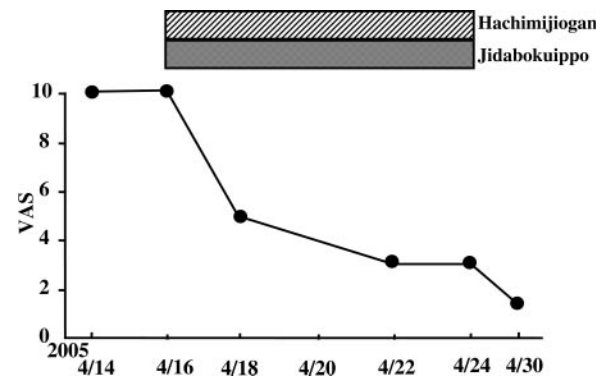


Figure 5. Pain Score (right wrist sprain) after administration of Kampo medicines (sprain case 2: 85 years old female).

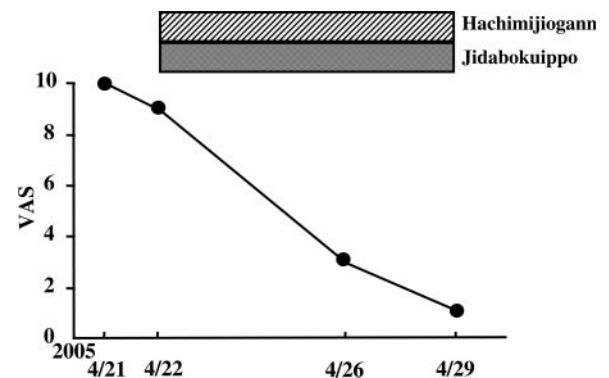


Figure 6. Pain Score (right ankle) after administration of Kampo medicines (sprain case 3: 77 years old male).

administration of the two Kampo medicines for 7 days, his VAS was 1. Fourteen days after the injury, he was pain-free.

Case 4: (Fig. 7) A Japanese female (YH, 68 years old) sprained her right ankle. A compress of Inuzansyo (Quanshanjiao in Chinese) (*Zanthoxylum schinifolium* Sieb. et Zucc.), which is a Japanese folk remedy for bruises was applied to the affected area that day, but she awoke with pain at midnight. The VAS was 10 at 26 h after the trauma. After she took an analgesic suppository, her VAS fell to 9 at 30 h after the trauma. With regular treatment consisting of Inuzansyo compresses, her VAS decreased to 8 at 49 h after the trauma and to 7 at 80 h. When the patient visited the clinic 82 h after the trauma, her VAS remained at 7. Administration of 4.5 g of Hachimijiogan and 5 g of Jidabokuippo was accompanied by 1 g of Hangeshashinto (EK-14, Kanebo Ltd). Two hours after the administration of these therapies (84 h since the trauma), her VAS decreased to 3. She continued taking the same dosages of Kampo medicines and 2 h later (86 h), her VAS fell to 0. Despite a decrease in the intake of the Kampo medicines, as shown in Fig. 7 her VAS remained 0 for 1 week. The patient has remained symptom-free since that time.

Arthritis

Case 1: (Fig. 8) Japanese female (TA, 76 years old) had been suffering from chronic arthritis, for which she had been treated

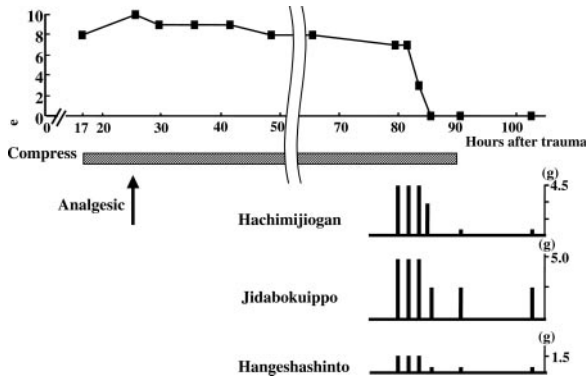


Figure 7. Clinical course of the patient with right ankle sprain (sprain case 4: 68 years old female).

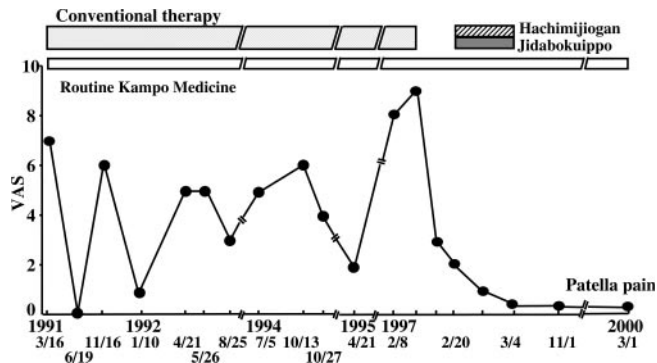


Figure 8. Pain Score (patellar arthritis) after administration of Kampo medicines (arthritis case 1: 76 years old female).

unsuccessfully with conventional therapies for more than 6 years. Her family doctor often told her she should lose weight. He prescribed a lipid-lowering drug. She fell, bruising her patella; however, her pain resolved within 1 week with conventional therapies. She decided to begin Kampo medicine in hope of relieving frequent arthritis flares. She took the two Kampo medicines for 14 days, and her arthritis was successfully controlled for more than 3 years.

Case 2: A Japanese female (40 years old) had difficulty walking due to pain and swelling in her right ankle after hormone replacement therapy for amenorrhea. Two Kampo medicines were administered, and she was pain-free after 14 days of this treatment.

Spinal Compression Fracture

A Japanese female (70 years old) had been suffering from Sjogren's syndrome for which she had received steroid hormones with resultant osteoporosis. She developed back pain caused by a spinal compression fracture. She started to take the two Kampo medicines. Five days later, her back pain had decreased from VAS 10 to 5. One month later, her VAS was 4. She was pain-free after ~2 months of this Kampo treatment (Fig. 9).

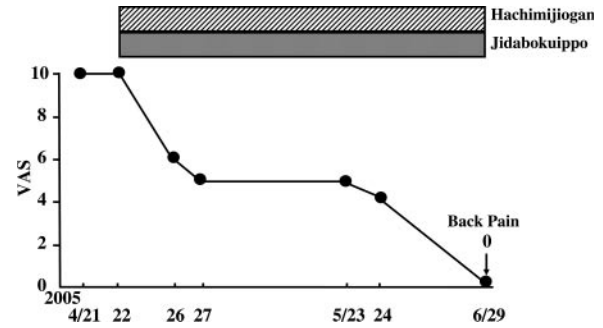


Figure 9. Pain Score after administration of Kampo medicines (spinal compression fracture: 70 years old female).

Discussion

In TCM theory, Jidabokuippo removes certain conditions that occur in the affected areas of sprains or bruises (5). Within this extract, the components *Cinnamomi Cassiae Cortex* (9) and *Caryophylli Flos* (9) promote blood circulation, and *Ligustici Chuanxiong Rhizoma* (9) accelerates blood circulation and dilates blood vessels. Clinical experience in Japan suggests that *Nupharis Rhizoma* (9) stops active bleeding and promotes the reabsorption of internal bleeding. *Rhei Rhizoma* (10) removes the waste produced by resolving hematomas and injured tissue, thus hastening hematoma resolution. *Quercus Cortex* (9) is thought to have detoxification, antiphlogistic and astringent properties, thus helping to stop bleeding. *Glycyrrhizae Uralensis Radix* (9) regulates other herbs, facilitating their successful action. Thus, this prescription exerts antiphlogistic actions (5).

All herbs in the two Kampo medicines work synergistically to improve certain conditions in TCM theory, including bone metabolism (5). In bruise case 1, the patient had been suffering for more than a year from patellar pain while walking, despite receiving conventional therapy. After taking Hachimijiogan for 84 days, she was pain-free, suggesting that this complex hastened the disappearance of pain. In bruise case 2 (Fig. 2), the patient usually took about a month to recover completely from bruise pain (data not shown). Jidabokuippo, however, hastened recovery. As shown in the lower part of Fig. 2, pain disappeared even faster when Hachimijiogan was added to her treatment. This suggests that these two Kampo medicines work synergistically.

In sprain cases 1, 2 and 3 and in bruise case 3, pain began to decrease as soon as the two Kampo medicines were administered and the pain was almost completely resolved within 2 weeks. This also implies a synergy between these drugs. As shown in sprain case 4, administration of large doses of Kampo medicines for a short period of time provided prompt recovery from the pain of sprains. High doses for a short time may be preferable for acute injury treatment.

The patient with the spinal compression fracture case (Fig. 9) took 2 months to obtain complete pain relief with the two Kampo medicines; however, it is notable that pain improved despite concomitant administration of

steroid hormone. Though data are not shown, the pain of the avulsion fracture of a 19 years old boy started to decrease immediately after taking Jidabokuippo. This suggests that Kampo medicine may be effective for pain relief even from bone fractures.

As shown in the arthritis case 1, conventional treatment of chronic arthritis did not lead to complete recovery. In addition, too much walking led to frequent aggravation of the condition. The administration of Kampo medicines led to stable improvement of the chronic arthritis. This improvement lasted more than 3 years. These results imply that the two Kampo medicines work for chronic arthritis (Fig. 8). Finally, these two Kampo medicines even worked to treat ankle arthritis that was a side effect of hormone therapy.

Hachimijogan heals presumed minute bone injury. Quick recovery, facilitated by the administration of these two drugs is based on the synergistic effects.

Consideration should be given to administering these two Kampo medicines to aged patients suffering from sprains, bruises and arthritis.

References

1. Kobayashi H, Takahashi K, Mizuno N, Kutsuna H, Ishii M. An Alternative approach to atopic dermatitis: Part II-Summary of cases and discussion. *Evid Based Complement Alternat Med* 2004;1:145-55.
2. Qin B, Magasaki M, Ren M, Bafotto G, Oshida Y, Sato Y. Gosha-jinkigan (a herbal complex) corrects abnormal insulin signaling. *Evid Based Complement Alternat Med* 2004;1:269-76.
3. Hijikata Y. Analgesic treatment with Kampo prescription. *Expert Rev Neurotherapeutics* 2006;6:795-802.
4. Kagawa S. *Ippondoijisetuyaku* 1808 (in Japanese).
5. Kobe Chuigaku Kenkyukai. *Clinical Research of Chinese Traditional Medicine-Prescription*. Tokyo: Ishiyaku Publishers Inc., 1992, 277-9, 365 (in Japanese).
6. Yasui H. Appendix-Composition and indications of 148 prescriptions. *J Kampo Acupunct Integr Med* (Special Edition) 2005, 91.
7. Bensky D, Barolet R. *Chinese Herbal Medicine Formulas & Strategies*. Seattle: Eastland Press, 1990, 150-2, 265.
8. Tierra M, Tierra L. *Chinese Traditional Herbal Medicine Vol. 1. Diagnosis and Treatment*. Twin Lakes, WI: Lotus Press, 1998, 153-8.
9. Bensky D, Gamble A. *Chinese Herbal Medicine Materia Medica*. Revised Edition. Seattle: Eastland Press, 1992, 68-71, 115-7, 131-2, 145-6, 266, 297-303, 305-6, 320-1, 323-5, 375-6.
10. Namba T. *The Encyclopedia of Wakan-Yaku (Traditional Sino-Japanese Medicines)*. Osaka: Hoikusya, 1994, 38, 160 (in Japanese).

Received October 4, 2006; accepted November 20, 2006