

Venous Thromboembolism Following Dantrolene Treatment for Neuroleptic Malignant Syndrome

Po-Hao Chen¹, Hsien-Yuan Lane^{2,3}, Chieh-Hsin Lin^{1,2}

¹Department of Psychiatry, Kaohsiung Chang Gung Memorial Hospital, Chang Gung University College of Medicine, Kaohsiung, ²Institute of Clinical Medical Science and ³Department of Psychiatry, China Medical University Hospital, Taichung, Taiwan

Neuroleptic malignant syndrome (NMS) is one of the most severe iatrogenic emergencies in clinical service. The symptoms including sudden consciousness change, critical temperature elevation and electrolytes imbalance followed by multi-organ system failure were common in NMS. In addition to aggressive interventions with intravenous fluid resuscitation and antipyretics, several antidotes have been suggested to prevent further progression of the muscle damage. Dantrolene has been reported to be one of the most effective treatments for NMS. However, the adverse effects of dantrolene treatment for NMS have not yet been evaluated thoroughly. Here we report a young male patient with bipolar I disorder who developed NMS after rapid tranquilization with haloperidol. Dantrolene was given intravenously for the treatment of NMS. However, fever accompanied with local tenderness, hardness with clear border and swelling with heat over the patient's left forearm occurred on the sixth day of dantrolene treatment. Venous thromboembolism (VTE) over intravenous indwelling site at the patient's forearm was noted and confirmed by Doppler ultrasound. The patient's VTE recovered after heparin and warfarin thrombolytic therapy. To our knowledge, this is the first case report demonstrating the possible relationship between dantrolene use and VTE in a patient with antipsychotic treatment. Although the causal relationship and the underlying pathogenesis require further studies, dantrolene should be used with caution for patients with NMS.

KEY WORDS: Venous thromboembolism; Dantrolene; Neuroleptic malignant syndrome.

INTRODUCTION

Neuroleptic malignant syndrome (NMS) is a life threatening complication of antipsychotic treatment. Dantrolene is one of the treatments for NMS.¹⁾ Here we reported a case whose NMS was successfully treated with dantrolene. The patient later experienced venous thromboembolism (VTE). This is the first report of VTE after dantrolene treatment in a patient with antipsychotic treatment.

CASE

The 18 year-old male was hospitalized due to irritable mood and poor impulse control for 2 weeks. He also had inflated self-esteem, decreased need for sleep, distractibility, disorganized behavior and psychomotor agitation.

Bipolar I disorder, manic episode, was diagnosed according to the Diagnostic and Statistical Manual of Mental Disorders 5th edition and valproic acid 1,000 mg combined with sulpiride 600 mg daily were given. The patient had physical threatening toward ward staff and destructive behavior to objects. Rapid tranquilization with haloperidol was applied. Totally 45 mg of haloperidol was given in 4 days. NMS with high fever, muscular rigidity, elevated blood pressure and tachycardia accompanied with drowsiness was noted 3 days after rapid tranquilization. The fever lasted for 2 days, with the highest core temperature up to 40.7°C even under regular (every 6 hours) antipyretic treatment. Laboratory tests showed leukocytosis, elevated creatinine phosphokinase (3,428 µg/L), elevated myoglobin level (717.6 ng/ml) and elevated aminotransferase level. All psychotropics were discontinued immediately. Hydration and dantrolene 100 mg every 12 hours were given intravenously (the patient's body weight was 90 kg) according to the instruction of the medicine (initially, ≥ 1 mg/kg via rapid intravenous [IV] injection, may repeat if necessary, up to a total dose of 10 mg/kg). The patient's NMS subsided after a total of 640 mg of dan-

Received: December 14, 2015 / **Revised:** February 22, 2016

Accepted: February 23, 2016

Address for correspondence: Chieh-Hsin Lin, MD, PhD

Department of Psychiatry, Kaohsiung Chang Gung Memorial Hospital, No. 123, Da-Pi Road, Niao-Sung District, Kaohsiung 803, Taiwan
Tel: +886-7-7317123, Fax: +886-7-7318762
E-mail: cyndi36@gmail.com

© This is an Open-Access article distributed under the terms of the Creative Commons Attribution Non-Commercial License (<http://creativecommons.org/licenses/by-nc/4.0>) which permits unrestricted non-commercial use, distribution, and reproduction in any medium, provided the original work is properly cited.

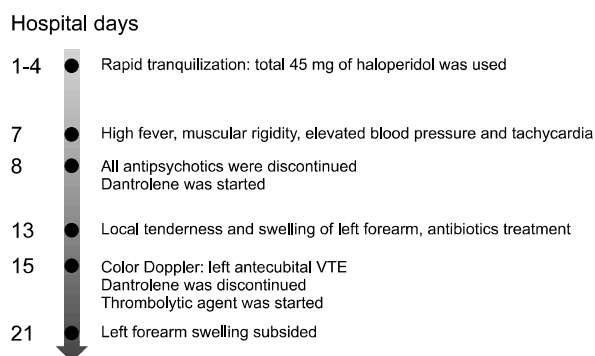


Fig. 1. The progression of symptoms of the patient.

trolene treatment in 5 days. His consciousness fully recovered and the creatinine phosphokinase declined to 183 $\mu\text{g/L}$.

On the next day after dantrolene treatment, local tenderness and swelling with heat appeared over the patient's left forearm where the IV line was indwelt. The d-dimer level was 1.7 mg/L. Under the impression of cellulitis, cefadroxil monohydrate 1 g per day was given. The antibiotics were shifted to IV form cefazoline 1 g every 8 hours, then to teicoplanin 400 mg every 12 hours. However, the lesion extended to the upper arm. The d-dimer level rose to 3.45 mg/L. Color Doppler ultrasound showed left antecubital VTE. Dantrolene was discontinued and thrombolytic treatment by IV heparin was given. Heparin was shifted to warfarin 2 days later. The swelling and tenderness faded after 6 days of thrombolytic treatment. Follow-up Doppler ultrasound 4 weeks later showed improvement of forearm VTE. The clinical course of the patient is shown in Fig. 1. The patient was discharged one month later with quetiapine and valproate therapy.

DISCUSSION

The incidence of venous thrombosis was higher in schizophrenia patients than in general population.²⁾ Risks factors include immobilization,³⁾ prolonged physical restraint⁴⁾ and antipsychotic use.⁵⁾ NMS *per se* is a risk factor for thromboembolism⁶⁾ because fever may induce hemoconcentration and rhabdomyolysis may worsen the hypercoagulation. It is proven that dantrolene, bromocriptine and amantadine alone reduce mortality rate caused by NMS, from 21 percent in conservative treatment group to 8.6%, 7.8%, 5.9% respectively.⁷⁾ Dantrolene depresses the excitation-contraction coupling in skeletal muscle by binding to the ryanodine receptor and decreasing free intracellular calcium concentration which modify muscle ri-

gidity and reverse heat generation from muscle.^{1,8)} However, it is possible that dantrolene causes muscle weakness thereby inducing thrombogenesis although this has not yet been verified. Brandom *et al.* reported a 9% incidence of phlebitis associated with dantrolene use.⁹⁾ This complication is relatively high and should be anticipated in any patient who receives dantrolene. Grodofsky *et al.*¹⁰⁾ also reported a case of upper extremity VTE after dantrolene treatment for malignant hyperthermia.

This patient was not immobilized for long time during the hospitalization. He did not have dyslipidemia or hyperglycemia. The possibility of antipsychotics-induced VTE was low due to brief use of antipsychotics (10 days). The patient's VTE was most likely to be caused by dantrolene for the following reasons. First, the lesion extended from the IV-catheter site over the ulnar vein. Second, VTE over upper extremities was extremely rare. Third, the symptoms of the VTE started after dantrolene use and improved after the discontinuation of dantrolene. Despite the aforementioned reasons, the causal relationship and pathogenesis between dantrolene and VTE needs to be confirmed by further studies.

Although dantrolene relieves NMS symptoms, the complications including phlebitis and venous thrombosis limit its clinical application. Furthermore, this patient developed VTE after receiving dantrolene with the dosage lower than recommended by Malignant Hyperthermia Association of the United States (2.5 mg/kg, <http://www.mhaus.org>). Oral administration of dantrolene may be less risky in causing venous complications; however, patients with unclear consciousness or who are uncooperative still need IV dantrolene treatment. Future research is needed to describe different rates of phlebitis in patients who received different formulations of dantrolene. Further study may also focus on reducing dantrolene-induced side-effect by establishing standard protocol and developing better treatment for NMS.

REFERENCES

- Perry PJ, Wilborn CA. *Serotonin syndrome vs neuroleptic malignant syndrome: a contrast of causes, diagnoses, and management.* *Ann Clin Psychiatry* 2012;24:155-162.
- Thomassen R, Vandenbroucke JP, Rosendaal FR. *Antipsychotic medication and venous thrombosis.* *Br J Psychiatry* 2001;179:63-66.
- Beam DM, Courtney DM, Kabrhel C, Moore CL, Richman PB, Kline JA. *Risk of thromboembolism varies, depending on category of immobility in outpatients.* *Ann Emerg Med* 2009; 54:147-152.
- Ishida T, Katagiri T, Uchida H, Takeuchi H, Sakurai H, Watanabe K, et al. *Incidence of deep vein thrombosis in restrained psychiatric patients.* *Psychosomatics* 2014;55:69-

- 75.
5. Hägg S, Jönsson AK, Spigset O. *Risk of venous thromboembolism due to antipsychotic drug therapy. Expert Opin Drug Saf* 2009;8:537-547.
 6. Mathew JC, Pillai U, Lacasse A. *Extensive deep venous thrombosis in a patient with neurolept malignant syndrome despite being on prophylaxis. Case Rep Psychiatry* 2011; 2011:258172.
 7. Sakkas P, Davis JM, Janicak PG, Wang ZY. *Drug treatment of the neuroleptic malignant syndrome. Psychopharmacol Bull* 1991;27:381-384.
 8. Krause T, Gerbershagen MU, Fiege M, Weisshorn R, Wappler F. *Dantrolene--a review of its pharmacology, therapeutic use and new developments. Anaesthesia* 2004; 59:364-373.
 9. Brandom BW, Larach MG, Chen MS, Young MC. *Complications associated with the administration of dantrolene 1987 to 2006: a report from the North American Malignant Hyperthermia Registry of the Malignant Hyperthermia Association of the United States. Anesth Analg* 2011;112: 1115-1123.
 10. Grodofsky S, Levitt C, Schlichter RA, Stanton DC, Liu R, Chen L. *Upper extremity deep vein thrombosis in a patient treated for malignant hyperthermia. J Clin Anesth* 2013; 25:350-352.