

Radiofrequency ablation of osteoid osteoma in common and technically challenging locations in pediatric population

Shaileshkumar Garge, Shyamkumar N Keshava, Vinu Moses, George K Chiramel, Munawwar Ahmed, Suraj Mammen, Vrisha Madhuri¹

Departments of Radiology and ¹Paediatric Orthopedics, Christian Medical College, Vellore, Tamil Nadu, India

Correspondence: Dr. Shaileshkumar Garge, Department of Radiology, Christian Medical College, Vellore - 632 004, Tamil Nadu, India.
E-mail: drshaileshgarge@gmail.com

Abstract

Context: Percutaneous radiofrequency ablation (RFA) of osteoid osteoma has a high technical and clinical success rate. However, there is limited data on its use in the pediatric population, especially in technically challenging locations. **Objective:** To assess the safety and efficacy of computed tomography (CT)-guided percutaneous RFA of osteoid osteoma in pediatric population. **Patients and Methods:** From June 2009 to May 2014, 30 patients with osteoid osteoma were treated with CT-guided RFA in common (25 cases) and technically challenging (five cases: four near articular surface and one in sacrum) locations. Therapy was performed under general anesthesia with a three-array expandable RF probe for 6 min at 90°C and power of 60–100 W. The patients were discharged next day under instruction. The treatment success was evaluated in terms of pain relief before and after (1 day, 1 month, and 6 months) treatment. **Results:** Technical success was achieved in all patients (100%). Primary clinical success was 96.66% (29 of total 30 patients), despite the pediatric population and atypical location. One patient had persistent pain after 1 month and was treated successfully with a second procedure (secondary success rate was 100%). One patient had immediate complication of weakness of right hand and fingers extension. No delayed complications were observed. **Conclusions:** CT-guided RFA is relatively safe and highly effective for treatment of osteoid osteoma in pediatric population, even in technically difficult locations.

Key words: Computed tomography guided; osteoid osteoma; pediatric population; radiofrequency ablation

Introduction

Osteoid osteoma is a benign bone tumor consisting of an osteoid nidus in a highly vascular connective tissue stroma. These tumors are exquisitely painful, and demonstrate characteristic findings on clinical and radiographic examinations.^[1,2] The traditional

treatment of osteoid osteoma consists of surgical en bloc excision.^[2-4] The major drawback of this traditional approach is prolonged surgery and hospital stay, weakening of the bone requiring a prophylactic fixation, and its subsequent removal and additional time off school due to open surgery. To overcome this drawback, different

This is an open access article distributed under the terms of the Creative Commons Attribution-NonCommercial-ShareAlike 3.0 License, which allows others to remix, tweak, and build upon the work non-commercially, as long as the author is credited and the new creations are licensed under the identical terms.

For reprints contact: reprints@medknow.com

Cite this article as: Garge S, Keshava SN, Moses V, Chiramel GK, Ahmed M, Mammen S, et al. Radiofrequency ablation of osteoid osteoma in common and technically challenging locations in pediatric population. *Indian J Radiol Imaging* 2017;27:88-91.

Access this article online

Quick Response Code:



Website:
www.ijri.org

DOI:
10.4103/0971-3026.202955

minimally invasive techniques have been described as alternative therapeutic options (radiofrequency ablation, laser photocoagulation, and percutaneous resection).^[3-7] Computed tomography (CT) guidance has become a very useful and easy method for the percutaneous treatment of these lesions.^[8] We started using CT guided radiofrequency ablation for osteoid osteoma 5 years ago and immediately noted many beneficial effects in terms of duration of hospital stay, morbidity, and overall patient comfort prompting us to do this study. We report our experience with CT-guided percutaneous radiofrequency ablation (RFA) of osteoid osteoma in common and technically challenging locations in 30 pediatric patients and evaluate technical and clinical results.

Patients and Methods

This is a retrospective observational study of 30 pediatric and adolescent patients who underwent CT-guided percutaneous RFA of osteoid osteoma between June 2009 to May 2014. All patients reported severe pain that usually increased at night and required nonsteroidal anti-inflammatory drugs for pain relief. The osteoid osteoma was diagnosed from clinical and imaging findings (radiography, CT, and/or magnetic resonance imaging (MRI) scan), demonstrating a nidus and other findings that are typical of osteoid osteoma. Patients and their legal guardians were fully informed of the procedure as well as of the surgical and medical alternatives, and informed consent was obtained.

All procedures were performed under general anesthesia in the CT room on six slice CT scanner (Philips Brilliance, Massachusetts, USA). Grounding pads were placed. Under aseptic precautions, a guidewire (K-wire) was drilled into the center of the nidus using either a hand drill (Aesculap Inc. B Braun, Center Valley, PA) or a battery operated drill (stryker Corp., Kalamazoo, MI) with a cannulated drill bit (2.5–4.5 mm) (Zimmer, Warsaw, IN) along the planned tract by the pediatric orthopedist; keeping the cannulated drill bit in nidus of osteoid osteoma, K-wire was exchanged for the stiff end of the amplatz wire; a 5F sheath which was cut near hub and a linear cut along its entire length was made to allow it to expand and peel off when RFA probe was inserted through; subsequently, a 4 mm cannulated bone drill was exchanged for a 5F sheath over an Amplatz wire. This is an important step for safe insertion of RFA probe. RFA needle [RITA SDE StarBurst Probe (17 gauge 2 cm diameter, 12 cm long, three tines) Angiodynamics, Inc., GA, USA] was inserted into the nidus of osteoid osteoma through the sheath. Sheath was withdrawn approximately 2 cm back, and the tines were opened and confirmed to be within the lesion with check CT sections. Using the radiofrequency waves from RF generator (Model 1500X; Angiodynamics, Inc., GA, USA), the tines were heated to a target temperature

of 90°C and power of 60–100 W and the peak temperature was maintained for 6 min. After 6 min, the tines were withdrawn into the probe and then the RF probe was removed. Next day, the patient was clinically evaluated for type and severity of pain.

The treatment success was evaluated in terms of pain relief before and after procedure (1 day, 1 month, and 3 months). Patients were also contacted by telephone at 6 months for follow-up regarding complications or recurrence of pain. Technical success was defined as the ability to localize the radiolucent nidus and placement of an electrode under CT guidance with ablation performed for the desired period. Clinical success was defined as complete relief of pain without the use of oral pain medication within 1 month of the procedure.

Results

From June 2009 to May 2014, 30 pediatric patients underwent CT-guided RFA of osteoid osteoma. There were 25 boys and 5 girls, with a male-to-female ratio of 5:1. Their age ranged between 4 years to 20 years with a mean age of 13.16 years. Lesions were grouped into common and challenging location. Among the common location ($n = 25$), lesions were located in the femur ($n = 21$) [Figure 1] and tibia ($n = 4$). Among the challenging locations ($n = 5$), four were near articular surface (one each at glenoid fossa of right scapula, head of right radius, talocalcaneal joint of right calcaneum [Figure 2] and left femoral head) and one was in the left sacrum.

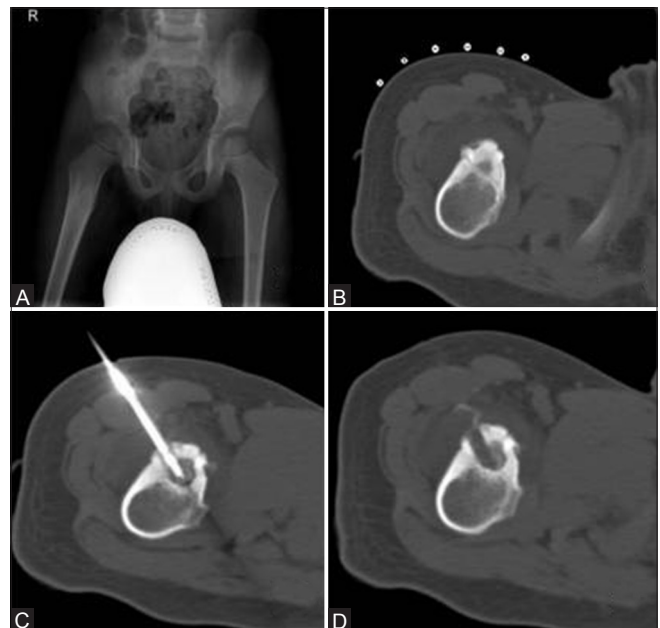


Figure 1 (A-D): An 11-year-old boy with a right proximal femur osteoid osteoma. Radiography (A) and CT scan bone window axial image (B) show a radiolucent nidus and surrounding reactive sclerosis. (C) CT scan shows RFA probe *in situ* in nidus. (D) CT scan post procedure shows RF ablation tract

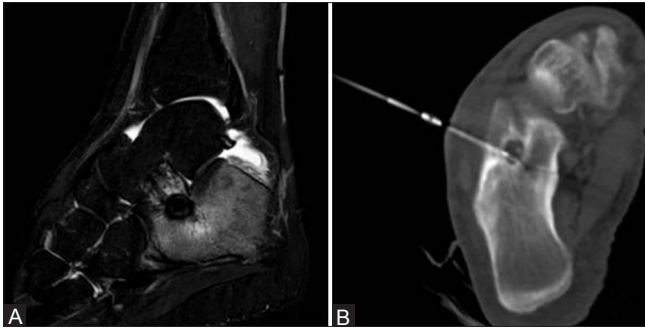


Figure 2 (A and B): A 17-year-old boy with a right calcaneal osteoid osteoma near the talocalcaneal joint margin. (A) Magnetic resonance imaging (STIR) sagittal image shows central nidus surrounded by hypointense reactive sclerosis. Rest of the surrounding calcaneum appear hyperintense due to reactive edema due to osteoid osteoma. (B) CT scan shows RFA probe *in situ* in nidus

Technical success was achieved in all patients (100%). The number of ablations per treatment session was one. The time of ablation was 6 min for each setting. The duration of the procedures ranged from 60 to 150 min. Primary clinical success was 96.66% (29 of total 30 patients), despite pediatric population and challenging location. One patient with an osteoid osteoma in the shaft of right femur had persistent pain after 1 month and was treated successfully with a second procedure (secondary success rate 100%). One patient from the challenging location group with osteoid osteoma at right radial head had immediate post-procedure weakness of wrist and finger extension because the lesion was very close to posterior interosseous nerve, which slowly recovered with physiotherapy. No delayed complications were observed.

Discussion

Since the promising results of Rosenthal *et al.*,^[9] in the management of osteoid osteoma with RFA, a large number of studies evaluating RFA of osteoid osteoma have been reported in the literature. Most of these studies found very high technical success rates (100%) and good primary success rates with a single session of ablation ranging from 76% to 100%.^[10-17] The secondary success rate after repeated ablations ranged from 87% to 100%. Hence, this minimally invasive technique has become the method of choice for treatment of osteoid osteomas, provided that the diagnosis is based on a typical clinical, scintigraphy, and CT presentation.^[18] To our knowledge, there are few reports in the literature regarding the role of percutaneous RFA in treating osteoid osteomas in children at atypical locations.

Our study of RFA of osteoid osteoma included 30 pediatric patients. Our technical success rate was 100%, which is similar to most of the other studies (100%). In our study in the pediatric population, the primary and secondary clinical success ratings were 96.66% and 100%, respectively,

which are comparable to success rates in most other studies among adults, where primary success and secondary success ranged from 76% to 100% and 87% to 100%, respectively.^[10-17] In a study done by Donkol *et al.*^[19] on the efficacy of RFA of osteoid osteoma in children showed that the technical success, primary clinical success, and secondary clinical success rates were 91.3%, 78.2%, and 82.6% respectively. Donkol *et al.*^[19] and Vanderschueren *et al.*,^[20] in their studies, showed that lower age can be a risk factor for lower clinical success rate. This can be explained by the greater technical difficulty during ablation of osteoid osteoma in children due to the small body mass, difficulty in positioning and fixation of the needle, and shorter ablation time (range: 2–6 min in their study) for each procedure. Our study showed that if technical success is 100% and if strict desired temperature (90°C) can be maintained for desired time (6 min) using controlled power (wattage) delivery (60–100 W) then high clinical success can be achieved even in pediatric population similar to adult population.

In our study, transient radial nerve palsy was the only complication. This happened in a child with radial head (technically challenging position) osteoid osteoma who had developed an immediate post procedure weakness of wrist and finger extension as the lesion was very close to posterior interosseous nerve. This slowly recovered with physiotherapy. There are few case reports of likely articular cartilage damage in weight bearing joints such as acetabulum following CT-guided percutaneous RFA of juxta-articular osteoid osteoma, however, it was not confirmed whether the articular cartilage was damaged only by head due to RFA or if it had also been weakened before by the osteoid osteoma.^[21] Another study by Papagelopoulos *et al.*^[22] on RFA of intra-articular osteoid osteoma of the hip showed that there is good ossification and bone regeneration following RFA and that it is a safe and effective treatment even for intra-articular lesions. No delayed complications were observed in our study.

In comparison to percutaneous CT-guided curettage of osteoid osteoma, during RFA there is lack of confirmation of histological diagnosis. However, there are other disadvantages of curettage technique that it is little more traumatic with complications of neuropraxia, skin abrasions, damage to blood vessels especially in femur leading to avascular necrosis, and frequently incomplete curettage.^[23] We suggest that when the clinical and radiological features are not typical, the technique should be supplemented with a core biopsy from the nidus area. This is specially indicated when the differential diagnosis is infection as management will be required.

Limitations of our study are that it is an observational study, lack of confirmation of histological diagnosis, and lack of imaging follow-up.

Conclusion

Percutaneous CT-guided RF ablation is a relatively safe, highly effective, and minimally invasive procedure for the treatment of osteoid osteoma in pediatric population despite atypical location.

Financial support and sponsorship

Nil.

Conflicts of interest

There are no conflicts of interest.

References

- Kransdorf MJ, Stull MA, Gilkey FW, Moser RP Jr. Osteoid osteoma. *Radiographics* 1991;11:671-96.
- Sans N, Galy-Fourcade D, Assoun J, Jarlaud T, Chiavassa H, Bonneville P, *et al.* Osteoid osteoma: CT-guided percutaneous resection and follow-up in 38 patients. *Radiology* 1999;212:687-92.
- Voto SJ, Cook AJ, Weiner DS, Ewing JW, Arrington LE. Treatment of osteoid osteoma by computed tomography-guided excision in the pediatric patient. *J Pediatr Orthop* 1990;10:510-3.
- Torriani M, Rosenthal D. Percutaneous radiofrequency treatment of osteoid osteoma. *Pediatr Radiol* 2002;32:615-8.
- Gangi A, Dietemann JL, Gasser B, Mortazavi R, Brunner P, Mourou MY, *et al.* Interstitial laser photocoagulation of osteoid osteomas with use of CT guidance. *Radiology* 1997;203:843-8.
- Woertler K, Vestring T, Boettner F, Winkelmann W, Heindel W, Lindner N. Osteoid osteoma: CT-guided percutaneous radiofrequency ablation and follow-up in 47 patients. *J Vasc Interv Radiol* 2001;12:717-22.
- Towbin R, Kaye R, Meza MP, Pollock AN, Yaw K, Moreland M. Osteoid osteoma: Percutaneous excision using a CT-guided coaxial technique. *AJR* 1995;164:945-9.
- Assoun J, Railhac J, Bonneville P, Poey C, Salles de Gauzy J, Baunin C, *et al.* Osteoid osteoma: Percutaneous resection with CT-guidance. *Radiology* 1993;188:541-7.
- Rosenthal D, Alexander A, Rosenberg AE, Springfield D. Ablation of osteoid osteomas with a percutaneously placed electrode: A new procedure. *Radiology* 1992;183:29-33.
- Rosenthal DI, Hornicek FJ, Torriani M, Gebhardt MC, Mankin HJ. Osteoid osteoma: Percutaneous treatment with radiofrequency energy. *Radiology* 2003;229:171-5.
- Rimondi E, Bianchi G, Malaguti MC, Ciminari R, Del Baldo A, Mercuri M, *et al.* Radiofrequency thermoablation of primary non-spinal osteoid osteoma: Optimization of the procedure. *Eur Radiol* 2005;15:1393-9.
- Vanderschueren GM, Taminiau AH, Obermann WR, Bloem JL. Osteoid osteoma: Clinical results with thermocoagulation. *Radiology* 2002;224:82-6.
- Lindner NJ, Ozaki T, Roedel R, Gosheger G, Winkelmann W, Wörtler K. Percutaneous radiofrequency ablation in osteoid osteoma. *J Bone Joint Surg Br* 2001;83:391-6.
- Gebauer B, Tunn PU, Gaffke G, Melcher I, Felix R, Stroszczyński C. Osteoid osteoma: Experience with laser- and radiofrequency-induced ablation. *Cardiovasc Intervent Radiol* 2006;29:210-5.
- Kjar RA, Powell GJ, Schlicht SM, Smith PJ, Slavin J, Choong PF. Percutaneous radiofrequency ablation for osteoid osteoma: Experience with a new treatment. *Med J Aust* 2006;184:563-5.
- Martel J, Bueno A, Ortiz E. Percutaneous radiofrequency treatment of osteoid osteoma using cool-tip electrodes. *Eur J Radiol* 2005;56:403-8.
- Mastrantuono D, Martorano D, Verna V, Mancini A, Faletti C. Osteoid osteoma: Our experience using radio-frequency (RF) treatment. *Radiol Med* 2005;109:220-8.
- Ismat G. The management of osteoid osteoma: Updates and controversies. *Curr Opin Pediatr* 2006;18:36-41.
- Donkol RH, Al-Nammi A, Moghazi K. Efficacy of percutaneous radiofrequency ablation of osteoid osteoma in children. *Pediatr Radiol* 2008;38:180-5.
- Vanderschueren GM, Taminiau AH, Obermann WR. Osteoid osteoma: Factors for increased risk of unsuccessful thermal coagulation. *Radiology* 2004;233:757-62.
- Bosschaert PP, Deprez FC. Acetabular osteoid osteoma treated by percutaneous radiofrequency ablation: Delayed articular cartilage damage. *JBR-BTR Organe Société R Belge Radiol SRBR Orgaan Van K Belg Ver Voor Radiol KBVR*. 2010;93:204-6.
- Papagelopoulos PJ, Mavrogenis AF, Kyriakopoulos CK, Benetos IS, Kelekis NL, Andreou J, *et al.* Radiofrequency ablation of intra-articular osteoid osteoma of the hip. *J Int Med Res*. 2006;34:537-44.
- Fenichel I, Garniack A, Morag B, Palti R, Salai M. Percutaneous CT-guided curettage of osteoid osteoma with histological confirmation: A retrospective study and review of the literature. *Int Orthop* 2006;30:139-42.