



Case report

Pharyngeal abscess complicated by Lemierre's syndrome: Identification of an atypical germ



Solène Barguil^{a,*}, Audrey Sousa Alves^a, Jacques-Robert Christen^a, Cécile De Jerphanion^a, Joris Valero^a, Tiphaine Gaillard^{b,c}, Ludovic Karkowski^a

^aHôpital d'Instruction des Armées Desgenettes, Lyon, France

^bLaboratoire de Biologie Médicale, HIA Desgenettes, Lyon, France

^cLaboratoire de Biologie Médicale, CH Croix-Rousse, Lyon, France

ARTICLE INFO

Article history:

Received 29 November 2020

Received in revised form 7 January 2021

Accepted 9 June 2021

Keywords:

Lemierre's syndrome

Gardnerella vaginalis

Extragenital localization

Pharyngeal abscess

Sexually transmitted infection

ABSTRACT

Introduction: Lemierre's syndrome is a rare but serious complication of an oral infection mostly related to *Fusobacterium necrophorum*. This condition combines jugular vein thrombosis and septic emboli to the lungs or other organs.

Case presentation: We report here an original case of a pharyngeal abscess complicated by Lemierre's syndrome in a young healthy male patient. Samples taken from the pus of the pharyngeal abscess showed the presence of *Gardnerella vaginalis* associated with *Fusobacterium necrophorum*. The patient was treated by draining the abscess, antibiotic therapy and preventive anticoagulation for 1 month. The evolution was good with a resolution of the thrombosis.

Conclusions: This case highlights the need for bacterial identification to adapt antibiotic therapy in Lemierre's syndrome. It also shows the possibility of extragenital localization of *Gardnerella vaginalis* in a male patient having oral sex with women. In contrast to sexually transmitted infections such as syphilis and pharyngeal gonococcus, this oral localization of *Gardnerella vaginalis* has not been described previously in the literature.

© 2021 Published by Elsevier Ltd. This is an open access article under the CC BY-NC-ND license (<http://creativecommons.org/licenses/by-nc-nd/4.0/>).

Introduction

Cases of Lemierre's syndrome are rare. While angina due to *Neisseria gonorrhoeae* and *Treponema pallidum* are uncommon, angina with *Gardnerella vaginalis* has never been described.

We report here a typical case of Lemierre's syndrome concerning a young immunocompetent patient with a tonsil abscess from which we have isolated *Gardnerella vaginalis* and *Fusobacterium necrophorum*.

Case presentation

A 27-year-old man consulted his doctor for odynophagia and a fever that have been evolving for 24 h. He didn't report any particular history and has not taken any non-steroidal anti-inflammatory drugs.

The initial clinical examination revealed pharyngitis with erythematous tonsillitis and the rest of the clinical exam was clean. The strepto-test was negative, he was therefore given symptomatic treatment.

Five days later, in view of the lack of improvement, the patient went to the emergency room.

Clinical examination revealed hyperthermia, hemodynamics were stable, he was eupneic in air with 98 % saturation. General conditions were altered with marked asthenia, there was erythematous angina with cervical and submandibular adenopathies associated with right laterocervical induration. The patient complained of basithoracic pain, cardiopulmonary auscultation was normal, the electrocardiogram indicated a regular sinus rhythm without conduction and repolarization disorders. Neurologically, the patient's Glasgow score was 15, there was no headache or meningeal syndrome. The abdomen was supple on palpation, there was no transit disturbance. The patient did not report any urinary symptoms, genital examination was normal, no rash was found and there was no arthritis.

A biological assessment was carried out and found an inflammatory syndrome with a C-Reactive-Protein of 315 mg/l and hyperleukocytosis to 17 G/L of which 15 G/L neutrophil polymorphism. EBV, CMV and HIV serologies were negative.

* Corresponding author.

E-mail addresses: solene.barguil@intradef.gouv.fr (S. Barguil), ludovic.karkowski@intradef.gouv.fr (L. Karkowski).

A cervicothoracic CT scan was performed as an emergency and showed Lemierre's syndrome with a right tonsillar abscess, measured at 12 × 29 mm in the axial plane extended over 2 cm in height, complicated by right jugular and facial vein thrombosis and pulmonary septic emboli with multiple pulmonary abscesses (Fig. 1).

The patient was hospitalized and managed by the otorhinolaryngologist for drainage of the tonsillar abscess with evacuation of purulent fluid.

Antibiotic therapy was introduced with Ceftriaxone, Metronidazole and Linezolid. Blood cultures detected the presence of

Fusobacterium necrophorum and cultures of the evacuating puncture fluid of the tonsillar abscess identified *Fusobacterium necrophorum* and *Gardnerella vaginalis* by MALDI-TOF (VITEK® bioMérieux) without misidentification. Antibiotic therapy was therefore modified with Amoxicillin-Clavulanic Acid intravenous for 1 week then relayed orally for 3 supplementary weeks. The evolution of the biological inflammatory syndrome was favourable under treatment after 1 month of follow-up.

He received preventive anticoagulation with sub-cutaneous Enoxaparine 0.4 mL per day during 4 weeks.

On resuming the interview, the patient reported heterosexual intercourse with oral sex with an unknown woman a few days before the onset of symptoms. Serologies for sexually transmitted diseases (syphilis, HBV and HCV hepatitis) were negative.

Discussion

Oral infections of sexually transmitted germs are well described in the literature. Oropharyngeal infections with *Neisseria gonorrhoeae* or *Chlamydia trachomatis* can cause pharyngitis and tonsillitis. Out of 33 studies studying the prevalence of extragenital gonococcal and chlamydial infections in women published between 1981 and 2015, the range of prevalence of extragenital infections was 0–29.6 % for pharyngeal gonorrhoea and 0.2–3.2 % for pharyngeal chlamydia [1]. Among men who have sex with men, analysis of 53 studies showed a prevalence ranging from 0.5 to 16.5% for pharyngeal gonorrhoea and 0–3.6 % for pharyngeal chlamydia. Among men who have sex with women only, 9 studies were analyzed and showed a prevalence of 0.4–15.5 % for pharyngeal gonorrhoea and 0–22 % for pharyngeal chlamydia. The pharyngeal and rectal locations are the main extragenital locations. In most cases, extragenital infections are asymptomatic.

Cases of oral syphilis are also well described in the literature. Oral syphilis usually affects men in their 30s and 40s. In the secondary stage, the most common locations are the lips and tongue, which can be mistaken for herpes virus infections or aphthous ulcers [2]. But the particularity of syphilitic oral lesions is that they are, in the majority of cases, painless. More rarely, oral lesions of tertiary syphilis characterized by syphilitic gum may be found on the palate, tongue or tonsils. Unlike the typical primary syphilitic chancre, which can also be found in the oral region, the secondary and tertiary oral manifestations of syphilis are not related to the direct practice of oral sex [3].

Changes in sexual practices involve extragenital manifestations of sexually transmitted infections. The diagnosis of these oral lesions is a challenge because they can themselves manifest in different clinical forms and can mimic other pathologies. Practitioners should therefore be made aware of the occurrence of these oral manifestations and offer screening serologies in case of suspicion in a patient at risk.

As described above, the extragenital forms of syphilis, gonococcus, chlamydia are currently well known. Here, this is the first case to our knowledge and described in the literature concerning angina and tonsillar abscess documentation of *Gardnerella vaginalis* (GV). This variable GRAM anaerobic germ is the main pathogen encountered in bacterial vaginosis either as the sole pathogenic germ or in association with anaerobic bacteria. GV is mainly found in the female genital tract, 87 % of women without bacterial vaginosis are carriers of Gardnerella [4]. In men, asymptomatic urethral colonization is estimated at 11.4 % [5,6]. This germ is responsible for various genitourinary disorders in women and men (urethritis, cystitis, balanoposthitis, prostatitis) [7]. More rarely, bacteremia has been noted in women at the time of delivery [8]. In men, it is usually asymptomatic carriage, however, we have found cases of severe infection including sepsis, pulmonary infection, pulmonary and peripheral abscesses [9,10].

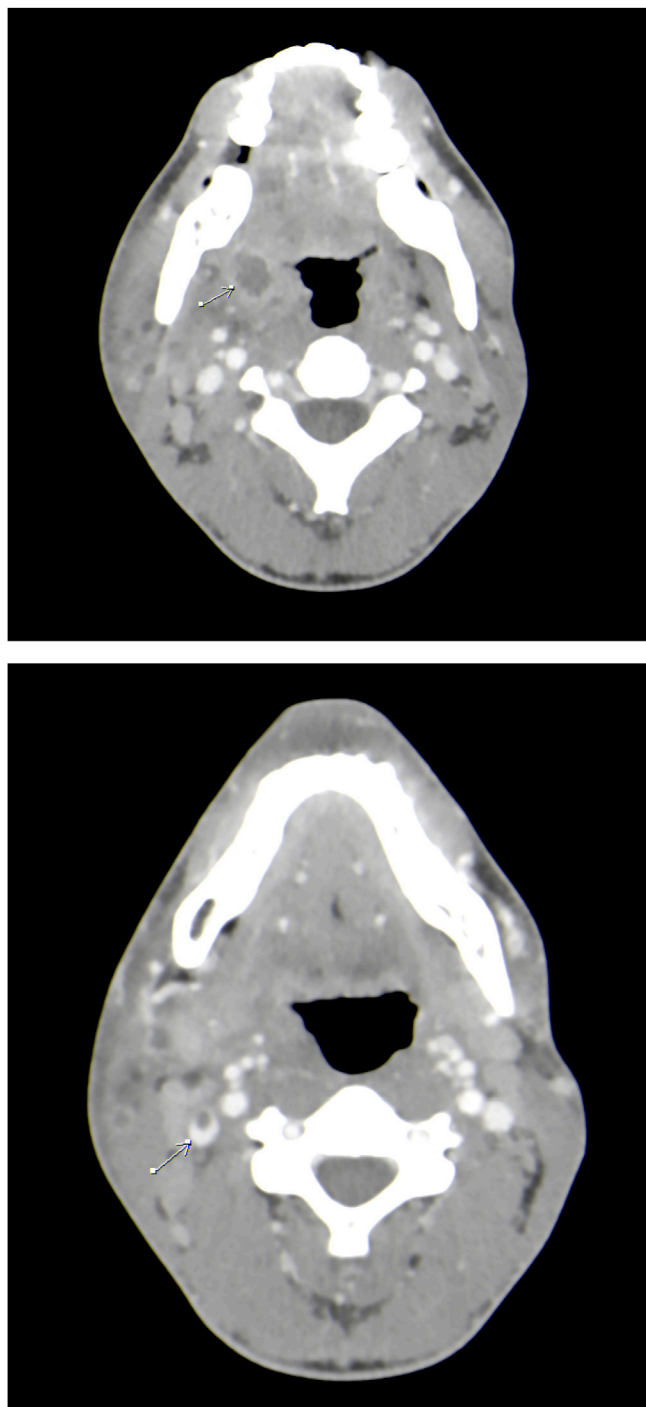


Fig. 1. Cervical CT scan showing right tonsillar abscess complicated by thrombosis of the right internal jugular vein.

The pulmonary abscesses of our patient were not sampled but we can imagine that the germ would have been found there too.

Vaginosis with GV is not traditionally included in the category of sexually transmitted infections. Indeed, the pathogenesis of GV vaginosis remains poorly understood despite several years of research. Multiple factors seem to be intertwined, such as the change in the vaginal microbiota that would lead to a dysbiotic state and the development of several anaerobic germs [11].

However, according to several epidemiological and microbiological data, GV vaginosis could be assimilated to a sexually transmitted infection because of several similarities that it shares with these pathologies [12]. Firstly, there would be sexual transmission by male partners colonized by GV and this sexual transmission could also promote recurrent vaginosis by reinfection (the male partner would be the reservoir). Women with vaginosis could also colonize their male partners. Similarly, vaginosis would be promoted by irregular condom use and would be predominant in women with exposure to a new sexual partner. In addition, although the symptomatology is considered minor, vaginosis can have a significant impact on quality of life and reproductive and obstetrical sequelae. Finally, they are believed to promote the transmission of other STIs such as HIV [12].

Even if it is not possible to assert the pathogenicity of this germ in this context of Lemierre's syndrome, this case shows that bacterial identification is necessary in order to adapt the antibiotic therapy. This bacteria is sensitive to beta-lactam antibiotics, Erythromycin, Pristinamycin, Clindamycin, Vancomycin and Metronidazole. *Gardnerella vaginalis* is resistant to Aminoglycosides. The treatment of vaginosis uses Metronidazole *per os* which can also be used during pregnancy without any teratogenic effect.

Lemierre's syndrome is also known as the "forgotten disease" because of the decrease in the number of cases since the development of antibiotics. It is a rare condition characterized by thrombophlebitis of the internal jugular vein and septic emboli. It is very often preceded by an otorhinolaryngology infection, especially tonsillitis, but can also result from an infection of the nose, ears, parotid gland or sinuses [13].

This condition is mainly caused by the anaerobic oropharyngeal flora and most often by *Fusobacterium necrophorum*. However, other germs may be related to this infection: *Staphylococcus*, *Streptococcus* (groups A,B,C, oral, *constellatus*, *intermedium*), *Enterococcus*, *Proteus mirabilis*, *Pseudomonas aeruginosa*, *Eikenella corrodens*, *Leptotricha buccalis* [14] and *Klebsiella pneumoniae* have been discovered in middle-aged patients recently diagnosed with type 2 diabetes [14,15]. *Campylobacter pylori* was also found in a previously healthy male [16]. The causative agent was not detected in 33 % of cases [17].

The diagnosis of Lemierre's syndrome is based on clinical, microbiological and imaging evidence. The most effective diagnostic imaging tool is still debated but the majority of diagnoses are based on CT scans to identify jugular vein thrombosis and septic emboli [17].

According to a recent meta-analysis, Lemierre's syndrome preferentially affects men (60 %) with an average age of 28.8 [18]. The mortality rate is estimated at 4.1 %. Pulmonary septic embolisms are common (37.6 %) while cerebral embolisms are more rare (3%) [18]. Because of the seriousness of this condition, antibiotic treatment combining Betalactamine or Cephalosporin and Metronidazole must be started immediately after diagnosis. Sometimes, surgical treatment is necessary (needle aspiration, incision and drainage or acute tonsillectomy) [19].

There is no consensus in the scientific literature regarding anticoagulation. But review of the literature tend to show that anticoagulation would have no effect on vessel revascularization and mortality [20]. Some suggest that anticoagulation should be

offered in some cases if there is a poor clinical response despite well-conducted antibiotic therapy or predisposing thrombophilia and intracranial thrombosis [21]. Our team opted for preventive anticoagulation and the patient did not present clinical signs of thrombosis extensions or thromboembolic phenomena.

Conclusion

In conclusion, we described a case of Lemierre's syndrome with identification of *Gardnerella vaginalis* and *Fusobacterium necrophorum* in retropharyngeal abscess specimens. The bibliographical research showed us that *Gardnerella vaginalis* could be responsible for abscesses of various localizations, especially pulmonary. This clinical situation shows the possibilities of secondary pharyngeal localizations of *Gardnerella vaginalis*.

In addition, when faced with a case of severe of dragging angina, it may be interesting to widen our questioning to include the search for various sexual practices in order to open up the possible diagnostic panel.

Author statement

S. BARGUIL : Writing original draft, Reviewing and Editing, Visualization, Investigation **A.SOUSA-ALVES** : Writing original draft, Reviewing and Editing, Visualization, Investigation **J-R CHRISTEN**: Supervision, Resources **C. DE JERPHANION** : Supervision, Resources **J. VALERO** : Supervision, Resources **L.KARKOWSKI** : Conceptualization, Methodology, Validation, Reviewing and Editing, Supervision.

Sources of funding

The authors declare that they have no study sponsors.

Consent

None.

Ethical approval

None.

Declaration of Competing Interest

The authors declare that they have no conflict of interest.

References

- [1] Chan Philip A, Robinette Ashley, Montgomery Madeline. Extragenital infections caused by Chlamydia trachomatis and Neisseria gonorrhoeae: A Review of the Littérature. Infect Dis Obstet Gynecol 2016.
- [2] Schuch LF, da Silva KD, de Arruda JAA, Etges A. Forty cases of acquired oral syphilis and a review of the literature. Int J Oral Maxillofac Surg 2019;48:635–43.
- [3] Queiros Catarina, Costa João Borgesda. Oral transmission of sexually transmissible infections: a narrative review. Acta Med Port 2019;32 (12):776–81.
- [4] Janulaitiene Migle, Paliulyte Virginija, Grinceviciene Svitrigaile, Zakareviciene Jolita, Vladisauskiene Alma, Marcinkute Agne, et al. Prevalence and distribution of Gardnerella vaginalis Subgroups in women with and without bacterial Vaginosis. BMC infectious Disease. 2017;17:394.
- [5] Julie M, Bitter BA, Joshua Gazzetta DO. Gardnerella Vaginalis causing pulmonary infection in young adult : a novel case. Respir Med Case Rep 2019;28:100916 Elsevier.
- [6] Dawson SG, Ison CA, Csonka G, Easmon SF. Male carriage of Gardnerella vaginalis. Br J Vener Dis 1982;58:243–5.
- [7] Gardnerella Vaginalis: an overlooked pathogen in male patients? Méd Interne et Maladies Infectieuses 2015;45:423–6.
- [8] Chen Y, Han X, Guo P, Huang H, Wu Z, Liao K. Bacteremia caused by Gardnerella vaginalis in a cesarean section patient. Clin Lab 2018;64(3):379–82.
- [9] An unusual case of Gardnerella vaginalis septicemia. BMJ 1986;293(2 August).

- [10] Calvert LD, Collins M, Bateman JRM. Multiple abscesses caused by Gardnerella vaginalis in an immunocompetent man. *J Infect* 2005;51:e27–9 Elsevier.
- [11] Castro J, Machado D, Cerca N. Unveiling the role of Gardnerella vaginalis in polymicrobial Bacterial Vaginosis biofilms: the impact of other vaginal pathogens living as neighbors. *ISME J* 2019;13(5):1306–17.
- [12] Unemo M, Bradshaw CS, Hocking JS, de Vries HJC, Francis SC, Mabey D, et al. Sexually transmitted infections: challenges ahead. *Lancet Infect Dis* 2017;17(8 August):e235–79.
- [13] Duwaiki Suad Marhoon Al, Barzani Aliya Sarhan Al, Taif Sawsan. Lemierre's syndrome. *Oman Med J* 2018;33(6):523–6.
- [14] Mesrar H, Mesrar J, Maillier B, Kraoua S, Chapoutot L, Delclaux B. Syndrome de Lemierre : diagnostic, exploration, traitement. *La Revue de Médecine interne* 2018;39:339–45.
- [15] Chuncharunee A, Khawcharoenporn T. Lemierre's syndrome caused by Klebsiella pneumoniae in a diabetic patient: a case report and review of the literature. *Hawaii J Med Public Health* 2015;74(8):260–6.
- [16] Jawad Issrah I, Chandna Arjun, Morris-Jones Stephen, Logan Sarah. Unusual case of Lemierre's syndrome. *BMJ* 2018.
- [17] Katrine M, Bodtger Johannesen Uffe. Lemierre's Syndrome: current perspectives on diagnosis and management. *Infect Drug Resist* 2016;6(9):221–7.
- [18] Gore Mitchell R. Lemierre syndrome: a meta-analysis. *Int Arch Otorhinolaryngol* 2020.
- [19] Peritonsillar abscess: clinical aspects of microbiology, risk factors, and the association with parapharyngeal abscess. *Tejs Ehlers Klug. Dan Med J.* 2017;64(3).
- [20] Cupit-Link MC, Nageswara Rao A, Warad DM, Rodriguez V. Lemierre Syndrome: A Retrospective Study of the Role of Anticoagulation and Thrombosis Outcomes. *Acta Haematol* 2017;137(2):59–65.
- [21] Campo F, Fusconi M, Ciotti M, Diso D, Greco A, Cattaneo CG, et al. Antibiotic and Anticoagulation Therapy in Lemierre's Syndrome: Case Report and Review. *Chemother* 2019;31(1 February):42–8.