











Original Article



Reversibility of Pulmonary Hypertension Following Surgical Atrial Septal Defect Closure in Children with Down Syndrome

Jue Seong Lee , MD¹, Seul Gi Cha , MD², Gi Beom Kim , MD, PhD², Sang Yun Lee , MD, PhD², Mi Kyoung Song , MD², Hye Won Kwon , MD², Eun Jung Bae , MD, PhD², Jae Gun Kwak , MD, PhD³, Woong Han Kim , MD, PhD³, and Jeong Ryul Lee , MD, PhD³

¹Department of Pediatrics, Korea University College of Medicine and Korea University Medical Center, Seoul, Korea.

²Department of Pediatrics, Seoul National University Children's Hospital, Seoul, Korea.

³Department of Thoracic and Cardiovascular Surgery, Seoul National University Children's Hospital, Seoul, Korea.



Received: Feb 18, 2019

Revised: May 8, 2019

Accepted: May 8, 2019

Address for Correspondence:

Gi Beom Kim, MD, PhD

Department of Pediatrics, Seoul National University Children's Hospital, Seoul National University School of Medicine, 101 Daehak-ro, Jongno-gu, Seoul 03080, Korea.
E-mail: ped9526@snu.ac.kr


Copyright © 2019 Korean Society of Echocardiography

This is an Open Access article distributed under the terms of the Creative Commons Attribution Non-Commercial License (<https://creativecommons.org/licenses/by-nc/4.0/>) which permits unrestricted non-commercial use, distribution, and reproduction in any medium, provided the original work is properly cited.

ORCID iDs

Jue Seong Lee 


<https://orcid.org/0000-0003-1803-4682>

Seul Gi Cha 


<https://orcid.org/0000-0001-7470-9774>

Gi Beom Kim 

<https://orcid.org/0000-0002-7880-280X>

Sang Yun Lee 

<https://orcid.org/0000-0002-3071-2661>

Mi Kyoung Song 

<https://orcid.org/0000-0002-0529-869X>

Hye Won Kwon 

<https://orcid.org/0000-0002-4949-9688>

ABSTRACT

BACKGROUND: Many Down syndrome (DS) patients have an atrial septal defect (ASD) and associated pulmonary hypertension (PH) from early childhood. ASD closure in DS patients with PH is often controversial due to concerns regarding exacerbation of PH. The aim of this study was to investigate the clinical outcome following surgical ASD closure in children with DS.

METHODS: We retrospectively reviewed the medical records of DS patients who underwent surgical ASD patch closure from January 2000 to December 2016.



RESULTS: A total of 15 patients underwent surgery for ASD. Prior to ASD patch closure, nine patients were diagnosed with PH, three of whom took medications for PH. The mean age of patients at ASD patch closure was 17.3 months, and the mean diameter of the ASD was 10.2 mm. Three patients who took medications for severe PH underwent ASD patch closure at ages 7, 12, and 25 months. Two patients continued medication for an additional 13 and 21 months, and one patient remained on medication 52 months after ASD closure. PH did not recur following discontinuation of selective pulmonary vasodilators in two patients. Although a moderate degree of PH remained in one patient due to a chronic lung problem, it was improved compared to before ASD closure. No PH was observed in the remaining 12 patients following ASD closure.

CONCLUSIONS: A large ASD can be closed even in DS patients with severe PH during early childhood with the support of multiple selective pulmonary vasodilators.

Keywords: Down syndrome; Pulmonary hypertension; Atrial septal defect

INTRODUCTION

Down syndrome (DS, Trisomy 21) is a well-recognized genetic condition with various associated medical issues, most notably congenital heart disease (CHD).¹⁾ An estimated 50% of patients with DS have CHD, and an atrial septal defect (ASD) has been reported in 8% of patients with DS.²⁾ Patients with DS have a high risk of developing pulmonary hypertension

Eun Jung Bae <https://orcid.org/0000-0003-2134-151X>Jae Gun Kwak <https://orcid.org/0000-0002-6375-1210>Woong Han Kim <https://orcid.org/0000-0003-2837-7929>Jeong Ryul Lee <https://orcid.org/0000-0001-8537-587X>**Conflict of Interest**

The authors have no financial conflicts of interest.

(PH) compared to genetically normal individuals.³⁾ The high risk of PH among patients with DS is related to greater incidence of airway obstruction, tracheobronchomalacia, hypoplastic lung, and gastroesophageal reflux disease.¹⁾⁴⁾ PH has been reported in 9% to 35% of patients with a secundum ASD, regardless of whether it is open or closed.⁵⁾⁶⁾ PH is reversible in some patients when ASD closure is performed during early childhood. However, in some patients, PH is irreversible, and their outcomes following ASD closure are often poorer than in those who do not undergo closure.⁷⁾ As such, ASD closure in patients with DS and severe PH is controversial due to concerns regarding PH exacerbation. The aim of this study was to determine the clinical outcome and reversibility of severe PH after surgical closure of hemodynamically significant ASD in children with DS.

METHODS

We retrospectively reviewed the medical records of patients with DS who underwent surgical ASD patch closure at our hospital from January 2000 to December 2016. Patients with complex CHD with ASD were excluded from the study. The degree of PH was diagnosed by transthoracic echocardiography and clinical symptoms. The degree of PH was divided into mild, moderate, and severe, according to tricuspid regurgitation peak velocity and configuration of the interventricular septum. We classified PH as mild if the systolic pulmonary artery pressure (sPAP) was below 50% of the systemic systolic pressure, moderate if the sPAP was 50%-100% of the systemic systolic pressure, and severe if the sPAP was greater than 100% of the systemic systolic pressure. The sPAP can be estimated from the tricuspid regurgitation jet flow and is calculated using the modified Bernoulli equation [systolic pulmonary artery pressure = $4 \times (\text{tricuspid regurgitation peak jet velocity})^2 + \text{right atrial pressure}$].⁸⁾⁹⁾ The systolic pulmonary arterial pressure was also graded according to configuration of the interventricular septum. Partial flattening of the interventricular septum (round interventricular septum at end-systole) indicates a right ventricular (RV) systolic pressure below 50% of the systemic systolic pressure. Flattening of the interventricular septum at end-systole indicates that the RV pressure is 50%-100% of the systemic systolic pressure. A squeezed left ventricle at end-systole indicates that the RV pressure is greater than 100% of the systemic systolic pressure.⁸⁾

We also reviewed the patients' surgical records and laboratory findings to determine the severity of PH and perioperative change in clinical data. Furthermore, we reviewed the data on cardiac catheterization to determine the severity and reversibility of PH before ASD closure. We also serially reviewed patients' echocardiographic data to evaluate for PH regression after ASD closure.

This study was approved by the institutional review board of our hospital, and informed consent was waived given the retrospective nature of this study.

RESULTS

A total of 15 patients underwent surgery for ASD (**Table 1**). Nine patients (60%) were diagnosed with PH by echocardiography before ASD patch closure. Five patients (33%) had mild, one patient (7%) had moderate, and three patients (20%) had severe PH (**Figure 1**). Among them, three patients (20%) were taking multiple selective pulmonary vasodilators

Table 1. Patient demographics and treatment outcomes

Patient	Age (mo.) at diagnosis of PH	Age (mo.) / weight (kg) at Op.	ASD size (mm)	ASD size index (mm/BSA)	PH	Medication for PH	Survival	F/U duration (years)
1	7	8/9.8	10.0	24.39	Mild	None	Survival	17.5
2	25	25/9.5	12.1	25.20	Severe	Viagra, Bosentan	Survival	7.3
3	4	7/5.8	10.0	31.25	Severe	Viagra, Bosentan, Ventavis	Survival	8.2
4	-	6/5.7	7.0	22.58	None	None	Survival	7.8
5	-	21/9.4	7.2	16.00	None	None	Survival	6.5
6	2	3/4.0	9.9	41.25	Moderate	None	Survival	7.5
7	-	7/6.6	14.2	39.44	None	None	Survival	7.3
8	-	7/7.5	15.0	39.47	None	None	Survival	5.8
9	-	132/36.0	15.8	13.98	None	None	Survival	5.5
10	-	10/10.7	4.9	10.00	None	None	Survival	3.7
11	2	2/4.4	14.9	55.18	Mild	None	Survival	5.0
12	4	10/9.7	14.0	29.78	Mild	None	Survival	4.0
13	5	9/8.5	8.0	20.00	Mild	None	Survival	3.0
14	0	12/6.5	9.7	23.50	Severe	Viagra, Bosentan	Survival	2.0
15	3	7/6.9	11.5	31.94	Mild	None	Survival	2.2

ASD: atrial septal defect, BSA: body surface area, F/U: follow-up, Med: medication, mo.: months, Op.: operation, PH: pulmonary hypertension

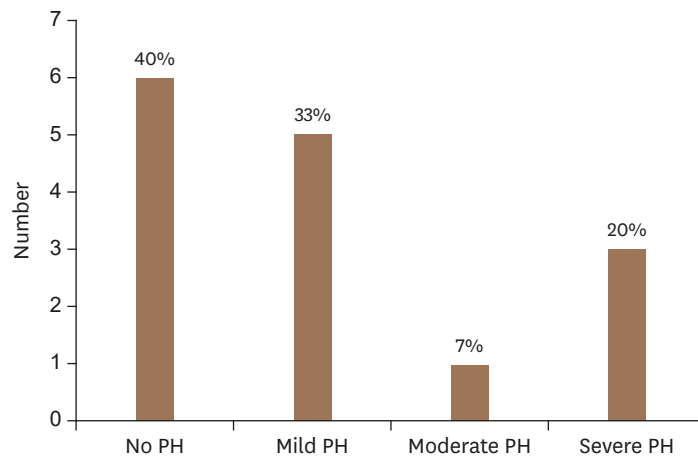


Figure 1. Pulmonary hypertension (PH) severity before surgical atrial septal defect repair. Three of 15 patients (20%) had severe PH before surgery.

(bosentan, sildenafil) for severe PH before ASD closure. The mean age at surgical ASD patch closure was 17.3 months (range: 2 months to 11 years), and the mean ASD defect diameter was 10.2 mm (range: 4.9-15.8 mm). Six patients (40%) did not have PH before ASD closure.

One patient (female, one-year-old) underwent diagnostic cardiac catheterization with an acute pulmonary vasoreactivity test (AVT) before ASD closure. The patient's mean pulmonary arterial pressure was 66 mmHg and pulmonary vascular resistance (PVR) was 10.7 Wood units/m². Following O₂ inhalation (10 L/min via mask), the mean pulmonary arterial pressure dropped to 44 mmHg, and the PVR decreased to 2.17 Wood units/m². Therefore, we decided to perform surgical ASD closure with confidence.

Three patients (20%) who were taking selective pulmonary vasodilators for severe PH before ASD closure underwent ASD patch closure at ages 7, 12, and 25 months, respectively (**Table 2**). **Table 3** shows echocardiographic changes in patients with severe PH after ASD closure. Two patients continued medication for an additional 13 and 21 months after surgery, and one patient remained on medication for 52 months after ASD closure. PH did not recur following discontinuation of selective pulmonary vasodilators in two patients. One female

Table 2. Clinical outcomes of three patients with severe PH before ASD closure

Patient	Medication			Age at operation (month)	Duration of medication after ASD closure (month)	PH recurrence
	Viagra (mg/kg/d)	Bosentan (mg/kg/d)	Ventavis (µg/6 hr)			
2	1.6	1.8	-	25	21	No
3	3.1	1.4	2	7	13	No
14	2.5	1.5	-	12	52	Moderate degree of PH due to chronic lung disease

ASD: atrial septal defect, PH: pulmonary hypertension

Table 3. Echocardiographic changes in patients with severe pulmonary hypertension

Patient	Pre-operative			Post-operative			Time interval (month)
	IVS	TR amount	TR peak velocity (m/s)	IVS	TR amount	TR peak velocity	
2	Squeezed LV	Trivial	Unable to assess	Flat	Trivial	Unable to assess	13
3	Squeezed LV	Mild	4.5	Normal	Trivial	Unable to assess	45
14	Squeezed LV	Moderate	4	Flat	Trivial	Unable to assess	18

IVS: interventricular septum, LV: left ventricle, TR: tricuspid regurgitation

patient showed improved PH, from severe to mild, on echocardiography three months after ASD closure. However, PH recurred six months after ASD closure, and the patient was hospitalized at a different institution several times due to pneumonia and dyspnea over the course of two years. Two years following ASD closure, the patient's respiratory symptoms gradually improved, and the patient had not been hospitalized in the previous six months. The patient had been taking pulmonary vasodilators (bosentan and sildenafil) due to moderate PH diagnosed by echocardiography. However, all patients with severe PH improved after ASD closure. Six patients who had PH before ASD closure and were not taking selective pulmonary vasodilators showed improvement within one week of ASD closure. The remaining six patients who did not have PH prior to ASD closure did not develop PH after ASD closure.

Ten of the 15 patients in this study have been followed up at our hospital and none have died. The remaining five patients were lost to follow-up. Four of them were alive and without symptoms of heart disease at their most recent visit, although one patient had moderate PH that seemed to be improving gradually after ASD closure as described above. The mean survival years after ASD closure was 6.22 ± 3.74 years.

DISCUSSION

All patients with DS included in this study showed PH regression after ASD closure, including three patients who had severe PH before ASD closure, when closure was accompanied by therapy with multiple selective pulmonary vasodilators. PH can progress very rapidly and be more severe in patients with DS due to a number of contributing factors that affect disease progression.⁴⁾¹⁰⁾¹¹⁾ Although CHD, including ASD, can influence the progression of PH, it is also vital to search for other common causes of PH in DS patients, such as upper airway obstruction, tracheobronchomalacia, hypoplastic lung, gastro-esophageal reflux, abnormal pulmonary vasculature growth, and recurrent pulmonary infection, and to manage these conditions appropriately.⁴⁾¹¹⁾

The majority of ASD patients is asymptomatic, with diverse symptoms manifesting as the patient gets older.¹²⁾¹³⁾ Continuous exposure of the pulmonary vasculature to increased blood flow in patients with ASD may cause histological changes in the intima and media

of the pulmonary arteries and arterioles, with resultant luminal narrowing and subsequent aggravation of PH.¹⁴ Even when the patient is asymptomatic, severe complications, such as RV failure, atrial arrhythmias, paradoxical embolization, cerebral abscess formation, PH, and even Eisenmenger syndrome, can occur.¹²

An AVT can help assess whether or not patients with PH and CHD are operative candidates. A baseline PVR index < 6 Wood units/m² and a PVR/SVR (systemic vascular resistance) < 0.3 have been used as indicators of favorable prognosis after repair, with no need for vasoreactivity testing.¹⁵ AVT is required if the baseline PVR is between 6 and 9 Wood units/m² and PVR/SVR is between 0.3 and 0.5.¹⁵ We can predict a favorable outcome after ASD closure when the final PVR index is < 6 Wood units/m² and the final PVR/SVR is < 0.3 or there is a greater than 20% decrease in the PVR index after AVT.^{16,17} Although these are currently the best measures of assessing candidacy for surgical intervention, there is still no consensus as to whether the vasoreactivity test is sufficiently accurate to identify patients who will have a favorable outcome after surgery.¹⁷

The current life expectancy for patients with PH and DS is into the fourth or fifth decade of life, and it is well known that comorbidities can have a significant effect on quality of life.⁴ PH can be prevented if the ASD is closed early, but careful consideration of operative intervention is necessary in patients with a left-to-right shunt through the defect.^{18,19}

A novel treatment and repair approach for PH associated with CHD has recently been introduced. This approach involves treating a patient previously considered to have irreversible, inoperable CHD with targeted pulmonary vasodilator therapy to reduce their PH, followed by surgery to repair the cardiac defect.²⁰ In the past, severe PH associated with a septal defect has been considered inoperable, as patients are perceived to have irreversible obstructive pulmonary vascular disease that puts them at high operative risk with a low possibility of benefit from the operation.²⁰

Nevertheless, despite the established long-term pulmonary vascular disease with evidence of significant vascular remodeling/obstruction, Eisenmenger patients often show a good response to advanced selective pulmonary vasodilator therapy.²¹ It has been established that almost one-third of Eisenmenger patients have some degree of pulmonary vasoreactivity despite obstructive PH.²²

Some cases with severe PH and ASD have shown improvement with the treatment and repair technique.²⁰ Schwerzmann et al.²³ described a 38-year-old woman with a large ASD and significant PAH (mean pulmonary arterial pressure 53 mmHg and PVR 8 Wood units/m²) who underwent percutaneous ASD closure after one year of therapy with intravenous prostacyclin. After ASD closure, bosentan therapy was continued, and the pulmonary arterial pressure was markedly reduced. Imanaka et al.²⁴ described a 51-year-old patient with an ASD and severe PAH. After ASD closure, she experienced recurrent pulmonary hypertensive crises and was treated with nitric oxide. Two years later, her systolic pulmonary arterial pressure had decreased from 96 to 52 mmHg and PVR from 14 to 10 Wood units/m².

However, all of these patients showed a significant response with advanced selective pulmonary vasodilator therapy; there is limited data regarding outcomes of successful ASD repair in patients who have no response to advanced therapy. Further studies are required to fully elucidate the long-term effects and risks of this approach.¹¹

Our study has some limitations. First, the number of study participants was small, with few patients who had both DS and PH with an ASD. Further multicenter studies with large cohorts are required to support the findings of this study. Secondly, although the gold standard for diagnosing PH is cardiac catheterization, this was only performed in one patient; PH in other patients was diagnosed based on echocardiography and clinical symptoms.

In conclusion, there were no patients with PH progression after ASD closure, including three patients who had severe PH before ASD closure. Our findings suggest that children with DS and severe PH with a large ASD may undergo surgery for ASD closure during early childhood without exacerbation of PH by using multiple selective pulmonary vasodilators.

REFERENCES

1. King P, Tulloh R. Management of pulmonary hypertension and Down syndrome. *Int J Clin Pract Suppl* 2011;65:8-13.
[PUBMED](#) | [CROSSREF](#)
2. Freeman SB, Taft LF, Dooley KJ, et al. Population-based study of congenital heart defects in Down syndrome. *Am J Med Genet* 1998;80:213-7.
[PUBMED](#) | [CROSSREF](#)
3. Greenwood RD, Nadas AS. The clinical course of cardiac disease in Down's syndrome. *Pediatrics* 1976;58:893-7.
[PUBMED](#)
4. Herbert S, Tulloh RM. Treatment of pulmonary hypertension in Down's syndrome. *J Genet Syndr Gene Ther* 2015;6:273.
5. Vogel M, Berger F, Kramer A, Alexi-Meshkishvili V, Lange PE. Incidence of secondary pulmonary hypertension in adults with atrial septal or sinus venosus defects. *Heart* 1999;82:30-3.
[PUBMED](#) | [CROSSREF](#)
6. Engelfriet P, Meijboom F, Boersma E, Tijssen J, Mulder B. Repaired and open atrial septal defects type II in adulthood: an epidemiological study of a large European cohort. *Int J Cardiol* 2008;126:379-85.
[PUBMED](#) | [CROSSREF](#)
7. Balint OH, Samman A, Haberer K, et al. Outcomes in patients with pulmonary hypertension undergoing percutaneous atrial septal defect closure. *Heart* 2008;94:1189-93.
[PUBMED](#) | [CROSSREF](#)
8. Kim GB. Pulmonary hypertension in infants with bronchopulmonary dysplasia. *Korean J Pediatr* 2010;53:688-93.
[PUBMED](#) | [CROSSREF](#)
9. Dabestani A, Mahan G, Gardin JM, et al. Evaluation of pulmonary artery pressure and resistance by pulsed Doppler echocardiography. *Am J Cardiol* 1987;59:662-8.
[PUBMED](#) | [CROSSREF](#)
10. Cua CL, Blankenship A, North AL, Hayes J, Nelin LD. Increased incidence of idiopathic persistent pulmonary hypertension in Down syndrome neonates. *Pediatr Cardiol* 2007;28:250-4.
[PUBMED](#) | [CROSSREF](#)
11. Banjar HH. Pulmonary hypertension (PHT) in patients with Down syndrome: the experience in a tertiary care center in Saudi Arabia. *J Pulm Respir Med* 2012;2:115.
[CROSSREF](#)
12. Skride A, Upmale S, Sablinskis K, Rudzītis A, Lejnieks A. Pulmonary arterial hypertension associated with adult congenital heart disease, when inoperable becomes operable: a case report. *J Pulm Respir Med* 2016;6:350.
[CROSSREF](#)
13. Diaconu CC. Atrial septal defect in an elderly woman—a case report. *J Med Life* 2011;4:91-3.
[PUBMED](#)
14. Murphy JG, Gersh BJ, McGoan MD, et al. Long-term outcome after surgical repair of isolated atrial septal defect. Follow-up at 27 to 32 years. *N Engl J Med* 1990;323:1645-50.
[PUBMED](#) | [CROSSREF](#)

15. Lopes AA, O'Leary PW. Measurement, interpretation and use of haemodynamic parameters in pulmonary hypertension associated with congenital cardiac disease. *Cardiol Young* 2009;19:431-5.
[PUBMED](#) | [CROSSREF](#)
16. Hansmann G. Pulmonary hypertension in infants, children, and young adults. *J Am Coll Cardiol* 2017;69:2551-69.
[PUBMED](#) | [CROSSREF](#)
17. Myers PO, Tissot C, Beghetti M. Assessment of operability of patients with pulmonary arterial hypertension associated with congenital heart disease. *Circ J* 2014;78:4-11.
[PUBMED](#) | [CROSSREF](#)
18. Galie N, Humbert M, Vachiery JL, et al.. 2015 ESC/ERS guidelines for the diagnosis and treatment of pulmonary hypertension: the Joint Task Force for the Diagnosis and Treatment of Pulmonary Hypertension of the European Society of Cardiology (ESC) and the European Respiratory Society (ERS): endorsed by: Association for European Paediatric and Congenital Cardiology (AEPC), International Society for Heart and Lung Transplantation (ISHLT). *Eur Heart J* 2016;37:67-119.
[PUBMED](#) | [CROSSREF](#)
19. D'Alto M, Mahadevan VS. Pulmonary arterial hypertension associated with congenital heart disease. *Eur Respir Rev* 2012;21:328-37.
[PUBMED](#) | [CROSSREF](#)
20. Dimopoulos K, Peset A, Gatzoulis MA. Evaluating operability in adults with congenital heart disease and the role of pretreatment with targeted pulmonary arterial hypertension therapy. *Int J Cardiol* 2008;129:163-71.
[PUBMED](#) | [CROSSREF](#)
21. Galie N, Beghetti M, Gatzoulis MA, et al.. Bosentan therapy in patients with Eisenmenger syndrome: a multicenter, double-blind, randomized, placebo-controlled study. *Circulation* 2006;114:48-54.
[PUBMED](#) | [CROSSREF](#)
22. Budts W, Van Pelt N, Gillyns H, et al.. Residual pulmonary vasoreactivity to inhaled nitric oxide in patients with severe obstructive pulmonary hypertension and Eisenmenger syndrome. *Heart* 2001;86:553-8.
[PUBMED](#) | [CROSSREF](#)
23. Schwerzmann M, Zafar M, McLaughlin PR, Chamberlain DW, Webb G, Granton J. Atrial septal defect closure in a patient with "irreversible" pulmonary hypertensive arteriopathy. *Int J Cardiol* 2006;110:104-7.
[PUBMED](#) | [CROSSREF](#)
24. Imanaka K, Kotsuka Y, Takamoto S, Furuse A, Inoue K, Shirai T. Atrial septal defect and severe pulmonary hypertension in an adult who needed nitric oxide inhalation after repair. *Kyobu Geka* 1998;51:403-5.
[PUBMED](#)