



Since January 2020 Elsevier has created a COVID-19 resource centre with free information in English and Mandarin on the novel coronavirus COVID-19. The COVID-19 resource centre is hosted on Elsevier Connect, the company's public news and information website.

Elsevier hereby grants permission to make all its COVID-19-related research that is available on the COVID-19 resource centre - including this research content - immediately available in PubMed Central and other publicly funded repositories, such as the WHO COVID database with rights for unrestricted research re-use and analyses in any form or by any means with acknowledgement of the original source. These permissions are granted for free by Elsevier for as long as the COVID-19 resource centre remains active.



Clinical Letter

Childhood Multisystem Inflammatory Syndrome With Prominent Neurological Involvement



Gül Demet Kaya Özçora, MD ^{a,*}, Ferhan Çetindağ, MD ^b, Murat Doğan, MD ^b,
Murat Baştemir, MD ^c

^a Division of Pediatric Neurology, Hasan Kalyoncu University, University of Health Sciences, Gaziantep, Turkey

^b Department of Pediatrics, Private Medical Park Hospital, Gaziantep, Turkey

^c Department of Radiology, Private Medical Park Hospital, Gaziantep, Turkey

ARTICLE INFO

Article history:

Received 10 January 2022

Accepted 6 July 2022

Available online 4 August 2022

Keywords:

MIS-C

Laminar necrosis

Children

Immunotherapy

Introduction

Severe acute respiratory syndrome coronavirus 2 (SARS-CoV-2) is the pathogen that causes coronavirus disease 2019 (COVID-19), which was declared a pandemic on March 11, 2020, by the World Health Organization.¹ The difference in clinical severity between adults and children may be due to the differences in renin-angiotensin system receptors and altered inflammatory pathogen responses.²

Several mechanisms are responsible for such nervous system manifestations. After infection, the virus can reach the whole brain and cerebrospinal fluid (CSF) in less than seven days. In such cases, postinfectious immune-mediated processes, direct viral infection of the central nervous system (via the olfactory bulb, transsynaptic transfer across infected neurons, leukocyte migration across the blood-brain barrier, or infection of the vascular endothelium), and virus-induced hyperinflammatory and hypercoagulable conditions are commonly observed.^{3,4}

Until the description of multisystem inflammatory syndrome in children (MIS-C) associated with COVID-19, SARS-CoV-2 infection in children received little attention because it did not seem clinically important. Febrile seizures and acute meningoencephalitis are two major neurological complications of COVID-19 in infants and children in the acute phase. Nonspecific neurological manifestations have also been reported in more severe COVID-19-associated cases of MIS-C.^{5–7}

Herein, we describe the clinical and radiologic features of 3 children with neurologic manifestations related to SARS-CoV-2 infection and MIS-C.

Patient Description

Written informed consent to publication has been obtained from the parents on behalf of the patients.

Patient 1

A 14-year-old girl who underwent surgery for medulloblastoma with accompanying epilepsy and was under follow-up since 2014 presented to the hospital with severe abdominal pain for 1 day and altered mental status followed by a seizure. Upon developing fever and respiratory distress during examination, she was intubated and

Conflicts of Interest: The authors declare no conflict of interest.

* Communications should be addressed to: Kaya Özçora; Division of Pediatric Neurology; Hasan Kalyoncu University; University of Health Sciences; Mucahitler Mah 25203, Street No:2, Sehitkamili; Gaziantep, Turkey.

E-mail address: guldemetkaya@hotmail.com (G.D. Kaya Özçora).

taken to the intensive care unit (ICU). A SARS-CoV-2 real-time polymerase chain reaction (PCR) test of a nasopharyngeal swab sample was negative. SARS-CoV-2 immunoglobulin M (IgM) was found to be negative, whereas IgG was positive. She had a history of contact with a patient with COVID-19 within the last two months. Clinical, laboratory, and imaging findings are presented in Table and Figs 1 and 2. Lumbar puncture revealed lymphocytic pleocytosis and normal CSF pressure. Empirical treatment with vancomycin meropenem and lopinavir was initiated with a diagnosis of MIS-C. Electroencephalography (EEG) revealed diffuse background slowing with reduced amplitude. Mild left ventricular systolic dysfunction was present, and the coronary arteries were intact in the echocardiogram. Intravenous immunoglobulin (IVIg) (2 g/kg) and methylprednisolone (2 mg/kg/day) were administered with low-dose aspirin. However, due to a lack of clinical improvement and increased need for inotropes, pulse steroid therapy (30 mg/kg/day) was given for three days. The patient was extubated after 18 days. She did not experience any further seizures, but there was no change in her altered mental status. Repeated brain magnetic

resonance imaging on day 21 demonstrated bilateral laminar necrosis and gliosis. The patient stayed in the ICU for 56 days and ultimately died due to sepsis.

Patient 2

An 18-month-old girl with a history of premature birth and pneumococcal meningitis, normal neurological development, and no dysmorphic findings was admitted to our hospital with fever for three days, generalized tonic-clonic seizures, and confusion. Clinical, laboratory, and imaging findings are presented in Table and Figs 1 and 2. Laboratory findings on admission revealed elevated inflammatory markers. Echocardiogram showed no coronary artery abnormalities. Nasopharyngeal SARS-CoV-2 PCR and SARS-CoV-2 IgM were negative, whereas IgG was positive. Lumbar puncture was normal. The parents reported that the patient's grandmother and grandfather had COVID-19 infection six weeks earlier. Based on the clinical and laboratory findings, the patient was diagnosed with MIS-C. After developing impaired consciousness and hypertension,

TABLE.
Clinical and Laboratory Findings of Children With SARS-CoV-2

Demographic and Clinical Findings	Patient 1	Patient 2	Patient 3
Sex/age (years)	Female/14	Female/1.5	Male/2
Initial symptom	Abdominal pain	Fever	Fever
Neurological symptom	Convulsion, altered mental status	Convulsion, altered mental status	Ataxia, ptosis, altered mental status
Contact history	6 weeks	3-4 weeks	3-4 weeks
White blood cell (per µL)	2460	22,450	27,100
Lymphocyte (per µL)	690	5700	5130
Monocyte (per µL)	10	1780	6500
Neutrophil (per µL)	1750	14,940	17,870
Platelet (per µL)	191,000	587,000	619,000
ALT/AST (U/L)	17/51	12/21	19/20
CRP (mg/L)	224	232.72	36.62
Procalcitonin (ng/mL) (N: 0-0.5)	>100	3.03	1.79
Pro-BNP (ng/L) (N: 0-157)	4898	N/A	N/A
IL-6 (pg/mL) (N: 0-5.9)	>1000 (0-5.9)	55	160
Ferritin (µg/L) (N: 12-327)	1161	358	310
LDH (120-300)	347	213	311
D-dimer (ng/mL) (N: 0-500)	10,000	986	1282
Fibrinogen (mg/dL) (N:1,8-3,5)	4.65	NA	NA
Troponin I (ng/ml) (N: 0-0.16)	0.262	<0.1	0.426
C3 (g/L) (N: 0.75-1.80)	0.75	1.72	1.04
C4 (g/L) (N: 0.15-0.42)	0.19	0.34	0.27
IgG (g/L) (N: 2.2-10.7)	10.8	7.94	7.74
IgA (g/L) (N: 0.15-1.5)	1.35	0.19	1.1
IgM (g/L) (N: 0.45-2)	0.96	1.65	1.6
CSF glucose (mg/dL) (60-80 mg/dL)	71	63	65
CSF protein (mg/dL) (15-45 mg/dL)	78	50	43
CSF cell count (/mm ³)	10 Lymphocytes	None	None
EEG	Diffuse slowing	Diffuse slowing	Diffuse slowing
Immune treatment	IVIg (2 g/kg, 1 dose) MP (30 mg/kg/day, 3 days) MP (2 mg/kg/day 3 weeks)	IVIg (2 g/kg, 1 dose) MP (2 mg/kg/day 7 days)	IVIg (2 g/kg, 1 dose) MP (30 mg/kg/day, 10 days) MP (2 mg/kg/day 3 weeks)
Follow-up	-	18 months	17 months
Prognosis	Exitus	No sequelae	No sequelae

Abbreviations:

- AST = Aspartate aminotransferase
- ALT = Alanine aminotransferase
- C = Complement
- CSF = Cerebrospinal fluid
- CRP = C-reactive protein
- EEG = Electroencephalography
- Ig = Immunoglobulin
- IL-6 = Interleukin 6
- IVIg = Intravenous immunoglobulin
- LDH = Lactate dehydrogenase
- MP = Methylprednisolone
- N = Normal range
- N/A = Not available
- pro-BNP = Pro-B-type natriuretic peptide
- SARS-CoV-2 = Severe acute respiratory syndrome coronavirus 2

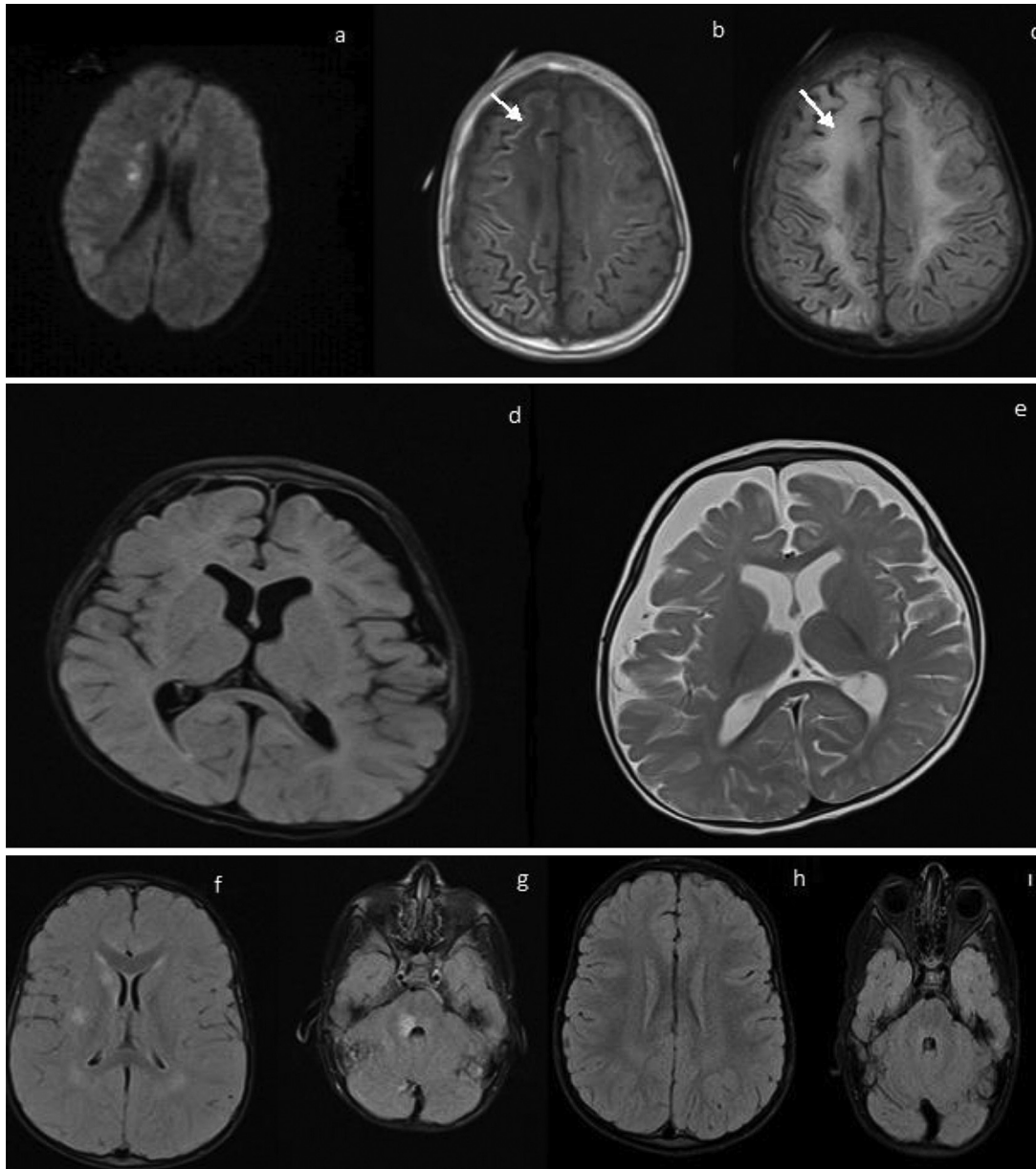


FIGURE 1. Brain magnetic resonance imaging of children. (A) Acute phase of patient 1; showed cortical and subcortical signal increase in T1-weighted sequences in both cerebral hemispheres. (B, C) Subacute phase of patient 1; showed laminar necrosis (arrows) and gliosis in T1-weighted and fluid-attenuated inversion recovery (FLAIR) sequences. (D, E) T1- and T2-weighted axial images; first and follow-up MRI of patient 2; atrophy in the left hemisphere was interpreted as a sequela change. (F, G) Acute phase of patient 3; showed cortical and subcortical signal increase in FLAIR sequences in both cerebral hemispheres and brainstem. (H, I) Follow-up MRI of patient 2; normal.

the patient was admitted to ICU for monitoring. IVIG 2 g/kg and methylprednisolone 2 mg/kg/day for 1 week were initiated with low-dose aspirin. Echocardiogram was repeated 48 hours later, and no abnormality was observed. The patient no longer required intensive care after day 2 and was discharged from the hospital on day 10, recovering completely.

Patient 3

A previously healthy two-year-old boy was admitted with complaints of fever, gait disturbance, difficulty swallowing, and a drooping eyelid for three days. On physical examination, he had a fever, respiratory distress, ataxia, ptosis in the right eye and torticollis. Clinical, laboratory, and imaging findings are shown in Table and Figs 1 and 2. The patient's entire family (parents, uncle,

grandparents) had a COVID-19 infection four weeks earlier. SARS-CoV-2 PCR and IgM were negative, whereas IgG was positive. He was intubated due to respiratory distress and hospitalized in the ICU.

CSF biochemistry was normal, and no cells were observed. Anti-neuromyelitis optica and anti-myelin oligodendrocyte glycoprotein antibody testing yielded negative results. Echocardiogram did not reveal any pathology. Based on the available laboratory and clinical findings, the patient was diagnosed as having MIS-C and associated acute demyelinating encephalomyelitis. The patient was given pulse steroid therapy for five days, and maintenance treatment was initiated in addition to antibiotic treatment. IVIG was administered due to persistent fever and a lack of clinical and laboratory improvement, and clinical improvement was seen at 48 hours after IVIG treatment. The patient was extubated 96 hours after IVIG

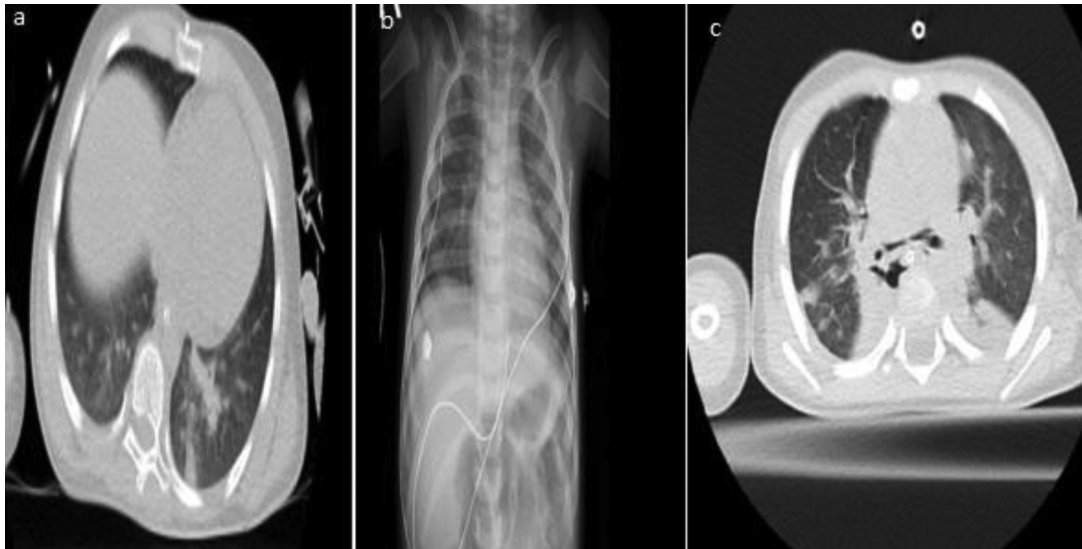


FIGURE 2. Chest imaging in children. Mosaic attenuation in the bilateral lung parenchyma, ground-glass opacity, and left basal pulmonary infiltration in patient 1 (A); normal in patient 2 (B); and bilateral pulmonary infiltration, atelectasis, and ground-glass opacity in patient 3 (C).

treatment was initiated. On day 26, the patient was discharged with low-dose aspirin and steroid therapy. Third and sixth month control magnetic resonance imaging were similar and demonstrated marked regression in the supratentorial lesions and partial regression of the lesions in the brainstem and total regression at fifteenth month (Fig 1) His neurological examination findings were normal.

Discussion

The incidence of COVID-19 is significantly lower in children than in adults, with only 2% of confirmed cases in the pediatric age group. Symptomatic children have higher viral loads when compared with asymptomatic children. Nevertheless, on April 12, 2020, The US Centers for Disease Control and Prevention described a severe systemic inflammatory response syndrome requiring hospitalization and rarely resulting in death among children who had asymptomatic or minimally symptomatic COVID-19 infection. The condition, named MIS-C, was characterized by high fever and multisystemic involvement (persistent fever, mucocutaneous manifestations, elevated inflammatory markers, and involvement of respiratory, cardiovascular, neurological and renal systems) with no plausible alternative diagnoses/exclusion of any other microbial cause, a positive test for current or recent SARS-CoV-2 infection, and COVID-19 exposure within the four weeks before symptom onset.⁸ However, very few patients were found to meet the MIS-C criteria in the acute phase of infection.^{8,9} Single IgG and IgM tests have been defined as efficient to diagnose SARS-CoV-2; we repeated more than once and IgM was found to be negative.

Most neurological complications associated with SARS-CoV-2 are unlikely to be related to direct viral neuroinvasion, but neuroinvasion can have subacute and/or delayed consequences, such as acute or subacute disseminated encephalomyelitis or viral encephalitis.¹⁰ The major neurological complications due to coronaviruses in infants and children are febrile seizures and acute meningoencephalitis.^{3,6,11–18} In the present series, one patient had meningoencephalitis, the second had convulsion, and the third patient had anti-neuromyelitis optica/myelin oligodendrocyte glycoprotein antibody-negative acute disseminated encephalomyelitis. Studies have reported that disease severity, hospitalization, and fatality are variable in different ethnicities and races. Sözeri

et al¹⁹ reported 67 patients in our country in whom the early prognosis was good with appropriate treatment and the patients recovered without any sequelae. Akçay et al.²⁰ reported two patients with acute disseminated encephalomyelitis-like disease as a postinfectious/immune-mediated complication of SARS-CoV-2 infection of which one has laminar necrosis. The patient with laminar necrosis was referred from our clinic for therapeutic plasma exchange, and he originates from the same region as patient 1. This observation supports that ethnic origin and racial differences significantly affect the prognosis of the disease.

COVID-19 can trigger new-onset seizures in patients with no known history of seizures. The reported incidence of acute symptomatic seizures due to COVID-19 is less than 1% in many studies.^{2,4,7,9} Seizures are not common compared with other viral infections, but existing seizures may increase. Cases of pediatric seizures have been reported during the pandemic; therefore, seizures must be evaluated as a potential presentation of COVID-19 in the pediatric population. Patients 1 and 2 in our series presented with seizures, and no seizure or nonconvulsive status was detected after antiepileptic treatment. The electroencephalography findings of patients with COVID-19 have been described in many reports.^{21,22} We did not find any specific findings other than background slowing.

In the present study, treatment was provided according to the current recommendations of the international treatment guidelines for MIS-C with immunoglobulin, higher-dose methylprednisolone, and IVIG treatment or therapeutic plasma exchange.²³ The patient with the demyelinating lesion was given pulse steroid therapy before IVIG treatment, and we observed clinical improvement and regression of inflammatory marker elevation after IVIG treatment. Steroids and IVIG may help the neurological symptoms related to MIS-C. Despite steroids and IVIG, patient 1 developed laminar necrosis and diffuse gliosis, and only partial improvement in lesions were observed in patient 3 in the early period. In children, cortical laminar necrosis can be caused by various diseases, including hypoxic-ischemic encephalopathy, infarction, status epilepticus, moyamoya disease, metabolic disorders, and intoxication. None of these were found in our patients, and we do not know whether the development of laminar necrosis is due to direct neuroinvasion of virus or severe MIS-C. Our patient has mild left ventricular systolic dysfunction and the coronary arteries were

normal. Hypotension, hypoglycemia, or cardiac arrest was not seen. The patient who developed laminar necrosis in the report by Akçay et al.²⁰ was positive for positive SARS-CoV-2 antibody in CSF on day 55 of admission and pleocytosis was detected. In our case CSF COVID-19 antigen or antibody was not evaluated because the test was not available. Laminar necrosis without meningoencephalitis can be a complication or manifestation of COVID-19 in the central nervous system.

Conclusion

We think that immunotherapy alone is not sufficient in acute or subacute disseminated encephalomyelitis or encephalomyelitis; an antiviral therapy is required. It is rare to detect SARS-CoV-2 by PCR or intrathecal antibody synthesis demonstrating viral neuroinvasion in the CSF examinations of patients with COVID-19 with neurological symptoms. The limiting factor of our study is we were not able to examine the CSF SARS-CoV-2 PCR of our patients.

References

- World Health Organization (WHO). Coronavirus disease (COVID-19) Situation Report 2020-104. Available at: https://www.who.int/docs/default-source/coronaviruse/situation-reports/20200503-covid-19-sitrep-104.pdf?sfvrsn=53328f46_2. Accessed May 7, 2020.
- Tezer H, Demirdağ TB. Novel coronavirus disease (COVID-19) in children. *Turk J Med Sci*. 2020;50:592–603.
- Pooya AA. Seizures associated with coronavirus infections. *Seizure*. 2020;79:49–52.
- Jha NK, Ojha S, Jha KS, et al. Evidence of coronavirus (CoV) pathogenesis and emerging pathogen SARS-CoV-2 in the nervous system: a review on neurological impairments and manifestations. *J Mol Neurosci*. 2021;19:1–18.
- Riphagen S, Gomez X, Gonzalez-Martinez C, Wilkinson N, Theocharis P. Hyperinflammatory shock in children during COVID-19 pandemic. *Lancet*. 2020;395:1607–1608.
- Chiotos K, Bassiri H, Behrens EM, et al. Multisystem inflammatory syndrome in children during the coronavirus 2019 pandemic: a case series. *J Pediatr Infect Dis Soc*. 2020;9:393–398.
- Abdel-Mannan O, Eyre M, Lobel U, et al. Neurologic and radiographic findings associated with COVID-19 infection in children. *JAMA Neurol*. 2020;77:1440–1445.
- Jiang L, Tang K, Levin M, et al. COVID-19 and multisystem inflammatory syndrome in children and adolescents. *Lancet Infect Dis*. 2020;20:276–288.
- Esposito S, Principi N. Multisystem inflammatory syndrome in children related to SARS-CoV-2. *Paediatr Drugs*. 2021;23:119–129.
- Lewis A, Frontera J, Placantonakis DG, et al. Cerebrospinal fluid in COVID-19: a systematic review of the literature. *J Neurol Sci*. 2021;15:117316.
- Lu H, Stratton CW, Tang YW. Outbreak of pneumonia of unknown etiology in Wuhan, China: the mystery and the miracle. *J Med Virol*. 2020;92:401–402.
- Varatharaj A, Thomas N, Ellul MA, et al. CoroNerve Study Group. Neurological and neuropsychiatric complications of COVID-19 in 153 patients: a UK-wide surveillance study. *Lancet Psychiatry*. 2020;7:875–882.
- Kumar L, Kahlon N, Jain A, et al. Loss of smell and taste in COVID-19 infection in adolescents. *Int J Pediatr Otorhinolaryngol*. 2021;142:110626.
- Poyiadji N, Shahin G, Noujaim D, Stone M, Patel S, Griffith B. COVID-19-associated acute hemorrhagic necrotizing encephalopathy: imaging features. *Radiology*. 2020;296:119–120.
- Emamikhah M, Babadi M, Mehrabani M, et al. Opsoclonus-myooclonus syndrome, a post-infectious neurologic complication of COVID-19: case series and review of literature. *J Neurovirol*. 2021;27:26–34.
- Ruijter NS, Kramer G, Gons RAR, Hengstman GJD. Neuromyelitis optica spectrum disorder after presumed coronavirus (COVID-19) infection: a case report. *Mult Scler Relat Disord*. 2020;46:102474.
- Zhou S, Jones-Lopez EC, Soneji DJ, Azevedo CJ, Patel VR. Myelin oligodendrocyte glycoprotein antibody-associated optic neuritis and myelitis in COVID-19. *J Neuroophthalmol*. 2020;40:398–402.
- Khan A, Panwala H, Ramadoss D, Khubchandani R. Myelin oligodendrocyte glycoprotein (MOG) antibody disease in a 11 year old with COVID-19 infection. *Indian J Pediatr*. 2021;88:488–489.
- Sozeri B, Ulu K, Kaya-Akça U, et al. The clinical course of SARS-CoV-2 infection among children with rheumatic disease under biologic therapy: a retrospective and multicenter study. *Rheumatol Int*. 2022;42:469–475.
- Akçay N, Bektaş G, Menentoğlu ME, et al. COVID-19-associated acute disseminated encephalomyelitis-like disease in 2 children. *Pediatr Infect Dis J*. 2021;40:e445–e450.
- Kuroda N. Epilepsy and COVID-19: updated evidence and narrative review. *Epilepsy Behav*. 2021;116:107785.
- Morgello S. Coronaviruses and the central nervous system. *J Neurovirol*. 2020;26(4):459–473.
- National Institutes of Health. Coronavirus disease 2019 (COVID-19) treatment guidelines. [covid19treatmentguidelines.nih.gov/](https://www.covid19treatmentguidelines.nih.gov/). Accessed May 31, 2022.