


# A Comparison of Percutaneous Kyphoplasty with High-Viscosity and Low-Viscosity Bone Cement for Treatment of Osteoporotic Vertebral Compression Fractures: A Retrospective Study

Geriatric Orthopaedic Surgery  
& Rehabilitation  
Volume 13: 1–8  
© The Author(s) 2022  
Article reuse guidelines:  
[sagepub.com/journals-permissions](https://sagepub.com/journals-permissions)  
DOI: 10.1177/21514593221119625  
[journals.sagepub.com/home/gos](https://journals.sagepub.com/home/gos)  


Wenhao Wang, MM<sup>1,#</sup>, Hao Liu, MM<sup>1,#</sup>, Zhikai Wu, MM<sup>1,#</sup>, Yun Teng, MM<sup>1,#</sup>,  
Yixue Huang, MM<sup>1</sup>, Tao Liu, MD, PhD<sup>1</sup>, and Huilin Yang, MD, PhD<sup>1</sup>

## Abstract

**Background:** Osteoporotic vertebral compression fracture (OVCF) has become a health issue of worldwide concern. Percutaneous kyphoplasty (PKP) is one of the main surgical methods for OVCFs. This study aimed to evaluate and compare the clinical efficacy and safety of PKP with high- and low-viscosity bone cement for OVCFs. **Methods:** Totally 62 patients with single-level OVCF were enrolled in this study from December 2018 to April 2021. Among them, 32 cases underwent PKP with high-viscosity bone cement, while 30 cases underwent PKP with low-viscosity bone cement. Visual analog scale (VAS) scores and Oswestry disability index (ODI) scores were used in the pre- and post-operative period to assess patients' rehabilitation. Compression rates of anterior vertebra height (AVH) and posterior vertebra height (PVH) were analyzed to evaluate the restoration of vertebra height. Leakage rates and locations were recorded to show clinical safety. **Results:** VAS and ODI scores both significantly improved in 2 groups at 1 day, 1 month, and 3 months after surgery. Compression rates of AVH and PVH at 1 day and 3 months after PKP were lower than those before surgery. However, there was no significant difference in VAS scores, ODI scores, and compression rates between both groups. However, PKP with high-viscosity bone cement achieved a lower bone cement leakage rate significantly, which showed the safety of high-viscosity bone cement in PKP. **Conclusions:** PKP with high- and low-viscosity bone cement both improved the recovery of patients and restored vertebra heights. Notably, PKP with high-viscosity bone cement can achieve favorable clinical outcomes as well as lower bone cement leakage rate.

## Keywords

bone cement, viscosity, percutaneous kyphoplasty, osteoporotic vertebral compression fracture, leakage rate

Submitted February 26, 2022. Revised July 13, 2022. Accepted July 27, 2022

## Background

Osteoporotic vertebral compression fracture (OVCF) is bringing suffering to the aging population, especially the elderly menopausal women, which has become a health issue of worldwide concern.<sup>1</sup> Pain, vertebra instability, loss of mobility, spinal deformities, and long-term bed rest all reduce the quality of life.<sup>2,3</sup> For a long time, bed rest and

<sup>1</sup>Department of Orthopaedics, The First Affiliated Hospital of Soochow University, Suzhou, China

<sup>#</sup>These authors contributed equally to this work

### Corresponding Authors:

Tao Liu, MD, PhD, Department of Orthopaedics, The First Affiliated Hospital of Soochow University, 188 Shizi Street, Suzhou 215006, China.

Huilin Yang, MD, PhD, Department of Orthopaedics, The First Affiliated Hospital of Soochow University, 188 Shizi Street, Suzhou 215006, China.



Creative Commons Non Commercial CC BY-NC: This article is distributed under the terms of the Creative Commons Attribution-NonCommercial 4.0 License (<https://creativecommons.org/licenses/by-nc/4.0/>) which permits non-commercial use, reproduction and distribution of the work without further permission provided the original work is attributed as specified on the

SAGE and Open Access pages (<https://us.sagepub.com/en-us/nam/open-access-at-sage>).

anti-osteoporosis medication are the main treatment measures for OVCFs. The complications greatly influence patient's daily life and worsen their prognosis. A simple, convenient and effective early surgery plan was badly expected at that time. Fortunately, with the development of minimally invasive surgery (MIS), percutaneous vertebroplasty (PVP) and percutaneous kyphoplasty (PKP) are stepping onto the brilliant stage of treating OVCFs. In 1987, Galibert and Deramond for the first time applied PVP to the treatment of C2 hemangioma.<sup>4</sup> In 1998, Food and Drug Administration (FDA) approved the clinical trial of the balloon for PVP. In 2001, Lieberman et al for the first time reported PKP for treating OVCFs. After years of clinical practice, PKP performs satisfactorily in the treatment of OVCFs, especially in relieving low back pain.<sup>5-7</sup> PKP can restore the height of the vertebra and rebuild the stability of the spine by using inflated balloons and succedent-infused bone cement.<sup>8,9</sup> Meanwhile, most scholars believe that PKP is superior to PVP in terms of safety to treat OVCFs.<sup>10</sup> The expansion of the balloon during PKP can effectively prevent the leakage of bone cement, greatly reducing the risk of complications such as embolism and paralysis of lower limbs, and greatly improving the safety after bone cement is penetrated into the fractured vertebra.<sup>11</sup>

Although PKP has been improved in terms of safety compared with PVP, how to reduce the leakage rate and make it safer still prompts scholars to research. With the rapid development of biomaterials, different bone cement formulas have appeared in recent years. Although their formulas vary, poly methyl methacrylate (PMMA) is one of their main ingredients. Using PMMA as the main component and supplemented by other components, different types of bone cement formulas can be created, which result in bone cement with different viscosity.<sup>12</sup> For example, OSTEOPAL<sup>®</sup>V is a radiopaque, low-viscosity, quick-setting bone cement for filling vertebral bodies, which is widely used for patients in hospitals. In recent years, new formulas with the characteristic of high viscosity such as KYPHON<sup>®</sup>Xpede<sup>™</sup> have come into the sight of doctors. Different from low-viscosity bone cement, this type increases the cement viscosity in the liquid phase. Many studies have compared PVP with low- and high-viscosity bone cement for vertebral fractures. Zhang et al<sup>13</sup> pointed out that PVP with high viscosity bone cement has a lower cement leakage rate than PVP with low viscosity bone cement. However, research on the comparison of high- and low-viscosity bone cement in PKP is relatively rare. From our perspective, high-viscosity bone cement may have promotion value in PKP for the treatment of OVCFs.

Therefore, we summarized our experiences and conducted the study to evaluate and compare the clinical efficacy and safety of high- and low-viscosity bone cement in PKP for the treatment of OVCFs. We hope our research could add something to the development of bone cement and PKP.

## Methods

### Subjects

A total of 62 patients with single-level OVCF, who were admitted to the Orthopaedics Department of our hospital from December 2018 to April 2021, were enrolled in this retrospective study. Inclusion criteria: 1. Single-level OVCF of thoracic and lumbar vertebrae. 2. Without neurological deficit. 3. Bone mineral density was less than 2.0 SD by dual-energy X-ray absorptiometry. 4. Acute back pain with clear medical history. 5. Those were well informed and volunteered to participate in the study. Exclusion criteria: 1. With a history of thoracic or lumbar surgery. 2. With contraindications to PKP. 3. With tumor, infection, or congenital diseases.

Group A: 32 cases underwent PKP with high-viscosity bone cement. Group B: 30 cases received PKP with low-viscosity bone cement. All patients' data and images were obtained from the electronic medical record management system of the hospital. This study was approved by the ethics committee of our hospital.

### Bone Cement

Two different formulas of bone cement were used in this study. KYPHON<sup>®</sup>Xpede<sup>™</sup> bone cement powder (20 g): Methylmethacrylate-styrene-copolymer 69.1%; Barium sulfate 30.0%; Benzoyl peroxide .9%. OSTEOPAL<sup>®</sup>V bone cement powder (26 g): Poly (methyl acrylate, methyl methacrylate) 14.2 g, 54.6%; Zirconium dioxide 11.7 g, 45.0%; Benzoyl peroxide 0.1 g, .3%. The different formulas show different physical and chemical properties. KYPHON<sup>®</sup>Xpede<sup>™</sup> has the characteristic of high viscosity, while OSTEOPAL<sup>®</sup>V is a type of low-viscosity bone cement that is widely used in our hospital.

### Percutaneous Kyphoplasty Procedure

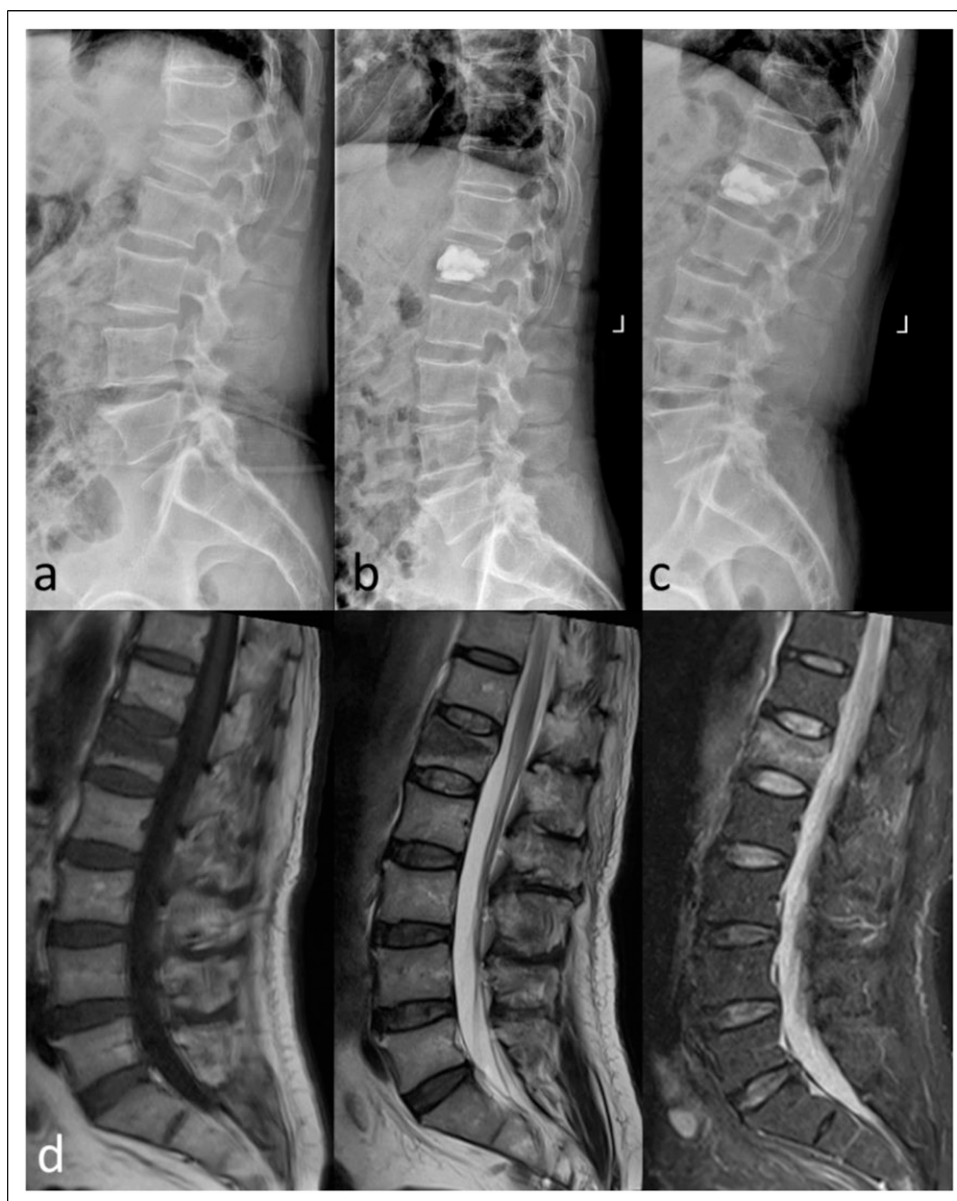
The same group of surgeons performed all the PKPs. They were experienced orthopedists in the Department of Orthopaedics of our hospital, and all the scrub nurses were well trained. Operations were carried out under general anesthesia. Each patient was positioned prone and C-arm fluoroscopy was used to locate and confirm the fractured vertebra before the operation started. The Bilateral approach was adopted. Marks were made on the skin and a small incision was made at each skin entry point. Needles were inserted into the fractured vertebra under the guidance of C-arm fluoroscopy. Afterwards, needles were withdrawn, guide pins inserted, and working tubes placed. Fine drills were used to drill holes carefully. Two balloons were used to expand the inner space of the vertebra through the 2 working channels. Bone cement was then freshly

injected into the fractured vertebra manually with the help of the scale on the tube and the C-arm fluoroscopy. The injection was terminated when cement diffusion reached the anterior cortex and entered the posterior 1/3 of the vertebra but did not reach the posterior cortex.

### Evaluation

X-rays and MRI images were taken during the peri-operative period and the follow-up (Figure 1). Visual analog scale (VAS) score and Oswestry disability index (ODI) questionnaire were used to assess the rehabilitation

of patients. VAS scores aimed to evaluate the pain and ODI scores aimed to evaluate their function disorders. They were assessed before the surgery and 1 day, 1 month, and 3 months after the surgery. We analyzed imaging information. We measured vertebral heights between superior and inferior endplates. The anterior vertebra heights (AVH) and the posterior vertebra heights (PVH) were measured 1 day and 3 months after the surgery in the lateral radiographic and their compression rates were calculated by the equation:  $\text{compression rate} = 1 - 2 * H1 / (H2 + H3)$ , where H1, H2, and H3 are the anterior or posterior heights of the fractured vertebra, the vertebra above the fractured



**Figure 1.** A 69-year-old male underwent PKP for L1 OVCF. (A) X-ray before PKP, (B) X-ray at 1 day after PKP, (C) X-ray at 3 months after PKP, (D) MRI before PKP, including T1, T2, and STIR.

**Table 1.** Demographic data of 2 groups.

Demographic Data	Total	Group A	Group B	P Value
Cases (n)	62	32	30	
Age (years)	67.52 ± 8.33	67.22 ± 7.07	67.83 ± 9.62	.774
Gender (male/female)	7/55	3/29	4/26	.623
Level (thoracic/lumbar)	28/34	18/14	10/20	.070
Hypertension (n)	25 (40.32%)	12 (37.50%)	13 (43.33%)	.640
Diabetes (n)	5 (8.06%)	3 (9.38%)	2 (6.67%)	.696
BMD (T-)	-2.99 ± .30	-2.88 ± .28	-3.03 ± .31	.053

BMD: bone mineral density.

**Table 2.** Perioperative parameters of 2 groups.

Parameters	Group A	Group B	P Value
Operative time (min)	59.44 ± 21.54	55.17 ± 15.84	.380
Blood loss (ml)	5.13 ± 3.02	4.53 ± 2.87	.433
Cement volume (ml)	7.76 ± 2.04	7.43 ± 1.96	.524
Hospital stay (days)	4.69 ± 1.49	5.17 ± 2.72	.389

vertebra, and the vertebra below the fractured vertebra. Leakage rates and locations were recorded to evaluate clinical safety. Locations included: disk space, epidural space, paravertebral areas, and peripheral veins.

### Statistical Analysis

SPSS 23.0 statistical software was used for data analysis. The t-test and Chi-square test were used for data analyses. Data were presented as the mean ± standard deviation. P value <.05 was considered statistically significant.

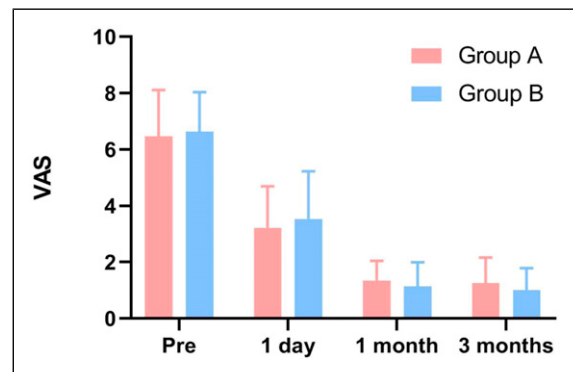
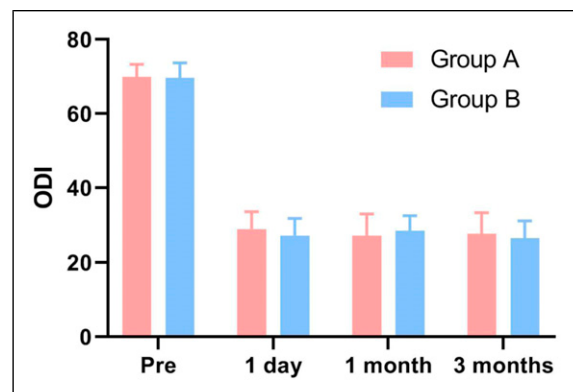
## Results

### Demographics

The demographic data of patients were shown in Table 1. There was no significant difference between the 2 groups ( $P > .05$ ).

### Clinical Outcomes

Perioperative parameters of the 2 groups were shown in Table 2. There was no statistical difference between the 2 groups ( $P > .05$ ). VAS scores of the 2 groups both decreased significantly after the operation, from over 6 points down to over 3 points ( $P < .05$ ). However, there was no significant difference of VAS scores between the 2 groups at the time point of 1 day, 1 month, 3 months after surgery ( $P > .05$ ) (Figure 2). Similarly, ODI scores significantly improved after PKP compared with those before surgery ( $P < .05$ ). However, at 1 day, 1 month, and 3 months after surgery, no

**Figure 2.** Comparison of visual analog scale scores between the 2 groups.**Figure 3.** Comparison of Oswestry disability index scores between the 2 groups.

significant difference in ODI scores was revealed between the 2 groups ( $P > .05$ ) (Figure 3).

### Compression Rates of Anterior Vertebra Height and Posterior Vertebra Height

For radiographic data, AVH and PVH were measured and the compression rates of AVH and PVH were all observed to improve significantly at 1 day and 3 months after PKP in

**Table 3.** Compression rates of AVH (%) in the pre- and post-operative period.

Group	Cases	Pre-operation	1 day after Operation	3 months after Operation
A	32	13.16 ± 10.91	7.97 ± 5.43	12.49 ± 7.75
B	30	17.06 ± 9.14	10.58 ± 6.21	11.25 ± 3.65
P value		.133	.082	.418

AVH: anterior vertebra height.

**Table 4.** Compression rates of PVH (%) in the pre- and post-operative period.

Group	Cases	Pre-operation	1 day after Operation	3 months after Operation
A	32	4.50 ± 3.85	4.34 ± 5.27	4.44 ± 4.39
B	30	6.34 ± 4.13	5.37 ± 4.02	3.33 ± 2.38
P value		.075	.390	.226

PVH: posterior vertebra height.

**Table 5.** Leakage rates and locations.

Group	Leakage Rate	Paravertebra	Disc Space	Peripheral Vein	Epidural Space
A	4/32	2	1	1	0
B	10/30	4	5	1	0
P value	.049*				

\*Significance between the 2 groups,  $P < .05$ .

comparison with the pre-operative period. The compression rates of AVH before PVP were higher than that after surgery in both groups, which decreased 1 day after surgery, and then slightly increased 3 months after surgery. There was no significant difference in the compression rates between the 2 groups ( $P > .05$ ) (Table 3).

The compression rates of PVH were lower than that of AVH. It was obvious that compression rates of PVH of the 2 groups both decreased after PKP. However, no significant difference was observed between the 2 groups ( $P > .05$ ) (Table 4).

### Leakage Rates and Locations

The leakage rate of Group A was 4/32, and of Group B 10/30. There was a significant difference between the 2 groups ( $P < .05$ ). Leakage occurred mainly in the paravertebra and disc space. No leakage occurred in epidural space (Table 5).

## Discussion

Making PKP safer requires innovation in aspects such as surgical procedures, instruments, and biological materials. Changing the formula of bone cement has always been one of the focuses. Scholars tend to divide bone cement into 2 different types, high-viscosity bone cement

and low-viscosity bone cement, and then analyze their clinical efficacy and safety.<sup>14-17</sup> Guo et al<sup>18</sup> pointed out that compared with low-viscosity bone cement, high-viscosity bone cement had no difference in clinical efficacy and had a lower cement leakage rate. Ran Lador et al<sup>19</sup> found out that PVP with high viscosity bone cement resulted in less chance of leakage to endplates and vessels. Such research about PVP is concise and often draws convincing conclusions. However, in the surgical treatment of OVCF, PKP has become more popular in many hospitals. Many scholars believe that PKP is safer than PVP.<sup>20-23</sup> In clinical research of different bone cement, many scholars adopted PVP as the surgical plan rather than PKP.<sup>16,18</sup> Therefore, we know little about PKP with high- and low-viscosity bone cement for the treatment of OVCFs. With population ages, the number of patients with OVCF is rapidly increasing. There is an astonishing number of cases performed PKP every year. How to further improve PKP is still a problem that doctors have been thinking about and trying to resolve. Therefore, we hope our study could add something to the existing literature about PKP and bone cement.

It is believed that PKP can restore the height of the vertebral body and regain the stability of the vertebra. The compression rate of AVH is a good indicator.<sup>17,18</sup> Consistent with some research on PVP, PKP with high-viscosity bone cement reconstructed the height of the

vertebral body and reduce the compression rate of AVH in our study. Additionally, we deliberately analyzed PVH and used the compression rate of PVH as another indicator of vertebral height recovery. Some scholars may think that the analysis of the compression rate of PVH does not make much sense. As we performed surgery, the closer the needle was to the spinal canal, the smaller the amount of cement was injected for safety. However, according to the three-column theory, the spine can be divided into the anterior column, middle column, and posterior column.<sup>24</sup> It is the middle column that determines the stability of the spine. PVH is a typical representative of the middle column. Therefore, we measured both AVH and PVH and calculated the compression rates of AVH and PVH. We found that both compression rates of AVH and PVH improved at 1 day and 3 months after surgery and the compression rates of AVH and PVH increased to varying degrees at 3 months compared with 1 day after PKP. For this phenomenon, not taking drugs to prevent osteoporosis after surgery may be one of the important reasons.

In terms of pain relief and rehabilitation, VAS and ODI scores of the 2 groups both decreased significantly after the operation. However, there was no significant difference in VAS and ODI scores between the 2 groups at 1 day, 1 month, and 3 months after surgery. It could be clearly found that PKP with high-viscosity and low-viscosity bone cement can both alleviate the patient's pain and improve the rehabilitation of patients. In terms of safety, bone cement leakage may result in unsatisfactory outcomes. It was reported that cement leakage caused disc herniation and influenced the rate of progression of disc degeneration, not to mention leakage into epidural space, or major vascular leakage.<sup>25,26</sup> PKP with high-viscosity bone cement had a lower leakage rate than low-viscosity cement. Many factors resulted in bone cement leakage, such as injection approach, cement volume, fracture level, and cement viscosity.<sup>27</sup> In addition, technical proficiency was an important factor and leakage can be avoided through standardized operations. To sum up, PKP with high-viscosity bone cement achieved good clinical efficacy and safety.

From our perspective, it is quite difficult to accurately compare high-viscosity and low-viscosity bone cement. There are many points which need to be solved or improved. Firstly, the viscosity of the bone cement is constantly changing during the operation. Gisep A et al showed the time-viscosity-injection pressure curve.<sup>28</sup> When the bone cement is injected into the vertebral body, it is usually in the "doughy state". The time point of injecting cement is judged by the subjective consciousness of the same group of surgeons. Unfortunately, there is no objective physical indicator to measure the cement viscosity in the "doughy state" and the change of cement viscosity after injection into the vertebral body could be even more unmeasurable.

Secondly, both in PVP and PKP, viscosity is not the only variable. Due to the different bone cement formulations, there are many changes in the surgery, including viscosity, injection time, heat released... The changes in these variables all contribute to the efficacy and safety. Therefore, although we controlled many variables, unknown variables or factors still affect the results. However, we believe that the effect of cement viscosity on PKP will be fully explained with further and deeper research.

We acknowledge several limitations in our study. Our study only included 62 patients which is a small size. A large study with long-term follow-up is needed to verify the conclusions. This study focuses on PKP with the viscosity of bone cement and other relevant variables and factors that need to be further studied. In addition, more formulations of bone cement need to be studied. Randomized controlled trials in the multicenter will also be necessary to evaluate the clinical efficacy and safety of bone cement in PKP in the future.

## Conclusions

According to our research, PKP with high-viscosity bone cement relieved pain, improved recovery, restored the height of the vertebral body, and had a lower leakage rate. High-viscosity bone cement is recommended in PKP for the treatment of OVCFs.

## Acknowledgments

We thank the staff at the Department of Orthopedics, the First Affiliated Hospital of Soochow University, and all the patients.

## Authors' Contributions

HY and TL was responsible for designing and planning of the study. All authors were involved in preparing and planning of the data analyses. WW, HL, ZW, YT performed the statistical analyses. WW drafted the first manuscript with contributions from the other authors. All authors read and approved the manuscript.

## Availability of Data and Materials

The datasets used during the current study are available from the corresponding author on reasonable request.

## Declaration of Conflicting Interests

The author(s) declared no potential conflicts of interest with respect to the research, authorship, and/or publication of this article.

## Ethics Approval

The research was approved by the ethics board of The First Affiliated Hospital of Soochow University. All methods were carried out in accordance with relevant guidelines and informed consent was obtained from all participants.

## Funding

The author(s) disclosed receipt of the following financial support for the research, authorship, and/or publication of this article: This work was supported by the National Natural Science Foundation of China (No. 82072476) and the Natural Science Foundation of Jiangsu Province (No. BK20191173).

## References

- Benyamin R, Vallejo R. Vertebroplasty. *Tech Reg Anesth Pain Manag.* 2005;9:62-67.
- Kim KW, Cho KJ, Kim SW, Lee SH, An MH, Im JH. A nation-wide, outpatient-based survey on the pain, disability, and satisfaction of patients with osteoporotic vertebral compression fractures. *Asian Spine J.* 2013;7(4):301-307.
- Venmans A, Klazen CA, Lohle PN, Mali WP, van Rooij WJ. Natural history of pain in patients with conservatively treated osteoporotic vertebral compression fractures: results from VERTOS II. *AJNR Am J Neuroradiol.* 2012;33(3):519-521.
- Ryska P, Málek V, Klzo L, et al. Perkutánní vertebroplastiky [Percutaneous vertebroplasty]. *Cas Lek Cesk.* 2005;144(9):620-623.
- Peh WC, Gelbart MS, Gilula LA, Peck DD. Percutaneous vertebroplasty: Treatment of painful vertebral compression fractures with intraosseous vacuum phenomena. *AJR Am J Roentgenol.* 2003;180(5):1411-1417.
- Kim YJ, Lee JW, Kim KJ, et al. Percutaneous vertebroplasty for intravertebral cleft: Analysis of therapeutic effects and outcome predictors. *Skeletal Radiol.* 2010;39(8):757-766.
- Nakamae T, Fujimoto Y, Yamada K, Hashimoto T, Olmarker K. Efficacy of percutaneous vertebroplasty in the treatment of osteoporotic vertebral compression fractures with intravertebral cleft. *Open Orthop J.* 2015;9:107-113.
- Takahara K, Kamimura M, Moriya H, et al. Risk factors of adjacent vertebral collapse after percutaneous vertebroplasty for osteoporotic vertebral fracture in postmenopausal women. *BMC Musculoskel Disord.* 2016;17:12.
- Zhou X, Meng X, Zhu H, Zhu Y, Yuan W. Early versus late percutaneous kyphoplasty for treating osteoporotic vertebral compression fracture: A retrospective study. *Clin Neurol Neurosurg.* 2019;180:101-105.
- Huang X, Chang H, Xu H, Chen X, Wang H, Song Y. Comparison of outcomes between percutaneous vertebroplasty and percutaneous kyphoplasty for the treatment of kummell's disease: A meta-analysis. *Clinical spine surgery.* 2021;35:276-286. doi:10.1097/BSD.0000000000001269.
- Watts NB, Harris ST, Genant HK. Treatment of painful osteoporotic vertebral fractures with percutaneous vertebroplasty or kyphoplasty. *Osteoporos Int.* 2001;12:429-437.
- Wang CH, Ma JZ, Zhang CC, Nie L. Comparison of high-viscosity cement vertebroplasty and balloon kyphoplasty for the treatment of osteoporotic vertebral compression fractures. *Pain Physician.* 2015;18(2):E187-E194.
- Zhang ZF, Yang JL, Jiang HC, et al. An updated comparison of high- and low-viscosity cement vertebroplasty in the treatment of osteoporotic thoracolumbar vertebral compression fractures: A retrospective cohort study. *Int J Surg.* 2017;43:126-130.
- Zhang L, Wang J, Feng X, et al. A comparison of high viscosity bone cement and low viscosity bone cement vertebroplasty for severe osteoporotic vertebral compression fractures. *Clin Neurol Neurosurg.* 2015;129:10-16.
- Tang S, Fu W, Zhang H, Zhang H, Liang B. Efficacy and safety of high-viscosity bone cement vertebroplasty in treatment of osteoporotic vertebral compression fractures with intravertebral cleft. *World neurosurgery.* 2019;132:e739-e745.
- Anselmetti GC, Zoarski G, Manca A, et al. Percutaneous vertebroplasty and bone cement leakage: Clinical experience with a new high-viscosity bone cement and delivery system for vertebral augmentation in benign and malignant compression fractures. *Cardiovasc Intervent Radiol.* 2008;31(5):937-947.
- Li K, Feng H, Luo D, et al. Efficacy and safety of high-viscosity cement in percutaneous vertebroplasty for treatment of Osteoporotic vertebral compression fractures: A retrospective cohort study. *Medicine.* 2020;99(23):e20515.
- Guo D, Cai J, Zhang S, Zhang L, Feng X. Treating osteoporotic vertebral compression fractures with intraosseous vacuum phenomena using high-viscosity bone cement via bilateral percutaneous vertebroplasty. *Medicine.* 2017;96(14):e6549.
- Lador R, Liberman S, Ben-Galim P, Dreiangel N, Reitman CA, Hipp JA. A cadaver study to compare vertebral augmentation with a high-viscosity cement to augmentation with conventional lower-viscosity cement. *J Spinal Disord Tech.* 2013;26(2):68-73.
- Tan B, Fan B, Qi-Yuan Y, et al. Unilateral vertebroplasty and kyphoplasty by digital subtraction angiography for the treatment of osteoporotic vertebral compression fractures. *Zhong Guo Gu Shang.* 2021;34:710-716.
- Li Y, Feng X, Pan J, et al. Percutaneous vertebroplasty versus kyphoplasty for thoracolumbar osteoporotic vertebral compression fractures in patients with distant lumbosacral pain. *Pain Physician.* 2021;24(3):E349-E356.
- Yu D, Liu Z, Wang H, et al. Analysis on the effect of different surgical methods on the treatment of senile osteoporotic spinal compression fractures and the influencing factors of complications. *Evid Based Complement Alternat Med eCAM.* 2021;2021:1599470-1599478.
- Zhang B, Chen G, Yang X, Fan T, Chen Z. Percutaneous kyphoplasty versus percutaneous vertebroplasty for neurologically intact osteoporotic kummell's disease: a systematic review and meta-analysis. *Global Spine J.* 2021;12(2):308-322.
- Su Q, Li C, Li Y, et al. Analysis and improvement of the three-column spinal theory. *BMC Musculoskel Disord.* 2020;21(1):537.

25. Tzeng SW, Chen CL. Herniated disc of lumbar spine caused by bone cement leakage after kyphoplasty - A case report and literature review. *Int J Surg Case Rep.* 2021;88:106478.
26. Jamjoom B, Patel S, Bommireddy R, Klezl Z. Impact of the quantity of intradiscal cement leak on the progression of intervertebral disc degeneration. *Ann R Coll Surg Engl.* 2017;99(7):529-533.
27. Zhu SY, Zhong ZM, Wu Q, Chen JT. Risk factors for bone cement leakage in percutaneous vertebroplasty: A retrospective study of four hundred and eighty five patients. *Int Orthop.* 2016;40(6):1205-1210.
28. Gisep A, Boger A. Injection biomechanics of in vitro simulated vertebroplasty - correlation of injection force and cement viscosity. *Bio Med Mater Eng.* 2009;19(6):415-420.