



# Treatment strategies for scapular spine fractures: a scoping review

Julia Sußiek\*

Philipp A. Michel\*

Michael J. Raschke

Benedikt Schliemann

J. Christoph Katthagen

- Fractures of the scapular spine are relatively rare and can occur without (1) or with (2) association to a reverse shoulder arthroplasty (RSA). To date there are only limited data on the topic. The aim of this scoping review was to identify all available literature and report current treatment concepts.
- A scoping review was conducted by searching PubMed for relevant studies between 2000 and October 2020. All studies were included which gave detailed descriptions of the treatment strategy.
- A total of 21 studies with 81 patients were included for the analysis. The mean age over all patients was 62 years (range: 24 to 89 years) and 77% of the patients were female. In 19.8% of cases, the fracture occurred after a traumatic fall from standing height. Eighty-six per cent of the patients had an RSA-associated scapular spine fracture (2). These patients were older compared to group (1) ( $47 \pm 19.6$  vs.  $76 \pm 5.6$  years,  $p = 0.0001$ ) and the majority were female (85%). The majority from group (1) underwent operative treatment with plate fixation. Most patients regained full function and range of motion. RSA-associated fractures (2) were mainly treated non-operatively, with moderate clinical outcome. A high rate of nonunions was reported.
- Scapular spine fractures without RSA are mainly treated operatively with good clinical results. In association with RSA, scapular spine fractures are mainly treated non-operatively and lead to inferior clinical and radiological results. This scenario seems to be problematic and further research is required to sharpen treatment concepts in this group.

**Keywords:** reverse shoulder arthroplasty; scapular fracture; scapular spine fracture

Cite this article: *EFORT Open Rev* 2021;6:788-796.

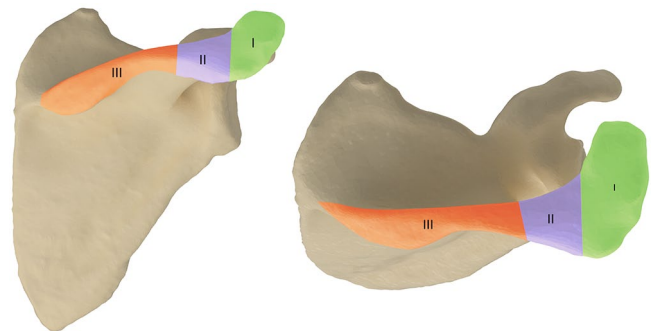
DOI: 10.1302/2058-5241.6.200153

## Introduction

Scapular fractures are relatively rare and account for only 0.3–1.7% of all fractures.<sup>1</sup> A scapular spine fracture is a subtype accounting for 6–11% of all scapula fractures.<sup>2,3</sup> According to the classification system introduced by Euler and Rüedi, those fractures can be classified as type B1.<sup>4</sup>

Aetiologically, a scapular spine fracture can either occur without<sup>1</sup> or with<sup>2</sup> association to a reverse shoulder arthroplasty (RSA). The latter can be classified as type III fractures (according to Levy et al) located at the base of the scapular spine (Fig. 1).<sup>5</sup> The overall incidence of acromial and scapular fractures associated with RSA varies between 0.8 and 10.2%.<sup>6</sup>

To date, very few data are available on treatment concepts of fractures of the scapular spine. There is no consensus as to whether operative or non-operative treatment is superior. Furthermore, it is unclear whether the two scenarios – fracture with or without RSA – might profit from a differentiated treatment algorithm. This is of



**Fig. 1** Classification system of acromial and scapular spine fractures in association with a reverse shoulder arthroplasty (RSA) introduced by Levy et al.<sup>5</sup> I and II are defined as acromial fractures, III are defined as scapular spine fractures.

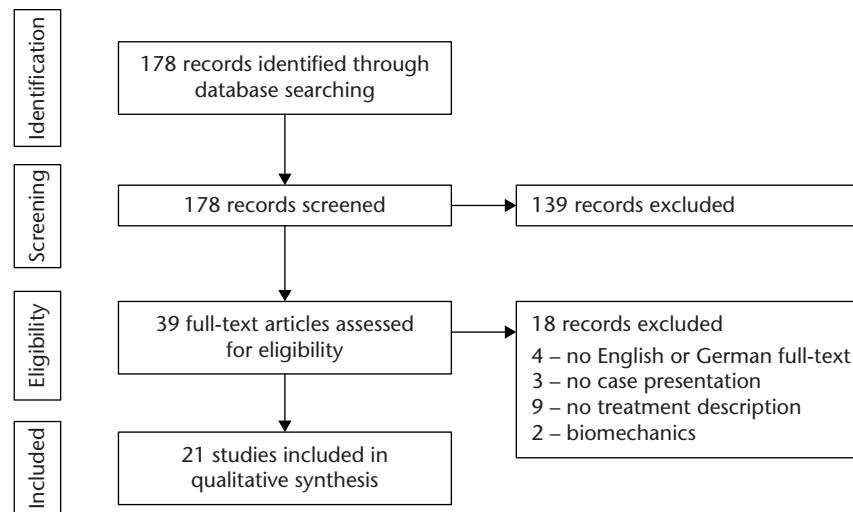


Fig. 2 Literature search profile.

great interest as we have experienced a rapid increase in the number of patients treated with RSA over the past decade.<sup>7</sup>

The aim of this scoping review is to identify the available literature with detailed treatment concepts on scapular spine fractures and report epidemiological data, fracture aetiology, patient-related and radiological outcomes, as well as frequent complications. The hypothesis was that non-operative treatment leads to a higher nonunion rate and a decreased shoulder function.

## Methods

The scapular spine fracture is a rare entity and the available data limited. Methodologically we therefore opted for a scoping review. The purpose of a scoping review is to identify knowledge gaps, scope a body of literature, clarify concepts or to investigate research conduct.<sup>8</sup>

The PubMed database was searched for studies published between 2000 and October 2020 using the keywords scapula\* spine fracture. Studies with the following criteria were included:

- detailed description of the treatment strategy for fractures of the scapular spine
- reporting patient-related outcome data

The applied exclusion criteria were as follows:

- full text not published in English or German language
- no detailed presentation of treatment modalities
- pathologic fractures
- fractures in children

- surgical technique descriptions and reviews not presenting own cases

The initial literature search identified 178 papers of which 21 were included in the final analysis (see Fig. 2).

For the remaining studies, we used a standardized extraction form to collect the following data:

- epidemiological data:
  - number of patients with scapular spine fractures
  - age
  - gender
  - fracture aetiology
- treatment-associated data:
  - fracture type
  - treatment type
  - mean clinical follow-up (in months)
  - initial function after fracture
  - functional outcome at follow-up
  - radiological outcome
  - RSA type

The studies were divided into two major groups:

- (1) scapular spine fractures in patients *without* RSA
- (2) scapular spine fractures in patients *with* RSA

## Statistics

For the epidemiological and treatment-related outcome data we assumed a standard (Gaussian) distribution. We therefore applied the t-test and the chi-square test. Missing information are stated as such within the tables. Significance was set at  $p > 0.05$ .

**Table 1.** Epidemiological data comparing patients with scapular spine fractures with and without reverse shoulder arthroplasty (RSA)

	Scapular spine fractures in patients without RSA (1)	Scapular spine fractures in patients with RSA (2)	Statistics
Total patients	12	69 (72*)	
Age (years)	47 ± 16.6	76 ± 5.6	p < 0.0001#
Male	8 (66.7%)	11* (15.0%)	p < 0.0001+
Female	4 (33.3%)	61* (85.0%)	p < 0.0001+
<b>Fracture aetiology</b>			
Accident	4 (33.3%)	0 (0.0%)	
Traumatic fall	4 (33.3%)	12 (17.3%)	
Heavy object on shoulder	1 (8.3%)	0 (0.0%)	
Sudden pain without trauma	3 (25.0%)	12 (17.3%)	
NF	0 (0.0%)	45 (65.2%)	

\*Including three acromion fractures, due to missing gender specification in Ascione et al.

#t-test.

+chi-square test.

## Results

### Epidemiological data

The 21 studies which met the inclusion criteria reported a total of 83 fractures of the scapular spine in 81 patients. The mean age over all patients was 62 years (range: 24 to 89 years) and 65 (77.4%) of the patients were female. In 16 patients (19.8%) the fracture occurred after a traumatic fall from standing height, which made this the leading fracture cause. Fifteen patients (18.5%) reported sudden pain without trauma. No specific information on the fracture cause was reported in 45 patients (55.5%).

Of the patients in our study collective, 85.2% had an RSA-associated scapular spine fracture. Detailed epidemiological data comparing the two groups without <sup>1</sup> and with <sup>2</sup> RSA are shown in Table 1. In summary the patient cohort <sup>2</sup> with RSA is older (47 ± 19.6 vs. 76 ± 5.6 years, p = 0.0001) and the majority of the patients are female.

### Treatment-associated data for scapular spine fractures in patients without RSA (1)

Ten studies including 12 patients reported the treatment strategies for patients who had sustained a fracture without RSA (1) (Table 2).

Two studies with four patients described a non-operative treatment. Morioka et al presented two young patients who had sustained incomplete avulsion fractures. Treatment consisted of immobilization in a sling. The fractures healed completely and the patients had no restrictions in the range of motion.<sup>9</sup> Groot et al presented a case report with two women who each sustained a fracture without any trauma. Due to their pre-existing conditions both patients were treated non-operatively. This consisted of physiotherapy, ultrasound bone growth stimulation and corticosteroid injections. In both cases the fracture did not heal and the range of motion was severely restricted.<sup>10</sup>

Eight studies including eight patients presented operative treatment with plate fixation. Locking compression

plates (LCP)<sup>11,12</sup> or limited contact dynamic compression plates LCDCP<sup>13,14</sup> were used most frequently. In three reports, the authors used bone grafts in addition to the plates for patients with delayed union or nonunion.<sup>11,13,14</sup> At the final follow-up six patients regained full function and range of motion.<sup>11,13-17</sup> Two patients had limited range of motion compared to the unaffected side or a decreased activity level.<sup>12,18</sup> Concerning the radiographic results at the final follow-up, four patients showed complete fracture healing.<sup>11,13-15</sup> For the remaining four patients no radiographic results were reported. In two cases the plates were removed due to implant-associated irritations.<sup>16,17</sup>

Summary for treatment of scapular spine fractures without RSA (1):

- Four out of 12 patients were treated non-operatively with sling-immobilization;
  - o two of these patients showed a nonunion with a resulting limited range of motion.
- Eight out of 12 patients were treated operatively with plate fixation;
  - o seven of these patients regained full function and range of motion,
  - o four showed radiologically complete fracture healing.

### Treatment-associated data for scapular spine fractures in patients with RSA (2)

Eleven studies including 69 patients reported a fracture of the scapular spine with RSA (2) (Table 3).

Eight studies with 62 patients described non-operative treatment. In three studies the patients' shoulders were immobilized with an abduction splint for six weeks,<sup>19-21</sup> and for two studies the treatment consisted of immobilization in a sling.<sup>6,22</sup> In the remaining studies treatment consisted of pain medication and/or physiotherapy.<sup>23-25</sup> Nearly all patients remained limited in their shoulder function at the final follow-up. Functional scores were slightly improved compared to the initial score. Most authors chose the functional situation before the RSA implantation

**Table 2.** Summary of studies with scapula spine fractures in patients *without* reverse shoulder arthroplasty (RSA) (1)

Author	Year	Number of patients	Fracture type	Treatment type	Mean clinical follow-up (months)	Initial function after fracture	Functional outcome at follow-up	Radiological outcome
Groot <sup>12</sup>	2012	2	NF	Case 1: Physiotherapy, subacromial and intra-articular corticosteroid injection, ultrasound bone growth stimulation Case 2: Subacromial corticosteroid injections. 10 months after onset of pain: circumduction exercises and ultrasound bone growth stimulation	NF	Initial presentation after fracture Case 1: Active FF 100°, ABD: 100°, ER: 45°, Loss of abduction strength Case 2: Active GHABD: 90°, ER: 30°	Case 1: Stiff shoulder with pain treated with analgesics Case 2: ABD: 60° ER: 0°	Case 2: 3-months follow-up radiograph: progressive callus formation but no sign of consolidation
Morioka <sup>9</sup>	2014	2	1x incomplete fracture	Case 1: Immobilization in a sling for 1 week, then passive range of motion exercises & ADL Case 2: Patient was allowed to use the affected upper extremity, after 3 weeks: passive ROM exercises after 8 weeks: isotonic muscular strength exercises	84	Initial presentation after fracture Case 2: No limitation in the passive ROM, drop arm sign positive	Case 1: 8 weeks: no limitation in range of motion, no drop arm signs, no pain. 10 years after the accident – asymptomatic Case 2: 4 months: no limitation in range of motion, no pain during resistive movement. 4 years after the accident: asymptomatic	Case 1: Radiogram: concurrent resorption and osteogenic changes along the fracture line Case 2: 4 months after injury: complete bone union
As-Sultany <sup>13</sup>	2008	1	Minimally displaced scapular spine fracture at the base of the acromion and entering the spino-glenoid notch	6 months' conservative treatment: immobilization in a sling and analgesics – nonunion of the fracture. Then ORIF: 6 hole LCDCP plate and 6 cortical screws + bone graft	5 months post-operative	ABD: 90°, FF: 90°, ER & IR: no restriction	Full painless function	3 months post-operative radiograph: complete fracture healing
Cabot <sup>18</sup>	2019	1	Comminuted & displaced fracture of the scapular spine & body with an avulsion of the acromion base and free-floating fragments	ORIF: Zimmer Biomet elbow plate	7	NF	Mild pain with terminal motion lacked in all directions, mild weakness compared to contralateral side	Last radiograph: Maintained alignment of the acromion process without implant failure
Copuroglu <sup>11</sup>	2014	1	Nonunion of the scapular spine	ORIF: 8-holed LCP plate + bone graft	24	FF: 90° Passive, ABD: 90°, IR & ER: comfortable, VAS: 8	Pain-free VAS: 1	Radiographs 24 months post-operative: complete union
Hackl <sup>12</sup>	2015	1	Dislocation of the scapular spine greater than 5 mm	ORIF: 3.5 mm 5-hole LCP distal humerus plate dorsolateral right (Synthes); lag screw over the plate for additional fracture compression	12	NF	CMS: 94 ABD strength: 10 kg (unaffected arm: 11.5 kg) IR: remained limited	NF
Karthik <sup>14</sup>	2014	1	Bilateral stress fractures of the spine of scapula, left side significantly displaced with no evidence of healing	Right side: conservative treatment Left side: after 2 months conservative treatment – ORIF: 3.5 mm LCDCP (Synthes) + bone graft	24	Right: ABD: 30°, FF: 30°, IR: T7, ER: 0°, VAS: 8 Left: ABD: 30°, FF: 30°, IR: T7, ER: 0°, VAS: 10	Right: ABD: 60° FF: 80° IR: Iliac crest ER: 4° VAS: 1–3 Left: ABD: 60° FF: 70° IR: Iliac crest ER: 40° VAS: 1–3 Final DASH Score: 30.8 Final Oxford Shoulder Score: 30	Left: CT scan: bony union
Kembhavi <sup>15</sup>	2015	1	Scapular spine fracture with acromioclavicular joint disruption	ORIF: 8-holed 3.5 recon titanium plate	7	NF	Good functional outcome, near-normal range of movements CMS: 96	Radiograph: complete union CT: minimal persistence of AC joint opening
Nunes <sup>16</sup>	2019	1	Fracture of the lateral angle of the spine of the scapula (Ogawa 3, Hunt 3)	ORIF: Locked plate of mini fragments with 4 cortical screws	NF	NF	Shoulder movements in ABD, anterior elevation & rotation normal	NF
Ogawa <sup>17</sup>	2018	1	Displaced scapular spine fracture	ORIF: reconstruction plate, screws, transosseus wire loops	144	AFE: 10°, ER: 5°, IR: L4	Left shoulder compared to right shoulder: AFE: 5° ER: 5° IR: 2 vertebrae ABD: 15° Manual muscle test score: adduction, flexion, internal rotation: 5 external rotation: 4 DASH 4.2 CMS ratio compared with right shoulder 95%	NF

Notes. FF, forward flexion; AFE, active forward elevation; ER, external rotation; IR, internal rotation; ABD, abduction; ADL, activities of daily living; ROM, range of motion; VAS, Visual Analogue Scale for pain; CMS, Constant–Murley Score; GHABD, glenohumeral abduction; NF, not found; ORIF, open reduction internal fixation; LCP, locking compression plate; LCDCP, limited contact dynamic compression plate; DASH, Disabilities of Arm, Shoulder and Hand questionnaire; CT, computer tomography; AC, acromioclavicular.

**Table 3.** Summary of studies with scapula spine fractures in patients with reverse shoulder arthroplasty (RSA) (2)

Author	Year	Number of patients	Fracture type	Treatment type	Mean clinical follow-up (months)	Initial function after fracture	Functional outcome at follow-up	Radiological outcome	RSA type
Ascione <sup>19</sup>	2018	18	Type II and III according to Levy	Abduction splint for 6 weeks for pain relief	16.3 ± 6.5  *Including 3 Acromion fractures and 2 operatively treated spine fractures	CMS 21.1 ± 11.3 FF 58 ± 36 ER 6 ± 12 (before the RSA implantation)	CMS 35 FF 105° ER 20°	NF	Aequalis Ascend Flex prosthesis (Tornier, Bloomington, MN, USA)
Burkholz <sup>23</sup>	2007	1	Mildly displaced scapula spine fracture	Rest, analgesic and physical therapy	36	Active elevation: 20° Active ABD: 20° (after the fracture)	Persistent pain at shoulder movement	6 months' post-op radiographs: mild progressive inferior displacement of the fracture	NF
Familiari <sup>24</sup>	2014	1	Acute fracture of the scapular spine	Pain medication shoulder motion as tolerated. Because patient was not interested in surgical intervention, this fracture was treated non-operatively	11	NF	No complete fracture healing, no pain	CT 8 months post-operative: nonunion of scapular fracture	NF
Hattrup <sup>22</sup>	2010	6	NF	Sling, followed by physiotherapy as the pain allowed	30.4	VAPS: 7.2 Flexion: 57° Abduction: 54° ER: 24° ASES: 24.4 SST: 2.2 (before the RSA implantation)*	VAPS: 4 Flexion: 97° Abduction: 90° ER: 42° ASES: 48.5 SST: 5.1*	Only one case showed radiographic signs of fracture healing	Delta III (Depuy Orthopedics, Warsaw, USA) or Trabecular Metal Reverse Prostheses (Zimmer, Inc., Warsaw, USA)
Neyton <sup>20</sup>	2019	9	NF	Immobilization with an abduction splint for 6 weeks for pain relief; patients were asked to resume daily activities as tolerated after the period of immobilization*  * 3 patients received no treatment as their fracture was only detected at the last follow-up X-ray control (asymptomatic fracture)	110.7	CMS: 24.3 ± 11.2 (2–40) AFE: 61 ± 30.5 (50–160) Pain 4.4 ± 2.8 (0–10) (before the RSA implantation)	CMS: 41.3 ± 23.4 (8–79) AFE: 100 ± 41.2 (50–160) Pain 9.8 ± 5.6 (0–15)	4x healed fracture 5x nonunion – 2 of them underwent ORIF after nonunion	Aequalis reversed (Tornier, Bloomington, MN, USA) Delta (DePuy, Warsaw, IN, USA) or Aequalis fracture long stem (Tornier, Bloomington, MN, USA); 4 fixation screws
Nicolay <sup>25</sup>	2014	1	Bilateral fracture	Conservative treatment with active and passive physiotherapy	4	NF	No pain, never regained complete shoulder function	NF	Delta X-tend™ (DePuy Synthes, Warsaw, USA)
Routman <sup>6</sup>	2020	18	Type III according to Levy	Conservative treatment with a sling and abduction pillow	27.8	CMS: 35.6 ABD: 70.4 ± 48.8° AFE: 75.5 ± 40.8° IR: 4.0 ± 1.8° ER: 27.2 ± 22.0° (before the RSA implantation)	CMS: 47.8 ABD: 86.3 ± 39.3° AFE: 95.4 ± 41.8° IR: 3.7 ± 1.8° ER: 34.1 ± 25.3°	NF	NF
Teusink <sup>21</sup>	2014	8	NF	Sling immobilization for 6 weeks & then advancing activities as tolerated	50*  *including 17 acromion fractures	Flexion: 67° ABD: 57° ER: 25° (before the RSA implantation)*	Flexion: 92° ABD: 80° ER: 25° VAS pain score: 2.3 (range 0–6) ASES final: 53.8*	4 patients had radiographic follow-up > 1 year → 2 fractures healed, 2 fractures showed no healing	Reverse Shoulder Prosthesis (DJO Surgical, Austin, TX, USA)
Bauer <sup>28</sup>	2020	1	Displaced fracture	ORIF: Double plating in 90/90 configuration 3.5/2.7 mm lateral clavicular plate (Synthes/LCP) and 2.4 mm straight LCP (Synthes/compact food set)	12	NF	CMS: 67 AFE: 140° ABD: 140° ER: 30° IR: L5 No pain, slight discomfort	Fracture union	Reversed II
Debeer <sup>26</sup>	2005	1	Displaced fracture	ORIF: 7-hole 1/3 tubular plate, contoured over the scapular spine	2	After RSA with fracture: nearly complete loss of function of the deltoid muscle	Pain-free, same active & passive mobility as before the fall	NF	Delta III (DePuy, Warsaw, IN, USA)
Toft <sup>27</sup>	2019	5	2x acute fracture 2x delayed union 1x nonunion	ORIF: double plating in 90/90 configuration 5 or 6-hole quarter tubular plate at the caudal area of the scapular spine and 1x 5-hole LCP distal humerus plate + bone graft 1x VA-LCP olecranon plate 3x VA-LCP distal humerus plate + 3x bone graft	12	2 years after RSA implantation: CMS: 55.25 FF: 131° ABD: 106° ER: 32°*	CMS: 44.4 FF: 104° ABD: 88° ER: 28°	5x healed fracture	1x UniverseRevers® (Arthrex Swiss AG, Belp-Bern, Switzerland); 3x PROMOS® (Smith & Nephew Orthopedics AG, Rotkreuz, Switzerland); 1x SMRTM Reverse Modular Shoulder System (LimaCorporate S.p.a., Udine, Italy)

Notes. FF, forward flexion; AFE, active forward elevation; ER, external rotation; ABD, abduction; CMS, Constant–Murley Score; NF, not found; ORIF, open reduction internal fixation; LCP, locking compression plate; VA-LCP, variable angle locking compression plate; VAPS, Visual Analogue Pain Score; ASES, American Shoulder and Elbow Surgeons (ASES) score; SST, Simple Shoulder Test; CT, computer tomography; IR, internal rotation; VAS, Visual Analogue Scale for pain.

as the threshold of the initial functional score.<sup>6,19–22</sup> The radiological follow-up showed six healed fractures<sup>20,21</sup> and a partial fracture union for one patient.<sup>22</sup> For 14 patients the radiographic imaging revealed a nonunion,<sup>20–24</sup> of whom two underwent subsequent plate fixation. For 41 patients no radiographic results were available.

Three studies with seven patients reported operative treatment.<sup>26–28</sup> Toft et al reported a case series of five patients treated with two plates in 90/90° configuration. The patients achieved a higher Constant–Murley Score (CMS) compared to the situation before the RSA implantation, but three of four patients did not reach the same mobility level as before the fall (for one patient the information was not available). For two cases complications were recorded. One patient experienced a screw loosening after two weeks. Without any specific intervention the fracture healed, nevertheless. Another patient suffered from an intra-operative pneumothorax, according to the author most likely due to drill or K-wire perforation.<sup>27</sup>

Bauer et al also chose double plating for one patient, who sustained a fracture two weeks after the implantation of an RSA. Three weeks after the operative fracture fixation, an additional fracture of the acromion occurred. Nevertheless, a CT scan three months later revealed the union of the scapular spine fracture. The patient was satisfied and achieved good functional results.<sup>28</sup> In the third study, Groot et al presented a case report with a patient who was treated with plate fixation. After the follow-up the patient was pain free and reached the same mobility level as before the fall.<sup>10</sup> For six out of seven patients the radiographic imaging revealed a fracture union, for one patient no information on the radiological results were available.

Summary for treatment of scapular spine fractures *with* RSA (2):

- 62 out of 69 patients were treated non-operatively with abduction splint or sling;
  - nearly all patients remained limited in their shoulder function,
  - seven patients showed complete or partial union, 14 patients nonunion, while for 41 patients no radiographic results were available.
- Seven out of 69 patients were treated operatively with plate fixation:
  - heterogenous operative procedures (number and design of plates),
  - limited shoulder function was reported in three cases,
  - six patients showed radiographic healing.

## Discussion

Patients with scapular spine fractures can be divided into two groups (those with and without RSA). Our study showed that patient characteristics and treatment

strategies differ between the groups. Our hypothesis – that non-operative treatment leads to a higher nonunion rate and a decreased shoulder function – can only partially be confirmed. The limited availability of radiographic outcome data, especially in the non-operative RSA group (in 66.1% of the patients no information was found), makes valid comparisons impossible. A differentiation between the two scenarios is necessary.

Patients without RSA are typically younger males and the leading fracture cause is a high-energy accident or a traumatic fall. These findings are in line with the aetiology of scapular fractures as a concomitant effect of thoracic trauma with other corresponding injuries.<sup>29</sup> On the other hand, patients with RSA are on average older and female, and there is no distinct leading fracture cause. We found equal numbers of patients suffering from a traumatic fall or sudden pain without a trauma. The cause of RSA-associated scapular spine fractures is still controversial. Some authors consider them as traumatic (caused by another fall) or stress fractures due to increased deltoid strain.<sup>30</sup> Others believe that the design of the prosthesis with a different centre of rotation plays a role.<sup>31</sup> Nyffeler et al question the theory of an increased tension in the deltoid or a stress fracture in their recent study. The authors discuss the altered shape of the shoulder after implantation of an RSA with a greater exposition of the acromion and the scapular spine, which makes it more vulnerable to direct trauma.<sup>30</sup> Furthermore, Taylor et al hypothesized that the transection of the coracoacromial ligament (CAL), which is often performed for surgical exposure for prosthesis implantation, leads to higher strain on the scapular spine. In a recently published biomechanical study, they were able to show that the transection of the CAL results in significantly higher strain on the scapular spine during abduction movement.<sup>32</sup>

The majority of patients without RSA were treated operatively, although we could only identify case reports. Older studies (which were not in the scope for this review) reported tension band wiring, sometimes in combination with lag screws.<sup>33–35</sup> Nowadays all authors choose plate fixation, but differences concerning plate configuration can be detected. Lin et al report a wide variation in the anatomy of the scapular spine,<sup>36</sup> aggravating proper placement of the plate. In addition, differences in the mechanical properties of the implant configuration were noted. While some authors used locking plates,<sup>11,12,14</sup> others chose a non-locking screw configuration.<sup>13–18</sup> In a biomechanical study, Kicinski et al compared the construct stability for three different types of fracture fixation at the scapular spine. They created a fracture in an artificial bone model and fixation was achieved with either a lateral clavicular plate, a locking compression plate or a reconstruction plate. In this experimental setup, the LCP gave the best results.<sup>37</sup> Another biomechanical study, by Ting et al,



**Table 4.** Summary of treatment-related outcome data and complications

	Scapular spine fractures in patients without RSA (1)	Scapular spine fractures in patients with RSA (2)	Statistics
Total patients	12	69 (72*)	
<b>Non-operative</b>	4 (33.3%)	62 (89.9%)	p < 0.0001+
Radiographic outcome			
– healing	2 (50.0%)	6+1 partially healed (11.3%)	
– nonunion	2 (50.0%)	14 (22.6%)	
– NF	0 (0.0%)	41 (66.1%)	
Limited ROM	2 (50.0%)	62 (100.0%)	
<b>Operative</b>	8 (66.7%)	7 (10.1%)	p < 0.0001+
Radiographic outcome			
– healing	4 (50.0%)	6 (85.7%)	
– nonunion	0 (0.0%)	0 (0.0%)	
– NF	4 (50.0%)	1 (14.3%)	
Limited ROM	2 (25.0%)	3 (42.9%)	
Bone graft	4 (50.0%)	0	
Implant removal	2 (25.0%)	0	
Screw loosening	0	1 (14.3%)	
Pneumothorax	0	1 (14.3%)	
Peri-implant fracture	0	1 (14.3%)	

Notes. RSA, reverse shoulder arthroplasty; ROM, range of motion; NF, not found.  
 \*Including three acromion fractures, due to missing gender specification in Ascione et al.  
 +chi-square test.

reported that direct subcutaneous plating of the scapular spine is more stable than supraspinatus fossa plating.<sup>38</sup> In our cohort, the patients achieved good results concerning range of motion after operative treatment.<sup>13–17</sup> In only one case, the patient had a slightly limited range of motion and mild pain.<sup>18</sup> Radiographic fracture healing was achieved in four cases (while no information was available for the other four cases). In two cases the plates were removed due to local irritations.<sup>16,17</sup> Overall, no major complications were reported for operative treatment. Only one study reported non-operative treatment for full fractures (the study from Morioka et al reports avulsion fractures).<sup>9</sup> This resulted in an unfavourable outcome for both patients with pain and limited range of motion.<sup>10</sup>

In this small cohort, operative treatment with plate fixation of scapular spine fractures without RSA seems to be a safe treatment option for younger patients with high functional demands with good functional and radiographic outcomes. In contrast, the majority of patients with RSA were treated non-operatively. This consisted of immobilization with an abduction splint or sling for six weeks. Nearly all patients remained limited in their shoulder function at the final follow-up, although slight improvement in CMS was reported.<sup>19–22</sup> Information was very limited on exact values for range of motion. Radiological follow-up information was only available for 21 of the 62 patients. Seven patients showed complete or partial union,<sup>20–22</sup> while 14 patients were reported as nonunion.<sup>20–24</sup> The high number of patients without sufficient fracture union raises the question of whether fracture nonunion is a symptomatic pathology in every case. Only two of these patients underwent secondary operative treatment.<sup>20</sup>

Only three studies with seven patients reported operative treatment for elderly patients with a fracture after RSA

implantation.<sup>26–28</sup> Toft et al fixed the fracture using a double plate technique.<sup>27</sup> The range of motion improved after fracture fixation but did not reach the level before the fracture. Two patients suffered from complications (screw loosening and an iatrogenic pneumothorax). Likewise Bauer et al chose fracture fixation in a double plate technique.<sup>28</sup> At the final follow-up the patient was pain free and had only slight discomfort. Debeer et al presented a patient who underwent open reduction and internal fixation (ORIF) with a single plate.<sup>26</sup> After two months, he was pain free and had regained the same mobility level as before the injury.

These data indicate that the present treatment standard for scapular spine fractures with RSA is non-operative. This seems questionable, as the reported functional and radiological outcome are not quite satisfactory. Particularly older patients could possibly benefit from operative fracture fixation to provide a quick recovery of function and power.<sup>39</sup> The data on operative fixation in the RSA group yield a high rate of radiographic healing and acceptable functional outcomes. On the other hand, this cohort is mainly composed of older women, with a moderate functional demand. Another reason for the low rate of operatively treated fractures in this group might be the fear of an additional operation, which fuels the non-operative approach. Further research is required to define indication criteria for operative fracture fixation.

There are some limitations of this review. The available literature on the topic is very limited and mainly consists of case reports with small sample size. The largest cohorts were presented by Ascione et al and Routman et al each with 18 patients.<sup>6,19</sup> The maximum level of evidence was IV. Also, there are several studies, such as those by Nyffeler et al or Tashjian et al, which stated the complication of a scapular spine fracture in association with RSA but did

not give any detailed information on the exact treatment modalities.<sup>30,40</sup> Those studies were not in the scope of this review and therefore were excluded from further analysis.

Additionally, the available literature was difficult to compare, as many authors used different definitions and outcome parameters. Another limitation concerns the validity of the radiographic outcome. In the RSA group, radiological follow-up information was only available for 21 of the 62 patients. This scoping review can only give a broad overview of the current treatment concepts. General concepts drawn from this study must be assessed very carefully and validated with further research.

## Conclusion

The hypothesis – that non-operative treatment leads to a higher nonunion rate and a decreased shoulder function – can only partially be confirmed. Fractures of the scapular spine can occur with or without association to a reverse shoulder arthroplasty (RSA). Patients without an RSA are typically younger and have suffered from a high-energy accident. Standard treatment includes operative plate fixation and clinical and radiological results are quite satisfactory. Fractures associated with RSA are more common, typically in older patients with no or a low-energy trauma, such as a fall from standing height. Current treatment concepts are mainly non-operative. Functional outcome is impaired, although slight improvements are reported over time. The rate of radiological nonunion seems high compared to the operated group, although valid radiographic outcome data are scarce. Operative fixation is rarely performed, although clinical and radiological results seem promising. Further research is required to define indication criteria for operative fracture fixation in patients with scapular spine fractures and RSA.

### AUTHOR INFORMATION

Department of Trauma-, Hand- and Reconstructive Surgery, University Hospital Muenster, Muenster, Germany.

\*These authors contributed equally.

Correspondence should be sent to: Dr. med. Philipp A. Michel, Department of Trauma-, Hand- and Reconstructive Surgery, University Hospital Muenster, Waldeyer Str. 1, D-48149, Münster, Germany.  
Email: Philipp.Michel@ukmuenster.de

### ICMJE CONFLICT OF INTEREST STATEMENT

MJR reports monies paid via the AO Foundation for a board membership; a consultancy for Marquardt Medizintechnik and payment for lectures from AOTrauma Deutschland, for relevant financial activities outside the submitted work.

JCK reports consultancy fees paid by DePuy Synthes, SPI and AO Sports; grants pending from Arthrex GmbH and payments for lectures from Arthrex, IBRA, all for relevant financial activities outside the submitted work.

All other authors report no conflicts of interest.

### FUNDING STATEMENT

Although none of the authors has received or will receive benefits for personal or professional use from a commercial party related directly or indirectly to the subject of this article, benefits have been or will be received but will be directed solely to a research fund, foundation, educational institution, or other non-profit organization with which one or more of the authors are associated.

### OPEN ACCESS

© 2021 The author(s)

This article is distributed under the terms of the Creative Commons Attribution-Non Commercial 4.0 International (CC BY-NC 4.0) licence (<https://creativecommons.org/licenses/by-nc/4.0/>) which permits non-commercial use, reproduction and distribution of the work without further permission provided the original work is attributed.

### REFERENCES

1. Court-Brown CM, Caesar B. Epidemiology of adult fractures: a review. *Injury* 2006;37:691–697.
2. Armstrong CP, Van der Spuy J. The fractured scapula: importance and management based on a series of 62 patients. *Injury* 1984;15:324–329.
3. Ada JR, Miller ME. Scapular fractures: analysis of 113 cases. *Clin Orthop Relat Res* 1991;269:174–180.
4. Gilbert F, Eden L, Meffert R, et al. Intra- and interobserver reliability of glenoid fracture classifications by Ideberg, Euler and AO. *BMC Musculoskelet Disord* 2018;19:89.
5. Levy JC, Anderson C, Samson A. Classification of postoperative acromial fractures following reverse shoulder arthroplasty. *J Bone Joint Surg [Am]* 2013;95-A:e104, 1–7.
6. Routman HD, Simovitch RW, Wright TW, Flurin PH, Zuckerman JD, Roche CP. Acromial and scapular fractures after reverse total shoulder arthroplasty with a medialized glenoid and lateralized humeral implant: an analysis of outcomes and risk factors. *J Bone Joint Surg [Am]* 2020;102-A:1724–1733.
7. Garcia P, Domnick C, Lodde G, Raschke MJ. Operative treatment in orthopedics and trauma surgery: are more operations carried out in Germany? *Unfallchirurg* 2018;121:20–29.
8. Munn Z, Peters MDJ, Stern C, Tufanaru C, McArthur A, Aromataris E. Systematic review or scoping review? Guidance for authors when choosing between a systematic or scoping review approach. *BMC Med Res Methodol* 2018;18:143.
9. Morioka T, Honma T, Ogawa K. Incomplete avulsion fractures of the scapular spine caused by violent muscle contraction. *Keio J Med* 2014;63:13–17.
10. Groot D, Giesberts AM, van Mourik JB. Spontaneous scapular spine fracture related to rotator cuff pathology: a report of two cases. *Strateg Trauma Limb Reconstr* 2012;7:105–107.
11. Copuroglu C, Tan L, Copuroglu E, Ciftdemir M, Ozcan M. Pseudo-arthrosis of the spine of the scapula: a case report with a delayed diagnosis. *Strateg Trauma Limb Reconstr* 2014;9:173–177.
12. Hackl M, Moro F, Durchholz H. Combined displaced fracture of the lesser humeral tuberosity and the scapular spine: a case report. *Int J Surg Case Rep* 2015;13:106–111.
13. As-Sultany M, Tambe A, Clark DI. Nonunion of a scapular spine fracture: case report and management with open reduction, internal fixation, and bone graft. *Int J Shoulder Surg* 2008;2:64–67.
14. Karthik K, Lau J, Sinha J, Tavakkolizadeh A. Scapular spine stress fractures: to fix or not to fix, our experience in a patient with bilateral fractures and review of the literature. *Int J Shoulder Surg* 2014;8:90–93.



- 15. Kembhavi RS, James B.** Ipsilateral closed clavicle and scapular spine fracture with acromioclavicular joint disruption. *J Orthop Case Rep* 2015;5:58–61.
- 16. Nunes SR, Fernandes Filho MR, Fernandes MR.** Acromion fracture and lateral angle of the scapula spine: case report and literature review. *Int J Surg Case Rep* 2019;60:353–357.
- 17. Ogawa K, Inokuchi W, Matsumura N.** Delayed surgery for displaced fracture of the anatomic neck and spine of the scapula: a case report and literature review. *JSES Open Access* 2018;2:169–173.
- 18. Cabot JH, Dang KH, Dutta AK.** Free-floating scapular spine: a rare shoulder injury. *Case Rep Orthop* 2019;2019:1839375.
- 19. Ascione F, Kilian CM, Laughlin MS, et al.** Increased scapular spine fractures after reverse shoulder arthroplasty with a humeral onlay short stem: an analysis of 485 consecutive cases. *J Shoulder Elbow Surg* 2018;27:2183–2190.
- 20. Neyton L, Erickson J, Ascione F, Bugelli G, Lunini E, Walch G.** Grammont Award 2018: scapular fractures in reverse shoulder arthroplasty (Grammont style): prevalence, functional, and radiographic results with minimum 5-year follow-up. *J Shoulder Elbow Surg* 2019;28:260–267.
- 21. Teusink MJ, Otto RJ, Cottrell BJ, Frankle MA.** What is the effect of postoperative scapular fracture on outcomes of reverse shoulder arthroplasty? *J Shoulder Elbow Surg* 2014;23:782–790.
- 22. Hattrup SJ.** The influence of postoperative acromial and scapular spine fractures on the results of reverse shoulder arthroplasty. *Orthopedics* 2010;33:302.
- 23. Burkholz KJ, Roberts CC, Hattrup SJ.** Scapular spine stress fracture as a complication of reverse shoulder arthroplasty. *Radiol Case Rep* 2007;2:78–82.
- 24. Familiari F, Huri G, Gonzalez-Zapata A, McFarland EG.** Scapula fracture and os acromiale after reverse total shoulder arthroplasty. *Orthopedics* 2014;37:434, 92–95.
- 25. Nicolay S, De Beuckeleer L, Stoffelen D, Vanhoenacker F, Pouillon M.** Atraumatic bilateral scapular spine fracture several months after bilateral reverse total shoulder arthroplasty. *Skeletal Radiol* 2014;43:699–702.
- 26. Debeer P, Robyns F.** Fracture of the scapular spine in a patient with a Delta III prosthesis. *Acta Orthop Belg* 2005;71:612–614.
- 27. Toft F, Moro F.** Does ORIF of rare scapular spine fractures sustained after reverse shoulder arthroplasty benefit elderly patients? A case-series appraisal. *Orthop Traumatol Surg Res* 2019;105:1521–1528.
- 28. Bauer S, Traverso A, Walch G.** Locked 90°-double plating of scapular spine fracture after reverse shoulder arthroplasty with union and good outcome despite plate adjacent acromion fracture. *BMJ Case Rep* 2020;13:e234727.
- 29. Tatro JM, Gilbertson JA, Schroder LK, Cole PA.** Five to ten-year outcomes of operatively treated scapular fractures. *J Bone Joint Surg [Am]* 2018;100-A:871–878.
- 30. Nyffeler RW, Altioklar B, Bissig P.** Causes of acromion and scapular spine fractures following reverse shoulder arthroplasty: a retrospective analysis and literature review. *Int Orthop* 2020;44:2673–2681.
- 31. Brusalis CM, Taylor SA.** Periprosthetic fractures in reverse total shoulder arthroplasty: current concepts and advances in management. *Curr Rev Musculoskelet Med* 2020;13:509–519.
- 32. Taylor SA, Shah SS, Chen X, et al.** Scapular ring preservation: coracoacromial ligament transection increases scapular spine strains following reverse total shoulder arthroplasty. *J Bone Joint Surg [Am]* 2020;102-A:1358–1364.
- 33. Hardegger FH, Simpson LA, Weber BG.** The operative treatment of scapular fractures. *J Bone Joint Surg [Br]* 1984;66-B:725–731.
- 34. Mugikura S, Hirayama T, Tada H, Takemitsu Y.** Avulsion fracture of the scapular spine: a case report. *J Shoulder Elbow Surg* 1993;2:39–42.
- 35. Ogawa K, Naniwa T.** Fractures of the acromion and the lateral scapular spine. *J Shoulder Elbow Surg* 1997;6:544–548.
- 36. Lin Y, Gan K, Zhang L, Wei H, Zhou X, Chen H.** The anatomical variation of the scapular spine in a Chinese population. *Med Sci Monit* 2019;25:8863–8872.
- 37. Kicinski M, Puskas GJ, Zdravkovic V, Jost B.** Osteosynthesis of type III acromial fractures with locking compression plate, lateral clavicular plate, and reconstruction plate: a biomechanical analysis of load to failure and strain distribution. *J Shoulder Elbow Surg* 2018;27:2093–2098.
- 38. Ting FSH, Lockhart JS, Axford D, Johnson JA, Langohr DG, Athwal GS.** Comparing internal fixation constructs for scapular spine insufficiency fractures following reverse shoulder arthroplasty. *J Shoulder Elbow Surg* 2021;30:172–177.
- 39. Schoch C, Drews BH, Geyer S, Geyer M.** Therapie bei Acromionfraktur nach inverser Prothese. *Obere Extremität* 2016;12:46–50.
- 40. Tashjian RZ, Granger E, Broschinsky K, Kawakami J, Chalmers PN.** Effect of complications on outcomes after revision reverse total shoulder arthroplasty. *JSES Int* 2020;4:662–668.