

# Extracranial to intracranial by-pass anastomosis: Review of our preliminary experience from a low volume center in Egypt

Arundhati Biswas, A. EL Samadoni<sup>1</sup>, Ahmed Elbassiouny<sup>2</sup>, Khaled Sobh<sup>3</sup>, Ahmed Hegazy<sup>4</sup>

Department of Neurosurgery, Montefiore Medical Center, Albert Einstein College of Medicine, Bronx, NY 10467, USA, <sup>1</sup>Departments of Vascular Surgery and <sup>4</sup>Neurosurgery, Cairo University, Giza, <sup>2</sup>Department of Neurology and Interventional Neurology, Ain Shams University, <sup>3</sup>Department of Neurology, Al-Azhar University, Cairo, Egypt

## ABSTRACT

**Background:** Cerebral revascularization is a useful microsurgical technique for the treatment of steno-occlusive intracranial ischemic disease, complex intracranial aneurysms that require deliberate occlusion of a parent artery and invasive skull base tumors. We describe our preliminary experience with extracranial-to-intracranial by-passes at a low volume center; and discuss clinical indications and microsurgical techniques, challenges in comparison to large advanced referral centers.

**Materials and Methods:** Twenty-seven patients with hemodynamic ischemia or complex aneurysms or skull base tumors were operated at Cairo University Hospitals in the period between May 2009 and June 2014. All patients operated by a low flow by-pass were operated through a superficial temporal artery to middle cerebral artery (MCA) anastomosis. All patients chosen for a high flow by-pass were operated using a radial artery graft interposed between the MCAs distally and the common or the external carotid artery proximally. Patency was confirmed at the end of surgery using appearance on the table and confirmed after surgery by transcranial color-coded duplex or computed tomography angiography. All patient data were prospectively collected and retrospectively analyzed at the end of surgery.

**Results:** Nineteen patients (70.4%) were operated upon for flow augmentation and eight patients (29.6%) were operated upon for flow replacement. A total of 30 anastomoses were performed. All except one were patent which gives a patency rate of 96.3%. There was one death in the present series resulting from a hyperperfusion syndrome. 89.5% of patients with hemodynamic ischemia stopped having symptoms after surgery. All but one patient operated for hemodynamic ischemia showed a considerable cognitive improvement after surgery. None of the patients operated upon for flow replacement showed improvement of oculomotor nerve function in spite of adequate intraoperative decompression. All patients treated for flow replacement showed the absence of recurrence on follow-up.

**Conclusion:** Our initial results for both low and high flow by-pass procedures in our low volume center indicate that such complex surgical procedures are possible with results comparable to those obtained in other larger referral centers throughout the world. This procedure not only represents a more definitive treatment when compared to other endovascular or radiation treatments but is also much less costly when compared to other treatment modalities.

**Key words:** Complex tumors, Extracranial-to-intracranial by-pass, hemodynamic ischemia, vascular lesions

### Access this article online

#### Quick Response Code:



#### Website:

www.asianjns.org

#### DOI:

10.4103/1793-5482.162711

## Introduction and Aim of Work

Extracranial-to-intracranial (EC-IC) by-pass, either for flow augmentation or replacement, is an important tool in the armamentarium of practicing vascular and skull base surgeons.<sup>[1-4]</sup> Ever since it was introduced by Yasargil in 1967, it has become an indispensable tool for managing patients with hemodynamic ischemia, or for managing patients with complex aneurysms or skull base tumors; that are not amenable to radical resection; because of major vascular involvement.<sup>[5-9]</sup> Patients with hemodynamic ischemia have an annual stroke rate of 25% which increases by 2% every year. Such patients characteristically fail medical treatment.<sup>[2]</sup> Unless some form

### Address for correspondence:

Dr. Arundhati Biswas, Department of Neurosurgery, 3316 Rochambeau Avenue, Montefiore Medical Center, Albert Einstein College of Medicine, Bronx, NY 10467, USA.  
E-mail: arundhati.biswas@gmail.com

of by-pass is performed, they continue to have symptoms, and they can develop a fatal stroke. This category also includes patients with Moyamoya disease. On the other hand, patients with complex, giant aneurysm, have an 80% 5 years mortality rate. This means that they have a prognosis worse than most cancers.<sup>[10-12]</sup> Because they cannot be treated by endovascular means, surgical clipping is the only option. Clipping is usually not performed because of a wide neck, a fusiform aneurysm, major parent vessels arising from the dome or the neck of the aneurysm, and because the aneurysm must be decompressed under direct trapping all of which necessitate some form of by-pass. It is, therefore, very important that neurosurgeons managing such complex disorders should be able to perform this procedure.<sup>[13,14]</sup> We report on our initial experience with extracranial to intracranial by-pass surgery.

## Materials and Methods

In the period between May 2009 and June 2014, 27 patients with either hemodynamic ischemia, complex aneurysms, or skull base tumors were operated at Cairo University Hospitals.

Preoperatively, all patients were subjected to a detailed cardiac assessment. A cerebral angiography was usually done in most patients. It was sometimes not necessary to perform a formal angiography in patients intended for flow augmentation. If preoperative transcranial color-coded duplex showed clear evidence of hemodynamic ischemia, and provided adequate information regarding both, donor and the recipient vessels, then we did not perform a formal angiography. Cases intended for flow replacement were subjected to color-coded duplex of both saphenous veins and the left radial artery. Patients were asked to discontinue antiplatelet therapy 1-week to 10 days prior to surgery. The main aim of preoperative investigations was to provide adequate information about the anatomy of both donor and recipient vessels and the extent of the disease.

After induction of general anesthesia, normotension, normocapnia, and mild hypothermia was maintained throughout the surgical procedure. The procedure was started by harvesting the donor vessel in cases of flow augmentation, or the graft followed by preparation of the donor vessel in cases of flow replacement. This was kept in place till the time of anastomosis. (If an insufficient donor vessel was found before surgery, then an alternative option was, either to choose another donor, or to augment the donor itself. For example, one of our cases had an insufficient superficial temporal artery (STA). In this particular case, we used a short saphenous vein graft to revascularize the STA from the transverse cervical artery and we waited for 3 months until flow in the artery approached the contralateral side and then we used the STA for by-pass.). Attention is then shifted to the recipient vessel. A craniotomy is done and the recipient vessel is chosen for by-pass.

Once both donor and recipient vessels were ready, burst suppression was started and the patient was heparinized. Mean arterial blood pressure was elevated 20% above the baseline and the anastomosis was created using a standard technique described elsewhere. However, recently we started to use a standard back wall through the front wall (one-way up) suture technique. We have found this technique to be faster and can be used for end to end, end to side, and side to side anastomosis. After completion of the anastomosis, microvascular clamps are removed. Any bleeding from the suture line was dealt with by additional sutures when necessary. Patency was then confirmed and the wound closed in layers to avoid compression in cases of flow augmentation.

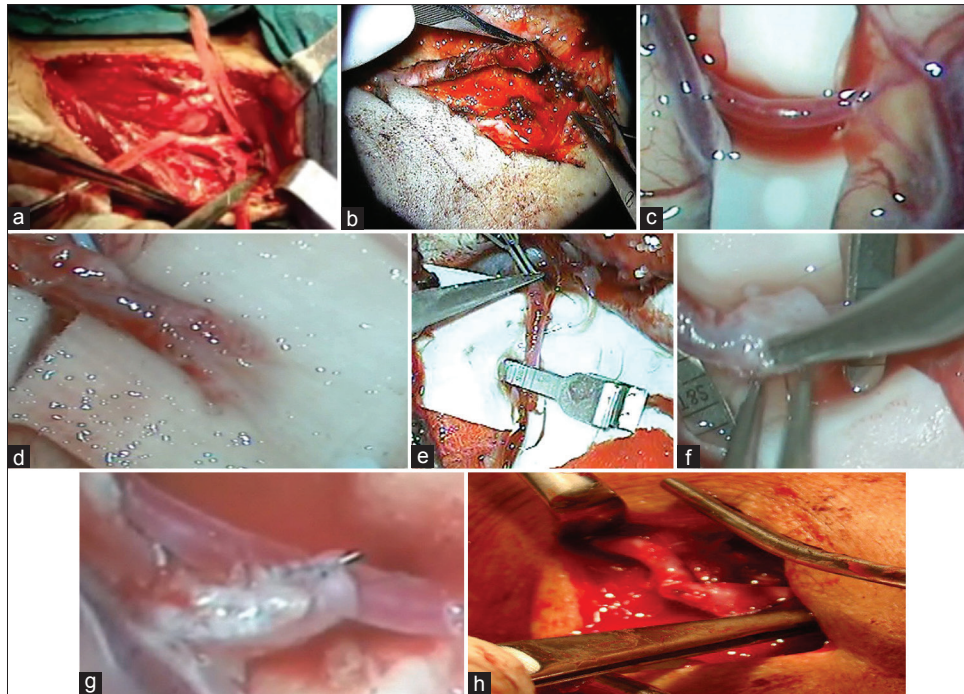
In cases of flow replacement, the proximal anastomosis is completed after tunneling the graft. For the tunneling, a pediatric chest tube is used along with marking the outer layer of the graft to prevent rotation or kinking. Bulldog clamps are used for cross clamping and the same process is repeated as for the distal anastomosis. In the present series, for all cases of flow replacement we have used an end to side anastomosis with the common carotid artery as the proximal anastomosis. In one case, an end- to end anastomosis was used with the external carotid artery. In another case, an end to end internal carotid artery anastomosis was done.

After surgery, all cases were monitored in an intensive care unit and maintained on low dose heparin along with aspirin and Plavix for the first 48 h. After 48 h, heparin was stopped and patient continued on aspirin for life. In cases of flow replacement, aspirin was stopped 10 days before tumor surgery. In cases of aneurysms, the aneurysm was dealt with at the same time. Blood pressure is maintained at a high normal level. In cases of flow augmentation, attention is given to prevent the development of a hyperperfusion syndrome. This is managed by keeping the patients on selective alpha channel blockers (labetalol). Figures 1-3 show a stepwise demonstration of the creation of an end to side anastomosis. Table 1 shows details of all cases in the study.

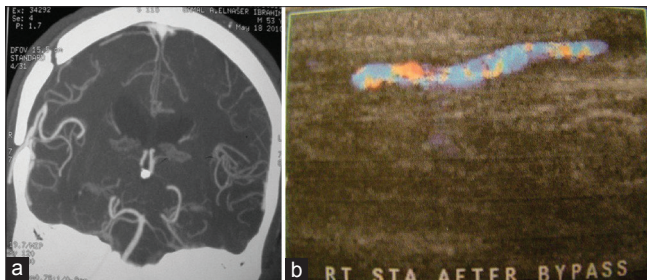
## Illustrative cases

### Case 1

This was a 54-year-old male patient who presented with hemodynamic ischemia resulting from a right total internal carotid artery occlusion. Preoperative transcranial color-coded duplex revealed a remarkable diminution in blood flow in the middle cerebral artery (MCA) on the right side in comparison to the left side. The patient had recurrent attacks of facio-brachial monoplegia associated with amaurosis fugax in the right eye that was also associated with diminution of vision. The patient was also hypertensive and diabetic. Aggressive medical treatment including risk factor management failed to alleviate the symptoms resulting from hemodynamic ischemia. The patient was operated upon by a low flow by-pass (superficial temporal to MCA by-pass). After surgery, the facio-brachial



**Figure 1:** The sequential intraoperative photographs revealing (a) cervical carotid artery exposure (b) superficial temporal artery dissection (c) recipient vessel preparation (d) donor vessel or graft preparation and fish mouthing (e) cross clamping of the recipient vessel (f) creation of distal anastomosis (g) testing for patency (h) creation of proximal anastomosis after tunneling

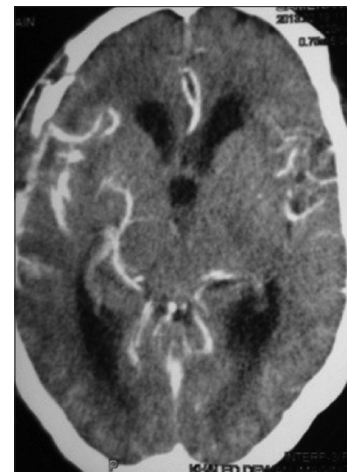

**Figure 2:** (a) Postoperative computed tomography angiography revealing a patent by-pass graft with improvement of blood flow in the middle cerebral artery (MCA) territory in comparison to the contralateral side, (b) transcranial colored duplex revealing the same findings with improvement of flow velocity has compared to the contralateral normal MCA

monoplegia disappeared and so did the amaurosis fugax. However, the diminution of vision that was present before surgery did not improve. Postoperative imaging revealed a patent graft as well as improvement of flow in the right sided MCA in comparison to the left MCA as compared to the preoperative status.

### Case 2

This was a 58-year-old female patient with a right sided cavernous sinus meningioma. The patient presented with recurrent attacks of headache associated with a complete ophthalmoplegia on the right side. The patient could not tolerate carotid occlusion on the right side as well. The patient was operated using a high flow by-pass (external carotid artery to MCA using a radial artery graft). The internal carotid artery



**Figure 3:** Postoperative computed tomography angiography revealing a patent radial artery graft with improvement in circulation in the right hemisphere as compared to the left after carotid ligation

was then completely ligated for tumor resection. Postoperative computed tomography angiography revealed the flow on the side with the by-pass to be very good, in fact better than, the normal side because of a patent high flow by-pass graft.

### Results

The study included 27 patients. Patients' ages ranged between 15 and 65 years. 18 patients (66.7%) were males and 9 (33.3%) were females. Regarding surgical indications, 19 patients (70.4%) were operated upon for flow augmentation and 8 patients (29.6%) were operated upon

**Table 1: Summary of clinical characteristics of patients**

Age	Sex	Reason for By-pass	Procedure	Pre-operative status	Post-operative status	Anastomotic patency	Complications
50	Male	Lt M1 and cervical ICA stenosis	Low flow by-pass	TIA,s	Died	Patent	Hyper perfusion syndrome
54	Male	Rt ICA occlusion	Low flow by-pass	TIA,s	Subsided	Patent	Non
45	Male	Lt ICA and CCA occlusion	Low flow by-pass after sta augmentation	TGA,s	Once on second day after surgery and then subsided completely	Patent	Non
51	Male	Rt ICA occlusion	Low flow by-pass	TIA,s	Subsided	Patent	Non
55	Female	Rt ICA occlusion	Low flow by-pass	TIA,s	Ongoing symptoms	Occluded 2 months after surgery	Non
15	Male	Moya- moya disease	Low flow by-pass+myosinangiosis	TIA,s	Subsided	Patent	Non
60	Female	Rt ICA occlusion	Low flow by-pass	Severe cognitive deficit	Remarkable cognitive improvement	Patent	Non
49	Male	Rt ICA occlusion	Low flow by-pass	Severe cognitive deficit	Remarkable cognitive improvement	Patent	Non
61	Male	Bilateral ICA occlusion and Lt VA stenosis	Low flow by-pass	VBI	Subsided	Patent	Non
36	Female	Rt cavernous sinus meningioma	High flow by-pass	Rt visual loss and oculomotor paralysis	same	Patent	Non
65	Female	Rt cavernous ICA giant aneurysm	High flow by-pass	TIA,s	Aneurysm exclude and decompressed	Patent	Non
59	Female	Rt cavernous sinus meningioma	High flow by-pass	Headaches and oculomotor paralysis	Tumor resection	Patent	Non
56	Male	Lt ICA occlusion	Low flow by-pass	TIA,s	Non	Patent	Non
49	Male	Lt ICA occlusion	Low flow by-pass	TIA,s	Non	Patent	Non
50	Male	Rt ICA occlusion	Low flow by-pass	TIA,s	Non	Patent	Non
52	Male	Rt ICA occlusion	Low flow by-pass	TIA,s	Non	Patent	Non
62	Female	Lt cavernous ICA giant aneurysm	High flow by-pass	TIA,s and oculomotor deficit	Aneurysm exclude and decompressed	Patent	Non
58	Female	Rt cavernous sinus meningioma	High flow by-pass	Headaches and oculomotor paralysis	Tumor resection	Patent	Non
42	Male	Rt total ICA occlusion	Low flow by-pass Rt STA-MCA	Lt sided facio brachial monoplegia and disturbed conscious level	Continues to improve	Patent anastomosis and an improvement in the difference between both sides by TCD	Regained consciousness and weakness improved
56	Male	IT total ICA occlusion	Lt STA-MCA	Rt sided TIAs and cognitive disfunction Associated IHD	Continues to improve	Patent anastomosis and an improvement in the difference between both sides by TCD	TIAs stopped and improved cognitive deficit
56	Male	Rt total ICA occlusion	Rt STA-MCA	Lt sided facio brachial monoplegia	Continues to improve	Patent anastomosis and an improvement in the difference between both sides by TCD	TIAs stopped
29	Male	RT recurrent skull base mass with petrous ICA involvement	Rt sided high flow bypass using radial artery between CCA and M2	RT recurrent skull base mass with petrous ICA involvement causing headache ,hearing loss as well as TIAs	Continues to improve	Patent anastomosis	Tumor removal
62	Male	Bilateral total ICA occlusion	Rt STA-MCA and developed a subdural hematoma before the second surgery	Severe cognitive deficit and LT sided TIAs as faciobrachial monoplegia	Developed an acute subdural hematoma 7 months after surgery due to head trauma while he was on plavix	Patent anastomosis	TIAs stopped with cognitive improvement
19	Male	Lt fusiform ICA aneurysm	Lt CCA-RAG-M2 Bypass	Lt LMN facial palsy and conductive hearing loss associated with a partial third nerve palsy	Non	Patent anastomosis	Improved facial nerve, third nerve and hearing functions

Contd...

Table 1: Contd....

Age	Sex	Reason for By-pass	Procedure	Pre-operative status	Post-operative status	Anastomotic patency	Complications
52	Female	Recurrent Rt sided cavernous sinus meningioma	Rt CCA-RAG-M2 Bypass	Complete paralysis of ocular motility and loss of vision on the Rt side	Non	Patent anastomosis	No improvement of ocular motility or vision
58	Male	Lt total ICA occlusion	Lt STA-MCA Bypass	Rt sided recurrent facio-brachial TIA,s	Non	Patent anastomosis	TIA,s stopped
64	Female	Lt sided near total ICA occlusion	Lt STA-MCA Bypass	Rt sided recurrent facio-brachial TIA,s	Non	Patent anastomosis	TIA,s stopped

for flow replacement. Of the 19 patients operated for flow augmentation, one patient (5.3%) had Moyamoya disease, one patient (5.3%) had MCA stenosis, and 17 patients (89.5%) had steno occlusive lesions of the internal carotid artery, two were bilateral. Of the 8 patients operated upon for flow replacement, 3 (37.5%) had nonclippable giant aneurysms of the internal carotid artery in the cavernous sinus and 5 (62.5%) had cavernous sinus meningiomas.

All patients operated for flow augmentation were operated by a standard STA to MCA by-pass. One patient (5.3%) with Moyamoya disease was operated in addition by myosinangiosis on one side in addition to the by-pass and myoencephalodurosinangiosis on the other side. Another patient (5.3%) with an associated external carotid artery stenosis was operated first by interposition of short saphenous vein graft between the transverse cervical artery and the STA to augment flow in the STA 3 months before performing a superficial temporal to MCA by-pass. Six patients (75%) operated for flow replacement, were operated using an interposition radial artery graft between the common carotid artery in the neck and the MCA. One patient (5.3%) was operated by an internal carotid to internal carotid end to end anastomosis, and one patient (5.3%) had a proximal anastomosis to the external carotid artery in the neck using end to end anastomosis with the radial artery graft.

Regarding anastomotic patency, all anastomoses were patent as confirmed by intra- and post-operative testing. One anastomosis was occluded 2 months after surgery. This particular patient had a vasculitic disorder and initially showed a remarkable postoperative improvement. The anastomosis was initially patent. This shows finally that only one of a total of 27 anastomosis showed a delayed occlusion. The remaining 26 were all patent. This means a patency rate of 96.3%.

There was one death in the present study (3.7%). This patient died of a postoperative cerebral hyperperfusion syndrome.

Regarding the surgical outcome, 17 patients (89.5%) with hemodynamic ischemia showed a cessation of preoperative transient ischemic attacks (TIAs). One case of vasculitis (5.3%) started developing symptoms, 2 months after discharge. This patient showed an occluded anastomosis. One patient (5.3%)

developed an attack of transient global amnesia in the immediate postoperative period and then ceased to have symptoms till the time this paper was written. The same applies for the patient with Moyamoya disease. Four patients with preoperative cognitive deficits showed a remarkable cognitive improvement after surgery. One patient was severely confused before surgery and became cognitively normal later on. The three operated aneurysms (37.5%) were completely excluded from the circulation. None suffered any postoperative complications. However, none of them regained oculomotor nerve function after 6 months of follow-up. The 5 patients (62.5%) operated for cavernous sinus meningiomas were totally resected and none of them regained oculomotor nerve function as well.

## Discussion

Ever since Alexis Carrel successfully performed vascular anastomotic procedures in 1914, the door has been opened for a new field of vascular surgery. The credit for the first intracranial EC-IC by-pass surgery goes to Donaghy and Yasargil in 1967.<sup>[15]</sup> Loughheed then performed the first high flow by-pass 2 years later using a great saphenous vein graft between the intra-petrous carotid artery and the supra-clinoid portion of the internal carotid artery.<sup>[16-18]</sup> EC-IC by-pass technique was first used in the treatment of ischemic stroke. Recent evidence suggests a revival of EC-IC by-pass surgery especially for the management of unclippable complex aneurysm and cranial base tumors involving major cranial arteries.

However, the technical skills of the surgical procedure prevent it from being widely practiced except in a few highly specialized referral centers worldwide. Very few reports have been published from low volume less equipped centers in developing countries. We report on our initial experience with by-pass surgery at such a center where more patients have surgical procedures than endovascular options.

Our choice of surgical procedure was a standard STA to MCA by-pass, as the general consensus of most other by-pass surgeons. There have been a number of reports on the use of high flow by-pass grafts for flow augmentation.<sup>[2]</sup> Our choice of graft was a radial artery graft in all of our cases operated for flow replacement. We did not use a great saphenous vein

graft in any of our cases. The radial artery has the benefits of having a thick wall, a good size match to the M2 and providing an intermediate flow which has been proven by many authors to be ideal to the brain.<sup>[19]</sup> The radial artery also has a proven long-term patency rate that has been accepted as superior to great saphenous vein grafts. The main drawback of using the radial artery is that it can be short in patients with long necks and short arms, and the radial artery is more liable to spasm than the saphenous vein.<sup>[20,21]</sup> However, there have been many techniques described with the aim of preventing spasm. In all of our cases, we have used a pressure distension technique as described by Ramanathan *et al.*<sup>[19]</sup> None of our cases operated for flow replacement showed postoperative spasm.

About 93.7% of our anastomoses were of the end to side type. 8.3% were of the end to end type. No side to side anastomoses were performed. There is also a general agreement, among by-pass surgeons, to use end to side anastomosis as the main form of anastomosis for most cases of cerebral revascularization.<sup>[22-24]</sup> All our cases were operated using a standard end to side anastomosis technique with two anchoring stitches at the heel and at the toe. However, only very recently, we have started to use a “one-way up suture technique” with only one anchoring suture at the heel. The recent literature on microvascular anastomoses also shows a tendency for using an open guide technique rather than a standard technique.<sup>[25]</sup> Our initial observations show; that it saves time and is much safer; because it avoids the occurrence of a through stitch at the heel. In all our cases, a slit arteriotomy was used rather than a tear drop arteriotomy. This has been proposed by many by-pass surgeons as well.<sup>[2,5,26,27]</sup>

About 96.3% of the anastomoses were patent at follow-up. Only one patient showed a delayed occlusion and this case proved to be a case of vasculitis. The reported patency rate coincides with the rate of patency described elsewhere.<sup>[7,9,13]</sup>

Seventeen patients (89.5%) with hemodynamic ischemia showed a cessation of preoperative TIAs, one continued to have symptoms due to an occluded anastomosis. One patient who developed symptoms in the early postoperative period improved during the period of follow-up. The 2 patients who developed symptoms initially were both found to have very small donor vessels at surgery. One of them was a patient with an occluded external carotid artery who had to receive a short saphenous vein graft to revascularize the STA from the transverse cervical artery. The second patient was the patient with Moyamoya disease. Both had patent anastomoses as proven by postoperative imaging. However, this process can be explained by graft maturation. STA-MCA by-passes has its own share of complications the major ones being graft occlusion, subgaleal hematoma, scalp necrosis, and postoperative intracranial hemorrhage.<sup>[8]</sup> Graft occlusion can be prevented by meticulous dissection of both the donor and recipient

artery with minimal handling of the endothelium. We did not see such complications in our study.

All patients treated by flow replacement were treated successfully either by complete tumor resection or by complete exclusion of the aneurysm from the circulation. None of them regained oculomotor nerve function after surgery and during follow-up. This coincides with the work of a number of authors performing by-pass for flow replacement.<sup>[11,18,24]</sup>

There was one mortality in the present series. This was the first patient operated for flow augmentation. This was a 50-year-old male patient who presented with hemodynamic ischemia caused by steno-occlusive disease of the left internal carotid artery and the MCA. The patient was operated and the anastomosis was patent. 48 h after surgery, the patient started to develop uncontrollable convulsions and severe hypertension; which were not responsive to any form of antiepileptic or antihypertensive therapy. Such symptoms characteristic for a hyperperfusion syndrome proved to be very difficult to treat.<sup>[16]</sup> Later on the patient developed a disturbed consciousness associated with chest infection and eventually died.

The risk of ischemia in the donor artery territory is related to the clamp time, which is directly related to the learning curve. The risk was reduced in our patients by raising the mean arterial pressure >20% above baseline and reducing metabolism by burst suppression.

By-pass treatment offers the only line of treatment for patients with hemodynamic ischemia. Patients indicated for flow replacement can rarely be treated by other means such as endovascular means or gamma knife.

## Conclusion

Our initial results for both low and high flow by-pass procedures in our low volume center indicate that such complex surgical procedures are possible with results comparable to those obtained in other larger referral centers throughout the world. This is of particular significance because it offers hope for a group of patients with complex disorders that can be only treated by such surgical procedures. This procedure not only represents a more definitive treatment when compared to other endovascular or radiation treatments but is also much less costly when compared to other treatment modalities. Hence, provides a financially viable option in a country with limited resources.

## References

1. Amin-Hanjani S, Barker FG 2<sup>nd</sup>, Charbel FT, Connolly ES Jr, Morcos JJ, Thompson BG, *et al.* Extracranial-intracranial bypass for stroke-is this the end of the line or a bump in the road? *Neurosurgery* 2012;71:557-61.
2. Amin-Hanjani S. Cerebral revascularization: Extracranial-intracranial bypass. *J Neurosurg Sci* 2011;55:107-16.
3. Chou CW, Chang JH, Lin SZ, Cho DY, Cheng YW, Chen CC.

- Extracranial-intracranial (EC-IC) bypass of symptomatic middle cerebral artery (MCA) total occlusion for haemodynamic impairment patients. *Br J Neurosurg* 2012;26:823-6.
4. Dong Y, Teoh HL, Chan BP, Ning C, Yeo TT, Sinha AK, *et al.* Changes in cerebral hemodynamic and cognitive parameters after external carotid-internal carotid bypass surgery in patients with severe steno-occlusive disease: A pilot study. *J Neurol Sci* 2012;322:112-6.
  5. Fiedler J, Pribán V, Skoda O, Schenk I, Schenková V, Poláková S. Cognitive outcome after EC-IC bypass surgery in hemodynamic cerebral ischemia. *Acta Neurochir (Wien)* 2011;153:1303-11.
  6. Fujimoto S, Toyoda K, Inoue T, Jinnouchi J, Kitazono T, Okada Y. Changes in superficial temporal artery blood flow and cerebral hemodynamics after extracranial-intracranial bypass surgery in moyamoya disease and atherothrombotic carotid occlusion. *J Neurol Sci* 2013;325:10-4.
  7. Hänggi D, Steiger HJ, Vajkoczy P; Cerebrovascular Section of the European Association of Neurological Surgeons (EANS). EC-IC bypass for stroke: Is there a future perspective? *Acta Neurochir (Wien)* 2012;154:1943-4.
  8. Ishii K, Morishige M, Anan M, Sugita K, Abe E, Kubo T, *et al.* Superficial temporal artery-to-middle cerebral artery anastomosis with encephalo-duro-myo-synangiosis as a modified operative procedure for moyamoya disease. *Acta Neurochir Suppl* 2010;107:95-9.
  9. Ishishita Y, Tanikawa R, Noda K, Kubota H, Izumi N, Katsuno M, *et al.* Universal extracranial-intracranial graft bypass for large or giant internal carotid aneurysms: Techniques and results in 38 consecutive patients. *World Neurosurg* 2014;82:130-9.
  10. Kalani MY, Zabramski JM, Hu YC, Spetzler RF. Extracranial-intracranial bypass and vessel occlusion for the treatment of unclippable giant middle cerebral artery aneurysms. *Neurosurgery* 2013;72:428-35.
  11. Kanamaru K, Araki T, Kawakita F, Hamada K, Kanamaru H, Matsuura K, *et al.* STA-MCA bypass for the treatment of ischemic stroke. *Acta Neurochir Suppl* 2011;112:55-7.
  12. Kawashima M, Rhoton AL Jr, Tanriover N, Ulm AJ, Yasuda A, Fujii K. Microsurgical anatomy of cerebral revascularization. Part I: Anterior circulation. *J Neurosurg* 2005;102:116-31.
  13. Kniemeyer HW, Voshege M, Soliman A, Abu Al Nasr TM, Beckmann H, Edelmann M. Late spontaneous recanalization of a symptomatically occluded internal carotid artery two years after extra-intracranial bypass. Case report and review of the literature. *J Cardiovasc Surg (Torino)* 2012;53:241-6.
  14. Krylov VV, Nakhabin OI, Polunina NA, Luk'ianchikov VA, Kuksova NS, Grigor'eva EV, *et al.* High-flow extracranial-intracranial (EC-IC) bypass surgery in a patient with giant right cavernous ica aneurysm. *Zh Vopr Neurokhir Im N N Burdenko* 2012;76:40-6.
  15. Yasargil MG. *Microsurgery Applied to Neurosurgery*. Stuttgart: Georg Thieme; 1969.
  16. Matano F, Murai Y, Tateyama K, Mizunari T, Umeoka K, Koketsu K, *et al.* Perioperative complications of superficial temporal artery to middle cerebral artery bypass for the treatment of complex middle cerebral artery aneurysms. *Clin Neurol Neurosurg* 2013;115:718-24.
  17. Mohit AA, Sekhar LN, Natarajan SK, Britz GW, Ghodke B. High-flow bypass grafts in the management of complex intracranial aneurysms. *Neurosurgery* 2007;60:ONS105-22.
  18. Newell DW. Superficial temporal artery to middle cerebral artery bypass. *Skull Base* 2005;15:133-41.
  19. Ramanathan D, Temkin N, Kim LJ, Ghodke B, Sekhar LN. Cerebral bypasses for complex aneurysms and tumors: Long-term results and graft management strategies. *Neurosurgery* 2012;70:1442-57.
  20. Newell DW, Vilela MD. Superficial temporal artery to middle cerebral artery bypass. *Neurosurgery* 2004;54:1441-8.
  21. Ohtaki S, Mikami T, Iihoshi S, Miyata K, Nonaka T, Houkin K, *et al.* Strategy for the treatment of large-giant aneurysms in the cavernous portion of the internal carotid artery. *No Shinkei Geka* 2013;41:107-15.
  22. Roh SW, Ahn JS, Sung HY, Jung YJ, Kwun BD, Kim CJ. Extracranial-intracranial bypass surgery using a radial artery interposition graft for cerebrovascular diseases. *J Korean Neurosurg Soc* 2011;50:185-90.
  23. Sia SF, Morgan MK. High flow extracranial-to-intracranial brain bypass surgery. *J Clin Neurosci* 2013;20:1-5.
  24. Teo K, Choy DK, Lwin S, Ning C, Yeo TT, Shen L, *et al.* Cerebral hyperperfusion syndrome after superficial temporal artery-middle cerebral artery bypass for severe intracranial steno-occlusive disease: A case control study. *Neurosurgery* 2013;72:936-42.
  25. Wanebo JE, Zabramski JM, Spetzler RF. Superficial temporal artery-to-middle cerebral artery bypass grafting for cerebral revascularization. *Neurosurgery* 2004;55:395-8.
  26. Yamaguchi K, Kawamata T, Kawashima A, Hori T, Okada Y. Incidence and predictive factors of cerebral hyperperfusion after extracranial-intracranial bypass for occlusive cerebrovascular diseases. *Neurosurgery* 2010;67:1548-54.
  27. Zhu W, Tian YL, Zhou LF, Song DL, Xu B, Mao Y. Treatment strategies for complex internal carotid artery (ICA) aneurysms: Direct ICA sacrifice or combined with extracranial-to-intracranial bypass. *World Neurosurg* 2011;75:476-84.

**How to cite this article:** Biswas A, Samadoni AE, Elbassiouny A, Sobh K, Hegazy A. Extracranial to intracranial by-pass anastomosis: Review of our preliminary experience from a low volume center in Egypt. *Asian J Neurosurg* 2015;10:303-9.

**Source of Support:** Nil, **Conflict of Interest:** None declared.