

Successful Endoscopic Disconnection for Hypothalamic Hamartomas in a Child with Gelastic Seizures: An Unusual Case in a Resource-Scare Setting

This article was published in the following Dove Press journal:
International Medical Case Reports Journal

He Van Dong^{1,*}
Van Dinh Tran^{1,*}
Dinh-Hoa Nguyen^{2-4,*}
Hoe Van Vu⁵
Tuan Anh Nguyen⁶
Ha Ngoc Thi Doan⁷
Hoang-Long Vo^{7,8}

¹Department of Neurosurgery I, Viet Duc University Hospital, Hanoi 100000, Vietnam; ²Institute of Orthopedic Trauma, Viet Duc University Hospital, Hanoi 100000, Vietnam; ³Social Affair Department, Viet Duc University Hospital, Hanoi 100000, Vietnam; ⁴Department of Surgery, Hai Duong Medical Technical University, Hai Duong 170000, Vietnam; ⁵Department of Neurosurgery, 103 Military Hospital, Hanoi 100000, Vietnam; ⁶Department of Neurology, Viet Duc University Hospital, Hanoi 100000, Vietnam; ⁷Institute for Preventive Medicine and Public Health, Hanoi Medical University, Hanoi 100000, Vietnam; ⁸Institute of Health Economics and Technology, Hanoi, Vietnam

*These authors contributed equally to this work

Correspondence: Hoang-Long Vo
Institute for Preventive Medicine and Public Health, Hanoi Medical University, No. 01 Ton That Tung Street, Dong Da, Hanoi 100000, Vietnam
Tel +84-985406430
Fax +84-4 38525115
Email vohoanglonghmu@gmail.com

Ha Ngoc Thi Doan
Email doanthingochahmu@gmail.com

Abstract: Although the endoscopic disconnection surgery for the hamartomas was previously shown as a safe and effective treatment strategy in eliminating gelastic epilepsy, to date, there was no convincing evidence with this procedure in the resource-scare settings. We discuss an unusual case of a 7-year-old child who suffered from pharmaco-resistant gelastic seizures was surgically treated with the endoscopic disconnection of the hypothalamic hamartomas. The patient underwent endoscopic surgery through the left ventricle approach to disconnect the lesion of the hypothalamus. Immediately after surgery, the patient's clinical laughter was eliminated with no complications. From the initial experience at our center, successful outcome of this case contributes to supporting the solid evidence in choosing the right treatment approach for the hypothalamus in subsequent cases, towards not only Vietnam but also the countries having similar resource-scare conditions.

Keywords: hypothalamic hamartomas, gelastic seizure, drug-resistant epilepsy, endoscopic surgical disconnection

Introduction

Hypothalamic hamartomas (HH) are rare non-neoplastic lesions composed of hyperplastic neurons and glial cells. Gelastic seizures, epileptic events characterized by the bouts of laughter, are the hallmark manifestation of HH.^{1,2} The brain magnetic resonance imaging (MRI) findings play a crucial and indisputable role in the diagnosis and the classification of HH.³

As was previously reported, the neonatal onset of seizures appeared as early as the first day,⁴ and gelastic seizures usually occur with high frequency and periodicity, especially in children. Gelastic seizure progressing over time is usually recognized with autonomic features such as sudden onset and end without amusing conditions, tending to be drug-resistant.^{1,5} Currently, the most effective surgical approach for the patients with gelastic seizures associated with HH is known to be HH disconnection or surgical resection.⁶ Newer approaches such as stereotactic radiofrequency thermocoagulation (SRT) and laser interstitial thermal therapy (LITT) have been reported with the safety and efficacy,^{7,8} nevertheless, these strategies have not been applied in Vietnam because of the surgery centers' limited surgical infrastructure. Here, from the initial experience at our institution, we aim to

discuss an unusual case of a 7-year-old child who suffered from pharmacoresistant gelastic seizures was surgically treated with the endoscopic disconnection of HH.

Case Report

A 7-year-old boy first exhibited seizures 4 months after birth. Seizures occurred averagely 30 times per week and were not treated until the patient was 2 years old. Typically, these gelastic seizures lasted approximately 10 to 30 s and stopped suddenly, which was uncontrollable. Initially, he had been treated with Topamax 100mg/day and Depakine 500 mg/day since 2 years old at a provincial General Hospital, however, this did not seem to be responding to drug treatment. Then although he was examined and treated in many different hospitals, the cause of laughter could not be detected. He continued to experience progressive seizures. He grew up normally without any sexual or behavioral disorders. In 2015, when he first visited our Department of Neurosurgery at Viet Duc Hospital, we re-evaluated and observed the characteristics of laughter that was recorded by the camera. The laughter was accompanied with an instant generalized seizure and short unconsciousness lasting within 1 min. In addition, routine EEG and video EEG were performed multiple times in order to identify whether the region causing epilepsy was multi- or mono-positional. The 17-channel scalp-EEG (multiple recordings) revealed paroxysmal sharp waves spreading over both hemispheres. Brain MRI 1.5 Tesla (coronal and sagittal sequences) revealed a small lesion measuring 12*14*8 mm located on the right of the third

ventricle, attached to mammillary nuclear and between tuber cinereum and optic chiasma (Figure 1). It was isointense with grey matter, hypointense on T1, and non-enhancing on sagittal T1W after Gadolinium and lightly hyperintense on T2W. In the HH classification modified by Choi,⁹ with the findings of MRI, HH was classified into four different groups showing the link between the hamartoma and hypothalamus or the third ventricle. A giant hypothalamic hamartomas (type IV) was considered as a hamartoma with the size over 20 mm. Small HH (<20 mm) were classified as midline (type I), lateral (type II), and intraventricular (type III) according to their location relative to the third ventricle. For our case, HH belonged to type II. The results of clinical evaluation and endocrine tests for our patient showed no endocrine disorders and no developmental abnormalities. The patient was diagnosed with the drug-resistant epilepsy according to the definition of the International League Against Epilepsy (ILAE).¹⁰

The patient underwent endoscopic surgery through the left ventricle approach to disconnect the hamartoma mass with the hypothalamus (Figure 2). In this case, we used a 30° pediatric telescope system (Karl Storz) with an outside diameter of 3.8 mm, together with basic endoscopic equipment including a monopolar electric coagulator, a forceps, fiberoptic light guide, a light source, an endovision system and a display screen. The patient received general anesthesia. His head was fixed in a Mayfield frame and attached to a neuro-navigation system and settled in a neutral posture with 15° head down. We used

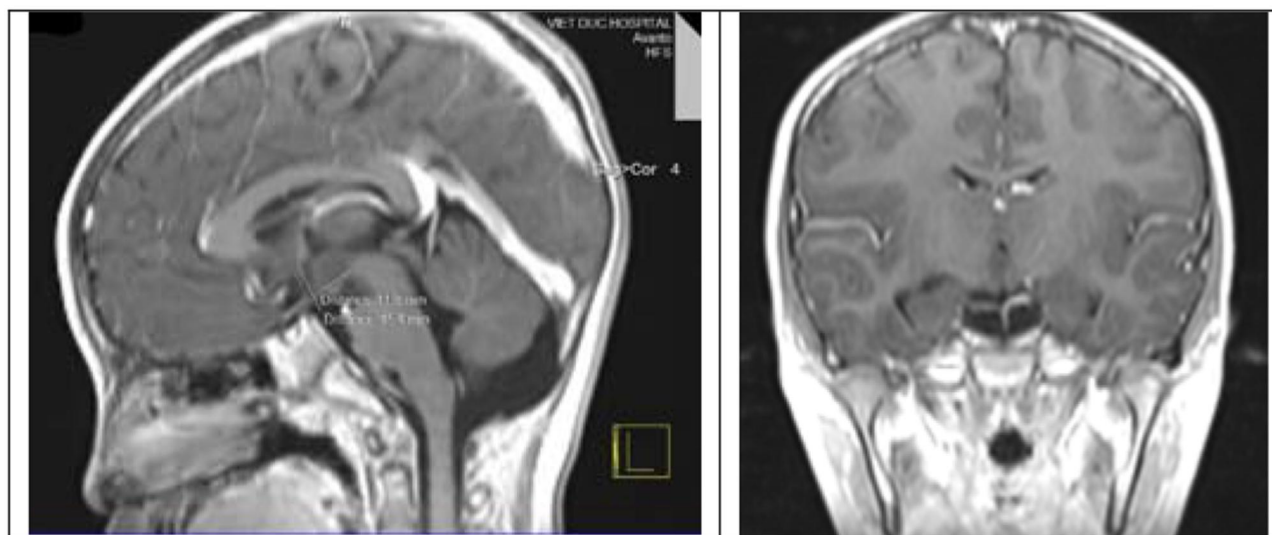


Figure 1 Brain MRI 1.5 Tesla (in hypothalamus area, mainly on coronal and sagittal sequences) revealed a hypothalamus lesion measuring 12*14*8 mm located on the right of the third ventricle, attached to mammillary nuclear and between tuber cinereum and optic chiasma.

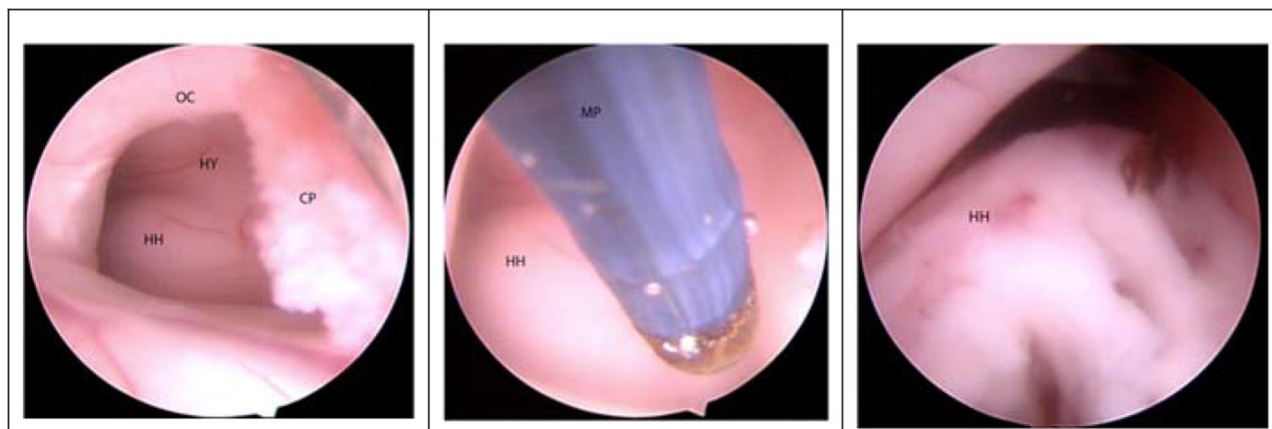


Figure 2 Endoscopic views in the surgery.

Abbreviations: OC, optic chiasma; HY, hypothalamus; CP, choroid plexus; MP, monopolar electrocoagulation; HH, hamartomas.

preoperative neuro-navigation to help determine the way into the ventricle and the corresponding incision site. The burr hole was made 1 cm in front of the coronal suture and 2–3 cm to the left of the midline.

Immediately after surgery, the patient's clinical laughter was eliminated with no complications. Scalp video EEG postoperatively showed a marked decrease in spike spread across the hemispheres compared to before surgery. Cranial MRI revealed, on coronal slices at T1 and T2, the disconnection of the hamartoma block with the hypothalamus confirmed. No complications occurred after surgery, and the patient was discharged after 1 week of surgery. He had free-seizures on the clinical, stopped with antiepileptic drug. At postoperatively 1 year, the patient had 2–4 gelastic seizures per week, and no generalized seizure.

Discussion

The classification for HH plays an important role in treatment options. Radiosurgery, endoscopic surgery and stereotactic radiofrequency ablation were proposed for types I and II. In which, type II, hamartoma totally extraventricular, can be treated by open craniotomy with pterional approach, while endoscopic surgery combined with open craniotomy with pterional approach can be applicable for type II mixed (part hamartoma intra and extraventricular). Endoscopic surgery or open craniotomy with transcallosal approach was applied to the intraventricular type of hamartoma (type III). In particular, regarding type IV (giant hamartoma), endoscopic disconnection combined with radiosurgery or endoscopic disconnection with open craniotomy should be selected.⁶

To date, there are some other options for treatment of HH such as SRT or LITT. SRT was known as a minimally invasive surgical strategy for HH with excellent seizure outcomes, even in patients diagnosed with giant HHs.⁷ A recent study indicated that, for the patients with small HHs (maximum HH diameter less than <20mm), SRT can provide similar seizure outcomes to resective surgery with a less invasive procedure. However, no significant difference in seizure outcomes was found between SRT and resective surgery.¹¹ Besides SRT was also considered to be a treatment option for HH patients with surgical contraindications such as hemopathy or the patients and their families refusing surgical treatment.

In addition, several LITT studies have been reported for recent positive results, LITT is a less invasive treatment modality with a lower incidence of complications. The principle of LITT is selective ablation of tumor cells by heat and is monitored by real-time MRI thermometry. LITT has a range of applications, such as treatment of glioma, metastases, radiation necrosis, chronic pain, and epilepsy. LITT is used for selected lesions and in selected patients as a safer alternative treatment option for patients in whom the lesion is not accessible by surgery, or in those in whom other standard treatment options have failed. LITT' complications include hemorrhage, brain edema, thermal injury of adjacent structures, and treatment failure.⁸ SRT and LITT approaches have not yet applicable for HH in our institution, and no evidence of the efficacy and safety of SRT and LITT for HH patients has been reported in Vietnam.⁸

The HH surgery poses two options including resective surgery of the lesion mass or disconnecting the hamartoma with the hypothalamus. Currently, the surgery to remove lesions was less selected due to the risks and sequelae that

can occur such as damage to the hypothalamus and tuber cinereum. In 2003, Delalande and Fohlen¹² reported the first case of endoscopic surgery for the patient with type III hamartoma (in the ventricles), and the previous authors also proposed surgical procedure to craniectomy associated with large hamartoma (type IV). Choi and his colleagues⁹ have indicated the endoscopic surgery to disconnect the hamartoma block from the hypothalamus, which was applied to type I, II and III. Besides the endoscopic disconnection combined with craniectomy was treated for type IV. In this type II case, we decided to approach the lesion from the opposite side for the best observation and manipulation.

In this case, anatomical disconnection was chosen to alleviate seizures and to improve cognitive function and mental and motor development, thereby, gradually reducing the dependence of epilepsy medication later. Endoscopic disconnection technique aims to disconnect the connecting tract between the hamartoma and the surrounding normal tissue, while HH surgical resection has a high risk of damage towards surrounding anatomical structures such as a third ventricular wall, a third ventricle floor, mammillary bodies, optic tract and cranial nerve. Surgical resection was not applied to our patient because its postoperative complications might occur such as stroke, short-term memory disturbance, weight gain, diabetes insipidus, and other endocrine disturbances. Besides, ideal candidates for the disconnection technique should be those with a lesion smaller than 1.5 cm in diameter.⁶ We would like to acknowledge that, our center has had a common experience of laparoscopic surgery for over 20 years, especially endoscopic ventricular surgery and sphenoid sinus endoscopy. The selection of neurosurgical procedure partly depends on the surgeon's preference and experience, principal reason for treatment in this case is still based on the location, shape, and size of the HH. According to Delalande, for type II (on the side), if the hamartoma is attached to the right of the hypothalamus, the approach will be selected from the anterior horn of the left ventricle and vice versa to ensure the best view of the hamartoma once entering the ventricles. Conducting a one-hole drilling at a defined position, maximizing the dura to the perimeter of the borehole, opening the arachnoid mater and putting the 30 degrees endoscope with a trocar head and navigation system mounted on the endoscope axis allowed us continuous identification of the direction and position of the endoscope. An endoscopy holder can be used to ensure the stability of the endoscope direction. Endoscope after going into the anterior horn of the left ventricle, going through the Monro hole will observe the hamartoma block attached to the

floor and the lateral wall of the third ventricle. For hamartoma type II, III, IV, it is easy to observe the hamartoma block boundary by comparing with the normal side of the third ventricular wall. However, for type I, it is sometimes difficult for the surgeon to determine the border of the hamartoma block with the surrounding structure. We used low-intensity monopolar electrical coagulator to cut along the border of the hamartoma (towards the posteroinferior floor and the lateral wall of the third ventricle), while ensured that either the mammillary body or the hypothalamus was not injured. The depth of the dissection into brain tissue had been measured preoperatively through the coronal T1W and T2W.

Between 1995 and 2005, Shim et al¹³ performed the endoscopic disconnection in 11 patients. Six were seizure-free (Engel's class 1) immediately after surgery. At postoperatively 2 months, a dramatic improvement in behavior was announced by their caregivers.¹³ Of 11 patients experiencing the endoscopic disconnection for hamartomas, class 1 and class 2 were one case and four cases, respectively. In another series of ReKate et al¹⁴ with 44 patients undergoing endoscopic resection utilizing frameless stereotaxis and a micromanipulator, the ideal patient has a lesion less than 1.5 cm in diameter. Eleven patients (25%) met early complications but resolved within 3 months in all patients except for three cases (6.8%). After surgery, six patients had difficulties with short-term memory, of which three patients lasted more than 3 months. Five patients gained more than 10% of their body weight, but the gain stabilized and improved within 3 months. One patient whose internal capsule was injured during endoscope manipulation suffered significant hemiparesis, which improved slowly over a year.¹⁴

Conclusion

Endoscopic surgical disconnection of the hamartomas towards eliminating gelastic epilepsy may be considered as an effective and safe option, instead of the surgical resection for HH. First in Vietnam, the authors have successfully applied this method on a child diagnosed with pharmacoresistant gelastic seizures associated with HH. Successful outcome of this case contributes to support the solid evidence in choosing the right treatment of the hypothalamus in subsequent cases, towards not only Vietnam but also the countries having similar resource-scare conditions.

Ethical Approval

Our institution does not require ethical approval for reporting individual cases or case series.

Consent for Participation and Publication

Written informed consent was obtained from the patient's parents for the publication of this case report and any accompanying images.

Funding

There is no funding to report.

Disclosure

The authors declared no potential conflicts of interest with respect to the research, authorship, and/or publication of this article.

References

- Télez-Zenteno JF, Serrano-Almeida C, Moien-Afshari F. Gelastic seizures associated with hypothalamic hamartomas. An update in the clinical presentation, diagnosis and treatment. *Neuropsychiatr Dis Treat*. 2008;4(6):1021. doi:10.2147/NDT.S2173
- Gascon G, Lombroso C. Epileptic (gelastic) laughter. *Epilepsia*. 1971;12(1):63–76. doi:10.1111/j.1528-1157.1971.tb03916.x
- Marliani A, Tampieri D, Melançon D, et al. Magnetic resonance imaging of hypothalamic hamartomas causing gelastic epilepsy. *Can Assoc Radiol J*. 1991;42(5):335–339.
- Kito M, Yabuta K, Kato S, et al. Gelastic seizures in clusters in a case of West syndrome after perinatal hypothalamic hemorrhage. *J Perinat Med*. 2001;29(4):357–359. doi:10.1515/JPM.2001.051
- Cerullo A, Tinuper P, Provini F, et al. Autonomic and hormonal ictal changes in gelastic seizures from hypothalamic hamartomas. *Electroencephalogr Clin Neurophysiol*. 1998;107(5):p. 317–322. doi:10.1016/S0013-4694(98)00074-1
- Akalan N, Di Rocco C. *Pediatric Epilepsy Surgery*. Vol. 39. Springer Science & Business Media; 2012.
- Shirozu H, Masuda H, Ito Y, et al. Stereotactic radiofrequency thermocoagulation for giant hypothalamic hamartoma. *J Neurosurg*. 2016;125(4):812–821. doi:10.3171/2015.6.JNS15200
- Salem U, Kumar VA, Madewell JE, et al. *Neurosurgical applications of MRI guided laser interstitial thermal therapy (LITT)*. *Cancer Imaging*. 2019;19(1):65. doi:10.1186/s40644-019-0250-4
- Choi J-U, Kim D-S. Treatment modalities for intractable epilepsy in hypothalamic hamartoma. In: *Pediatric Epilepsy Surgery*. Springer; 2012:117–130.
- Kwan P, Arzimanoglou A, Berg AT, et al. Definition of drug resistant epilepsy: consensus proposal by the ad hoc task force of the ILAE commission on therapeutic strategies. *Epilepsia*. 2010;51(6):1069–1077. doi:10.1111/j.1528-1167.2009.02397.x
- Wang S, Zhao M, Li T, et al. Stereotactic radiofrequency thermocoagulation and resective surgery for patients with hypothalamic hamartoma. *J Neurosurg*. 2020;1:1–8.
- Delalande O, Fohlen M. Disconnecting surgical treatment of hypothalamic hamartoma in children and adults with refractory epilepsy and proposal of a new classification. *Neurol Med Chir*. 2003;43(2):61–68. doi:10.2176/nmc.43.61
- Shim K-W, Chang J-H, Park Y-G, et al. Treatment modality for intractable epilepsy in hypothalamic hamartomatous lesions. *Neurosurgery*. 2008;62(4):847–856. doi:10.1227/01.neu.0000318170.82719.7c
- Rekate HL, Feiz-Erfan I, Ng Y-T, et al. Endoscopic surgery for hypothalamic hamartomas causing medically refractory gelastic epilepsy. *Childs Nerv Syst*. 2006;22(8):874–880. doi:10.1007/s00381-006-0125-4

International Medical Case Reports Journal

Dovepress

Publish your work in this journal

The International Medical Case Reports Journal is an international, peer-reviewed open-access journal publishing original case reports from all medical specialties. Previously unpublished medical posters are also accepted relating to any area of clinical or preclinical science. Submissions should not normally exceed 2,000 words or 4

published pages including figures, diagrams and references. The manuscript management system is completely online and includes a very quick and fair peer-review system, which is all easy to use. Visit <http://www.dovepress.com/testimonials.php> to read real quotes from published authors.

Submit your manuscript here: <https://www.dovepress.com/international-medical-case-reports-journal-journal>