

Safely completed radiotherapy in a patient with breast cancer and right axillary vein approach cardiac pacemaker implantation: A case report

YUNJUAN WANG¹, JIANLING ZHAO¹, YINBO HE¹, CAIYI LUO¹, YU SUN¹, LI ZHOU¹ and LI XIE²

¹Department of Radiology Oncology; ²Head and Neck Oncology Ward, Cancer Center, West China Hospital of Sichuan University, Chengdu, Sichuan 610044, P.R. China

Received May 24, 2022; Accepted October 19, 2022

DOI: 10.3892/etm.2022.11716

Abstract. Pacemaker implantation is becoming increasingly common in patients with breast cancer. Comprehensive treatment options, such as surgery, chemotherapy, radiation therapy, targeted therapy and immunotherapy, have greatly improved the prognosis of patients with breast cancer. In particular, radiotherapy is an important means of comprehensive breast cancer treatment that can reduce recurrence and prolong survival in high-risk patients who underwent mastectomy. The pacemaker electrical pulse generator is typically implanted subcutaneously in the left subclavian area above the pectoral muscle through the subclavian vein. The present report implemented a new method of 'temporary pacemaker electrode and permanent artificial pacemaker placement' through the right axillary vein in a patient with breast cancer. An electrical pulse generator was placed in the right subcutaneous subclavian tissue. The pacemaker was placed under the right clavicle, and the pacemaker was included as organ at risk (OAR). Dose of planning organ at risk volume (PRV) with additional 6 mm margin to the pacemaker was limited during radiotherapy planning design. This patient with breast cancer, who was also complicated with other underlying comorbidities (such as atrial fibrillation, coronary atherosclerosis, cardiac insufficiency, hypertension, type 2 diabetes mellitus) and implanted with a cardiac pacemaker, was treated with safe (means that the patient has not developed heart disease because of the pacemaker problem) and effective (tumor can be effectively controlled under the condition that the pacemaker does not malfunction) radiotherapy. At present, the patient has successfully completed radiation therapy for breast cancer with no recurrence or metastasis. To the best of our knowledge, the present report is the first to document this application, demonstrating the treatment of a patient with breast cancer and

cardiac pacemaker implantation, which is worthy of further study and continuous improvement in clinical practice.

Introduction

Breast cancer is a major type of cancer that threaten the health of women worldwide and has been attracting the attention of researchers worldwide. Among the 185 countries/regions in the world, 159 countries have the highest incidence of breast cancer, with the highest incidence and death rate of female cancer, with the incidence and death rate of 47.8 and 13.6% per 100,000 people, respectively (1). After standardized treatment of early breast cancer, the 5-year survival rate of breast cancer patients can reach 95% (2). The incidence and mortality of cancer are increasing rapidly worldwide, which is related to the aging of population and the increase of population. With the improvement of people's life quality and the improvement of pacing engineering, the indications for pacemaker implantation are gradually expanding. At present, the clinical application of pacemaker therapy, especially ordinary pacemaker, has become very popular. According to the 2012 ACCF/AHA/HRS Guidelines for Implanted Devices, common pacemaker implantation indications include 11 aspects (3) (1) Appropriate indications for permanent pacemaker implantation in patients with abnormal sinus node function; (2) Indications for permanent pacemaker implantation in adults with acquired atrioventricular block; (3) Indications for permanent pacemaker implantation in patients with chronic double branch block; (4) Indications of permanent pacemaker implantation in patients after acute myocardial infarction; (5) Indications of permanent pacemaker implantation in patients with hypersensitive carotid sinus syndrome and cardiogenic neurosyncope; (6) Indications of permanent pacemaker implantation in patients after heart transplantation; (7) An indication of permanent pacemaker implantation that automatically detects and terminates tachycardia; (8) Indications of permanent pacemaker for tachycardia prevention; (9) Indications of permanent cardiac pacemaker to prevent atrial fibrillation (AF); (10) Indications of permanent pacemaker implantation in patients with hypertrophic cardiomyopathy; (11) Indications for permanent pacemaker implantation in children and adults with congenital heart disease (CHD). How to improve the

Correspondence to: Professor Li Xie, Head and Neck Oncology Ward, Cancer Center, West China Hospital of Sichuan University, 37 Guoxue Lane, Chengdu, Sichuan 610044, P.R. China
E-mail: 975987432@qq.com

Key words: breast cancer, pacemaker, radiation therapy

survival rate and quality of life of breast cancer patients with pacemakers is an issue that we need to pay common attention to. At present, the treatment of breast cancer has entered the era of comprehensive therapy, including surgery, radiation therapy, chemotherapy, targeted therapy, endocrine therapy and immunotherapy. Therefore, when radiotherapy is performed on such patients, the path of pacemaker implantation should be considered for those who need pacemaker implantation, so as to prepare for safe radiotherapy with pacemaker irradiation dose control in the later stage. Ionizing radiation generated during radiotherapy can cause charge accumulation and abnormal current in the semiconductor components of cardiac pacemaker, which can cause pacemaker failure or interfere with the function of pacemaker, and even induce malignant arrhythmia. After implantation of the pacemaker electrode in the heart cavity, a foreign body rejection inflammatory reaction occurred at the electrode joint/tissue interface, resulting in inflammatory edema. Cardiomyocyte damage and inflammatory edema caused by radiotherapy can inhibit the conduction of electrical pulse signal of the pacemaker, and even cause working obstacles for the pacemaker in severe cases. Therefore, Medtronic recommends that the radiation dose of the pacemaker should not be greater than or equal to 5 Gy, and that the pacemaker and pulse generator should be placed in the irradiation field. When radiotherapists use 3D radiotherapy to delineate the target area, they should define the pacemaker as the organ at risk (OAR) and ensure that its maximum tolerance is 2 Gy. Tumor patients with pacemaker implantation can safely and effectively complete radiotherapy under certain treatment conditions, which requires us to take full consideration of the specific situation of patients in the process of making radiotherapy plan and implementing radiotherapy, so as to minimize the influence of various factors on pacemaker.

Case report

In May 2020, the patient, a 64-year-old female, found a left axillary mass that was not causing any redness, swelling or pain. In addition, the left axillary mass did not shrink significantly after oral traditional Chinese medicine (TCM) (100 ml twice a day, orally in the morning and evening). This manifestation was not followed by further examination or treatment. The patient's left axillary mass not only increased in size by October 2020, but additional masses were also found in the outer and upper part of the left breast. A breast ultrasound examination was performed by another hospital (Mianyang Central Hospital of Sichuan Province, October 2020). In the same month, the patient was admitted into the Department of Radiology Oncology, West China Hospital of Sichuan University (Chengdu, China) for further examination and treatment. The patient was diagnosed as left breast cancer with axillary lymph node metastasis, grade 3, lymphatic vascular invasion, by biopsy of left breast and left axillary mass. Following surgery, two cycles of TCbHP (docetaxel, carboplatin, trastuzumab, pertuzumab) chemotherapy were performed. After chemotherapy, the renal function of the patient worsened, and the patient was adjusted to four cycles of THP (docetaxel, trastuzumab, pertuzumab) chemotherapy. Chemotherapy was followed by endocrine therapy with

trozole, followed by targeted therapy. As the patient exhibited complications of atrial fibrillation, coronary atherosclerosis, cardiac insufficiency, hypertension and type 2 diabetes mellitus, antitumor therapy was suspended. The patient was subsequently admitted into the Department of Cardiology of West China Hospital of Sichuan University (Chengdu, China) in December 2020. The results of the medical examination are summarized in Table I.

The patient was ultimately diagnosed with the following: I) Atrial fibrillation with intermittent third-degree atrioventricular block; ii) cardiac insufficiency with grade III cardiac function (General physical activity is significantly limited. No symptoms at rest, less than normal physical activity can cause fatigue, palpitations, asthma or angina); iii) hypertrophic cardiomyopathy; iv) coronary atherosclerosis; v) hypertension; vi) type 2 diabetes mellitus; vii) left breast cancer with axillary lymph node metastasis; and viii) chronic renal insufficiency.

Considering that the patient was diagnosed with left breast cancer with axillary lymph node metastasis and required postoperative radiotherapy, a temporary pacing electrode and permanent artificial cardiac pacemaker placement' (model no. A3DR01; Medtronic, Inc.) procedure was performed using the right axillary vein approach. The electrical pulse generator (model no. A3DR01; Medtronic, Inc.) was placed in the right subclavian subcutaneous tissue.

In January 2021, the patient underwent left radical mastectomy and left axillary lymph node dissection. Postoperative pathological (HE staining and immunohistochemical staining of metastatic lymph nodes of breast cancer) assessment showed the following: i) Invasive ductal carcinoma of the left breast (grade III; tumor size, 2.0x1.8x1.5 cm); ii) lymphovascular invasion; and iii) positivity for estrogen receptor (strong-moderate; ~30% positive cells), progesterone receptor (moderate-strong; ~70%), human epidermal growth factor receptor 2 (HER2; predisposition to 3+), HER2-fluorescence *in situ* hybridization and Ki 67 (~30%; data not shown). The 'left subclavian lymph node' (1/8,8 were tested, and one was positive) and 'left axillary level 1 and 2 lymph node' (13/28,28 axillary lymph nodes were examined, and cancer metastasis was found in 13 of them) were subsequently examined for cancer metastasis. This was followed by the postoperative diagnosis of invasive ductal carcinoma of the left breast (pT1N3M0 stage III; HER2 overexpression type). After surgery, the TCbHP chemotherapy regimen (docetaxel 108 mg d1, carboplatin 500 mg d1, trastuzumab 400 mg d1 and pertuzumab 840 mg d1) was given for two cycles (3 weeks each). After chemotherapy, the patient's renal function was aggravated, meaning that the chemotherapy regimen had to be adjusted to that of the THP regimen (docetaxel 100 mg d1, trastuzumab 400 mg d1 and pertuzumab 840 mg d1) for four cycles (3 weeks each). Chemotherapy was followed by endocrine therapy with Letrozole endocrine therapy (2.5 mg/day for 5 years), thereby targeted therapy was continued. The patient also attended the department of Radiotherapy, West China Hospital to receive radiotherapy. The radiotherapy physician fully communicated with the patient and family members about the procedures of postoperative radiotherapy, in addition to possible side effects and impact on the pacemaker (pacemaker dysfunction and permanent damage), before the patient signed the radiotherapy informed consent form.

Table I. Hospital examination results of the patient.

Test	Result
Dynamic electrocardiogram	Slow ventricular rate atrial fibrillation, minimum heart rate 29 beats/min, transient third-degree atrioventricular block, ventricular escape heart rate, complete right ventricular block and ST-T changes seen during sleep
Echocardiogram	The left ventricle was enlarged, the interventricular septum was significantly thickened, the posterior wall of the left ventricle was slightly thicker and the ascending aorta was widened. Tricuspid regurgitation (mild) and normal left ventricular systolic diastolic function were observed
Enhanced MRI of cardiac function	Asymmetrical thickening of the left ventricular wall. The thickest point was 2.3 cm and myocardial perfusion defect was observed with extensive delayed enhancement, slightly decreased left ventricular ejection fraction (45.8%), significantly decreased right ventricular ejection fraction (31.2%) and enlarged left and right atria
Laboratory examination	Serum creatinine, 151 μ mol/l; estimated glomerular filtration rate, 31.46 ml/min/1.73 m ²

Patient location was captured with Revolution CT ES (GE USA) and transmitted to the RayStation planning system (RaySearch Laboratories). The location was secured by the company's vacuum breast bag. And the CBCT acquisition parameters: scan sequence: ABC CC, scan Angle from 100°-260°, rotation speed 3.18°/s, FOV diameter 26 cm, length 26 cm, S20 filter plate, the corresponding pixel size is 0.100 cm spatial resolution. The image acquisition speed is 5.5 Frames/S, with a total of 400 and 361 frames. Total mAs:36.1 m As, medium resolution reconstruction. The scanning time of CBCT for each patient was about 1 min, the scanning volume was 410x263x410 mm, the scanning center was isocentry, the image resolution was 512x512, and the reconstruction layer thickness was 3 mm. Radiotherapy physicians delineated the target area as 'CTV1' (left upper and lower clavicle area) and CTV2 (left chest wall). Furthermore, the radiotherapy physicians delineated the OAR (organs at risk), such as lung, heart, left anterior descending coronary artery, spinal cord, shoulder joint and the pacemaker. PCTV1 and PCTV2 are formed by placing 6 mm outside CTV1 and CTV2, spinal cord was placed 6 mm outside to form spinal cord PRV, and pacemaker PRV was placed 6 mm outside PM. PRV means the area of displacement caused by the patient's respiratory movement due to changes in position during radiotherapy.

The prescribed dose of PCTV1 and PCTV2 was 46 Gy/23f. Volumetric modulated arc therapy (VMAT) technology, a form of radiotherapy, was used (4). A total of four arcs were planned. After designating the pacemaker as the boundary, the target area was divided into the upper and lower parts. The upper part had two arcs of 0-150°, whilst the lower part had two arcs of 295-140°. Direct rays passing through the pacemaker were avoided. The left chest wall was irradiated, whereas the radiation dose to the heart and lung was controlled and the lead barrier was locked at 2 cm below the pacemaker. This was set so that the pacemaker dose is regulated (Fig. 1) and that the dose to the organs at risk reaches the standard limit dose (Fig. 2).

Since a complex VMAT plan with target area segments was used, the physicist then performed the dose validation of the VMAT plan using ArcCHECK three-dimensional (3D)

array measurements (Sun Nuclear Corporation) and analyzed the gamma ray pass rate of the measured data to verify the accuracy of the plan. In addition, the physician evaluated the planned data from the planning system.

The dose to which the pacemaker was exposed was measured using a metal oxide semiconductor field effect transistor during the first treatment (Fig. 3), including the exposure dose during cone beam computerized tomography (CBCT) and during radiotherapy (inner, central and outer pacemaker positions; Table II). The estimated maximum cumulative dose of the pacemaker during radiotherapy was 225.4 cGy. To reduce the exposed dose of the pacemaker during CBCT, CBCT verification was performed twice a week for a total of 10 times, following which the maximum cumulative dose of the pacemaker was reduced to 70.6 cGy. In the case of concurrent radiotherapy and CBCT, the maximum involved dose of the pacemaker was 296.0 cGy (cumulative dose of 23 radiotherapy plus 10 CBCT). CBCT was performed 10 times throughout the course of treatment, so the remaining 13 times were not validated by CBCT. They all used the Optical Surface Imaging (OSI) Catalyst™ (TM) system for setup validation. For the remaining three times, optical surface imaging (OSI) Catalyst™ system (C-Rad) was used to verify the positioning. The combination of the two methods not only improved the precision of positioning and guaranteed the accurate implementation of the complex VMAT plan, but also effectively controlled the dose to which the pacemaker was exposed.

An hour before radiotherapy treatment (23 fractions, 5 times a fractions), the patient went to the Cardiology Department to check the parameters of the pacemaker and confirm that the instrument is in normal working condition. Before each cycle of radiotherapy, the patient went to the Cardiology Department to adjust the pacemaker to the asynchronous pacing mode to prevent excessive perception. After radiotherapy, the pacemaker was adjusted back to the original working mode to monitor the status of the device.

Before and after each cycle of radiotherapy, the patient was asked if they experienced any discomfort, where her vital signs were also monitored. During the treatment period, the patient's state was closely monitored, who was

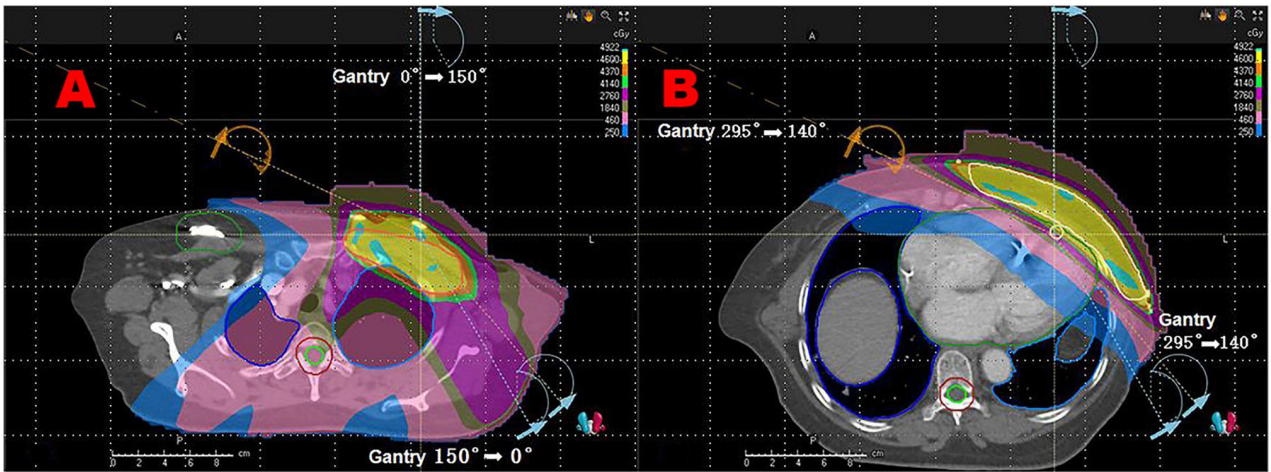


Figure 1. Radiotherapy planning target area and dose distribution. (A) Upper part of the target area 0-150° (two arcs). (B) Lower part of the target area 295-140° (two arcs). Areas are illustrated as follows: PCTV1 (planned area of the left upper and lower clavicular) in orange (supraclavicular, infraclavicular region); PCTV2 (planned area of the left chest wall) in white (chest wall); pacemaker and PRV (Planning organs at risk volume) in green; left anterior descending coronary artery in pale yellow.

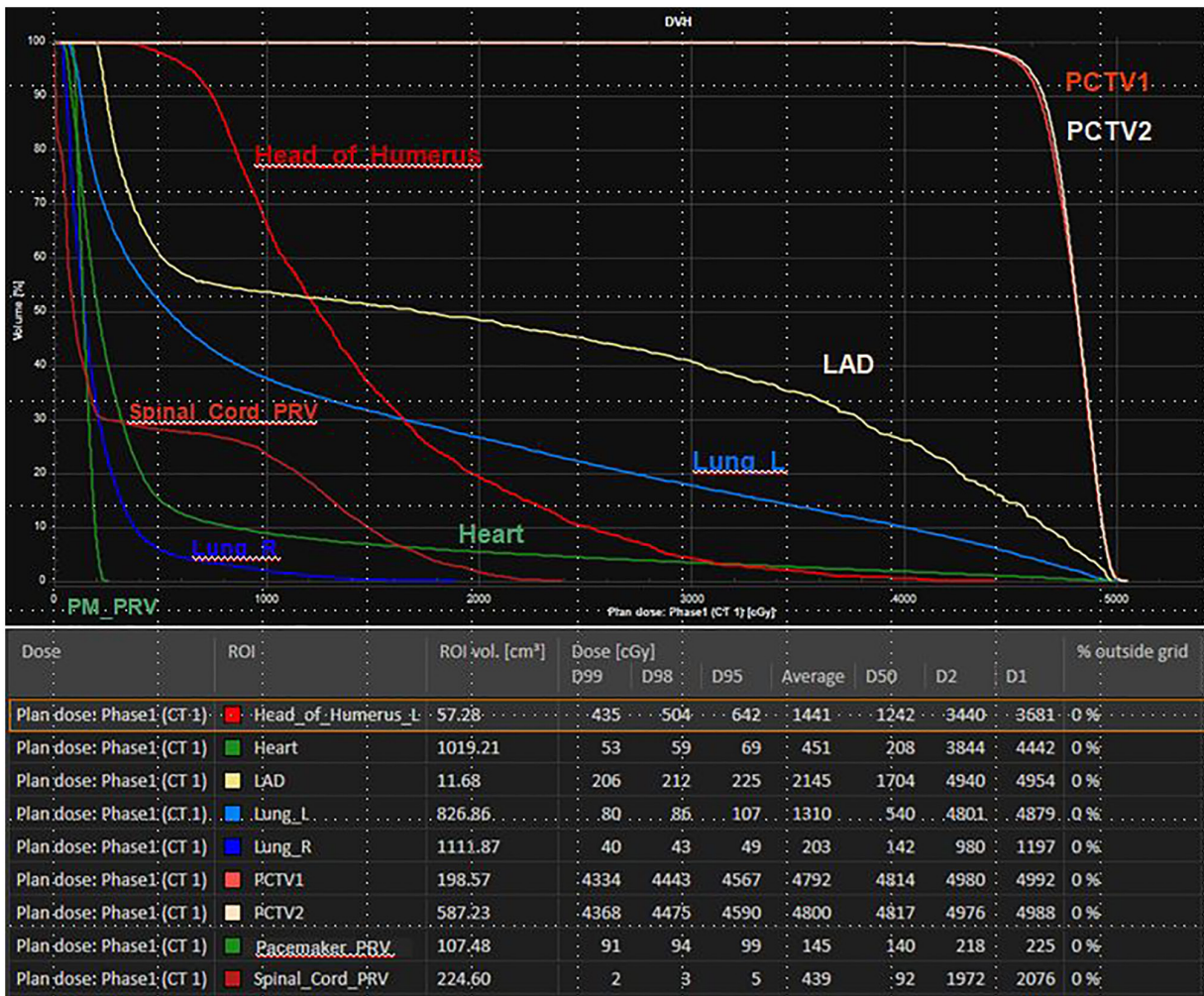


Figure 2. Dose volume histograms and doses of organ at risk. L, left; R, right; ROI, region of interest. PCTV1 is the left upper and lower clavicular planning area. PCTV2 is the left chest wall planning area; PRV, area of displacement caused by the patient's respiratory movement due to changes in position during radiotherapy.

also instructed to immediately raise her hand to report symptoms, including palpitation or chest tightness, in which

case the therapist would immediately stop radiotherapy. The treatment room was equipped with first-aid equipment.

Table II. Pacemaker irradiation dose.

Pacemaker position	Cone beam computerized tomography, cGy	Volumetric modulated arc therapy, cGy
Inner	7.06	9.80
Central	3.58	9.39
Outer	3.90	6.18

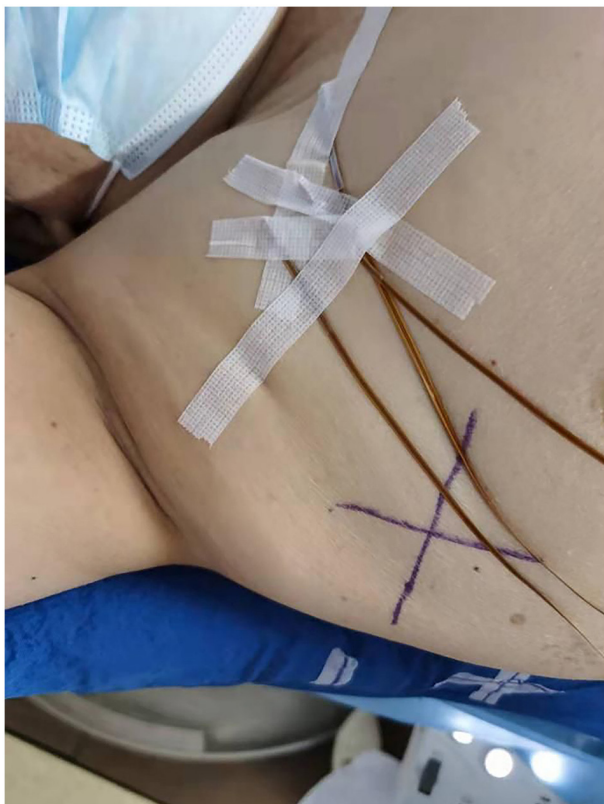

Figure 3. Measurements of the dose delivered to the pacemaker performed using metal oxide layer semiconductor field effect transistors. 'X' represents the position reference points marked on the patient's body.

Furthermore, if the patient encountered an emergency (such as Palpitation, chest tightness, tight breath), the radiotherapy physician, cardiologist and emergency physician would be immediately contacted for on-site first aid. The patient successfully completed radiotherapy. During radiotherapy, when the patient's cardiac pacemaker was adjusted to the asynchronous pacing mode, light activities (General physical activity, such as climbing the stairs 2 floors) were causing tiredness and palpitations. After adjusting back to the original mode, the symptoms were relieved and there was no cough, tightness of breath or second-degree skin reaction in the irradiated area.

As of April 2022, the patient has completed radiotherapy for 5 months and has not complained of any discomfort. There was no recurrence or metastasis of the tumor in a comprehensive review. Specific examinations included color ultrasound of breast chest wall, upper and lower clavicle, axillary lymph nodes, abdomen, and chest enhanced CT. The cardiac pacemaker remains in normal working condition.

Discussion

According to the Global Cancer Observatory database, there were 2,261,419 new cases of breast cancer in 2021, accounting for 11.7% of the total incidence of cancer (5). In particular, breast cancer has for the first time surpassed lung cancer as the most common cancer in women worldwide (5). At present, the number of patients with cardiovascular diseases in China has increased to >330 million, where there are ~1 million patients with bradycardia, with an average annual increase of 300,000-400,000 (6,7). For patients with bradycardia, implantation of a cardiac pacemaker is the only effective treatment (6). With the increase in cases of cardiac pacemaker implantations in China, the number of patients with heart disease complicated with tumors is likely to correspondingly increase. The safe implementation of radiotherapy regimens for such patients is an important obstacle faced by tumor radiotherapy physicians and therapists.

Cardiac implantable electronic devices (CIEDs) include cardiac pacemakers and implantable cardiac defibrillators (ICDs) (8). There are various factors that affect the use of CIEDs during radiotherapy. Ionizing radiation and electromagnetic fields generated during radiotherapy may cause pacemaker dysfunction, interfere with pacing function or even induce arrhythmias (9). Device malfunction is reported in 2.5% of patients with pacemakers and 6.8% of patients with ICD after radiotherapy (10). Regarding the influence of radiation dose and energy on CIED, the American Association of Physicists in Medicine (AAPM) recommended in its report no. 34 published in 1994 that in such patients, a cumulative dose received by pacemaker <2 Gy should be considered when planning radiotherapy (9). In addition, Memorial Sloan Kettering Cancer Center suggested that CIEDs should be outlined as organs at risk and optimized to the lowest dose, with a limit of 2-5 Gy for pacemakers and 0.5-2 Gy for ICDs (11). The device may suffer significant damage from direct exposure or from the use of energy >6 MV (10,12). Using energy of ≥ 10 MV, secondary neutrons can damage random access memory and additional semiconductors in modern devices (9,13). Finally, the distance between the radiation field and the pacemaker will affect the pacemaker, and the pacemaker will be placed in the irradiation field, which will cause the pacemaker device working obstacles. Irradiation field recommendations do not consider pacemakers (8). The pacemaker electrical pulse generator is normally implanted subcutaneously in the left subclavian area above the pectoral muscle through the subclavian vein. However, due to the left breast cancer radical surgery, in the present case the cardiologist chose the right axillary vein approach to implant the pulse generator subcutaneous device in the right clavicle area in preparation for the subsequent

Table III. Patient risk category.

Patient classification	<2 Gy	2-10 Gy	>10 Gy
Pacing-independent ^a	Low risk	Intermediate risk	High risk
Pacing-dependent ^b	Intermediate risk	High risk	High risk

^aIntrinsic ventricular rhythm of the heart is >30 beats/min and no emergencies related to bradycardia occur. ^bAbnormal operation of the implanted device causes a sudden stop of the heart rhythm, whilst the intrinsic rhythm of the heart is >30 beats/min, creating an emergency. Adapted from German Society of Radiation Oncology guideline, 2015 (12).

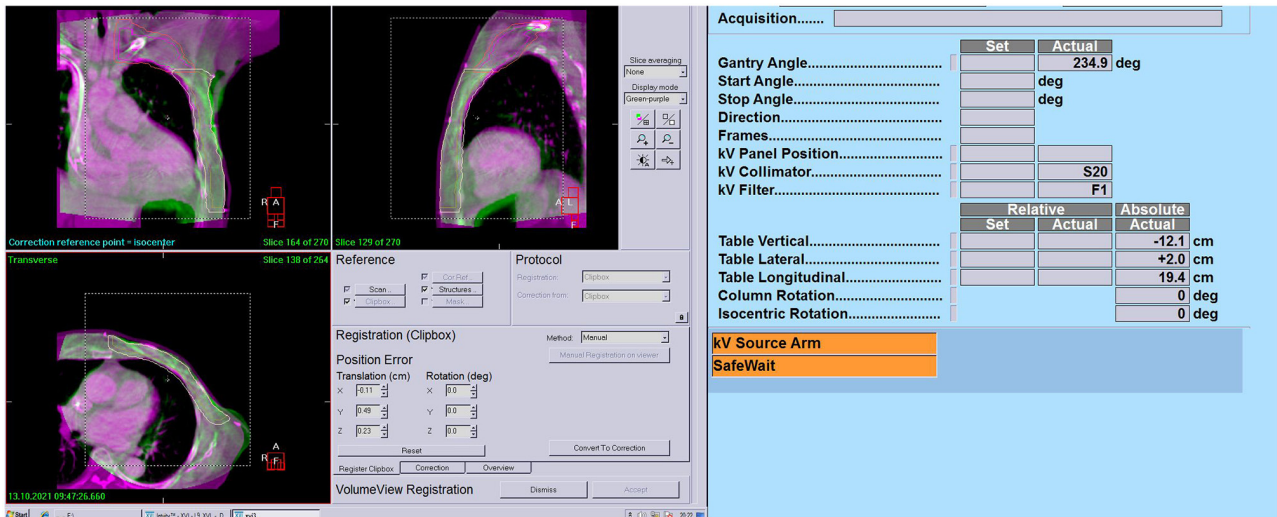


Figure 4. Cone beam CT alignment analysis. The main regions of interest are chest wall, upper and lower clavicle, vertebral body, and heart. Lat, lateral; long, longitudinal; vert, vertical; rot, Z axis rotation Angle.

radiotherapy. In addition, in the present case the manufacturer's protocols accompanying the pacemaker implanted into the patient indicated that to prevent excessive perception, the pacemaker can be programmed to asynchronous pacing mode, where such pacemaker parameters can be restored after radiotherapy. To prevent device damage, the pacemaker should be exposed to a dose of <5 Gy based on manufacturer's guidelines.

Indications for radiotherapy after mastectomy for patients with breast cancer include T3-4 and T1-2 tumors, ≥ 4 axillary metastatic lymph nodes and 1-3 positive axillary lymph node metastases (14). Therefore, there is a larger degree of heterogeneity in factors determining the indications for radiotherapy, not only with regards to the clinical and pathological characteristics of the patient, but also considering the systemic treatment (15). A previous meta-analysis performed by the Early Breast Cancer Clinical Trials Collaborative Group showed that for patients with positive axillary lymph nodes, post-operative radiotherapy reduced the 10-year overall recurrence rate and 20-year breast cancer-related mortality rate by 8.8 and 9.3%, respectively, in patients with ≥ 4 positive axillary lymph nodes (15). The target areas of radiotherapy mainly include the chest wall and supraclavicular lymphatic drainage area. By contrast, the efficacy of internal breast irradiation is controversial and is recommended in patients at high risk, such as patients with axillary metastatic lymph nodes ≥ 4 . Modern precision radiotherapy techniques such

as stereotactic radiotherapy, three-dimensional conformal radiotherapy and intensity modulated radiotherapy are recommended to accurately assess the dose of radiation delivered to normal tissues such as the heart. In addition, these techniques are recommended to adequately balance the benefits and risks of systemic therapy and radiotherapy in terms of heart-related injury following internal breast prophylaxis irradiation (15).

Although comprehensive treatment strategies of breast cancer has improved the long-term survival rate of patients, radiotherapy-induced late cardiotoxicity has emerged as a subject of concern (16). Darby *et al* (17) previously reported that ischemic heart disease after radiotherapy for breast cancer generally occurs 5 years after radiotherapy. In addition, the incidence is associated with the mean cardiac radiotherapy dose, such that for each increment in the mean dose by 1 Gy, the incidence of cardiac events, such as myocardial infarction, increases by 7.4%, with no significant threshold which means there was no significant minimum or maximum dose increase associated with the incidence of cardiac events (17). The most well-documented cardiotoxicity reduction study was performed in relation to the DIBH (Deep Inspiration Breath Holding) technique (18), which is typically used in combination with 3D conformal radiotherapy planning in tangential fields. Modern radiotherapy techniques, such as intensity-modulated radiotherapy (IMRT) and volumetric IMRT, have shown limited and inconsistent results in reducing cardiac dose. However, the results

Table IV. Dose region and risk category.

Patient classification	Dose region and risk category			
	<2 Gy	2-5 Gy	>5 Gy	Neutrons present
Pacing independent	Low risk	Medium risk	High risk	High risk
Pacing dependent	Medium risk	Medium risk	High risk	High risk

Adapted from Association of Physicists in Medicine TG-203 report, 2019 (21).

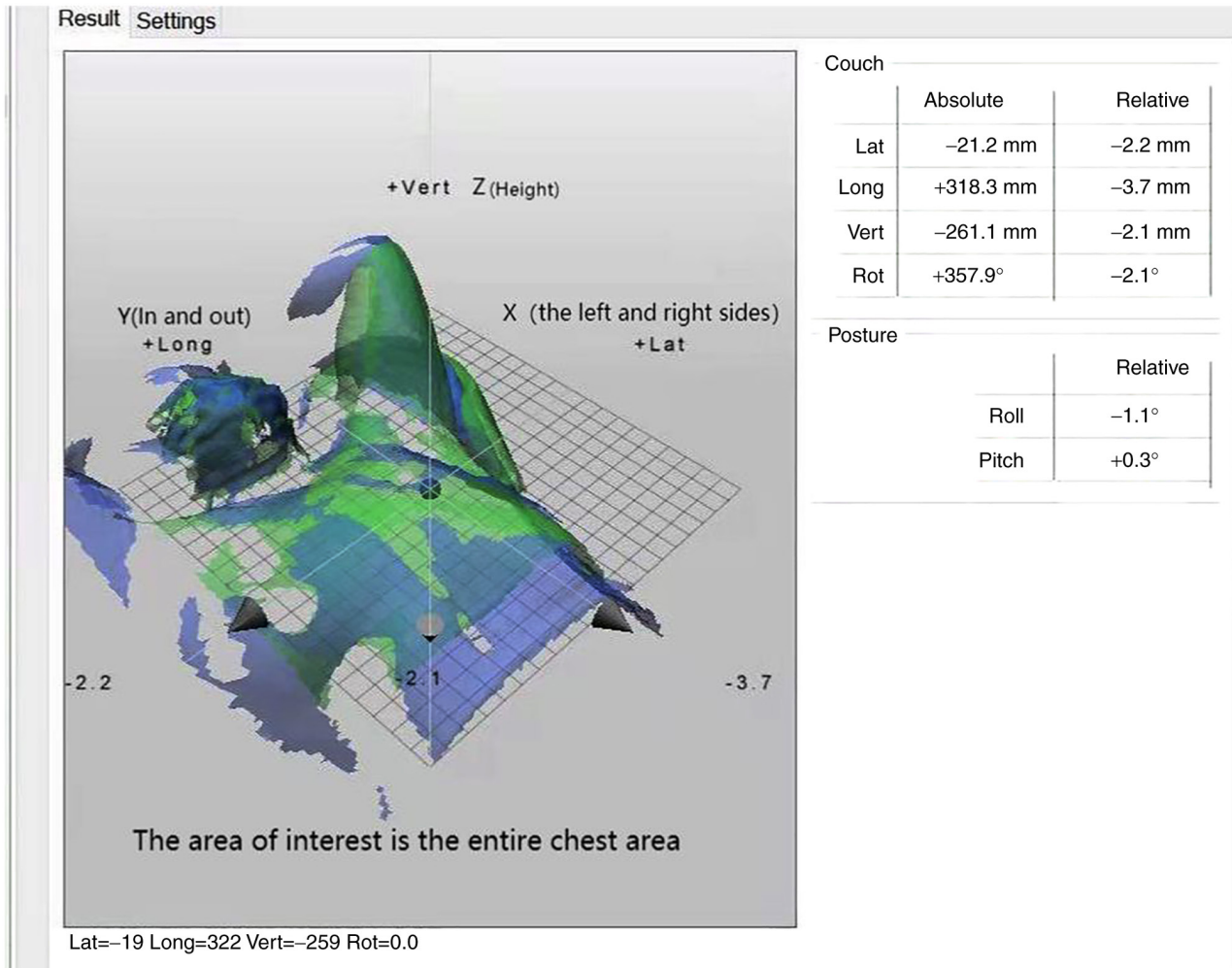


Figure 5. Alignment results of the optical surface imaging system. The main regions of interest are chest wall, upper and lower clavicle, vertebral body, and heart. Lat, lateral; long, longitudinal; vert, vertical; rot, Z axis rotation Angle; Roll, Y-axis rotation Angle; Pitch means X axis rotation Angle.

have been inconsistent (19). A previous dosimetry study by Popescu *et al* (20) found that conventional intensity-modulated radiotherapy (IMRT) and VMAT improved the dose distribution in the target region compared with that following 3D conformal radiotherapy with tangent field. Compared with conventional IMRT, VMAT reduces the average dose delivered to the heart and lung, resulting in improved protection of the organs at risk and shorter irradiation time (21). However, both techniques do increase the low-dose irradiation of surrounding healthy tissues at the same time. VMAT is also the treatment that it is commonly adopted by the authors of the present case report (20).

According to Guidelines for Chinese Physicians (15) and postoperative staging of the patient, the target area of radiotherapy should include the left chest wall and the lymphatic drainage area above and below the left clavicle. Subject to cardiac dose safety, the internal breast lymphatic drainage area can also be considered. The patient in the present case exhibited a combination of hypertrophic cardiomyopathy, an enlarged heart adjacent to the left chest wall and pacemaker implantation. Chemotherapy containing paclitaxel and targeted anti-HER2 therapy are cardiotoxic, meaning that radiotherapy requires strict control in terms of both cardiac and pacemaker doses,

which poses a great challenge to radiotherapists and physicians (22). We first adopted the DIBH-ABC technology, which is the characteristic technology of our hospital, and adopted the active breathing control device ABC to achieve deep inspiratory breath holding. ABC is a respiratory gating device manufactured by Swedish Medical company. Breathing training was performed for the patient for a week but discontinued because the patient's breath hold time was too short to cooperate with the technique. To improve the conformability of the target area and lower the cardiac dose, the radiation physicist used both static IMRT and VMAT techniques. Finally, the VMAT radiotherapy plan for the four arcs of the target area segment reached the limiting dose for organ and pacemaker endangerment, after discarding the internal breast target area and reducing the prescribed dose of radiotherapy to 46 Gy/23f. The upper part of the two non-tangential field direction arcs with smaller irradiation angles reduced the dose delivered to the pacemaker. The lower part of the two tangential field direction arcs with high conformality of the target area provided an improved control over the dose delivered to the heart and lung, which locked the lead gate adjacent to the pacemaker. This reduced the leakage of radiation from the multi-Leaf Collimator, further controlling the pacemaker dose. Due to the use of complex VMAT plans in the target area, the accuracy of the dose was verified by the radiation physicist before treatment. Chan *et al* (11) recommended the use of *in vitro* dose detection systems, such as optically-stimulated luminescence dosimeters, thermoluminescent dosimeters and diodes. The dose delivered to the device is measured on the first day of treatment to predict the cumulative dose throughout radiotherapy (11). The dose delivered to the pacemaker was measured on the first treatment, where the estimated maximum cumulative dose of the pacemaker throughout radiotherapy was 225.4 cGy, which was consistent with the radiotherapy plan. The maximum irradiated dose delivered to the pacemaker at a single CBCT was also measured to be 7.06 cGy, which provided a basis for predicting the additional irradiation dose of CBCT delivered to the pacemaker.

To precisely implement the VMAT radiotherapy plans in four arcs, image-guided radiotherapy techniques are needed. Borst *et al* (23) found that >50% patients with thoracic tumors who did not receive CBCT scans to assist with radiotherapy had setup errors of as high as 5 mm off target or higher. A number of studies have previously demonstrated that CBCT image guidance can reduce the positional error, decrease the toxic side effects of radiotherapy and help patients to receive more accurate radiation therapy (24,25). It has also been shown that the monitoring error of the OSI Catalyst-(TM) system is 0.24 ± 0.04 mm, with the maximum measurement error 0.33 ± 0.05 mm (26). Wikström *et al* (27) reported that the pendulum error calculated from the comparison of real-time with reference images has a repeatability difference of 0.2 mm. Since OSI is a noninvasive and radiation-free real-time extracorporeal monitoring system that has high degrees of accuracy for real-time motion monitoring, it has been proposed for use for the position verification of patients in a clinical setting (26,28). After CBCT scanning, the 3D image of the patient's anatomical volume reconstructed by the system was registered online with the imported CT positioning image (Fig. 4). Finally, radiotherapy can be performed after the matching area and registration mode are determined by

radiotherapy physicians. The OSI system is a stereo imaging system consisting of three high-definition cameras and led light sources fixed around the treatment bed at an angle of 120° . A calibrated CBCT image was collected as a reference image for OSI when this was first used for verification. The Light generator was then used to form the image of the patient's body surface whereas the charge-coupled device camera was used to obtain the reprojection. The visible light source calculated the error between the real-time body surface image and the reference image before directly projecting it onto the patient's body surface. The therapist calibrated the positioning error in the three directions before performing the treatment (Fig. 5).

Chan *et al* (11) suggested that patients should be positioned for verification and that the firing field should be angled to reduce the exposure dose of the device. For the same consideration, during CBCT imaging before treatment, the collimator and filter should be reasonably selected to avoid direct radiation on the pacemaker (11). The patient received radiotherapy under the medical ELekta Synerg accelerator. When CBCT was performed, the initial angle of the scan sequence was pre-set at 120 - 260° . The collimator used S20 (collimator with a small-field axial field length of 276.7 mm) and the F1 filter plate to reduce the radiation dose delivered to the pacemaker. F1 is a conformal filter, the collimator and filter are placed in the two slots of the KV source arm. In this manner, the quality of treatment and the safety of radiotherapy were optimized.

Various guidelines and reviews have been published internationally to guide the management of patients with implanted cardiac electronic devices receiving radiotherapy (11,12,29,30). Patients are first classified into low-, intermediate- and high-risk groups by cumulative dose and pacing dependence (Table III), with slight differences among different guidelines. For example, the risk stratification reported in the 2019 AAPM TG-203 guidelines (30) (Table IV) incorporated the presence or absence of neutron irradiation in addition to proposing stricter limits on the cumulative dose. Patients are then managed according to the different stages of radiotherapy with different risk stratifications. Although the recommendations for patient management vary slightly among guidelines, all emphasize the importance of close multidisciplinary collaboration among cardiologists, radiation oncologists, physicists, therapists and pacemaker specialist technicians. General management measures during radiotherapy include reprogramming to asynchronous pacing or placing magnets for pacemaker-dependent patients, delaying antiarrhythmic therapy and reprogramming or placing magnets at each radiotherapy session for patients with ICD (29). Different management measures are used for patients in different risk strata. For low-risk patients, the patient symptoms and vital signs are closely monitored, whilst weekly device checks are required for those with ICDs only (29). For medium-risk patients, emergency equipment is required (such as cardiac monitor and defibrillator), whilst for device-dependent patients, an external pacemaker should be available and a team of professionals (cardiologist, pacemaker specialist technician and resuscitator) should be available to ensure immediate intervention in case of an emergency, in addition to the device being checked weekly. For high-risk patients, the benefits of treatment should be weighed against the risk of inducing damage if device repositioning is not feasible. Electrocardiogram (ECG) monitoring should be

performed at each radiotherapy session and the device should be checked within 24 h after each treatment (29). The device should be regulated at 1, 3 and 6 months after the end of radiotherapy (29). In the present case report, the patient had a minimum cardiac rhythm of 29 beats/min on the 24-h ambulatory ECG before pacemaker implantation and the predicted maximum pacemaker involvement dose was 296.0 cGy. According to the AAPM TG-203 report, since the patient was classified to be a medium-risk patient, the aforementioned recommended management measures were followed. The patient successfully completed radiotherapy with only discomfort caused by changes in pacing patterns, with no pacemaker damage or functional abnormalities found upon regular cardiology examinations after radiotherapy was completed.

In conclusion, in the era of precision radiotherapy, the use of modern radiotherapy techniques, including radiotherapy planning assessment systems, intensity-modulated radiotherapy techniques, extracorporeal dosimetry and real-time image guidance, allows for the accurate assessment, limitation and prediction of the pacemaker dose. In addition, the use of risk-stratified management measures, with the participation of a multidisciplinary team, allows for the safe administration of radiotherapy to patients with pacemaker-implanted tumors.

Acknowledgements

Not applicable.

Funding

No funding was received.

Availability of data and materials

The datasets used and/or analyzed during the current study are available from the corresponding author on reasonable request.

Authors' contributions

YW and LX drafted the manuscript. LX performed the manuscript review and revision. JZ, YH, CL and YS performed patient planning, radiotherapy and data collection. LZ performed dose verification and pacemaker dosimetry. YW performed data analysis and drafted the manuscript. LX interpreted the data. YW and LX confirm the authenticity of all the raw data. All authors have read and approved the final manuscript.

Ethics approval and consent to participate

Not applicable.

Patient consent for publication

Written informed consent was obtained from the patient for publication of the present case report.

Competing interests

The authors declare that they have no competing interests.

References

1. Cao M and Chen W: Interpretation of Global cancer statistics in GLOBOCAN 2020. *Chin J Frontier Medicine* (electronic edition) 13: 63-69, 2021 (In Chinese).
2. Coldman AJ and Phillips N: Breast cancer survival and prognosis by screening history. *Br J Cancer* 110: 556-559, 2014.
3. Hua W and Zhang S: Interpretation of the 2012 ACCF/AHA/HRS Guidelines for the treatment of arrhythmia devices. *Chin J Cardiac Arrhythmias* 2012: 467, 2012 (In Chinese).
4. Bradley JA and Mendenhall NP: Novel Radiotherapy Techniques for Breast Cancer. *Annu Rev Med* 69: 277-288, 2018.
5. Duggan C, Trapani D, Ilbawi AM, Fidarova E, Laversanne M, Curigliano G, Bray F and Anderson BO: National health system characteristics, breast cancer stage at diagnosis, and breast cancer mortality: A population-based analysis. *Lancet Oncol* 22: 1632-1642, 2021.
6. National Center for Cardiovascular Diseases: Annual report on cardiovascular health and diseases in China 2020. *J Cardiovasc Pulm Dis* 40: 1005-1009, 2021.
7. National Cardiovascular Disease Center: China Cardiovascular Health and Disease Report 2019. Science Press, 2020.
8. Zhang T and Li X: Research progress of radiotherapy for patients with tumor with implanted cardiac pacemaker. *Chin J Interventional Cardiol* 37: 237-240, 2017 (In Chinese).
9. Marbach JR, Sontag MR, Van Dyk J and Wolbarst AB: Management of radiation oncology patients with implanted cardiac pacemakers: Report of AAPM Task Group No. 34. American Association of Physicists in Medicine. *Med Phys* 21: 85-90, 1994.
10. Zaremba T, Jakobsen AR, Sogaard M, Thøgersen AM, Johansen MB, Madsen LB and Riahi S: Risk of device malfunction in cancer patients with implantable cardiac device undergoing radiotherapy: A population-based cohort study. *Pacing Clin Electrophysiol* 38: 343-356, 2015.
11. Chan MF, Young C, Gelblum D, Shi C, Rincon C, Hipp E, Li J and Wang D: A Review and Analysis of Managing Commonly Seen Implanted Devices for Patients Undergoing Radiation Therapy. *Adv Radiat Oncol* 6: 100732, 2021.
12. Gauter-Fleckenstein B, Israel CW, Dorenkamp M, Dunst J, Roser M, Schimpf R, Steil V, Schäfer J, Höller U and Wenz F; DEGRO/DGK: DEGRO/DGK guideline for radiotherapy in patients with cardiac implantable electronic devices. *Strahlenther Onkol* 191: 393-404, 2015.
13. Soejima T, Yoden E, Nishimura Y, Ono S, Yoshida A, Fukuda H, Fukuhara N, Sasaki R, Tsujino K and Norihisa Y: Radiation therapy in patients with implanted cardiac pacemakers and implantable cardioverter defibrillators: A prospective survey in Japan. *J Radiat Res* 52: 516-521, 2011.
14. Wei J, Guo Y, Wang Y, Wu Z, Bo J, Zhang B, Zhu J and Han W: Clinical development of CAR T cell therapy in China: 2020 update. *Cell Mol Immunol* 18: 792-804, 2021.
15. Chinese Physicians Association, Radiation Oncology Therapy Physicians Branch: Radiation Therapy Guidelines for Breast Cancer (CMA 2020 Edition). *Chin J Radiat Oncol* 30: 321-342, 2021 (In Chinese).
16. Wang S: Radiotherapy for Left-sided Breast Cancer: Focusing on Heart Dosimetry (unpublished PhD thesis). Zhejiang University, 2018.
17. Darby SC, Ewertz M, McGale P, Bennet AM, Blom-Goldman U, Brønnum D, Correa C, Cutter D, Gagliardi G, Gigante B, *et al*: Risk of ischemic heart disease in women after radiotherapy for breast cancer. *N Engl J Med* 368: 987-998, 2013.
18. Shengye W: Cardiac dosimetry of radiotherapy for left breast cancer (unpublished PhD thesis). Zhejiang University, 2018.
19. Duma MN, Baumann R, Budach W, Dunst J, Feyer P, Fietkau R, Haase W, Harms W, Hehr T, Krug D, *et al*: Heart-sparing radiotherapy techniques in breast cancer patients: A recommendation of the breast cancer expert panel of the German society of radiation oncology (DEGRO). *Strahlenther Onkol* 195: 861-871, 2019 (In English).
20. Popescu CC, Olivetto IA, Beckham WA, Ansbacher W, Zavgorodni S, Shaffer R, Wai ES and Otto K: Volumetric modulated arc therapy improves dosimetry and reduces treatment time compared to conventional intensity-modulated radiotherapy for locoregional radiotherapy of left-sided breast cancer and internal mammary nodes. *Int J Radiat Oncol Biol Phys* 76: 287-295, 2010.
21. Ahmad SS, Duke S, Jena R, Williams MV and Burnet NG: Advances in radiotherapy. *BMJ* 345: e7765, 2012.

22. Han Y, Chen K, Li Q and Chen J: Study on the application of A-DIBH method to reduce the cardiac dose in patients undergoing radiotherapy after breast-conserving surgery for left-sided breast cancer. *Chin Modern Doctor* 60: 84-87+197, 2022 (In Chinese).
23. Borst GR, Sonke JJ, Betgen A, Remeijer P, van Herk M and Lebesque JV: Kilo-voltage cone-beam computed tomography setup measurements for lung cancer patients; first clinical results and comparison with electronic portal-imaging device. *Int J Radiat Oncol Biol Phys* 68: 555-561, 2007.
24. Hansen EK, Larson DA, Aubin M, Chen J, Descovich M, Gillis AM, Morin O, Xia P and Pouliot J: Image-guided radiotherapy using megavoltage cone-beam computed tomography for treatment of paraspinal tumors in the presence of orthopedic hardware. *Int J Radiat Oncol Biol Phys* 66: 323-326, 2006.
25. Wu Y, Zhong R, Liu Z, Ye C, Chen L, He Z and Bai S: Management of cone beam CT technique for patient positioning in radiotherapy. *J Cancer Control Treatment* 23: 156-158, 2010 (In Chinese).
26. Chen L, Bai L, Li G, Quan H and Bai S: Real-time motion tracking accuracy of optical surface imaging system. *Chin J Med Physics* 38: 1053-1056, 2021 (In Chinese).
27. Wikström K, Nilsson K, Isacson U and Ahnesjö A: A comparison of patient position displacements from body surface laser scanning and cone beam CT bone registrations for radiotherapy of pelvic targets. *Acta Oncol* 53: 268-277, 2014.
28. Gierga DP, Riboldi M, Turcotte JC, Sharp GC, Jiang SB, Taghian AG and Chen GT: Comparison of target registration errors for multiple image-guided techniques in accelerated partial breast irradiation. *Int J Radiat Oncol Biol Phys* 70: 1239-1246, 2008.
29. Salerno F, Gomellini S, Caruso C, Barbara R, Musio D, Coppi T, Cardinale M, Tombolini V and de Paula U: Management of radiation therapy patients with cardiac defibrillator or pacemaker. *Radiol Med* 121: 515-520, 2016.
30. Miften M, Mihailidis D, Kry SF, Reft C, Esquivel C, Farr J, Followill D, Hurkmans C, Liu A, Gayou O, *et al*: Management of radiotherapy patients with implanted cardiac pacemakers and defibrillators: A Report of the AAPM TG-203†. *Med Phys* 46: e757-e788, 2019.



This work is licensed under a Creative Commons Attribution-NonCommercial-NoDerivatives 4.0 International (CC BY-NC-ND 4.0) License.