



Contents lists available at ScienceDirect

The Saudi Dental Journal

journal homepage: www.ksu.edu.sa
www.sciencedirect.com

Original Article

Evaluation of periodontal parameters on abutment teeth rehabilitated with single-unit crowns: A 12-month follow-up

Anne Kaline Claudino Ribeiro^{a,*}, Anna Clara Gurgel Gomes^b, Larissa Araújo Luz de Oliveira^a, Davi Neto de Araújo Silva^c, Luana Maria Martins de Aquino^d, Ana Rafaela Luz de Aquino Martins^e^a Department of Dentistry, Federal University of Rio Grande do Norte (UFRN), Natal, RN, Brazil^b Bauru School of Dentistry, University of São Paulo (USP), São Paulo, SP, Brazil^c Section of Periodontics, School of Dentistry, University of California, Los Angeles, CA, United States^d Mauricio de Nassau University Center (UNINASSAU), Natal, RN, Brazil^e Department of Dentistry, Federal University of Rio Grande do Norte (UFRN), Natal, Brazil

ARTICLE INFO

Keywords:

Dental Marginal Fit
Periodontal Index
Periodontium
Tooth Crown

ABSTRACT

Purpose: This prospective study evaluated the effects of the metal-free crowns on the periodontal tissues of abutment teeth during a 12-month follow-up.**Materials and Methods:** A sample of 24 patients (N = 32 abutment teeth) who needed a single-tooth restoration were enrolled to receive either a metal-ceramic (n = 21) or lithium disilicate (n = 11). The single-unit crowns were evaluated at baseline, 3-and 12-month follow-up. The periodontal parameters were evaluated: plaque index (PI), gingival bleeding index (GBI), bleeding on probing (BOP), probing depth (PD), clinical attachment loss (CAL), radiographically and clinical crown fitting, bone resorption, and marginal finish lines. Statistical analyses were performed using the Exact Fisher and Mann-Whitney tests, and the Wilcoxon signed-rank test as a post hoc test for Friedman (95 % confidence interval).**Results:** The marginal finish line showed a statistical difference with a biomaterial type (p = .004). After a 12-months, a significant increase was observed in PI and mean PD for abutment teeth of metal-ceramic crowns. The metal-free crowns presented higher values for GBI and CAL (p₂ < 0.05). Only distal cervical evaluation and dental biofilm formation in the abutment teeth showed a statistical difference between the groups at the 12-month follow-up. The supragingival margin metal-ceramic group revealed higher PI values (p₂ = 0.005) between the period and the subgingival margin of both biomaterials showed greater GBI scores (p₂ < 0.05).**Conclusions:** Metal-free crowns showed better periodontal outcomes compared to metal-ceramic crowns. Single-unit crown marginal location affects the periodontal tissue condition of the abutment teeth. The marginal fit was not changed regarding the biomaterial type.

1. Introduction

Single crowns (SCs) and Fixed Partial Dentures (FPDs) are the most reliable treatment options to replace missing teeth or with extensive coronal destruction (Nicolaisen et al., 2016). The preservation of tooth structures and maintenance of gingival tissue health from FPDs is a well-established treatment and has provided promising clinical outcomes (McCracken et al., 2016). Although the choice of material type is

multifactorial, biological principles should be followed to preserve marginal integrity and periodontal health (Nugala et al., 2012).

The predictability and success of the SCs and FPDs treatments are associated with periodontal tissue responses. Some situations require a dental crown such as severely broken-down teeth, dental carious, or endodontic treatment (McCracken et al., 2016). However, improper dental prostheses may result in dental biofilm development, contributing to the progression of periodontal disease (Avetisyan et al., 2021).

* Corresponding author at: Federal University of Rio Grande do Norte (UFRN), Department of Dentistry, Av. Sen. Salgado Filho, 1787, Natal, Rio Grande do Norte 59056-000, Brazil.

E-mail addresses: anne_claudino@hotmail.com (A.K.C. Ribeiro), annaclarag@yahoo.com.br (A.C.G. Gomes), larissluz@gmail.com (L.A.L. de Oliveira), davinetoaraujo@yahoo.com.br (D.N. de Araújo Silva), luanaquino@hotmail.com (L.M.M. de Aquino), anarafaella.luz@terra.com.br (A.R.L. de Aquino Martins).

<https://doi.org/10.1016/j.sdentj.2024.03.019>

Received 3 August 2023; Received in revised form 24 March 2024; Accepted 25 March 2024

Available online 27 March 2024

1013-9052/© 2024 THE AUTHORS. Published by Elsevier B.V. on behalf of King Saud University. This is an open access article under the CC BY-NC-ND license (<http://creativecommons.org/licenses/by-nc-nd/4.0/>).

Moreover, defective crowns may favor the environment for microbial growth, leading to bone loss, gingival sulcular fluid flow (Srimaneepong et al., 2022), and adverse effects on the quality of life and patient satisfaction (Serra-Pastor et al., 2021).

Understanding the biocompatibility between the FDPs and the periodontium is essential for the prognostic of the treatment. Evaluation of the incidence of complications, clinical performance, and survival rates (Gseibat et al., 2022, Ispas et al., 2022) have been documented and literature reviews have reported the interactions between periodontal health and prosthetic restorations (Ercoli et al., 2021, Léon-Martínez et al., 2020), considering the biomaterial type. However, longitudinal studies investigating radiographic and clinical periodontal parameters regarding single-unit crowns remain scarce.

Therefore, this study aimed to assess the effects of SCs rehabilitation using metal-free (lithium disilicate) and metal-ceramic on the periodontal tissues of the abutment teeth. The study hypothesis was that (1) no difference would be found between the material type and the evaluated parameters; (2) differences would be found between the biomaterial types according to follow-up periods and regarding the marginal finish line; and (3) statistically significant differences would be observed between the biomaterial type of the single crowns and the marginal location.

2. Materials and Methods

2.1. Study design, participants, and eligibility criteria

This prospective clinical pilot study was conducted at the Federal University of Rio Grande do Norte (UFRN) and the study protocol was previously approved by the Institutional Ethics Committee (protocol number 1.132.562).

The 24 participants represent a convenience sample of patients who sought treatment in the Faculty of Dentistry for Dental Fixed Prosthesis Rehabilitation. Patients who needed at least one tooth with a fixed prosthesis SC were recruited to participate in the study and were treated in the clinic at the Department of Dentistry (UFRN). A total of 32 abutment teeth were prepared and the SCs were cemented.

Inclusion criteria: patients with indication for the SC, vital abutment or suitable endodontic treatment, occlusal stability, periodontal health displayed a pocket depth ≤ 3 mm (no other signs of inflammation), no active periodontal disease, and no tooth mobility.

Exclusion criteria: users of removable partial dentures, rehabilitated with FPD, signs of bruxism, clenching of the teeth or temporomandibular joint disorders, malocclusion, pregnancy or breastfeeding, systemic or local drug use that could provide adverse effects on gingival health, systemic illnesses or conditions that affect periodontal tissues, and psychological or physical conditions, such as the inability to travel to the treatment location.

The eligible participants were informed of the nature of the research and signed an informed consent form.

2.2. Evaluation of clinical and radiographic methods

During the anamnesis and clinical examination, details regarding restorations and teeth presence were recorded in the odontogram. The decision-making about clinical crown lengthening was required depending on the tooth condition that would receive the single-tooth restoration. In this case, the healing time of 4 weeks was considered before the initial procedures for prosthetic preparation of the tooth.

The localization of the margin in the preparation of the crowns followed the principles to maintain the health of the structure of periodontal tissues. Although the better health condition is the supragingival margin, the subgingival extension was performed in cases of subgingival caries lesions or increased retention of preparations in teeth with short clinical crowns or esthetic reasons.

All patients received non-surgical periodontal treatment. Manual

curettes were used for subgingival and supragingival scaling, removing calculus, and dental biofilm. Dental preparations were conducted, and temporary restorations were cemented (Provicol, VOCO GmbH, Germany). Lithium disilicate (IPS e.max Press, Ivoclar, Vivadent, Liechtenstein) or porcelain-fused to metal (cobalt-chromium substructure, and opaceous and veneering ceramic layer) crowns were fabricated. The definitive SCs were made in the same laboratory and procedures followed a standardized scheme. Try-in, contact points, and clinical occlusal adjustment were performed. Dual-curing resin cement was used for cementation following the manufacturer's recommendations. After cementation, patients received an oral hygiene briefing. Clinical appointments were scheduled after 1 week (baseline), 3- and 12-month follow-up of the delivery of the crowns. At subsequent clinical appointments, if necessary, supportive and maintenance periodontal therapy was carried out to establish an oral environment compatible with periodontal tissue health. Fig. 1 shows the study flow diagram.

The clinical parameters recorded were the plaque index (PI), gingival bleeding index (GBI), bleeding on probing (BOP), probing depth (PD), and clinical attachment loss (CAL) of the abutment teeth. PI (%) and GBI (%) were evaluated as presence and absence on the main surfaces of the teeth. PD (mm), BOP (%), and CAL (mm; sum of PD and GR) were performed in the abutment teeth. The clinical periodontal examination was conducted using a clinical mirror n.5 (Golgran, Brazil), the WHO, and Williams periodontal probes (Golgran, Brazil). The WHO periodontal probe, a slender instrument with a 0.5 mm ball tip and a black band ranging from 3.5 mm to 5.5 mm marks, was used to evaluate the parameters PI, GBI, and BOP. For the measurement of pocket depth and attachment level, the Williams periodontal probe was used.

The marginal fit of the SCs on the prepared tooth was clinically evaluated by tactile and visual examination using a sharp explorer on the buccal and lingual/palatal surfaces. Biomaterial type, marginal finish line location, and position in the dental arch of the SCs were noted in the patient's clinical records. The radiographic examination was carried out to analyze whether there was bone loss, and to verify the marginal fit in the mesial and distal surfaces.

Periapical radiographs were taken at follow-up appointments. The parallel dental radiographic technique was performed using a Han Shin intraoral positioner (Indusbelo, Brazil). To standardize angulation and film position, the rubber of the positioner was duplicated with condensation silicone putty (Perfil, Coltene, Brazil) in a dappen glass. In addition, a self-curing acrylic resin device (Decrilon, Dencril, Brazil) was obtained. This device was inserted into the patient's mouth together with the positioner and a portion of the red self-curing acrylic resin (Dencrilay, Dencril, Brazil) (Melo et al., 2017). Thus, the patient bite registration was obtained. All periapical radiographs were taken in the Radiology Department using the same device for radiograph examination (Dabi Atlante, Spectro70X Seletronic) with an exposure time of 0.40 s.

All measurements to evaluate the mesial and distal marginal fit and the distance between the cervical margin to the alveolar crest (AC) were made on different days within a dark environment on the negatoscope by a previously trained examiner. The measurements were performed using a transparent ruler (mm) and a magnifying glass. The radiographic assessment was recorded repeatedly in five patients over 7 days for verification of the measurement. The concordance tests were verified to obtain a Kappa test > 0.8 , which indicated almost perfect intra-agreement (Landis and Koch, 1977).

2.3. Statistical analysis

The G*Power software (version 3.1.9.7, Heinrich-Heine-Universität Düsseldorf, Germany) was used to calculate the post-hoc power analysis. Differences in mean for the 26 abutment teeth were observed, considering large effect size $d = 0.80$ and $\alpha = 5\%$. Statistical analysis was performed using SPSS software version 20.0 for Windows. Fisher's Exact Test was used to evaluate an association between material type and

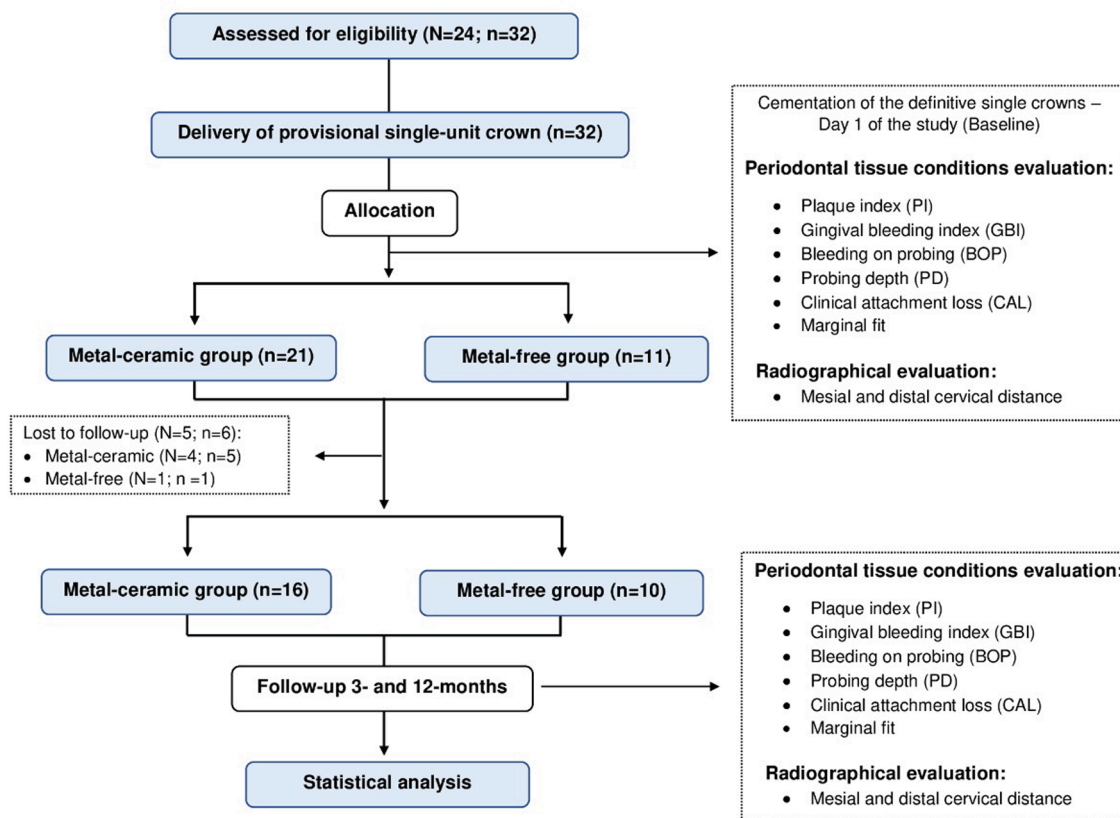


Fig. 1. Study flow diagram.

tooth-related variables, and the relationship between the biomaterial and clinical and radiographic characteristics. The Mann-Whitney test was used to assess statistical differences between the groups and periodontal parameters regarding the follow-up period. The Friedman test was conducted to analyze radiographic and periodontal parameters intragroup, at baseline, after 3- and 12-month follow-ups. When the Friedman test revealed a statistically significant difference, the post-hoc Wilcoxon test was applied. A 5 % significance level ($p \leq 0.05$) was used for all analyses.

3. Results

3.1. Sample characterization

A sample power of 94.7 % was obtained for the 26 abutment teeth. Nineteen patients were rehabilitated with SCs. The mean age of the patients was 44.00 years (± 12.58). Eleven patients (57.9 %) received metal-ceramic crowns (MC) and 8 (42.1 %) were treated with IPS e.max Press crowns (MF). A total of 26 fit-well SC (MC = 16; MF = 10) were included in the statistical analysis. Of the total sample of participants, 73.7 % had 1 abutment teeth assessed, 15.8 % had 2 abutment teeth examined, and 10.5 % had 3 abutment teeth evaluated at baseline, 3- and 12-months follow-up. Most MC crowns were placed in the posterior teeth (78.6 %). A statistical association was found between the material type and the marginal finish line. Table 1 shows the association between single crown biomaterial and tooth-related variables.

3.2. Clinical and radiographic evaluation

Table 2 shows the analyses of the radiographic and periodontal parameters at baseline, 3- and 12-months after rehabilitation with the SCs. In the intergroup evaluation, metal-ceramic crowns presented higher scores for distal cervical distance only for a 12-month time point ($p_1 =$

Table 1 Association between the biomaterial type regarding tooth-related variables.

	n	Metal-ceramic n (%)	Metal-free n (%)	RR	95 % CI	p^*
Marginal finish line						
Supragingival	26	13 (86.7)	2 (13.3)	3.17	1.18–8.51	0.004¹
Subgingival		3 (27.3)	8 (72.7)			
Tooth Position						
Anterior	26	5 (41.7)	7 (58.3)	0.53	0.25–1.09	0.105 ¹
Posterior		11 (78.6)	3 (21.4)			
Jaw						
Upper	26	8 (50.0)	8 (50.0)	0.62	0.35–1.11	0.218 ¹
Lower		8 (80.0)	2 (20.0)			
Endodontic treatment						
Present	26	14 (66.7)	7 (33.3)	1.66	0.54–5.08	0.340 ¹
Absent		2 (40.0)	3 (60.0)			

¹ Fischer’s Exact Test. Bold values mean statistical significance at the $p < .05$ level.

0.034). Regarding intragroup analyses, no statistical difference was found for BOP, and mesial and distal cervical distance ($p_2 > 0.05$). However, PI presented a statistically significant increase over time for the metal-ceramic rehabilitation and a statistical difference was observed for the mean PD, it was worse at the 12 month follow-up than at 3-months ($p_3 < 0.05$). The GBI values were significantly higher at the 12-month follow-up when compared with the baseline for the metal-free group. Although a statistical significance had been recorded in the metal-ceramic group for GBI, no differences were observed over time ($p_3 > 0.05$). CAL measurements ranged from 1.50 to 2.25 mm in the metal-free crowns and 1.50 to 2.00 mm in the metal-ceramic crowns, both at the 12-month follow-up. For CAL, the values increased

Table 2
Evaluation of radiographic and periodontal clinical parameters regarding material type [median (Q₂₅-Q₇₅)] at baseline, 3-and 12- months follow-up.

Parameter	Follow up	Metal-ceramic			Metal-free		
		n	Median (Q ₂₅ -Q ₇₅)	n	Median (Q ₂₅ -Q ₇₅)	p ₁	
PI (%)	Baseline	16	6.25 (0.00–12.77)* [†]	10	15.30 (3.07–23.90)	0.129	
	3 months	16	15.30 (12.50–23.32)*	10	9.75 (4.40–19.50)	0.153	
	12 months	16	21.50 (10.60–25.40) [†]	10	24.2 (7.10–29.52)	0.853	
	<i>p</i> ₂		0.001		0.122		
GBI (%)	Baseline	16	5.30 (0.90–14.30)	10	9.20 (3.30–14.0)*	0.832	
	3 months	16	16.05 (6.70–27.95)	10	14.00 (7.90–20.20)	0.874	
	12 months	16	17.00 (7.25–20.00)	10	16.70 (10.17–26.15)*	0.561	
	<i>p</i> ₂		0.047		0.009		
Mean PD (mm)	Baseline	16	1.80 (1.30–2.00)	10	1.90 (1.50–2.22)	0.311	
	3 months	16	1.70 (1.35–2.10)*	10	1.80 (1.30–1.85)	0.873	
	12 months	16	2.10 (1.80–2.50)*	10	2.10 (1.80–2.35)	1.000	
	<i>p</i> ₂		0.020		0.068		
BOP (%)	Baseline	16	0.00 (0.00–0.00)	10	0.10 (0.00–0.20)	0.083	
	3 months	16	0.00 (0.00–0.20)	10	0.00 (0.00–0.05)	0.399	
	12 months	16	0.00 (0.00–0.20)	10	0.00 (0.00–0.20)	0.835	
	<i>p</i> ₂		0.237		0.459		
CAL (mm)	Baseline	16	1.50 (1.00–2.50)	10	1.50 (1.00–2.00)	0.547	
	3 months	16	1.50 (1.00–2.00)	10	1.50 (1.00–1.62)*	0.348	
	12 months	16	2.25 (2.00–2.50)	10	2.00 (1.50–2.62)*	0.662	
	<i>p</i> ₂		0.053		0.005		
Mesial cervical distance (mm)	Baseline	16	1.00 (0.12–3.00)	10	1.50 (0.87–2.25)	0.767	
	3 months	16	2.00 (0.00–3.00)	10	2.00 (1.75–2.25)	0.978	
	12 months	16	2.50 (1.25–3.00)	10	2.00 (1.75–2.25)	0.528	
	<i>p</i> ₂		0.161		0.108		
Distal cervical distance (mm)	Baseline	16	2.00 (1.12–3.00)	10	1.25 (0.87–2.00)	0.098	
	3 months	16	2.00 (2.00–3.00)	10	2.00 (1.00–2.25)	0.170	
	12 months	16	2.75 (2.00–3.00)	10	2.00 (1.00–2.12)	0.034	
	<i>p</i> ₂		0.067		0.092		

Equal symbols mean statistically significant differences within the groups at the time points assessed, by the Friedman (*p*₂) and Wilcoxon test (*p* < .05) (*p*₃). *p*₁ shows the *p*-value between the groups in the periods evaluated by the Mann-Whitney test. Bold values mean statistical significance at the *p* < .05 level.

significantly between 3- and 12-months for the metal-free group. All SCs were fitted regarding the buccal and palatal/lingual surfaces. Of the 16 metal-ceramic crowns placed in the patients, 31.2 % were misfits in at least one of these surfaces at the 12-month follow-up. Also, mesial misfits in 12.5 % and distal misfits in 31.2 % were found in metal-ceramic crowns, although no statistical difference had been observed. When comparing the single crown type and periodontal clinical characteristics, no statistical significance was found. Although bone resorption was more prevalent in metal-ceramic crowns (63.6 %), there were no differences over time for either of the SCs (*p* > 0.05). According

to the association between biomaterial type and dental biofilm in the abutment teeth, only metal-ceramic presented oral biofilm on the surface with the statistical difference (*p* = 0.003) (Table 3). Table 4 shows the relationship between the marginal finish line, the biomaterial, and radiographic and periodontal parameters. For the MC group, intergroup comparisons revealed statistically higher values of PI for supragingival margin at baseline and 3-month follow-ups, while subgingival margin showed statistical differences greater for GBI and mesial cervical distance (3-months), mean PD (12-months), distal cervical distance (baseline) (*p*₁ < 0.05). For the metal-free group, the only

Table 3
Association between the clinical and radiographic characteristics and material type of the single crowns at 3-and12-months follow-up.

	n	Metal-ceramic	Metal-free	RR	95 % CI	<i>p</i> [*]	n	Metal-ceramic	Metal-free	RR	95 % CI	<i>p</i> [*]
		n (%)	n (%)					n (%)	n (%)			
Fit in bucco cervical margins												
Fit	26	11 (52.4)	10 (47.6)	0.52	0.35–0.79	0.121 ¹	26	11 (52.4)	10 (47.6)	0.52	0.35–0.79	0.121 ¹
Misfit		5 (100.0)	0 (0.0)					5 (100.0)	0 (0.0)			
Fit in linguo cervical margins												
Fit	26	11 (52.4)	10 (47.6)	0.52	0.35–0.79	0.121 ¹	26	11 (52.4)	10 (47.6)	0.52	0.35–0.79	0.121 ¹
Misfit		5 (100.0)	0 (0.0)					5 (100.0)	0 (0.0)			
Fit in mesial cervical margins												
Fit	26	14 (58.3)	10 (41.7)	0.58	0.41–0.81	0.508 ¹	26	14 (58.3)	10 (41.7)	0.58	0.41–0.81	0.508 ¹
Misfit		2 (100.0)	0 (0.0)					2 (100.0)	0 (0.0)			
Fit in distal cervical margins												
Fit	26	11 (52.4)	10 (47.6)	0.52	0.35–0.79	0.121 ¹	26	11 (52.4)	10 (47.6)	0.52	0.35–0.79	0.121 ¹
Misfit		5 (100.0)	0 (0.0)					5 (100.0)	0 (0.0)			
Clinical changes in the periodontium												
Absence	26	13 (61.9)	8 (38.1)	1.03	0.46–2.27	1.000 ¹	26	11 (55.0)	9 (45.0)	0.66	0.38–1.12	0.352 ¹
Presence		3 (60.0)	2 (40.0)					5 (83.3)	1 (16.7)			
Bone resorption												
Presence	26	14 (63.6)	8 (36.4)	1.27	0.45–3.56	0.625 ¹	26	14 (63.6)	8 (36.4)	1.27	0.45–3.56	0.625 ¹
Absence		2 (50.0)	2 (50.0)					2 (50.0)	2 (50.0)			
Dental biofilm formation												
Presence	26	7 (77.8)	2 (22.2)	1.46	0.83–2.59	0.399 ¹	26	10 (100.0)	0 (0.0)	2.66	1.41–5.02	0.003¹
Absence		9 (52.9)	8 (47.1)					6 (37.5)	10 (62.5)			

¹ Fischer’s Exact Test. Bold values mean statistical significance at the *p* < .05 level.

Table 4

Evaluation of marginal finish line and the biomaterial type [mean (SD)] regarding clinical and radiographic parameters at baseline, 3-and 12- months follow-up.

Parameter	Follow up	Metal-ceramic				Metal-free					
		Supragingival		n	Subgingival		Supragingival		Subgingival		
		n	Median (Q ₂₅ -Q ₇₅)		Median (Q ₂₅ -Q ₇₅)	p ₁	n	Median (Q ₂₅ -Q ₇₅)	n	Median (Q ₂₅ -Q ₇₅)	p ₁
PI (%)	Baseline	13	8.30 (3.05–14.25)* [†]	3	0.00 (0.00–0.00)	0.025	2	6.65 (4.70-NR)	8	22.95 (1.02–23.90)	0.711
	3 months	13	18.70 (12.95–24.00)*	3	5.00 (5.00–5.00)	0.004	2	12.75 (12.50-NR)	8	6.00 (4.40–25.70)	0.711
	12 months	13	17.40 (10.55–26.55) [†]	3	25.40 (25.40–25.40)	0.189	2	9.75 (7.80-NR)	8	29.20 (8.55–30.17)	0.400
	p ₂		0.005		0.050		0.135		0.197		
GBI (%)	Baseline	13	9.80 (1.30–18.15)	3	0.90 (0.90–0.90)*	0.082	2	9.20 (8.00-NR)	8	10.67 (1.10–14.00)	1.000
	3 months	13	7.10 (5.43–19.45)	3	31.30 (31.30–31.30)*	0.004	2	11.70 (8.30-NR)	8	14.00 (8.52–22.40)*	1.000
	12 months	13	11.60 (7.10–21.35)	3	20.00 (20.00–20.00)	0.189	2	8.00 (5.30-NR)	8	16.70 (15.20–28.45)*	0.089
	p ₂		0.232		0.050		0.223		0.004		
Mean PD (mm)	Baseline	13	1.80 (1.15–2.00)	3	1.50 (1.30-NR)	0.521	2	1.85 (1.70-NR)	8	1.90 (1.50–2.27)	1.000
	3 months	13	1.70 (1.40–1.75)	3	2.20 (1.20-NR)	0.439	2	1.80 (1.80–1.80)	8	1.65 (1.30–1.95)	0.711
	12 months	13	2.00 (1.75–2.20)	3	2.50 (2.50-NR)	0.039	2	2.45 (2.30-NR)	8	2.00 (1.80–2.27)	0.089
	p ₂		0.044		0.264		0.223		0.113		
BOP (%)	Baseline	13	0.00 (0.00–0.10)	3	0.00 (0.00–0.00)	0.611	2	0.00 (0.00–0.00)	8	0.00 (0.00–0.20)	0.267
	3 months	13	0.00 (0.00–0.20)	3	0.00 (0.00–0.00)	0.239	2	0.10 (0.00-NR)	8	0.00 (0.00–0.00)	0.533
	12 months	13	0.00 (0.00–0.20)	3	0.00 (0.00-NR)	1.000	2	0.00 (0.00–0.00)	8	0.10 (0.00–0.20)	0.400
	p ₂		0.303		0.368		0.368		0.197		
CAL (mm)	Baseline	13	1.50 (1.00–2.50)	3	1.50 (1.50-NR)	0.900	2	1.75 (1.50-NR)	8	1.50 (1.00–1.87)	0.400
	3 months	13	1.50 (1.00–2.00)	3	2.00 (1.00-NR)	0.704	2	1.75 (1.50-NR)	8	1.25 (1.00–1.50)	0.267
	12 months	13	2.00 (1.75–2.50)	3	2.50 (2.50-NR)	0.082	2	3.00 (3.00–3.00)	8	2.00 (1.50–2.37)	0.044
	p ₂		0.157		0.264		0.223		0.023		
Mesial cervical distance (mm)	Baseline	13	1.00 (0.00–2.50)	3	3.00 (1.00-NR)	0.146	2	2.00 (2.00–2.00)	8	1.00 (0.62–2.75)	0.533
	3 months	13	2.00 (0.00–3.00)	3	3.00 (3.00-NR)	0.039	2	2.00 (2.00–2.00)	8	2.00 (1.25–2.75)	1.000
	12 months	13	2.00 (1.00–3.00)	3	3.00 (3.00-NR)	0.082	2	2.00 (2.00–2.00)	8	2.00 (1.25–2.75)	1.000
	p ₂		0.117		1.000		1.000		0.108		
Distal cervical distance (mm)	Baseline	13	2.00 (0.50–2.50)	3	3.00 (3.00-NR)	0.025	2	2.00 (2.00–2.00)	8	1.00 (0.63–1.87)	0.178
	3 months	13	2.00 (1.75–3.00)	3	3.00 (3.00-NR)	0.057	2	2.00 (2.00–2.00)	8	1.50 (1.00–2.37)	0.711
	12 months	13	2.00 (2.00–3.00)	3	3.00 (3.00-NR)	0.057	2	2.00 (2.00–2.00)	8	2.00 (1.00–2.75)	0.889
	p ₂		0.040		1.000		1.000		0.092		

Equal symbols mean statistically significant differences within the groups at the time points assessed, by the Friedman (p₂) and Wilcoxon test (p < .05) (p₃). p₁ shows the p-value between the groups in the periods regarding the material type evaluated by the Mann-Whitney test. NR mean that was not possible to obtain the value because no difference was observed. Bold values mean statistical significance at the p < .05 level.

supragingival margin had a higher loss of attachment (p₁ = 0.044). Intragroup evaluations showed that supragingival margins were associated with an increase of the PI between baseline and 3-months, and baseline and 12-months in the metal-ceramic crowns. Regarding subgingival margins, metal-ceramic had a statistical association with GBI comparing baseline and 3-months, while metal-free had a significant association between 3- and 12-months (p₃ < 0.05).

4. Discussion

Periodontal health plays an important role in the longevity of fixed prosthodontic rehabilitation. Maintenance visits to control the dental biofilm buildup should be conducted even when patients are aware of the oral hygiene (Ortolan et al., 2012). This study investigated the effects of SCs manufactured using 2 biomaterials on the periodontal tissues. Metal-ceramic was the predominant material choice by patients because of the low cost. Although these crowns have excellent mechanical properties (Bajraktarova-Valjakova et al., 2018), the esthetic appearance because of black blue-gray margins and the probability of metal-allergic reactions (Miura et al., 2018) remain as disadvantages.

The first hypothesis was partially rejected since the metal-ceramic crown group had the highest PI and PD values over time, whilst for a

metal-free crown group these scores were greater regarding CAL and GBI, being statistically different. Previous studies comparing zirconia-based and metal-ceramic prostheses have demonstrated similar outcomes for periodontal clinical behavior, regardless of the biomaterial (Monaco et al., 2017, Pelaez et al., 2012). Although zirconia is a promising restorative material, and an option for metal-ceramic crowns, because excellent mechanical and esthetic properties (Srimaneepong et al., 2022), direct comparison was not possible with our study. Ercoli and Caton (2018) reported that tooth-supported crown material may be associated with dental biofilm retention and loss of clinical attachment. This increase of the periodontal indexes after delivery of the crowns may suggest poor oral hygiene conditions requiring often maintenance therapy for patient motivation and prevention of progression periodontal disease. Also, hypersensitivity reactions can occur because the material of the crowns causes gingival inflammation that, whether not controlled, will contribute to periodontal pocket development.

Similarly, (Al-Sinaidi and Preethanath, 2014, Ayoub and Rashid, 2017) showed that gingival index and probing pocket depth increased in abutment teeth following the insertion of the fixed dentures for a mean follow-up period of at least 2 years. The mean PD assessed in this study revealed more PD in abutment teeth with metal-ceramic than e-max crowns compared to 3- and 12-month follow-ups. These findings may be

attributed to a lack of stabilizing effect of the porcelain-fused-metal crowns disfavoring the gingival response. However, the authors are unaware whether the crown designs are responsible for periodontal tissue changes explaining the need for further clinical trials. Factors such as the presence of chromium oxide within the metal alloy (Schmalz and Garhammer, 2002), and different manufacturing techniques providing a higher marginal gap (Kokubo et al., 2006) may be reasons for the tissue alterations in the periodontium. Thus, regular recalls are critical for reaching the balance between periodontium and prosthodontic rehabilitation otherwise longevity of the treatment and periodontium will be compromised.

The dental biofilm is an etiologic factor for the development of periodontal disease. The findings of this study demonstrated that metal-ceramic crowns retain greater amounts of dental biofilm. An in vitro study showed similar results reporting that ceramic surfaces induce a lower oral biofilm buildup and the lowest amount of viable microbial cells compared with metal-based materials (Souza et al., 2016). Materials for fixed prosthodontic restorations may bring on biofilm development since irregular topography, porosity, and surface roughness provide a favorable environment for bacterial colonization (Avetisyan et al., 2021). So, microbial adherence and marginal misfit can occur, negatively impacting the clinical restoration longevity.

The second hypothesis was partially accepted because statistically significant differences were found between the groups only for the distance between the distal cervical margin and AC at the 12-month follow-up. In this study, the median for metal-ceramic crowns regarding evaluated radiographic measurement was higher ($p = 0.034$). It is important to note that this increase appears to be clinically irrelevant since no association was found between the distal crown fit and the material. Results showed that biological principles were followed and there was no gingival inflammation, relevant bone loss, or periodontal supporting tissue impairment. Prerequisite requirements regarding periodontal tissue evaluation should be followed for prosthetic procedures. Understanding the relationship between the cervical margin and the crest of the alveolar bone is fundamental for avoiding violation of the dimension biologic width (Savadi et al., 2011).

Herein, the third hypothesis was accepted since a statistical difference was found between the material type and the marginal location. Supragingival margins are desirable because they do not compromise marginal periodontium and avoids the occurrence of gingival recession or periodontal injuries (Savadi et al., 2011). In contrast, subgingival finish lines do not allow suitable oral hygiene maintenance, favoring dental biofilm deposition (Nugala et al., 2012). Marginal locations near or within the junctional epithelium and supra-alveolar connective tissue induces damage to periodontal health and is a factor associated with biofilm retention. This study showed that patients rehabilitated with subgingivally metal-free crowns had significantly higher mean scores of loss of attachment and gingival index. Moreover, greater mean values of probing pocket depth was observed in supragingival metal-ceramic crowns. A systematic review reinforced our findings that finished line placed subgingival increases the susceptibility the inflammation and changes in the health status of the periodontium (Léon-Martinez et al., 2020). This suggests that subgingival single crowns may lead to periodontal inflammation response since the environment is adequate for pathogenic periodontal microflora. Even with a predominance of the supragingival crowns, that are least irritating to the periodontal tissue, oral hygiene instructions and follow-up should be provided to the patient since it was observed to increase the plaque index over time.

In previous studies, the reproducibility of the PES for assessing soft tissue around single-tooth implant crowns considering the observer's degree of dental specialization was reported (Fürhauser et al., 2005, Gehrke et al., 2008). Findings showed that the orthodontists were a more critical group because they probably evaluated esthetic outcomes based on a natural approach when compared with the layperson's opinion. A prospective cohort study assessed soft tissue modifications around a two-piece implant (Prati et al., 2020). The PES values

significantly increased for soft tissue level and contour scores at 12 and 36 months, and no tissue inflammation was found after crown cementation. Our study did not approach the esthetic outcomes of the soft tissue around the crowns. Use of the Pink Esthetic Score for appearance results is a suitable tool that will aid in understanding possible soft tissue modifications during the clinical follow-up, enabling comparisons between the biomaterials used.

This study investigated the relationship between periodontal clinical parameters in a generalized manner in abutment teeth rehabilitated with metal-free and metal-ceramic single crowns throughout the follow-up period. However, limitations were observed as patient-related factors that could interfere with the predisposition to the development of oral biofilm, as well as risk factors associated with increased periodontal parameters and progression of periodontal disease, were not evaluated. Moreover, absence of randomization and a control group can lead to biases estimates, and no approach to biomaterial mechanical properties was performed. Although there were no mechanical and biological complications, clinical appointments over 12 months are required to assess the possible occurrence of complications such as fracture of the crowns, secondary caries, and marginal misfit.

As the sample inserted in this study was composed of the low-income population, rehabilitated in a Public University with financial resources of the Public Health System, and zirconia is a biomaterial with high laboratory costs, comparisons with the zirconia group were unfeasible. Further clinical trials assessing survival rates and periodontal aspects associated with oral hygiene conditions are important to verify the longevity of the treatment with these materials used for single crowns. Because of advancement in dentistry and the search for esthetic treatment, future studies comparing the biomaterials evaluated in this study along with other ceramic materials such as monolithic zirconia and high translucent zirconia crowns are needed to determine their behavior on the periodontal parameters.

5. Conclusion

Based on the findings of this study, the PI and mean PD were higher in the metal-ceramic crowns, while GBI and CAL demonstrated an increase in the metal-free crowns during the follow-up period. No association was observed between cervical marginal fit, periodontium clinical aspects, and bone loss regarding the crown biomaterial. The marginal finish line location interferes with the periodontal clinical parameters. PI was statistically associated with a supragingival margin over time, while GBI was higher in the metal-free crowns with a significant difference for the subgingival margin between 3- and 12-month follow-ups. Rehabilitation of the abutment teeth with metal-ceramic or metal-free SCs did not aggravate the prior periodontal tissue condition during the 12-month follow-up period.

CRedit authorship contribution statement

Anne Kaline Claudino Ribeiro: Conceptualization, Data curation, Visualization, Investigation, Validation, Formal analysis, Methodology, Resources, Writing – original draft, Writing – review & editing. **Anna Clara Gurgel Gomes:** Conceptualization, Data curation, Visualization, Investigation, Validation, Formal analysis, Methodology, Resources, Writing – original draft, Writing – review & editing. **Larissa Araújo Luz de Oliveira:** Conceptualization, Visualization, Validation, Formal analysis, Methodology, Writing – review & editing. **Davi Neto de Araújo Silva:** Conceptualization, Visualization, Validation, Formal analysis, Methodology, Writing – review & editing. **Luana Maria Martins de Aquino:** Conceptualization, Visualization, Validation, Supervision, Project administration, Writing – review & editing. **Ana Rafaela Luz de Aquino Martins:** Conceptualization, Visualization, Validation, Supervision, Project administration, Writing – review & editing.

Declaration of competing interest

The authors declare that they have no known competing financial interests or personal relationships that could have appeared to influence the work reported in this paper.

Acknowledgments

The research team would like to thank the patients who participated in this study.

Appendix A. Supplementary data

Supplementary data to this article can be found online at <https://doi.org/10.1016/j.sdentj.2024.03.019>.

References

- Al-Sinaidi, A., Preethanath, R.S., 2014. The effect of fixed partial dentures on periodontal status of abutment teeth. *Saudi. J. Dent. Res.* 5 (2), 104–108. <https://doi.org/10.1016/j.ksujds.2013.11.001>.
- Avetisyan, A., Markaryan, M., Rokaya, D., Tovani-Palone, M.R., Zafar, M.S., Khurshid, Z., Vardanyan, A., Heboyan, A., 2021. Characteristics of periodontal tissues in prosthetic treatment with fixed dental prostheses. *Molecules* 26 (5), 1331. <https://doi.org/10.3390/molecules26051331>.
- Ayoub, W., Rashid, R., 2017. The effect of fixed partial dentures on periodontal status of abutments teeth. *Int. J. App. Dent. Sci.* 3 (4), 103–106.
- Bajraktarova-Valjakova, E., Korunoska-Stevkovska, V., Kapusevska, B., Gigovski, N., Bajraktarova-Misevska, C., Grozdanov, A., 2018. Contemporary dental ceramic materials, a review: chemical composition, physical and mechanical properties, indications for use. *Open. Access. Maced. J. Med. Sci.* 9 (6), 1742–1755. <https://doi.org/10.3889/oamjms.2018.378>.
- Ercoli, C., Caton, J.G., 2018. Dental prostheses and tooth-related factors. *J. Periodontol.* 89, S223–S236. <https://doi.org/10.1002/JPER.16-0569>.
- Ercoli, C., Tarnow, D., Poggio, C.E., Tsigarida, A., Ferrari, M., Caton, J.G., Chochlidakis, K., 2021. The relationships between tooth-supported fixed dental prostheses and restorations and the periodontium. *J. Prosthodont.* 30 (4), 305–317. <https://doi.org/10.1111/jopr.13292>.
- Fürhauser, R., Florescu, D., Benesch, T., Haas, R., Mailath, G., Watzek, G., 2005. Evaluation of soft tissue around single-tooth implant crowns: the pink esthetic score. *Clin. Oral. Implants. Res.* 16 (6), 639–644. <https://doi.org/10.1111/j.1600-0501.2005.01193.x>.
- Gehrke, P., Lobert, M., Dhom, G., 2008. Reproducibility of the pink esthetic score—rating soft tissue esthetics around single-implant restorations with regard to dental observer specialization. *J. Esthet. Restor. Dent.* 20 (6), 375–384. <https://doi.org/10.1111/j.1708-8240.2008.00212.x>.
- Gseibat, M., Sevilla, P., Lopez-Suarez, C., Rodríguez, V., Peláez, J., Suárez, M.J., 2022. Prospective clinical evaluation of posterior third-generation monolithic zirconia crowns fabricated with complete digital workflow: two-year follow-up. *Materials (basel)*. 15 (2), 672. <https://doi.org/10.1016/j.jdent.2014.03.002>.
- Ispas, A., Iosif, L., Popa, D., Negucioiu, M., Constantiniuc, M., Bacali, C., Buduru, S., 2022. Comparative assessment of the functional parameters for metal-ceramic and all-ceramic teeth restorations in prosthetic dentistry - a literature review. *Biology* 11 (4), 556. <https://doi.org/10.3390/biology11040556>.
- Kokubo, Y., Tsumita, M., Ohkubo, C., Vult von Steyern, P., Murata, T., Fukuhsima, S., 2006. Clinical marginal gap of porcelain fused to electro-formed gold coping crowns. *Eur. J. Prosthodont. Restor. Dent.* 14 (2), 85–89.
- Landis, J.R., Koch, G.G., 1977. The measurement of observer agreement for categorical data. *Biometrics* 33 (1), 159–174.
- León-Martínez, R., Montiel-Company, J.M., Bellot-Arcís, C., Solá-Ruiz, M.F., Selva-Otaolaurruchi, E., Agustín-Panadero, R., 2020. Periodontal behavior around teeth prepared with finishing line for restoration with fixed prostheses: a systematic review and meta-analysis. *J. Clin. Med.* 9 (1), 249. <https://doi.org/10.3390/jcm9010249>.
- McCracken, M.S., Louis, D.R., Litaker, M.S., Minyé, H.M., Mungia, R., Gordan, V.V., Marshall, D.G., Gilbert, G.H., 2016. National Dental Practice-Based Research Network Collaborative Group. treatment recommendations for single-unit crowns: findings from the National Dental Practice-Based Research Network. *J. Am. Dent. Assoc.* 147 (11), 882–890. <https://doi.org/10.1016/j.adaj.2016.06.012>.
- Melo, L.A., de Souza, M.B.C., Barbosa, G.A.S., Carreiro, A.F.P., 2017. Peri-implant bone loss of external hexagon and morse taper in patients wearing immediately loaded overdentures. *Braz. Dent. J.* 28 (6), 694–698. <https://doi.org/10.1590/0103-6440201701577>.
- Miura, S., Kasahara, S., Yamauchi, S., Okuyama, Y., Izumida, A., Aida, J., Egusa, H., 2018. Clinical evaluation of zirconia-based all-ceramic single crowns: an up to 12-year retrospective cohort study. *Clin. Oral. Investig.* 22 (2), 697–706. <https://doi.org/10.1007/s00784-017-2142-y>.
- Monaco, C., Llukacej, A., Baldissara, P., Arena, A., Scotti, R., 2017. Zirconia-based versus metal-based single crowns veneered with overpressing ceramic for restoration of posterior endodontically treated teeth: 5-year results of a randomized controlled clinical study. *J. Dent.* 65, 56–63. <https://doi.org/10.1016/j.jdent.2017.07.004>.
- Nicolaisen, M., Bahrami, G., Schropp, L., Isidor, F., 2016. Comparison of metal-ceramic and all-ceramic three-unit posterior fixed dental prostheses: a 3-year randomized clinical trial. *Int. J. Prosthodont.* 29 (3), 259–264. <https://doi.org/10.11607/ijp.4504>.
- Nugala, B., Kumar, B.S., Sahitya, S., Krishna, P.M., 2012. Biologic width and its importance in periodontal and restorative dentistry. *J. Conserv. Dent.* 15 (1), 12–17. <https://doi.org/10.4103/0972-0707.92599>.
- Ortolan, S.M., Viskić, J., Stefanić, S., Sitar, K.R., Vojvodić, D., Mehulić, K., 2012. Oral hygiene and gingival health in patients with fixed prosthodontic appliances—a 12-month follow-up. *Coll. Antropol.* 36 (1), 213–220.
- Pelaez, J., Cogolludo, P.G., Serrano, B., Serrano, J.F., Suarez, M.J., 2012. A four-year prospective clinical evaluation of zirconia and metal-ceramic posterior fixed dental prostheses. *Int. J. Prosthodont.* 25 (5), 451–458.
- Prati, C., Zamparini, F., Canullo, L., Pirani, C., Botticelli, D., Gandolfi, M.G., 2020. Factors affecting soft and hard tissues around two-piece transmucosal implants: a 3-year prospective cohort study. *Int. J. Oral. Maxillofac. Implants.* 35 (5), 1022–1036. <https://doi.org/10.11607/jomi.7778>.
- Savadi, A., Rangarajan, V., Savadi, R.C., Satheesh, P., 2011. Biologic perspectives in restorative treatment. *J. Indian. Prosthodont. Soc.* 11 (3), 143–148. <https://doi.org/10.1007/s13191-011-0101-x>.
- Schmalz, G., Garhammer, P., 2002. Biological interactions of dental cast alloys with oral tissues. *Dent. Mater.* 18 (5), 396–406. [https://doi.org/10.1016/s0109-5641\(01\)00063-x](https://doi.org/10.1016/s0109-5641(01)00063-x).
- Serra-Pastor, B., Bustamante-Hernández, N., Fons-Font, A., Solá-Ruiz, M.F., Revilla-León, M., Agustín-Panadero, R., 2021. Periodontal behavior and patient satisfaction of anterior teeth restored with single zirconia crowns using a biologically oriented preparation technique: a 6-year prospective clinical study. *J. Clin. Med.* 10 (16), 3482. <https://doi.org/10.3390/jcm10163482>.
- Souza, J.C., Mota, R.R., Sordi, M.B., Passoni, B.B., Benfatti, C.A., Magini, R.S., 2016. Biofilm formation on different materials used in oral rehabilitation. *Braz. Dent. J.* 27 (2), 141–147. <https://doi.org/10.1590/0103-6440201600625>.
- Srimanepong, V., Heboyan, A., Zafar, M.S., Khurshid, Z., Marya, A., Fernandes, G.V.O., Rokaya, D., 2022. Fixed prosthetic restorations and periodontal health: a narrative review. *J. Funct. Biomater.* 13 (1), 15. <https://doi.org/10.3390/jfb13010015>.