

CASE REPORT

Right cardiac chambers echo-bubble contrast in a patient with decompression sickness: A case report and a literature review

Allam Harfoush^{1,2}  | Mohammad Ramadan¹ | Hanady Hamdallah²

¹Department of Cardiovascular Disease, Tishreen University Hospital, Latakia, Syria

²Chester medical school, University of Chester, Chester, UK

Correspondence

Allam Harfoush, Chester Medical School, University of Chester, Chester, UK.

Email: allamharf@gmail.com

Funding information

None

Abstract

The diagnosis of decompression sickness (DCS) is mostly based on clinical suspicion, and there is currently no available modality to fully confirm the diagnosis. However, the use of echocardiography in suspected DCS cases has become more common. In this case, transthoracic echocardiography (TTE) was used to detect microbubbles in the right cardiac chambers and monitor the patient after hyperbaric oxygen therapy (HBOT), suggesting the possible applicability of TTE in diagnosing and monitoring DCS patients. This report describes a 54-year-old Fisherman who was referred to the emergency department with dyspnea and mild confusion after a rapid ascent of a saturation dive at 50 m sea depth. After the initial evaluation, he was assessed using TTE to exclude the presence of structural heart disease, where it surprisingly showed spontaneous echo contrast inside the right cardiac chambers similar to agitated saline echo testing. The patient was then admitted for HBOT and follow-up; rapid improvement was noticed after the first HBOT session and the TTE findings were fully resolved. TTE could be considered in the initial workup when DCS is suspected, and it might have a role in monitoring DCS patients if echocardiographic findings of bubble formation were documented in the pre-hyperbaric therapy settings.

KEYWORDS

DCS, decompression sickness, hyperbaric oxygen therapy, microbubbles, transthoracic echocardiography, TTE

1 | BACKGROUND

Decompression sickness (DCS) is caused by the rapid change of the surrounding pressure while ascending.¹ As during descent, increased environmental pressure leads nitrogen to reach the bloodstream through the alveoli, which usually present in a dissolved form, while rapid ascend causes nitrogen to form bubbles,² leaving a

short-time window for these bubbles to be resolved and re-absorbed.³ Entrapment of these bubbles in specific tissues could lead to blood flow obstruction and vessel spasm, as well as activation of the platelets and the clotting cascade,⁴ causing tissue hypoperfusion. DCS is usually classified into two types, DCS I is characterized by mild cutaneous manifestations such as mottled or marbled rashes together with musculoskeletal pain; and DCS II is considered a

This is an open access article under the terms of the Creative Commons Attribution-NonCommercial-NoDerivs License, which permits use and distribution in any medium, provided the original work is properly cited, the use is non-commercial and no modifications or adaptations are made.

© 2022 The Authors. *Clinical Case Reports* published by John Wiley & Sons Ltd.

more severe form with neurological symptoms of poor coordination and confusion, together with cardiopulmonary manifestations that could present as dyspnea and retrosternal pain.⁵

2 | CASE PRESENTATION

A fit and well 54-year-old Fisherman, who is a moderate smoker, an occasional alcoholic with no notable medical history or chronic medications, was referred to the emergency department with dyspnea, lethargy, severe generalized arthralgia, and mild confusion after rapidly ascending of a saturation diving of 50 m sea depth. On initial assessment, the patient was dyspneic, alert, and responsive with a Glasco coma scale of 14. On examination, there was bilateral joints pain, which was aggravated by movement without signs of inflammation. The neurological, chest, cardiac, and abdominal examinations were unremarkable, with a blood pressure of 90/60 mm Hg, a pulse of 95 Bpm, saturation of 90%, respiratory rate of 24/minute, and a temperature of 36.6°; the calculated well's pulmonary embolism score was 3.

3 | INVESTIGATIONS

At the time of presentation, the patient was evaluated by the emergency core medical trainee, where high-flow oxygen was initiated and a multi-disciplinary team of cardiology, pulmonology, and neurology was gathered to assess the patient's symptoms. The initial investigation was electrocardiography (ECG), and it showed a normal ECG (Figure 1). The patient was then escorted to the radiology division, and a posterior–anterior chest X-ray (PA-CXR) was obtained and it showed a normal CXR (Figure 2). Meanwhile, the ordered blood tests revealed the following: normal D-dimer, normal hemoglobin, platelets, glucose, ESR, creatinine, urea, potassium, and sodium; however, it revealed elevated white blood cells of 13 (normal value 4500_11000) and CRP of 73 mg/L

(normal value 0_7 mg/L). Arterial blood gas (ABG) showed metabolic acidosis, with a PH of 7.32, P_{CO2} of 28, H_{CO3} of 15, and P_{O2} of 63 mm Hg. After ensuring the patient was stable, he was escorted by the cardiology intern for emergency transthoracic echocardiography (TTE) to exclude the presence of structural heart diseases; where it showed normal left ventricular, normal right ventricle, and no valvular disease; yet, spontaneous echo contrast inside the right cardiac chambers was witnessed, similar to agitated saline echo testing (Figure 3). During the examination, the patient was asked to do the Valsalva maneuver by taking a deep breath and holding it, and the aim was to evaluate the presence of patent foramen ovale (PFO) using color-flow Doppler, which could have an important role in DCS, and no flow was appreciated.

4 | DIFFERENTIAL DIAGNOSIS

After evaluating the clinical picture, together with the patient's history, physical examination, and relevant investigations, a differential diagnosis of pneumothorax, pulmonary embolism, aspiration pneumonia, and DCS was established. Pneumothorax was excluded due to the normal chest auscultation and normal PA-CXR. Aspiration pneumonia was also excluded due to the normal examination and normal PA-CXR; while pulmonary embolism (PE) was excluded due to the well's PE score, normal D-dimer, and the ABG findings.

5 | TREATMENT

Following admission, the patient was initially treated with 100% oxygen. Intravenous saline solution was also used for rehydration with a dose of 100 ml/h; and finally, due to the joint pain and the inability to walk, prophylactic subcutaneous (S.C) Enoxaparin was initiated with a dose of 40 mg/day. Meanwhile, the HBOT center was immediately contacted, and the first session was arranged.

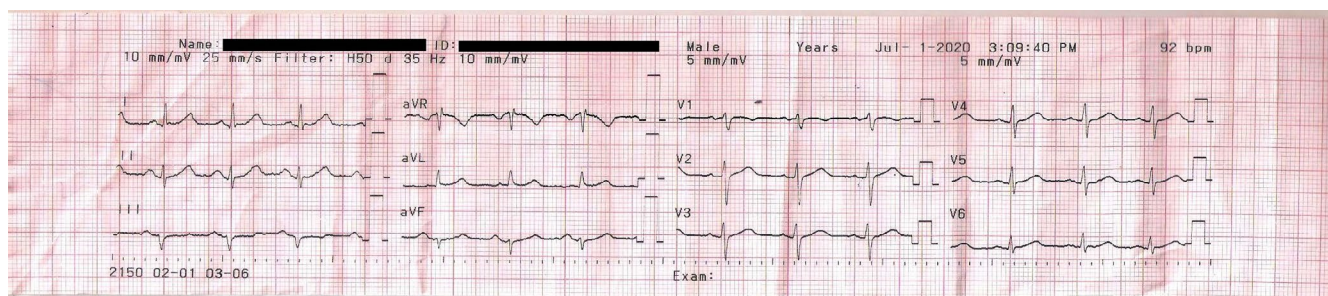


FIGURE 1 Patient's electrocardiogram upon admission

6 | OUTCOME AND FOLLOW-UP

A significant clinical and hemodynamic improvement was observed within 1 h of the first HBOT session, with a blood pressure of 135/75, a respiratory rate of 17/minute, a heart rate of 75 Bpm, and an oxygen saturation of 98%. Joint pain was mildly reduced, and the patient was able to stand by himself, though support was needed to walk around the hospital room. The patient was reevaluated using TTE within 1 h after the HBOT session, and surprisingly, the right cardiac chambers bubbles had fully vanished with no additional pathological findings (Figure 4), and he was discharged within 48 h of admission. Upon discharge, the patient's chief complaint was mild resistant arthralgia that was alleviated using paracetamol, and he was able to walk and support himself.

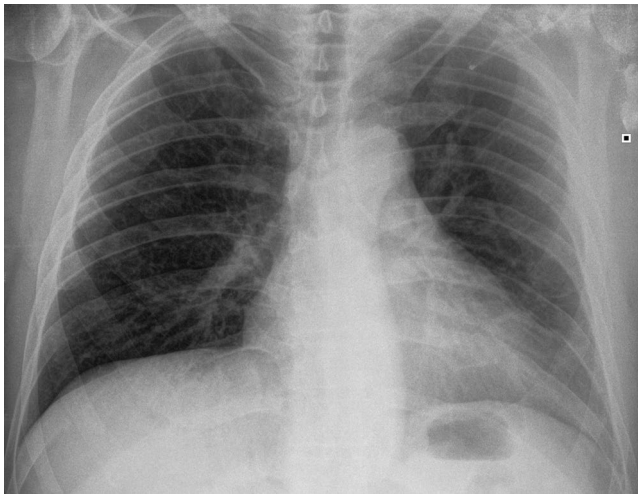


FIGURE 2 Patient's chest X-ray upon admission

7 | DISCUSSION

The diagnosis of DCS relies mostly on clinical suspicion; however, the patient's presentation intersects with several differential diagnoses that should be excluded before establishing the final diagnosis.⁶ The symptoms of dyspnea and chest pain after a rapid ascent suggest the diagnoses of pneumothorax and post-diving aspiration pneumonia, and chest X-ray is a useful method to exclude these conditions.⁷ While pulmonary embolism should also be considered, this patient's ABG was not compatible with the diagnosis, and the pretest probability with normal D-dimer could help to exclude the condition. The initial management for suspected DCS is the application of oxygen, as experimental studies showed a quicker decrease in the bubble load with the use of oxygen compared with air-breathing.⁸ Simultaneously, low molecular weight heparin could also be advised in DCS patients with reduced movement abilities to reduce the risk of DVT. Finally, HBOT is also present as one of the most important treatment lines. The main principle of this treatment is to deliver 100% inhaled oxygen inside a pressurized chamber equal or above 1.4 atmospheres absolute (ATA),⁹ which has a significant role in the pathology of DCS. The application of ultrasound for detecting microbubbles in DCS patients has been more common. In this case, TTE was used for three purposes, to exclude any structural heart disease, detect microbubbles, and search for the presence of left-right shunts (PFO). However, it has low specificity as a bubble screening tool¹⁰; another drawback is obtaining a clear ultrasound image, as suitable echocardiographic windows might not be accessible in the emergency settings.¹¹ Yet, this modality could be used as part of point-of-care ultrasound.¹²

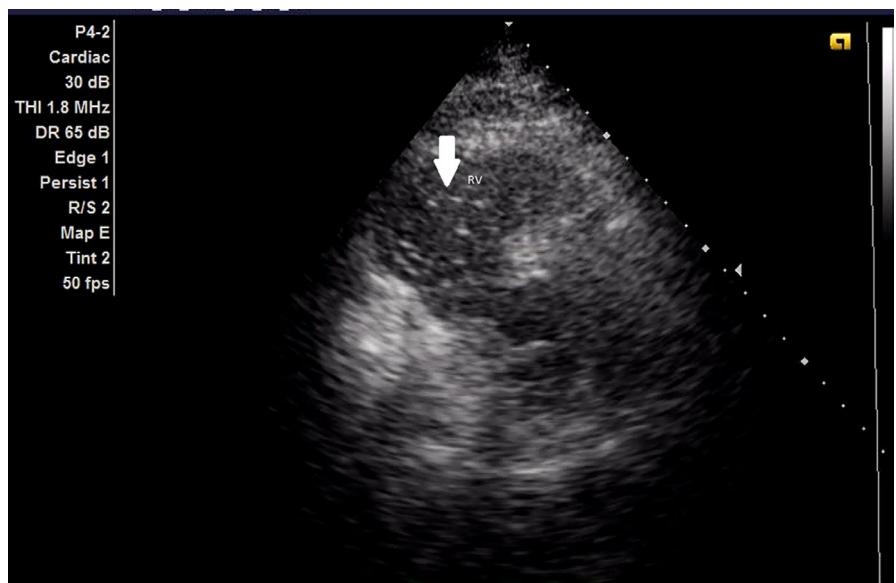


FIGURE 3 Patient's TTE before HBOT: microbubbles (Arrow) in the right ventricle. (TTE, transthoracic echocardiography; HBOT, hyperbaric oxygen therapy; RV, right ventricle)

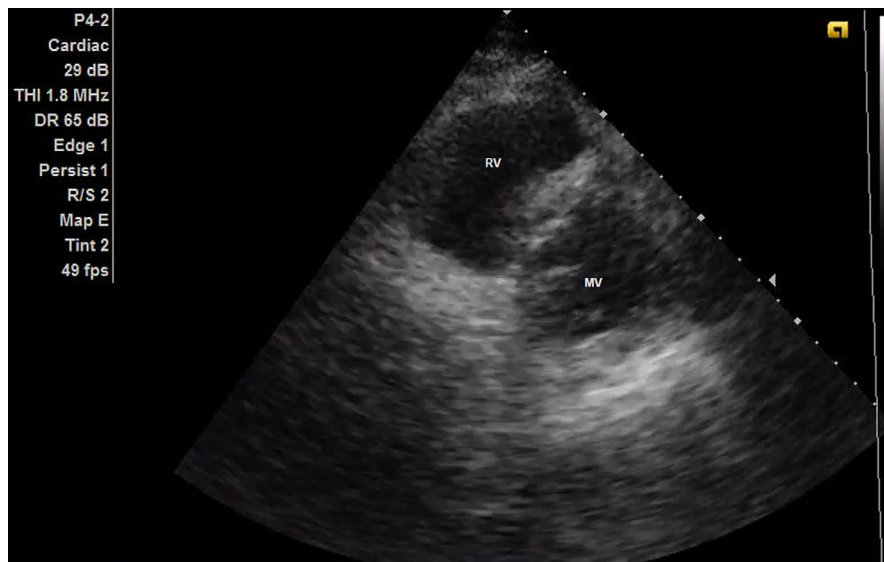


FIGURE 4 Patient's TTE after HBOT: the disappearance of the microbubbles. (TTE, transthoracic echocardiography; HBOT, hyperbaric oxygen therapy; RV, right ventricle; MV, mitral valve)

TABLE 1 Identified published cases of bubbles detection using ultrasound in DCS patients

Case	Yanagawa et al., 2021 ¹³	Jitsuiki et al., 2020 ¹⁴	Kondo et al., 2018 ¹⁵	Boussuges et al., 2008 ¹⁶
Age	53 years	26 years	65 years	N/A
Diving depth	21 meters	26 meters	24 meters	N/A
Chief complaint	Abdominal pain and dyspnea	Scotoma, headache and fatigue	Epigastric pain	N/A
Used modalities	US and CT scan	US and CT scan	US and CT scan	Echocardiography
US bubbles' location	Portal vein and RV	IVC	IVC	LV/RV
HBOT	Yes	Yes	Yes	N/A
Bubbles vanishing time	Within 2 days	N/A	N/A	N/A
Discharge	Within 6 days	Within 2 days	N/A	N/A
Reported complications	Memory disturbance	N/A	N/A	N/A

Abbreviations: CT, computed tomography; HBOT, hyperbaric oxygen therapy; IVC, Inferior vena cava; LV, left ventricle; N/A, not applicable; RV, right ventricle; US, ultrasound.

This report suggests that echocardiography is a useful screening tool to detect microbubbles in patients with suspected DCS. To support our hypothesis, a literature search was performed using PubMed and the Cochrane Library to evaluate similar case report findings. Four published cases were identified (Presented in Table 1), and the reference list of these studies was manually screened for similar case reports. Although patients' reported symptoms varied, all of these studies used ultrasound as a screening tool, and the most common locations for detected microbubbles were the right ventricle and inferior vena cava. Three studies detected bubbles in several other locations using CT scan; three studies described the use of HBOT, and improvement was reported in two studies. Three studies concluded that the use of CT following ultrasound could be a useful method to diagnose DCS.

In conclusion, echocardiography in the current case helped in the diagnosis of suspected DCS, and the purpose

of the patient admission to the cardiology department was to monitor these microbubbles' behavior using TTE after the first HBOT session and to see if the disappearance of these microbubbles could reflect clinical improvement or could be related to the overall prognosis. We found that these bubbles disappeared within 1 h of HBOT, and significant improvement was noticed during the same period, which could suggest possible applicability of TTE in diagnosing and monitoring DCS patients.

ACKNOWLEDGEMENTS

Allam Harfoush and Mohamad Ramadan would like to thank the patient for his cooperation and to thank Tishreen University hospital staff who helped in the management and follow-up of the patient during hospitalisation. Allam Harfoush would like to thank and acknowledge the work of the Council for At-Risk Academics (Cara) for their great efforts.

CONFLICT OF INTEREST

None.

AUTHOR CONTRIBUTIONS

Mohammad Ramadan was the first to review the patient and performed the initial TTE with a discussion with Allam Harfoush. The second TTE was done by Allam Harfoush with a discussion with Mohammad Ramadan. Follow-up was done by both. The case was written by Allam Harfoush as the corresponding author and Mohammad Ramadan and Hanady Hamdallah as the co-authors.

ETHICAL APPROVAL

No ethics committee approval is warranted as it was a clinical case.

CONSENT

Written informed consent was obtained from the patient's relative to publish this report in accordance with the journal's patient consent policy.

DATA AVAILABILITY STATEMENT

Data are available upon request to the corresponding author (Full blood tests and TTE clips before and after HBOT), please email the corresponding author, it was also uploaded to be reviewed by the CCR editorial board during submission.

ORCID

Allam Harfoush  <https://orcid.org/0000-0001-7317-4237>

REFERENCES

- Goad RF, Farmer JC Jr, Leitch DR, Hallenbeck JM, Hamilton RW. Diagnosis and treatment of decompression sickness. In: Carlston CB, Mathias RA, & Shilling CW eds. *The Physician's Guide to Diving Medicine*. Springer US; 1984:283-331.
- Elsevier. Bennett and Elliotts' Physiology and Medicine of Diving [Internet]. Elsevier.com. <https://www.elsevier.com/books/bennett-and-elliotts-physiology-and-medicine-of-diving/brubakk/978-0-7020-2571-6>. Accessed October 18, 2021.
- Hall J. The risks of scuba diving: a focus on decompression illness. *Hawaii J Med Public Health*. 2014;73(11 Suppl 2):13-16.
- Cooper JS, Hanson KC. eds. Decompression sickness. In: *StatPearls [Internet]*. StatPearls Publishing; 2020.
- Pollock NW, Buteau D. Updates in decompression illness. *Emerg Med Clin North Am*. 2017;35(2):301-319.
- Vann RD, Butler FK, Mitchell SJ, Moon RE. Decompression illness. *Lancet*. 2011;377(9760):153-164.
- Bove AA. Diving medicine. *Am J Respir Crit Care Med*. 2014;189(12):1479-1486.
- Kizer KW. Dysbaric cerebral air embolism in Hawaii. *Ann Emerg Med*. 1987;16(5):535-541.
- HBO indications - undersea & hyperbaric medical society [Internet]. Uhms.org. <https://www.uhms.org/resources/hbo-indications.html>. Accessed October 9, 2021.
- Eftedal OS, Lydersen S, Brubakk AO. The relationship between venous gas bubbles and adverse effects of decompression after air dives. *Undersea Hyperb Med*. 2007;34(2):99-105.
- Malik SB, Chen N, Parker RA 3rd, Hsu JY. Transthoracic echocardiography: Pitfalls and limitations as delineated at cardiac CT and MR imaging. *Radiographics*. 2017;37(2):383-406.
- Melgarejo S, Schaub A, E Noble V. *Point of Care Ultrasound: An Overview - American College of Cardiology [Internet]*. American College of Cardiology. 2022 [cited 21 January 2022]. <https://www.acc.org/latest-in-cardiology/articles/2017/10/31/09/57/point-of-care-ultrasound>
- Yanagawa Y, Takeuchi I, Ishiyama J. Ultrasound in the diagnosis of acute-phase decompression sickness. *Radiol Case Rep*. 2021;16(3):698-700.
- Jitsuiki K, Kushida Y, Nishio R, Yanagawa Y. Gas in joints after diving: computed tomography may be useful for diagnosing decompression sickness. *Wilderness Environ Med*. 2021;32(1):70-73.
- Kondo A, Nagawasa H, Takeuchi I, Yanagawa Y. Portal venous gas due to decompression sickness. *Intern Med*. 2018;57(14):2091.
- Boussuges A, Blatteau JE, Pontier JM. Bubbles in the left cardiac cavities after diving. *Heart*. 2008;94(4):445.

How to cite this article: Harfoush A, Ramadan M, Hamdallah H. Right cardiac chambers echobubble contrast in a patient with decompression sickness: A case report and a literature review. *Clin Case Rep*. 2022;10:e05706. doi:[10.1002/ccr3.5706](https://doi.org/10.1002/ccr3.5706)