



## Case report

# Colonic tuberculosis masquerading as ascending colon carcinoma in a patient of FIGO Stage IIB cervical carcinoma following chemo-radiotherapy: A case report

Gagan Adhikari<sup>\*</sup>, Bishal Buda, Jayant Kumar Shah, Bikal Ghimire, Prasan B.S. Kansakar

Department of General Surgery, Tribhuvan University Teaching Hospital, Institute of Medicine, Maharajgunj, Kathmandu, Nepal

## ARTICLE INFO

## Keywords:

Cervical carcinoma  
Colonic carcinoma  
Colonic tuberculosis  
Right standard hemicolectomy  
Anti-tuberculosis drugs

## ABSTRACT

**Introduction and importance:** Colonic tuberculosis may masquerade colonic carcinoma. Also, intestinal tuberculosis may mimic colonic carcinoma, Crohn's disease, ulcerative colitis, etc.

**Case presentation:** A 40 years female was diagnosed with cervical carcinoma FIGO Stage IIB underwent chemo-radiotherapy. She was symptom-free for a few months and then she developed right-sided abdominal pain and abdominal fullness for 4 months. She underwent a colonoscopy that showed ulcerative growth and friable tissue in hepatic flexure of colon and histopathology and immunohistochemistry findings suggested non-Hodgkin's lymphoma or poorly differentiated carcinoma. Then right standard hemicolectomy was performed and histopathology showed tuberculosis. The patient received medications for tuberculosis and the patient improved. **Clinical findings and investigations:** Preoperatively suspected colonic carcinoma in developing countries (where the prevalence of tuberculosis is high) may sometimes come out as colonic tuberculosis in histopathology. The biopsy sample taken from colonoscopy was examined by histopathology, which showed nonspecific results, and the case was mistakenly thought of as colonic carcinoma preoperatively.

**Interventions and outcomes:** The case underwent right standard hemicolectomy and to the surprise, the excised specimen came out as tuberculosis. The patient received anti-tubercular drugs and the patient is symptomatically better.

**Relevance and impact:** Colonic tuberculosis can mimic colonic carcinoma. Histopathology will confirm colonic tuberculosis and response to anti-tuberculosis drugs will verify the diagnosis. Though a patient undergoing chemotherapy may develop lymphoma, colonoscopic biopsy may not be conclusive. In any symptomatic patient with colonic stricture, surgery is the treatment of choice.

## 1. Introduction

Intestinal tuberculosis is common among the extra-pulmonary spectrum of tuberculosis seen in developing countries. Generally, intestinal tuberculosis mainly invades the ileocecal area and presents as a transverse ulcer. Isolated colonic tuberculosis is not common among intestinal tuberculosis. Apart from this, because of nonspecific symptoms, it is difficult to discriminate from other intestinal diseases like Crohn's disease, ulcerative colitis, colon cancer. Intestinal tuberculosis should be diagnosed based on overall considerations, including clinical manifestations, colonoscopy findings, and biopsy. The recent developments in colonoscopy, biopsies and acid-fast bacilli (AFB) smears can enable an early diagnosis [1]. There are reported cases of intestinal

tuberculosis mimicking colon cancer and Crohn's disease. Here we report a case of a female of FIGO Stage IIB cervical carcinoma [2] following chemo-radiotherapy whose colonoscopy findings were suggestive of poorly differentiated carcinoma or non-Hodgkin's lymphoma and underwent right standard hemicolectomy. But to the surprise, the histopathology showed colonic tuberculosis and the patient is improving after anti-tuberculosis drugs. This case report is reported according to SCARE criteria [3].

## 2. Presentation of the case

A 40 years female was diagnosed with cervical carcinoma FIGO Stage IIB whose MRI findings showed an eccentric lesion of 1 \* 1.3 \* 1.7 cm in

<sup>\*</sup> Corresponding author.

E-mail address: [adhikarigagan2@gmail.com](mailto:adhikarigagan2@gmail.com) (G. Adhikari).

<https://doi.org/10.1016/j.ijscr.2022.106943>

Received 16 February 2022; Received in revised form 8 March 2022; Accepted 10 March 2022

Available online 12 March 2022

2210-2612/© 2022 The Authors. Published by Elsevier Ltd on behalf of IJS Publishing Group Ltd. This is an open access article under the CC BY-NC-ND license

(<http://creativecommons.org/licenses/by-nc-nd/4.0/>).

the posterior and right lateral cervix with extension into right parametrium with obliteration of posterior fornix. She underwent 3 cycles of chemotherapy with cisplatin (1 cycle per week) and 3 cycles of External Beam Radiotherapy (EBRT) for 25 days (6 sessions per week) followed by 3 cycles 8 Gray (Gy) to the high-risk clinical target volume (HRCTV) brachytherapy (1 cycle per week) [4].

Following chemo-radiotherapy, cytopathology from the vaginal vault showed superficial and intermediate squamous epithelial cells along with few parabasal cells and radiation-associated changes.

She was doing well and symptom-free for one and half months after cessation of the therapies for cervical carcinoma. Then, she insidiously started to have right lower abdominal pain and abdominal fullness. According to her, the symptoms were mild and bearable. Besides her economic condition was also unfavorable. So she herself decided not to seek any medical attention.

But when the severity of symptoms increased, she finally presented to our OPD with a history of right-sided abdominal pain and abdominal fullness for 4 months. She had constipation. And she also had few episodes of postprandial vomiting and a few episodes of melena. Apart from these symptoms, she also had back pain, dry cough in the evening and easy fatigability. Clinical examination reveals no pallor, no palpable mass and no lymphadenopathy. She had no allergy history. She did not have family history of gastrointestinal and gynecological malignancy. She is non-smoker, non-alcoholic and consumes non-vegetarian diet.

Her total count was 5500/ml and her hemoglobin of 13.9 g/dl. The liver function test and renal function tests were within the normal range. Chest x-ray was normal. Colonoscopy suggested procto-sigmoiditis (likely due to radiation) as well as ulcerative growth and friable tissue in the hepatic flexure of the colon (Figs. 1 and 2). A biopsy sample was taken during Colonoscopy. The histopathology showed multiple fragments of colonic mucosal tissue having dispersed atypical cells in the lamina propria. These cells had scant cytoplasm and nuclei were round to oval, had coarse nuclear chromatin, prominent nucleoli and mitosis were seen. This histopathology suggested the differential diagnosis of non-Hodgkin lymphoma and poorly differentiated carcinoma. And further immunohistochemistry was done from the sample which showed CK was negative and LCA (CD45) was positive (can be positive in both neoplastic and non-neoplastic lymphoid cells) and these findings did not confirm non-Hodgkin lymphoma.

Her CECT showed asymmetrical circumferential thickening spanning a length of 8 mm is noted in hepatic flexure of colon. There was heterogeneous enhancement in the post contrast images with maximum thickness of 12 mm. Shouldering was noted in the proximal aspect of the thickening. In addition, approx. 7 \* 5 mm sized hypo dense subtle rim enhancement lesion was noted in segment II of liver. CECT findings were preoperatively suggestive of carcinoma of hepatic flexure of colon with hepatic metastasis (Fig. 3).

CEA was 1.4 ng/ml, CA-125 was 13.1 U/ml and CA-19.9 U/ml was

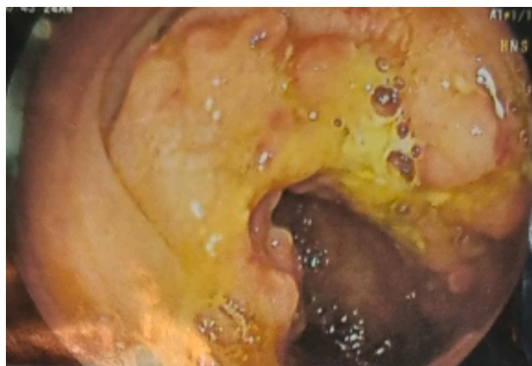


Fig. 1. Procto-sigmoiditis (likely due to radiation) as well as ulcerative growth and friable tissue in the hepatic flexure of the colon.

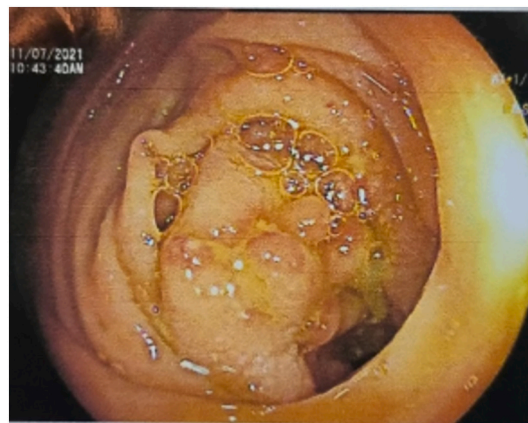


Fig. 2. Friable tissue in the hepatic flexure of the colon.

## 21.2.

Based on these findings, a provisional diagnosis of carcinoma hepatic flexure of colon with liver metastasis was made. The patient underwent right standard hemicolectomy with side-to-side anastomosis. The suspicious liver metastasis was also addressed with metastasectomy. Intraoperative findings showed a firm circular mass in the distal ascending colon measuring 2 cm \* 2 cm (Fig. 4).

The histopathological report revealed necrotizing granulomatous colitis suggestive of tuberculosis, with no evidence of malignancy (Figs. 5 and 6). Even the lymph nodes showed granulomas and Langhans giant cells (Fig. 7).

Then, anti-tuberculous therapy as per national tuberculosis guidelines was initiated with daily doses of isoniazid 300 mg, rifampicin 600 mg, pyrazinamide 1500 mg, and ethambutol 900 mg for 2 months followed by isoniazid and rifampicin for 4 months. The patient is recovering well and she is on regular follow-up.

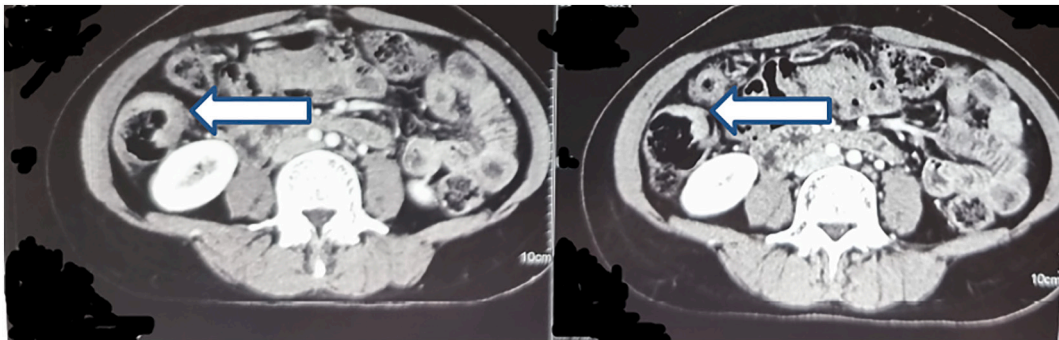
## 3. Discussion

Tuberculosis is common in the developing world. Among extra-intestinal manifestations, intestinal TB is common. Ileocecal TB is the common variety and isolated colonic tuberculosis is rare [5]. The intestinal TB is increasing with the rise in numbers of high-risk patients such as HIV-infected individuals, patients with chronic renal disease, and immunosuppressed patients on immunosuppressive or prolonged steroid therapy. Most reported colonic TB cases in non-immunosuppressed individuals come from South Asian belt where prevalence of pulmonary TB is also more [6,7]. The most common presentation is abdominal pain and abdominal mass (90% and 58% of patients, respectively) [8]. They also have nonspecific symptoms like weight loss and loss of appetite. Colonic tuberculosis may have altered bowel habits and melena.

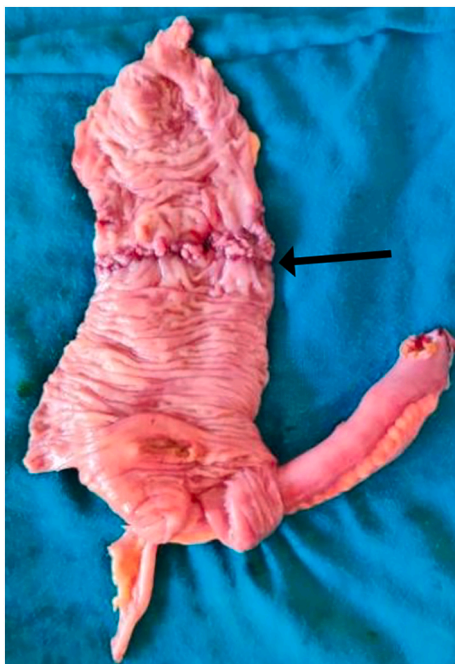
Since clinical presentation of colonic malignancy, colonic TB, Crohn's disease and ulcerative colitis may be similar, preoperative diagnosis can be difficult [9,10]. Some authors recommend a trial of anti-tuberculous chemotherapy in patients with high clinical suspicion of TB even in the absence of the classic features of TB, after ruling out other causes like cancer and Crohn's disease by histopathological examination [11].

TB and colon cancer may also coexist and there are some reported cases of coexistence of these two [11]. This coexistence may be of high frequency necessitating the need for epidemiological and histopathological investigations into the aetiological relationship between the two diseases [12].

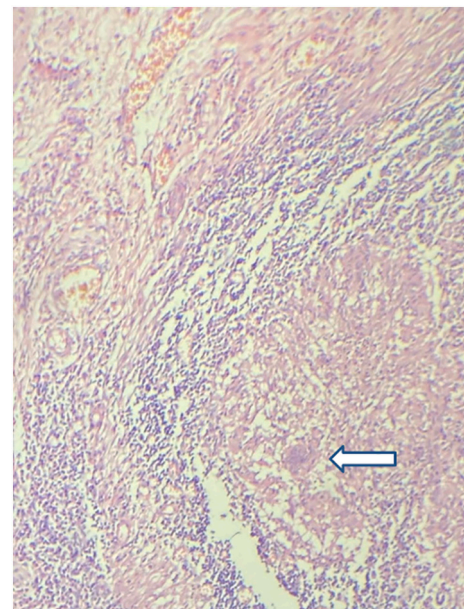
Colonoscopy and biopsy, histopathology and bacteriological study of biopsy specimens can diagnose intestinal TB in 60% of patients without the need for resectional surgery [6].



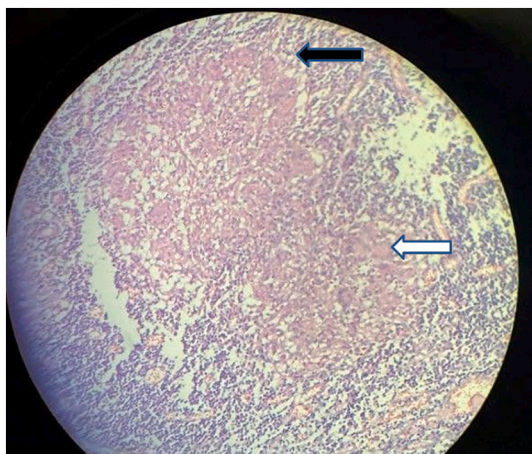
**Fig. 3.** Asymmetrical circumferential thickening at the hepatic flexure of colon (white arrow) and shouldering in the proximal aspect of the thickening.



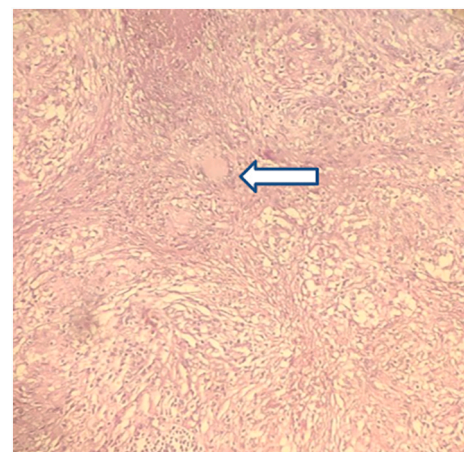
**Fig. 4.** Resected specimen of the colon and terminal ileum with appendix, showing the stricturing lesion near the hepatic flexure (black arrow).



**Fig. 6.** Central caseous necrosis and few Langerhans giant cells (white arrow) which is surrounded by collar of lymphocytes.



**Fig. 5.** Sections of ascending colon show multiple epithelioid cell submucosal granulomas, caseous necrosis and multinucleated Langerhans giant cells (white arrow). Underlying lamina propria shows moderate chronic lymphoplasmacytic infiltration (black arrow).



**Fig. 7.** Langerhans giant cells (white arrow) over lymph nodes.

However, the colonoscopic features are quite variable. Typical colonoscopy shows circumferential ulceration or a single ulcer with an elevated or nodular margin surrounded by hyperemic mucosa [5]. Colonoscopy may also show nodules, deformed segment of the colon/

cecum, polypoid lesions or pseudo-polyps, strictures, and less commonly, fibrous bands forming mucosal bridges [5]. Histopathology reveals well-formed granuloma which may have caseation or may have confluence of granulomas. Some may have acid-fast bacilli [13].

Tuberculous lesions may mimic carcinoma in 20% of cases and acid-fast bacilli (AFB) may not be isolated at all [8]. Polymerase chain reaction (PCR) analysis of a colonic biopsy may reveal AFB of the mycobacterium tuberculosis. PCR is also valuable in the differentiation between intestinal TB and Crohn's disease [14].

Contrast-enhanced CT (CECT) has a major role to suggest the diagnosis of abdominal tuberculosis. Peritoneal TB is most common and presents with ascites. Lymphadenopathy is most commonly presented as necrotic nodes at mesenteric, peripancreatic, periportal, and upper paraaortic regions. Commonest site of bowel involvement is ileocecal region, with the commonest pattern of involvement being circumferential bowel wall thickening without bowel stratification with mild luminal narrowing [15]. Other features are cecal amputation, ileocecal thickening and inflammation, shortening of the ascending colon, gaping of the ileocecal valve, mesenteric adenopathy, a misty mesentery, diffuse omental infiltration, loculated high-density ascites, an enhancing peritoneum with or without an omental line, nodularity of the surface of the mesenteric leaves, and transperitoneal permeation [16]. Other commonly observed radiological findings include strictures, colitis and less frequently polypoid lesions [16]. Complications like perforations and fistulae may also be seen [15].

In our case, the preoperative scenario of the carcinoma cervix misled us and we approached towards evaluation of carcinoma. Colonoscopy findings were more indicating towards carcinoma. Postoperative histopathology was a surprise, which came out tuberculosis. And the patient responded well to anti-tuberculosis drugs.

Our colonoscopic biopsy sample suggested the differential diagnosis of non-Hodgkin lymphoma and poorly differentiated carcinoma. As immunohistochemistry was done from that sample showed CK was negative and LCA (CD45) was positive (can be positive in both neoplastic and non-neoplastic lymphoid cells) [17] and these findings could be of non-Hodgkin lymphoma. Since the chemotherapeutic agents can cause lymphoma [18], we thought our case could be of lymphoma too. There were some reported cases of atypical presentation of lymphoma too [19]. to our surprise, even the immunohistochemistry came out inconclusive.

Here, intraoperative findings showed colonic stricture and symptomatic colonic stricture mandates resection [20].

Apart from tuberculosis, sometimes carcinoma may masquerade Crohn's disease too [21]. A clinician should always keep these scenarios in mind.

#### 4. Conclusion

Though colonic tuberculosis is rare, it can mimic colonic carcinoma. Though a patient undergoing chemotherapy may develop lymphoma, colonoscopic biopsy may not be conclusive. In any symptomatic patient with colonic stricture, surgery is the treatment of choice.

#### Consent

A written informed consent was obtained from the patient and patient's family member for publication of this case report. A copy of the written consent is available for review by the Editor-in-Chief of this journal on request.

#### Ethical approval

Nothing to declare.

#### Funding

None.

#### Guarantor

Gagan Adhikari.

#### Research registration number

1. Name of the registry: –
2. Unique identifying number or registration ID: –
3. Hyperlink to your specific registration (must be publicly accessible and will be checked): –.

#### CRedit authorship contribution statement

Gagan Adhikari, Jayant Kumar Shah, Bikal Ghimire and Prasan BS Kansakar: Study concept, Data collection, and surgical therapy for patient.

Gagan Adhikari and Bishal Buda: Writing and original draft preparation.

Gagan Adhikari, Jayant Kumar Shah, Bikal Ghimire and Prasan BS Kansakar: Editing and writing.

Jayant Kumar Shah, Bikal Ghimire and Prasan BS Kansakar: senior authors and manuscript reviewer.

All the authors read and approved the final manuscript.

#### Declaration of competing interest

None.

#### References

- [1] V. Singh, P. Kumar, J. Kamal, V. Prakash, K. Vaiphei, K. Singh, Clinicocolonoscopy profile of colonic tuberculosis, *Am. J. Gastroenterol.* 91 (3) (1996) (Springer Nature).
- [2] L.E. Subak, H. Hricak, C.B. Powell, E. Azizi, J.L. Stern, Cervical carcinoma: computed tomography and magnetic resonance imaging for preoperative staging, *Obstet. Gynecol.* 86 (1) (1995) 43–50.
- [3] R.A. Agha, T. Franchi, C. Sohrabi, G. Mathew, A. Kerwan, A. Thoma, et al., The SCARE 2020 guideline: updating consensus surgical CAse REport (SCARE) guidelines, *Int. J. Surg.* 84 (2020) 226–230.
- [4] W.-J. Koh, N.R. Abu-Rustum, S. Bean, K. Bradley, S.M. Campos, K.R. Cho, et al., Cervical cancer, version 3.2019, NCCN clinical practice guidelines in oncology, *J. Natl. Compr. Cancer Netw.* 17 (1) (2019) 64–84.
- [5] J.F. Alvares, H. Devarbhavi, P. Makhija, S. Rao, R. Kottoor, Clinical, colonoscopic, and histological profile of colonic tuberculosis in a tertiary hospital, *Endoscopy* 37 (04) (2005) 351–356.
- [6] D.K. Bhargava, A.K.S. Kushwaha, S. Dasarathy, P. Chopra, Endoscopic diagnosis of segmental colonic tuberculosis, *Gastrointest. Endosc.* 38 (5) (1992) 571–574.
- [7] B. Nagi, R. Kochhar, D.K. Bhasin, K. Singh, Colorectal tuberculosis, *Eur. Radiol.* 13 (8) (2003) 1907–1912.
- [8] R. Kaushik, R. Sharma, A.K. Attri, Coexisting tuberculosis and carcinoma of the colon: a report of two cases and a review of the literature, *Trop. Gastroenterol. Off. J. Dig. Dis. Found.* 24 (3) (2003) 137–139.
- [9] M.J. Navarro, D. Banayo, S.M. Verallo, A case of ascending colon mass in an immunocompetent individual secondary to intestinal tuberculosis masquerading as metastatic colon cancer, *GutLiver* 13 (2019).
- [10] S. Kedia, P. Das, K.S. Madhusudhan, S. Dattagupta, R. Sharma, P. Sahni, et al., Differentiating Crohn's disease from intestinal tuberculosis, *World J. Gastroenterol.* 25 (4) (2019) 418.
- [11] A.F. Leong, F. Seow-Choen, H.S. Goh, Colorectal cancer and intestinal tuberculosis, *Ann. Acad. Med. Singap.* 22 (6) (1993) 934–936.
- [12] B.K. Jain, S.S. Chandra, R. Narasimhan, N. Ananthakrishnan, R.B. Mehta, Coexisting tuberculosis and carcinoma of the colon, *Aust. N. Z. J. Surg.* 61 (11) (1991) 828–831.
- [13] A.B. Al-Zanbagi, M.K. Shariff, Gastrointestinal tuberculosis: a systematic review of epidemiology, presentation, diagnosis and treatment, *Saudi J. Gastroenterol. Off. J. Saudi Gastroenterol. Assoc.* 27 (5) (2021) 261.
- [14] H. Gan, Q. Ouyang, H. Bu, S. Li, D. Chen, G. Li, et al., Value of polymerase chain reaction assay in diagnosis of intestinal tuberculosis and differentiation from Crohn's disease, *Chin. Med. J.* 108 (03) (1995) 215–220.

- [15] S.S. Deshpande, A.R. Joshi, S.S. Deshpande, S.A. Phajlani, Computed tomographic features of abdominal tuberculosis: unmask the impersonator!, *Abdom. Radiol.* 44 (1) (2019) 11–21.
- [16] H. Jadvar, R.E. Mindelzun, E.W. Olcott, D.B. Levitt, Still the great mimicker: abdominal tuberculosis, *AJR Am. J. Roentgenol.* 168 (6) (1997) 1455–1460.
- [17] S. Pervez, R.D.A. Khawaja, Mediastinal lymphomas: primary mediastinal (Thymic) large B-cell lymphoma versus classical hodgkin lymphoma, histopathologic dilemma solved? *Pathol. Pract.* 206 (6) (2010) 365–367.
- [18] B. Krishnan, G.J. Morgan, Non-hodgkin lymphoma secondary to cancer chemotherapy, *Cancer Epidemiol. Prev. Biomark.* 16 (3) (2007) 377–380.
- [19] C.D. Ekanayake, R. Punchihewa, P.S. Wijesinghe, An atypical presentation of an ovarian lymphoma: a case report, *J. Med. Case Rep.* 12 (1) (2018) 1–3.
- [20] E.J. Williams, E.O. Lange, Colonic stricture, in: *Clinical Decision Making in Colorectal Surgery*, Springer, 2020, pp. 375–380.
- [21] C. Chatzicostas, I.E. Koutroubakis, M. Tzardi, M. Roussomoustakaki, P. Prassopoulos, E.A. Kouroumalis, Colonic tuberculosis mimicking Crohn's disease: case report, *BMC Gastroenterol.* 2 (1) (2002) 1–4.