

# Pebbled Trachea: A Case Series and Literature Review of Tracheobronchopathia Osteochondroplastica

Deepthi Sharma, Sindhu Kamath, Vishak K Acharya, Sharada Rai<sup>1</sup>

Departments of Pulmonary Medicine and <sup>1</sup>Pathology, Kasturba Medical College, Manipal Academy of Higher Education, Mangalore, Karnataka, India

## Abstract

We report a series of three cases diagnosed with tracheobronchopathia osteochondroplastica on bronchoscopy and computed tomography (CT) chest. Most patients were diagnosed incidentally on evaluation for chronic cough. The association of this entity with chronic bacterial infections and tuberculosis is an intriguing entity that was observed in our patients. Nodular, ulcerative, and calcific lesions in the trachea are bronchoscopic findings seen in quite a few other conditions posing diagnostic challenges. However, the classical bronchoscopic appearance with CT imaging in an appropriate clinical context can lead to an accurate diagnosis of this condition. We describe this array of cases with varying clinical presentations, their associations, and deliberate the literature reviews on this rare entity.

**Keywords:** Bronchoscopy, chronic infections, osteocartilaginous nodules, tracheobronchopathia osteochondroplastica, tuberculosis

## INTRODUCTION

Tracheobronchopathia osteochondroplastica (TPO) is an idiopathic and benign disease of the large airways characterized by submucosal osteocartilaginous nodules in the anterior and lateral walls of trachea, typically sparing the posterior membranous wall with or without the involvement of the major bronchi.<sup>[1,2]</sup> Most cases of TPO are either asymptomatic or present with nonspecific respiratory symptoms leading to an under-recognition of this rare disease. Over the last few decades, several case reports have revealed its clinical features, but the etiology and the long-term prognosis are poorly understood. In this case series, we review the literature on possible etiologies, associations, complications, and presentation of this rare entity.

## CASE REPORT

### Case-1

A 55-year-old diabetic female presented to our respiratory unit with complaints of dry cough and Grade 2 (modified Medical Research Council) breathlessness for 1 year. She gave no history of tuberculosis or respiratory illness in the past. She was not a smoker or an alcoholic.

Her general physical and respiratory system examination was normal with no added sounds on auscultation. Chest

X-ray, computed tomography (CT) thorax, blood and sputum examination reports revealed no abnormalities. Bronchoscopy showed whitish, hard, nodulo-ulcerative lesions in the trachea up to the bronchi unyielding to the biopsy forceps. Her lavage culture grew *Klebsiella pneumoniae* and *Staphylococcus aureus*. Bronchial wash acid-fast bacilli (AFB) culture was positive for *Mycobacterium tuberculosis* after 2 weeks; hence, she was put on 6 months of anti-tubercular (anti-TB) treatment after an initial course of parenteral antibiotics as per the lavage culture and sensitivity (C/S) report. However, at the end of the treatment, her cough persisted. Repeat bronchoscopy revealed persistent nodules within the trachea [Figure 1a]. On biopsy, the lesions had a gritty feel. Her repeat lavage samples grew *K. pneumoniae* and *S. aureus*, but AFB smear was negative for TB bacilli. Biopsies sent for histopathological examination (HPE) confirmed the diagnosis of TPO [Figure 2].

**Address for correspondence:** Dr. Sindhu Kamath, Department of Pulmonary Medicine, Kasturba Medical College, Manipal Academy of Higher Education, Attavar, Mangalore - 575 001, Karnataka, India.  
E-mail: sindhu.kamath@manipal.edu

This is an open access journal, and articles are distributed under the terms of the Creative Commons Attribution-NonCommercial-ShareAlike 4.0 License, which allows others to remix, tweak, and build upon the work non-commercially, as long as appropriate credit is given and the new creations are licensed under the identical terms.

**For reprints contact:** WKHLRPMedknow\_reprints@wolterskluwer.com

**How to cite this article:** Sharma D, Kamath S, Acharya VK, Rai S. Pebbled trachea: A case series and literature review of tracheobronchopathia osteochondroplastica. J Global Infect Dis 2021;13:180-2.

**Received:** 21 October 2020

**Revised:** 23 March 2021

**Accepted:** 07 May 2021

**Published:** 09 November 2021

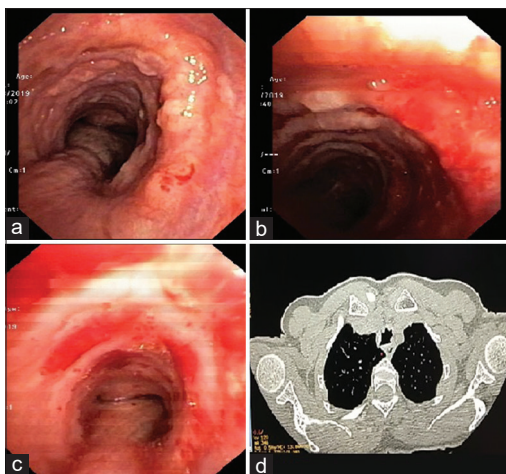
### Access this article online

Quick Response Code:



Website:  
www.jgid.org

DOI:  
10.4103/jgid.jgid\_379\_20



**Figure 1:** (a and b) Bronchoscopy revealing osteocartilaginous nodules in the anterior wall of the trachea with distribution along the cartilaginous rings. (c) Bronchoscopy revealing ulcerative lesions in the anterior wall of the trachea sparing the posterior membranous wall. (d) Computed tomography consistent with tracheobronchopathia osteochondroplastica: Beaded intraluminal calcifications and increased luminal thickening

She was prescribed inhaled bronchodilators and symptomatic management for cough. She was on regular follow-up for 1 year with resolution of symptoms.

### Case-2

A 69-year-old hypertensive female presented with breathlessness on exertion for 6 months which had worsened since 20 days.

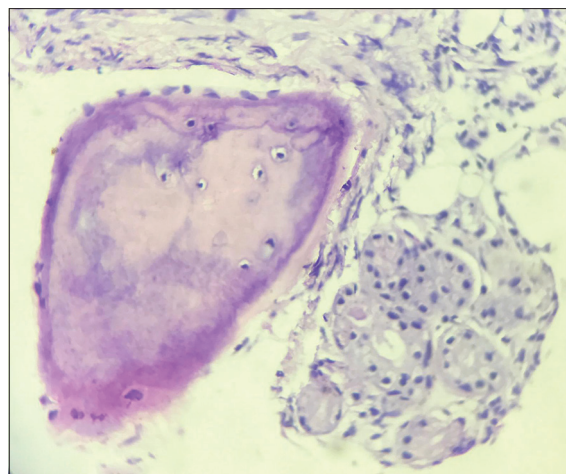
As her respiratory system examination was unremarkable and chest x-ray was normal, CT thorax was done which revealed nodular thickening of the anterior wall of the trachea sparing the posterior wall giving a stellate appearance of anterior third of the trachea in the coronal view [Figure 1d]. Bronchoscopy confirmed multiple whitish, firm nodules in the trachea sparing the posterior wall [Figure 1b]. Her bronchial lavage cultures grew *Acinetobacter spp* but were negative for AFB by stain and cultures.

The patient was initiated on a course of antibiotics as per the C/S report and followed up for a period of 1 year with no worsening of symptoms.

### Case-3

A 50-year-old male nonsmoker presented to our respiratory unit with complaints of cough with scanty sputum for 15 days. Respiratory system examination was unremarkable. CT thorax done showed patchy areas of consolidation in the bilateral lower lobes. He underwent flexible bronchoscopy which revealed extensive ulcerative lesions involving the anterior wall of the trachea with luminal narrowing [Figure 1c].

Bronchial wash sample was positive for *K. pneumoniae* hence appropriate antibiotics were given. He showed marginal improvement of symptoms following it. A repeat bronchoscopy was performed after 3 months and it showed persistent anterior tracheal wall lesions and HPE showed squamous metaplasia



**Figure 2:** Histopathological examination showing hyperplastic respiratory epithelium and fibrocollagenous tissue along with mature bone in subepithelium

with chronic lymphoplasmacytic infiltrates suggestive of TPO. He was started on inhaled corticosteroids for symptomatic management and regularly followed up for a year.

## DISCUSSION

The first case of TPO was reported by Samuel Wilks in 1857 in a 38-year-old male patient who had died of tuberculosis. Since then, more than 500 cases of TPO have been reported worldwide.<sup>[3]</sup> TPO is a disease of unknown etiology usually diagnosed incidentally in the sixth and seventh decades of life with a male predilection.

One of the important theories postulated for the etiology of TPO is chronic infection including tuberculosis. In a study by Zhu *et al.*, chronic inflammation of airways was weighed in as an important factor in the course of TPO.<sup>[3]</sup> In the course of chronic infections, the mucosa undergoes a low-grade inflammatory process causing squamous metaplasia of the epithelium.<sup>[3]</sup> All our patients had evidence of chronic, persistent infections on lavage. It is difficult to deduce if these chronic infections were the cause for TPO or if they were secondary infections due to epithelial desquamation seen in TPO.

Other major theories include long-term chemical or mechanical irritation, chronic respiratory tract infection by *M. ozaenae*, genetic predilection, primary amyloidosis, malignancy, degenerative abnormalities, and calcium and phosphorus metabolic disorders. The clinical features include nonspecific respiratory symptoms such as productive or nonproductive chronic cough, hemoptysis, dyspnea, dryness of the throat, recurrent, and slow resolving pneumonia.<sup>[4,5]</sup>

The diagnosis is made by imaging with CT scan, bronchoscopy, incidentally during intubation or on an autopsy.<sup>[6]</sup> Typical CT findings include irregular tracheobronchial wall thickening, multiple submucosal nodules, with or without calcifications, sparing the posterior membranous wall. CT-generated virtual bronchoscopy is a

novel technique that allows noninvasive visualization of the tracheobronchial tree and diagnosis.<sup>[7]</sup>

Bronchoscopy remains the gold standard for the diagnosis of TPO. The bronchoscopic appearance is typically characterized by the multiple, varied size whitish nodules sparing the posterior membranous wall.<sup>[8]</sup> Biopsy of these nodules is often difficult to obtain owing to its grittiness which makes the forceps slip off on their surfaces.<sup>[9]</sup>

TPO is a diagnosis of exclusion. Other common causes of tracheal nodules with or without calcifications include relapsing polychondritis, amyloidosis, endobronchial sarcoidosis, papillomatosis, granulomatosis polyangiitis, chondrosarcoma, tuberculoid calcifications, scleroderma, and malignancies. Hence, awareness is highly pertinent among the treating clinicians to identify the characteristic lesions sparing the posterior membranous wall and radiological features to arrive at correct diagnosis.<sup>[10]</sup>

TPO is a benign condition with treatment offered only to those patients who have persistent respiratory complaints. Symptomatic management is done including antibiotics for recurrent infections, reduction of airway irritation with anti-inflammatory drugs, antitussives, and prevention of complications. In severe cases of lumen obstruction with distressing symptoms, interventional strategies using a combination of rigid bronchoscopy, laser photocoagulation, mechanical debulking, and silicone stent placement have been used.<sup>[5]</sup>

### Declaration of patient consent

The authors certify that they have obtained all appropriate patient consent forms. In the form, the patients have given their consent for their images and other clinical information to be reported in the journal. The patients understand that their names and initials will not be published and due efforts will be made to conceal their identity, but anonymity cannot be guaranteed.

### Research quality and ethics statement

The authors followed applicable EQUATOR Network ([“http://www.equator-network.org/”](http://www.equator-network.org/)) guidelines, notably the CARE guideline, during the conduct of this report.

### Financial support and sponsorship

Nil.

### Conflicts of interest

There are no conflicts of interest.

### REFERENCES

- JabbarDarjani HR, Radpey B, Kharabian S, Masjedi MR. Tracheobronchopathia osteochondroplastica: Presentation of ten cases and review of the literature. *Lung* 2008;186:293-7.
- Fois AG, Arcadu A, Santoru L, Trisolini R, Marras V, Ginesu GC, *et al.* Tracheobronchopathia Osteochondroplastica: A rare case report of a non-smoker and non-atopic patient, with a long history of wheezing since childhood. *Multidiscip Respir Med* 2016;11:16.
- Zhu Y, Wu N, Huang HD, Dong YC, Sun QY, Zhang W, *et al.* A clinical study of tracheobronchopathia osteochondroplastica: Findings from a large Chinese cohort. *PLoS One* 2014;9:e102068.
- Luo T, Zhou H, Meng J. clinical characteristics of tracheobronchopathia osteochondroplastica. *Respir Care* 2019;64:196-200.
- Dutau H, Musani AI. Treatment of severe tracheobronchopathia osteochondroplastica. *J Bronchol* 2004;11:182-5.
- Zack JR, Rozenshtein A. Tracheobronchopathia osteochondroplastica: Report of three cases. *Comput Assist Tomogr* 2002;26:33-6.
- De Wever W, Vandecaveye V, Lanciotti S, Verschakelen JA. Multidetector CT-generated virtual bronchoscopy: An illustrated review of the potential clinical indications. *Eur Respir J* 2004;23:776-82.
- Prince JS, Duhamel DR, Levin DL, Harrell JH, Friedman PJ. Nonneoplastic lesions of the tracheobronchial wall: Radiologic findings with bronchoscopic correlation. *Radiographics* 2002;22 Spec No: S215-30.
- Jindal S, Nath A, Neyaz Z, Jaiswal S. Tracheobronchopathia osteochondroplastica – A rare or an overlooked entity? *J Radiol Case Rep* 2013;7:16-25.
- Devaraja K, Sagar P, Chirom AS. Tracheobronchopathia osteochondroplastica: Awareness is the key for diagnosis and management. *BMJ Case Rep* 2017;2017:1-3. Available from: <https://pubmed.ncbi.nlm.nih.gov/28784888/>.