

## Left Atrial Myxoma Presenting with Unusual Cystic Form

Kwon Jae Park, M.D., Jong Soo Woo, M.D., Jong Yoon Park, M.D.

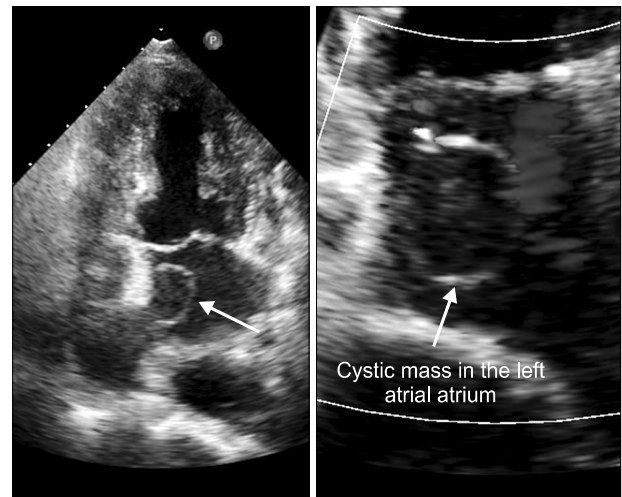
Cardiac myxomas are the most common primary benign tumors of uncertain etiology. They usually present as polypoid or oval-shaped masses projecting into a heart chamber from the interatrial septum and have a soft, gelatinous consistency without a cystic structure. We report a case of left atrial myxoma with a single cystic form.

Key words: 1. Heart neoplasms  
2. Myxoma  
3. Cysts

### CASE REPORT

A 65-year-old woman was referred to our department because of a recently diagnosed left atrial (LA) mass. She presented with a five-month history of fever, malaise, and myalgia and had been diagnosed with ventricular septal defect (VSD) two years earlier. On physical examination, a grade of 4/6 systolic murmur was heard at the left sternal border. Electrocardiography and a chest X-ray were unremarkable. Two-dimensional transthoracic echocardiography showed an LA cyst (24×23 mm) that was attached to the interatrial septum and detected the trace of blood flow at the margin of the cyst (Fig. 1). The VSD was a small perimembranous type and the pulmonary blood flow to systemic blood flow ratio (Qp/Qs) was 1.2.

The patient underwent surgical treatment. The cystic mass attached to the left side of the interatrial septum was white-pink-yellowish and oval in shape. It had a small opening on the surface and was 2.2×1.6 cm (Fig. 2). The cystic mass was widely excised with the atrial septum, leaving the defect in the atrial septum, and the small VSD was closed with two



**Fig. 1.** Transthoracic echocardiography showing a thin walled, cystic mass in the left atrium.

pledgeted sutures without a patch. The defect on the atrial septum was closed with an artificial patch (polytetrafluoroethylene, Gore-Tex patch; WL Gore & Assoc, Flagstaff, AZ, USA). The mass was a single cyst and didn't have any content. The diagnosis of myxoma was confirmed by microscopic

Department of Thoracic and Cardiovascular Surgery, Dong-A University Hospital, Dong-A University College of Medicine

Received: February 5, 2013, Revised: April 4, 2013, Accepted: April 8, 2013

Corresponding author: Jong Soo Woo, Department of Thoracic and Cardiovascular Surgery, Dong-A University Hospital, Dong-A University College of Medicine, 26 Daesingongwon-ro, Seo-gu, Busan 602-715, Korea  
(Tel) 82-51-240-5195 (Fax) 82-51-231-5195 (E-mail) [jswoo@dau.ac.kr](mailto:jswoo@dau.ac.kr)

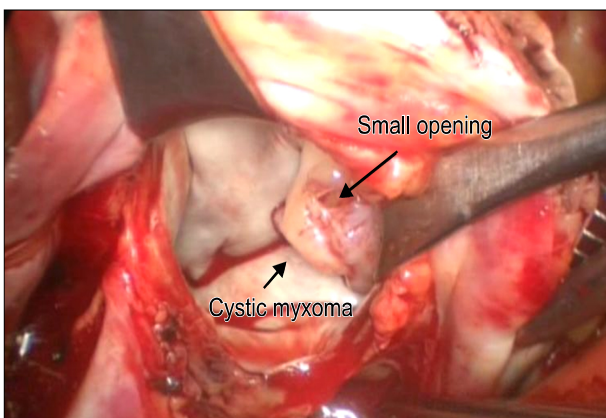
© The Korean Society for Thoracic and Cardiovascular Surgery. 2013. All right reserved.

© This is an open access article distributed under the terms of the Creative Commons Attribution Non-Commercial License (<http://creativecommons.org/licenses/by-nc/3.0>) which permits unrestricted non-commercial use, distribution, and reproduction in any medium, provided the original work is properly cited.

examination. Histologically, the mass consisted of myxoid cells in abundant loose and myxoid stroma, and the tumor cells were round or polygonal with eosinophilic cytoplasm (Fig. 3). Postoperative echocardiography revealed no VSD shunt and no mass in the left atrium. The patient was discharged 16 days after surgery without any problem.

## DISCUSSION

LA myxoma is usually a solid, round or polypoid mass without a cystic structure attached to the interatrial septum [1]. The size of the mass ranges from 1 to 15 cm and is usually about 5 to 6 cm. The mass has solid content with a consistency varying according to the amount of collagen it con-



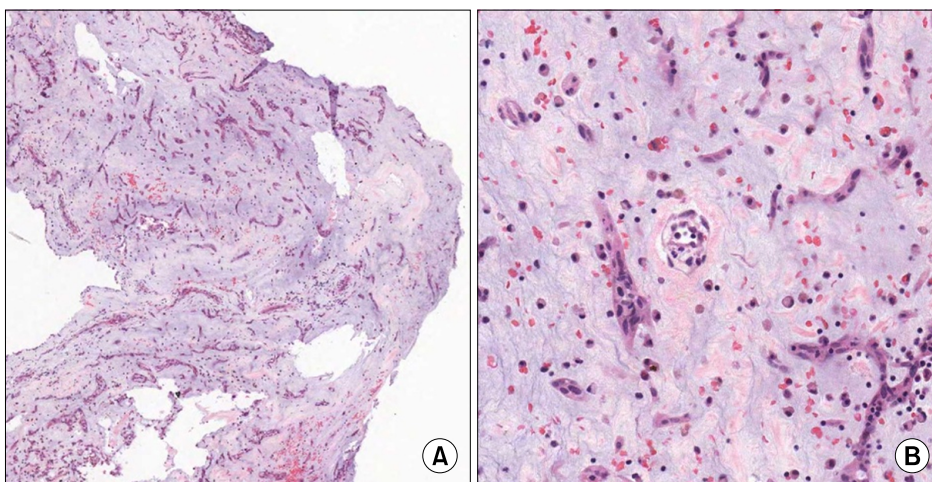
**Fig. 2.** The cystic mass in the left atrium was exposed through the left atriotomy.

tains [2]. The preoperative diagnosis of a cardiac mass has been enabled by echocardiographic examination. In this case, it was difficult to establish the diagnosis of the mass preoperatively because of its cystic structure without any content. At first, we tried to simply observe the patient without surgery. However, we believed that it was not a simple cyst and that surgical excision was needed because she had had constitutional symptoms.

Myxomas originated from the mesenchymal cells of the septal endocardium and can present as villous, papillary, sessile or pedunculated pattern and were usually divided into round and polypoid type and the majority of them are solid. Myxomas presenting with cystic form are rare [2-4]. The types of cystic masses that can appear in LA are as follows: myxoma, hydatid cyst, and interatrial septal aneurysm [5-8]. Owing to their many structural similarities, it is difficult to establish an accurate diagnosis using preoperative echocardiography. Major complications like stroke, rupture, and hemodynamic problems may develop if they are not removed. Therefore the surgical excision of an LA cyst is reasonable for establishing a definitive diagnosis and preventing sequelae.

## CONFLICT OF INTEREST

No potential conflict of interest relevant to this article was reported.



**Fig. 3.** (A) The mass consisted of myxoid cells in abundant loose and myxoid stroma (H&E,  $\times 40$ ). (B) The tumor cells were round or polygonal with eosinophilic cytoplasm (H&E,  $\times 200$ ).

## REFERENCES

1. Shapiro LM. *Cardiac tumours: diagnosis and management*. Heart 2001;85:218-22.
2. Lee GD, Lee JW, Jung JS, et al. *Clinical experiences for cardiac myxomas*. Korean J Thorac Cardiovasc Surg 2008; 41:703-9.
3. Yoo M, Graybeal DF. *An echocardiographic-confirmed case of atrial myxoma causing cerebral embolic ischemic stroke: a case report*. Cases J 2008;1:96.
4. Ha JW, Kang WC, Chung N, et al. *Echocardiographic and morphologic characteristics of left atrial myxoma and their relation to systemic embolism*. Am J Cardiol 1999;83: 1579-82, A8.
5. Wang XS, Mei YQ, Hu DY, Li DW, Ji Q. *A giant cyst-like mass: an unusual morphous of left atrial myxoma*. Chin Med J (Engl) 2009;122:236-7.
6. Biyik I, Acar S, Ergene O. *Left atrial mobile hydatid cyst mimicking left atrial myxoma and mitral stenosis and causing heart failure and arrhythmia*. Int J Cardiovasc Imaging 2007;23:193-5.
7. Kim JW, Kim YI, Cho WH, Park KS. *A closed right atrial septal aneurysm suspected as a tumor: 1 case report*. Korean J Thorac Cardiovasc Surg 2003;36:606-9.
8. Seebacher G, Binder T, Frank H, Wolner E, Mohl W. *Cystic formation of the foramen ovale mimicking a right atrial myxoma*. Ann Thorac Surg 2006;82:2296-8.