



Contents lists available at ScienceDirect

International Journal of Surgery Case Reports

journal homepage: www.casereports.com

Pericardial calcification: A case report of a three-dimensional disease

Raja Ohri, Kareem Salhiyyah*, Stephen Harding, Sunil Ohri

Wessex Cardiothoracic Centre, University Hospitals Southampton, Tremona Road, Southampton, SO16 6YD, United Kingdom

ARTICLE INFO

Article history:

Received 20 December 2018
 Received in revised form 22 February 2019
 Accepted 11 March 2019
 Available online 19 March 2019

Keywords:

Constrictive pericarditis
 Pericardial calcification
 Three-dimensional imaging

ABSTRACT

INTRODUCTION: Constrictive pericarditis is an important cause of diastolic heart failure. The relationship between the presence and degree of pericardial calcification with constrictive pericarditis is variable, however this should be an early warning sign to initiate appropriate investigations.

PRESENTATION OF CASE: A 64-year-old gentleman presented with dyspnoea and dizziness on exertion. Plain posterior-anterior chest X-ray showed mild to moderate pericardial calcification. He had an episode of atrial fibrillation which resolved spontaneously and thought to be the cause of his symptoms. Patient symptoms progressed. Further investigations including CT scan confirmed extensive constrictive pericarditis. He underwent a successful pericardiectomy and full recovery.

DISCUSSION: Constrictive pericarditis can be the consequence of different conditions such as tuberculosis, radiation, idiopathic or many others. Pericardial calcification is present in less than 25% of all cases of constrictive pericarditis, and patient with it are prone to develop atrial fibrillation. The presence of pericardial calcification on plain chest radiograph is an important indicator for the possibility of pericardial dysfunction. Many cases of pericardial calcification are benign without any clinical significance; however three-dimensional imaging is required to determine the calcium load and aid in reaching appropriate diagnosis.

CONCLUSION: Chest X-ray is valuable detector of pericardial calcification, a surrogate of pericardial constriction, but it is important to remember that pericardial calcification is a three-dimensional condition, and should be further investigated by lateral chest X-ray, CT scan and then appropriate functional imaging.

© 2019 The Authors. Published by Elsevier Ltd on behalf of IJS Publishing Group Ltd. This is an open access article under the CC BY license (<http://creativecommons.org/licenses/by/4.0/>).

1. Introduction

Constrictive pericarditis (CP) is a relatively uncommon condition caused by pericardial dysfunction secondary to different aetiologies. It results in impaired cardiac function and associated with diastolic heart failure [1]. It is associated with high morbidity and mortality and the early diagnosis and intervention improve outcomes [2]. The diagnosis can be challenging and require high index of suspicion. The relationship between pericardial calcification and CP is not definite. The presence of some pericardial calcification can be a benign phenomenon without any functional effect. On the other hand, pericardial calcification is only present in less than quarter of the cases of CP [3].

In this report, we present a case of CP associated with mild to moderate pericardial calcification, and emphasize on the importance of three-dimensional imaging in assessing the true extent of calcification and getting the accurate diagnosis. This report was written in line with the SCARE criteria [4].

2. Case presentation

A 64-year-old gentleman previously fit and well, apart from mild hypertension, generally active and enjoyed running, presented to the emergency department (ED) with an episode of acute shortness of breath and dizziness after running. He described episodes of progressive breathlessness over the previous few weeks. He was found to have atrial fibrillation (AF) which resolved spontaneously. The diagnosis of paroxysmal AF was made and his symptoms were attributed to his dysrhythmia. CT brain was normal, but a plain PA chest X-ray showed mild to moderate mediastinal calcification. The patient was discharged from ED without further treatment. However, he continued to deteriorate with progressive breathlessness and limitation of exercise tolerance. Eventually he was referred to a cardiologist and diagnosed with CP. The diagnosis was confirmed mainly on MRI scan which showed pericardial thickening. The interventricular septal morphology was abnormal with bowing into left ventricle consistent with ventricular coupling. This is exaggerated during dynamic inspiration and normalises during expiration consistent with constrictive physiology. Subsequently the patient was referred for surgery (Figs. 1–3).

He underwent successful pericardiectomy. The pericardium was stripped from the surface of the heart anteriorly, laterally from phrenic to phrenic and inferiorly. The right atrium was also released

* Corresponding author.

E-mail address: kareemsa@doctors.net.uk (K. Salhiyyah).

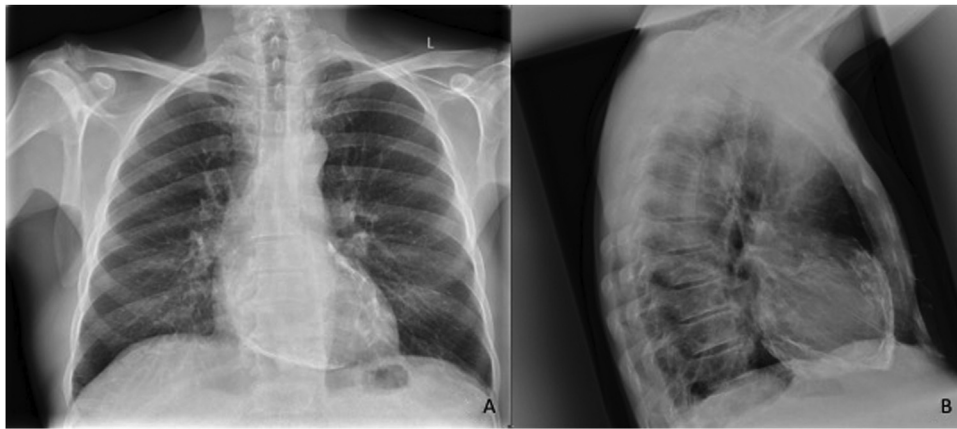


Fig. 1. (A): PA Chest X-ray showing mild to moderate pericardial calcification (B): Lateral Chest X-ray showing more extensive pericardial calcification.

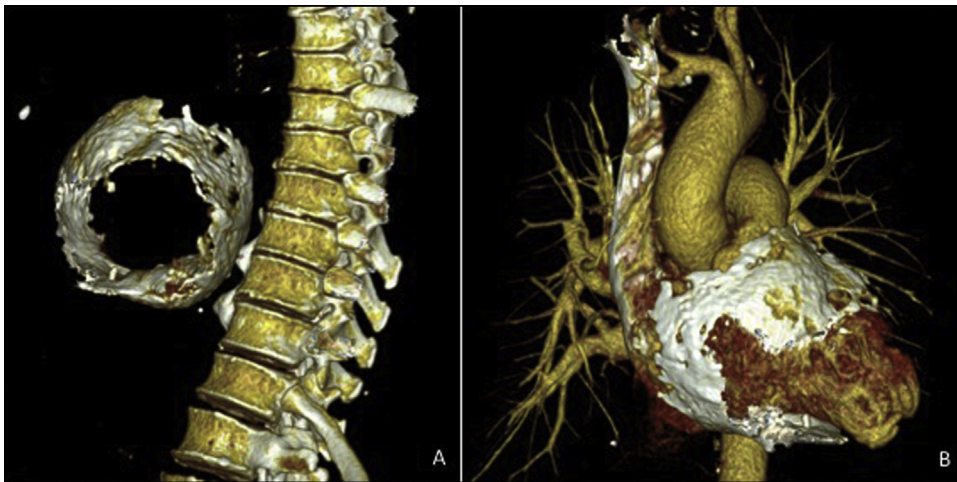


Fig. 2. (A): Three-dimensional CT reconstruction showing extensive circumferential pericardial calcification (B): Three-dimensional CT reconstruction with soft-tissue extraction showing extensive circumferential pericardial calcification.

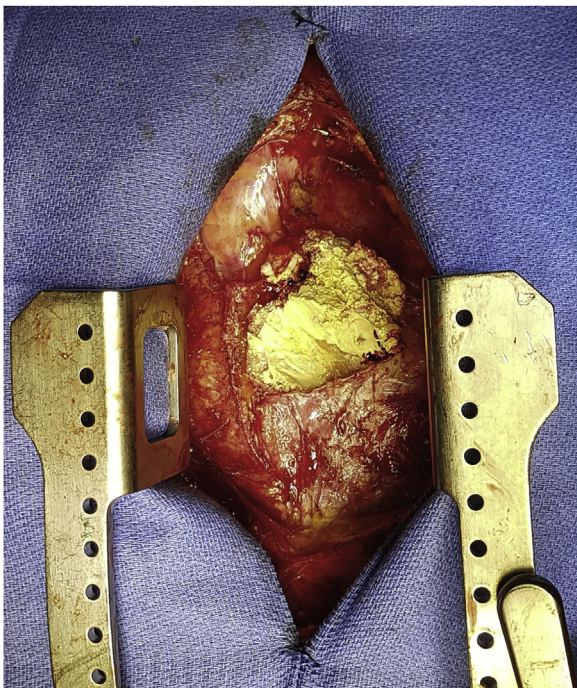


Fig. 3. Intra operative image showing severe pericardial calcification.

up to and around both cavae. He had an uneventful post-operative recovery. He was extubated 6 h post op. He intensive care stay was 40 h, during which he was kept on small dose dopamine (1.3 mcg/kg/min) as a precaution. His hospital length of stay was 5 days. He has returned to full activity and remains asymptomatic.

3. Discussion

Constrictive pericarditis is an important cause of diastolic heart failure. It is characterized by focal or global loss of pericardial compliance. It is associated with a variable degree of thickening, fibrosis and calcification [1]. Tuberculosis (TB) remains one of the leading causes in the developing world, whereas idiopathic or viral CP are more common in developed countries. Other causes of CP including radiotherapy, post-cardiac surgery and many other aetiologies.

Pericardial calcification is present in less than 25% of all cases of CP [3]. The cause of pericardial calcification is usually of uncertain aetiology. CP usually presents with symptoms of right heart failure. Patients with CP have increased incidence of developing atrial fibrillation [5].

The diagnosis of CP is made through a combination of different investigations, including echocardiography, computerised tomography (CT), magnetic resonance imaging (MRI) and right heart catheterisation [1,6]. Although chest X-ray has limited value in the diagnosis of CP, it has an important role in detecting pulmonary or pleural diseases and localising calcification to the pericardium.

This patient presented to the ED with progressive shortness of breath on exertion. He was found to have paroxysmal atrial fibrillation. A plain PA chest X-ray (CXR) film showed mild to moderate calcification, but a lateral chest X-ray was not undertaken. The symptoms were attributed to the AF alone. Unfortunately, no further investigations were organised. The pericardial calcification present on his PA CXR was overlooked. As the patient continued to deteriorate, he was only then referred to a cardiologist.

Early intervention with pericardiectomy is a predictor of good early and late outcome in CP [2]. Prolonged constriction can result in myocardial atrophy, residual constriction, and persistent heart failure despite successful pericardiectomy.

4. Conclusion

Although CP is an uncommon condition, this diagnosis should be kept in mind when patients present with cardiac symptoms. Chest X-ray remains a valuable early detector of pericardial calcification and hence increases the likelihood of CP, which should trigger a lateral CXR film and then appropriate subsequent functional imaging to confirm or refute the suspected diagnosis [6]. A prompt diagnosis and intervention will improve outcome.

Conflicts of interest

No conflict of interest.

Funding

No funding.

Ethical approval

No ethical approval was required.

Consent

Patient has kindly given a written informed consent for publication which is available for the Editor-in-Chief upon request.

Author contribution

Raja Ohri: Resources, Software, Methodology, Data curation, Writing – original draft.

Kareem Salhiyyah: Conceptualization, Resources, Software, Writing – review & editing, Project administration.

Stephen Harding: Resources, Software, Investigation, Formal analysis.

Sunil Ohri: Conceptualization, Funding acquisition, Writing – review & editing, Supervision, Validation.

Registration of research studies

No registration required.

Guarantor

Kareem Salhiyyah and Sunil Ohri.

Provenance and peer review

Not commissioned, externally peer reviewed.

References

- [1] W.R. Miranda, J.K. Oh, Constrictive pericarditis: a practical clinical approach, *Prog. Cardiovasc. Dis.* 59 (4) (2017) 369–379.
- [2] B.C. Depboylu, P. Mootoosamy, N. Vistarini, A. Testuz, I. El-Hamamsy, M. Cikirikcioglu, Surgical treatment of constrictive pericarditis, *Tex. Heart Inst. J.* 44 (2) (2017) 101–106.
- [3] B. Cosyns, S. Plein, P. Nihoyanopoulos, O. Smiseth, S. Achenbach, M.J. Andrade, et al., European Association of Cardiovascular Imaging (EACVI) position paper: multimodality imaging in pericardial disease, *Eur. Heart J. Cardiovasc. Imaging* 16 (1) (2015) 12–31.
- [4] R.A. Agha, A.J. Fowler, A. Saeta, I. Barai, S. Rajmohan, D.P. Orgill, et al., The SCARE statement: consensus-based surgical case report guidelines, *Int. J. Surg.* 34 (2016) 180–186.
- [5] G.R. Rezaian, M. Poor-Moghaddas, J. Kojuri, S. Rezaian, L. Liaghat, N. Zare, Atrial fibrillation in patients with constrictive pericarditis: the significance of pericardial calcification, *Ann. Noninvasive Electrocardiol.* 14 (3) (2009) 258–261.
- [6] Y. Adler, P. Charron, M. Imazio, L. Badano, G. Baron-Esquvias, J. Bogaert, et al., ESC Guidelines for the diagnosis and management of pericardial diseases: The Task Force for the Diagnosis and Management of Pericardial Diseases of the European Society of Cardiology (ESC) Endorsed by: The European Association for Cardio-Thoracic Surgery (EACTS), *Eur. Heart J.* 36 (42) (2015) 2921–2964, 2015.

Open Access

This article is published Open Access at [sciencedirect.com](https://www.sciencedirect.com). It is distributed under the [IJSCR Supplemental terms and conditions](#), which permits unrestricted non commercial use, distribution, and reproduction in any medium, provided the original authors and source are credited.