

# Air bubbles are released by thoracic endograft deployment: An in vitro experimental study

SAGE Open Medicine  
Volume 4: 1–5  
© The Author(s) 2016  
Reprints and permissions:  
sagepub.co.uk/journalsPermissions.nav  
DOI: 10.1177/2050312116682130  
smo.sagepub.com  


Kamuran Inci<sup>1</sup>, Giasemi Koutouzi<sup>2</sup>, Valery Chernoray<sup>3</sup>,  
Anders Jeppsson<sup>4</sup>, Håkan Nilsson<sup>3</sup> and Mårten Falkenberg<sup>2</sup>

## Abstract

**Purpose:** Embolic stroke is a dreaded complication of thoracic endovascular aortic repair. The prevailing theory about its cause is that particulate debris from atherosclerotic lesions in the aortic wall are dislodged by endovascular instruments and embolize to the brain. An alternative source of embolism might be air trapped in the endograft delivery system. The aim of this experimental study was to determine whether air is released during deployment of a thoracic endograft.

**Methods:** In an experimental benchtop study, eight thoracic endografts (five Medtronic Valiant Thoracic and three Gore TAG) were deployed in a water-filled transparent container drained from air. Endografts were prepared and deployed according to their instructions for use. Deployment was filmed and the volume of air released was collected and measured in a calibrated syringe.

**Results:** Air was released from all the endografts examined. Air volumes ranged from 0.1 to 0.3 mL for Medtronic Valiant Thoracic and from <0.025 to 0.04 mL for Gore TAG. The largest bubbles had a diameter of approximately 3 mm and came from the proximal end of the Medtronic Valiant device.

**Conclusion:** Air bubbles are released from thoracic endografts during deployment. Air embolism may be an alternative cause of stroke during thoracic endovascular aortic repair.

## Keywords

Air, embolism, thoracic endovascular aortic repair, stroke, experimental

Date received: 31 August 2016; accepted: 9 November 2016

## Introduction

Embolic stroke is a dreaded complication of thoracic endovascular aortic repair (TEVAR).<sup>1</sup> The prevailing theory about its cause is that manipulation of endovascular instruments in the aortic arch dislodges particulate debris from atherosclerotic lesions.<sup>2</sup> However, stroke can also occur after TEVAR in young trauma victims<sup>3–5</sup> who are unlikely to have developed such lesions.

Following abdominal endovascular aortic repair (EVAR), a collection of air is regularly observed in the aneurysm sac on early postoperative computed tomography (CT). This is considered to be innocuous, as the air is trapped in the excluded aneurysm, dissolves within a week or two, and does not appear to do any harm. No such collection of air is observed after TEVAR.

Endografts and delivery systems for the abdominal aorta and the thoracic aorta are similar in design, and air could

possibly be released during thoracic interventions also. If air bubbles are released in the proximal aorta during TEVAR, they may escape through the branches of the aortic arch and be an alternative cause of embolic stroke perioperatively.

<sup>1</sup>Department of Surgery, Varberg Hospital, Varberg, Sweden

<sup>2</sup>Department of Radiology, Sahlgrenska University Hospital, Gothenburg, Sweden

<sup>3</sup>Department of Applied Mechanics, Chalmers University of Technology, Gothenburg, Sweden

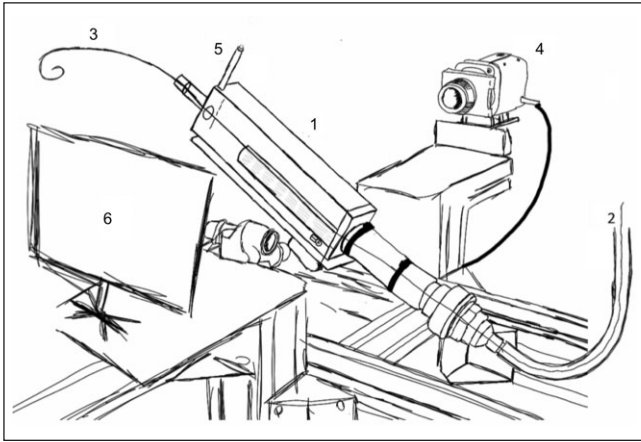
<sup>4</sup>Department of Thoracic Surgery, Sahlgrenska University Hospital, Gothenburg, Sweden

### Corresponding author:

Mårten Falkenberg, Department of Radiology, Sahlgrenska University Hospital, Bruna Stråket 11, SE-413 45 Gothenburg, Sweden.

Email: marten.falkenberg@vgregion.se





**Figure 1.** Experimental setup. The container (1) was mounted at an angle of  $40^\circ$ . The container and the access tubing (2) were filled with room-tempered water, free from air. The endografts were inserted through the access tubing over a 0.035-inch guide wire (3). Deployment was recorded with a high-speed camera (4) and the total volume of bubbles collected was measured using a Luer-lock syringe barrel mounted on the top of the container (5). A white shield (6) was used as background to improve the image quality.

The aim of this experimental study was to determine whether air bubbles are released by thoracic endograft deployment.

## Methods

Endografts were deployed in a water-filled transparent container. Deployment was filmed and the volume of air released was measured.

The  $80\text{ mm} \times 80\text{ mm} \times 300\text{ mm}$  rectangular container was made of clear glass with silicone sealants. It had pipe connections at both ends to allow a guide wire to pass through and to introduce (and evacuate) endografts. The barrel of a 1-mL Luer-lock syringe was attached to one of the upper corners and used to measure the volume of air released. A 65-cm-long rubber tube simulated vascular access vessels and a superstiff Lunderquist 0.035-inch guide wire (COOK) ran through both the tube and the container. The container was mounted at a  $40^\circ$  angle, with the entry of the access tube at the lower end and the Luer-lock syringe barrel at the upper end (Figure 1). The far end of the access tube was elevated above the container, and both the tube and the container were filled with distilled water at room temperature. Before each experiment, all visible bubbles attached to the inside of the glass were wiped off with a magnet and evacuated through the syringe barrel by aspiration in its Luer-lock connection.

The model was first tested by infusing variable and known volumes of air into the container. After each infusion, the container was tilted to assemble and collect all the bubbles into the attached Luer-lock syringe barrel. The air collected air volume was then measured. Volumes down to 0.025 mL could be verified. Volumes less than 0.025 mL could also be

**Table 1.** Results of measurement of volume of air released showing that air bubbles are released during deployment of a thoracic endograft.

Endograft type	Air volume (mL)
Valiant Thoracic 3434 100	0.2
Valiant Thoracic 4040 167	0.2
Valiant Thoracic 3232 100	0.3
Valiant Thoracic 3434 200	0.15
Valiant Thoracic 4040 167	0.1
Gore TAG 3110	0.04
Gore TAG 3420	<0.025
Gore TAG 4015	0.025

There appears to be a difference between the two types of endografts.

seen through the glass of the container, but they were too small to be measured accurately in the syringe.

Each deployment was filmed with a Phantom v341 high-speed camera (Vision Research) equipped with a Nikon Nikkor 28-mm f/2.8 lens. For the illumination, a 400-W halogen projector was used. The camera was equipped with a monochrome 12-bit low-noise CMOS sensor with a resolution of  $2560 \times 1600$  pixels. During each experiment, 1800 images were captured at a frame rate of 60 Hz. The images were processed with Mathworks MATLAB software.


Eight thoracic endografts were available and were used for the experiments. Five were made by Medtronic (Santa Rosa, CA, USA) and three by WL Gore & Associates (Flagstaff, AZ, USA) (Table 1). They were prepared and inserted according to the instructions for use (IFU). Briefly, all were flushed through the central lumen. The Valiant Thoracic delivery catheters were also flushed through the sidearm of the hub, with the tip of the catheter in a perpendicular position. The Gore TAG delivery catheter was inserted into the access tube through a Dry-Seal introducer sheath (Gore). Endografts were deployed in the container as described in the IFU.

## Results

Air was released from all endografts, and the volume from each endograft is shown in Table 1. Volumes ranged from 0.1 to 0.3 mL for the Medtronic Valiant endografts and from <0.025 to 0.04 mL for the Gore TAG endografts. Air bubbles mainly came out from the ends of the Valiant endografts (Figure 2). Some bubbles came from the inside of the graft and some bubbles were seen released from outside folds of the fabric when the endograft expanded. The largest bubbles had a diameter of approximately 3 mm and appeared from the proximal end of the Valiant endografts (Figure 2). Image and videos of released bubbles are shown in Figure 2.

## Discussion

We found that air is released during thoracic endograft deployment. Volumes ranged from less than 0.025 mL to



**Figure 2.** (a) Photograph of a Valiant Thoracic endograft deployment in the water-filled container, (b) magnification of (a) showing an air bubble released from inside the endograft during sheath retraction, (c) video of (b), (d) air bubbles released from distal end of Valiant Thoracic endograft, (e) video of (d), (f) air bubbles from proximal end of a Valiant Thoracic when the top stent is released, (g) video of (f), (h) large bubble released from proximal end of Valiant Thoracic endograft, and (i) video of (h).

0.3 mL, and the bubbles had diameters of up to 3 mm. To the best of our knowledge, this is the first report demonstrating that air bubbles are released during thoracic endograft deployment. Admittedly, any discussion regarding the clinical implications of these experimental observations is bound to be speculative, but we suggest that the possibility of air embolism as a cause of perioperative stroke during TEVAR should not be ignored.

TEVAR is now the therapy of choice for most patients with aneurysms and dissections in the descending aorta.<sup>6,7</sup> The main advantages compared to open surgery are less surgical trauma, less bleeding, and a lower risk of spinal cord ischemia.<sup>6,7</sup> However, stroke rates remain similar, at approximately 2%–5%.<sup>8</sup>

Furthermore, the aortic arch is the predicted next frontier for aortic endografting,<sup>9,10</sup> but enthusiasm is tempered by the higher stroke rate the more proximal the endograft is placed

in the arch.<sup>11–13</sup> Stroke during TEVAR appears to be predominantly embolic. Bismuth et al.<sup>14</sup> showed that the number of microembolic signals (MES) detected by transcranial Doppler was associated with rates of postoperative stroke, transient ischemic attack, and death. The majority of MES were recorded during the deployment of the endograft and not when devices were maneuvered into position. The authors suggested focusing on the deployment phase of endograft placement to better understand the mechanisms that lead to stroke.<sup>14</sup> Kahlert et al.<sup>2</sup> analyzed magnetic resonance imaging of the brain postoperatively and found that new embolic lesions appeared in approximately two-thirds of patients after TEVAR. Thus, the current evidence suggests that the majority of perioperative strokes during TEVAR are embolic. The assumption that these particles are predominantly solid, and not gaseous, was recently challenged by Kölbel et al.<sup>15</sup> who suggested a carbon dioxide flushing

technique of thoracic endografts to reduce the risk of air embolism. However, whether or not thoracic endografts actually do release air bubbles has not been previously shown.

In the literature, arterial air embolism is a recognized cause of stroke.<sup>16</sup> It has been described after open-heart surgery,<sup>17</sup> after accidental infusion of air during cardiac<sup>18</sup> and cerebrovascular<sup>19</sup> catheter interventions, and after accidental venous air infusion in patients with persistent foramen ovale.<sup>20,21</sup> The minimum amount of air required to cause major or minor cerebral damage in the clinical setting is not known. In a rabbit model, 0.025 mL of air caused a transient decrease in cerebral flow, whereas 0.4 mL caused a sustained deterioration of brain function.<sup>22</sup> Other animal models have shown that cerebral effects from a standardized bolus can vary considerably within the same species,<sup>23</sup> and bubbles as small as 0.01–0.02 mm in diameter can cause disruption of the blood–brain barrier.<sup>24</sup> In the clinical setting, the diagnosis of cerebral air embolism has proved elusive since small bubbles are transient in the vasculature, are resorbed quickly, and are therefore a rare finding on CT, even in cases where there is strong clinical suspicion of air embolism.<sup>25</sup>

In EVAR for abdominal aortic aneurysms, with the patient in supine position during interventions, bubbles are probably directed upward into the anterior dome of the aneurysm and stay there due to their buoyancy. Once the endografts are excluding the aneurysm, the air is trapped in the sac. In TEVAR, the course of bubbles released is also probably affected by their buoyancy and by the pulsatile and turbulent flow in the proximal aorta. In contrast to abdominal aneurysms, thoracic aneurysms are usually located lower than the proximal extension of the endograft when the patient is supine on the operating table. In our experience, we have never seen images of air trapped post procedure in TEVAR-treated thoracic aorta.

So, where do the bubbles go? With the patient in supine position, the buoyancy of bubbles from endografts deployed in the arch may direct them upward into the supra-aortic vessels. Depending on the deployment mode for each particular endograft, there is usually a stage during deployment when the endograft has circumferential apposition against the aortic wall, but it is not yet fully released. During this stage, there is no antegrade flow in the aorta and bubbles released from the inside of the endograft have no choice but to escape through the supra-aortic vessels. Interestingly, this is also the stage in a TEVAR procedure when most embolic particles are recorded in the carotid or intracranial arteries with Doppler ultrasound.<sup>14</sup>

Endografts can be deployed by the retraction of an outer sheath, such as with Medtronic devices, or by the unlacing of a sewn constraining sleeve, such as with Gore devices. The tighter packing allowed by the soft and formable sleeve of the Gore system appears to be more efficient in minimizing trapping of air. Despite the fact that the Medtronic delivery system is flushed via a sidearm prior to use, we found larger

volumes of air released by Medtronic devices than from Gore devices. The amount of air released by endografts may be even larger for the new complex devices with fenestrations and/or branches, which are being developed specifically for the arch. These endografts may have more folds in the fabric and more dead space in their delivery system than the standard straight tubes.

The limitations of this study must be acknowledged. The model was developed with the sole purpose of determining whether air is released during endograft deployment, and no conclusions can be made regarding clinical consequences. Moreover, the exact size of released bubbles will also be affected by fluid pressure and temperature. However, air embolism can cause cerebral damage—and it is noteworthy that other large endovascular implants used upstream of the cranial vessels, such as aortic valves and heart septal occluders, are usually mounted in their delivery systems immediately before use, while submerged in saline. Perhaps these measures should also be considered for thoracic endografts, at least in those designed for the aortic arch.

Another limitation was the small number of endografts examined. Due to their high cost, we were only able to obtain and test eight endografts with two different delivery systems. The amount of air released varied somewhat between each endograft. The differences were two- to threefold even between endografts of the same brand and did not appear to be related to the diameters or the lengths. It can be speculated that preconditions for secluded pockets of air may be created randomly during the assembly process in the factory and that some endografts may in fact release even larger volumes than we found in our eight devices. To speculate further, this could possibly reflect the seemingly unpredictable risk of symptomatic stroke after TEVAR in approximately 1 in 25 patients, as reported in most large clinical trials.

## Conclusion

Air bubbles are released from thoracic stent grafts during deployment. The results suggest a hitherto unrecognized cause of stroke during TEVAR—that of air embolism.

## Declaration of conflicting interests

The author(s) declared no potential conflicts of interest with respect to the research, authorship, and/or publication of this article.

## Ethical approval

Ethical approval was not sought for this study because it is an *in vitro* experimental study and no patient is involved.

## Funding

The author(s) disclosed receipt of the following financial support for the research, authorship, and/or publication of this article: This study was supported by the Västra Götaland region (M.F., grant ALFGBG-218331).



## Informed consent

Informed consent was not sought for this study because it is an in vitro experimental study and no patient was involved.

## References

1. Ullery BW, McGarvey M, Cheung AT, et al. Vascular distribution of stroke and its relationship to perioperative mortality and neurologic outcome after thoracic endovascular aortic repair. *J Vasc Surg* 2012; 56(6): 1510–1517.
2. Kahlert P, Eggebrecht H, Janosi RA, et al. Silent cerebral ischemia after thoracic endovascular aortic repair: a neuroimaging study. *Ann Thorac Surg* 2014; 98(1): 53–58.
3. Azizzadeh A, Ray HM, Dubose JJ, et al. Outcomes of endovascular repair for patients with blunt traumatic aortic injury. *J Trauma Acute Care Surg* 2014; 76(2): 510–516.
4. DuBose JJ, Leake SS, Brenner M, et al.; Aortic Trauma Foundation. Contemporary management and outcomes of blunt thoracic aortic injury: a multicenter retrospective study. *J Trauma Acute Care Surg* 2015; 78(2): 360–369.
5. Mousa A, Dombrovskiy V, Haser PB, et al. Thoracic aortic trauma: outcomes and hospital resource utilization after endovascular and open repair. *Vascular* 2010; 18(5): 250–255.
6. Cindy M, Sabrina H, Kim D, et al. Traumatic aortic rupture: 30 years of experience. *Ann Vasc Surg* 2011; 25(4): 474–480.
7. Minami T, Imoto K, Uchida K, et al. Clinical outcomes of emergency surgery for acute type B aortic dissection with rupture. *Eur J Cardiothorac Surg* 2013; 44(2): 360–364.
8. Makaroun MS, Dillavou ED, Kee ST, et al. Endovascular treatment of thoracic aortic aneurysms: results of the phase II multicenter trial of the GORE TAG thoracic endoprosthesis. *J Vasc Surg* 2005; 41(1): 1–9.
9. Vallabhajosyula P and Szeto WY. Current paradigms in aortic arch repair: striking the balance between open surgery and endovascular repair. *J Thorac Cardiovasc Surg* 2015; 150(6): 1399–1400.
10. Lu Q, Feng J, Zhao Z, et al. Endovascular repair by customized branched stent-graft: a promising treatment for chronic aortic dissection involving the arch branches. *J Thorac Cardiovasc Surg* 2015; 150(6): 1631–1638.
11. Gutsche JT, Cheung AT, McGarvey ML, et al. Risk factors for perioperative stroke after thoracic endovascular aortic repair. *Ann Thorac Surg* 2007; 84(4): 1195–1200.
12. Feezor RJ, Martin TD, Hess PJ, et al. Risk factors for perioperative stroke during thoracic endovascular aortic repairs (TEVAR). *J Endovasc Ther* 2007; 14(4): 568–573.
13. Melissano G, Tshomba Y, Bertoglio L, et al. Analysis of stroke after TEVAR involving the aortic arch. *Eur J Vasc Endovasc Surg* 2012; 43(3): 269–275.
14. Bismuth J, Garami Z, Anaya-Ayala JE, et al. Transcranial Doppler findings during thoracic endovascular aortic repair. *J Vasc Surg* 2011; 54(2): 364–369.
15. Kölbel T, Rohlfes F, Wipper S, et al. Carbon dioxide flushing technique to prevent cerebral arterial air embolism and stroke during TEVAR. *J Endovasc Ther* 2016; 23: 393–395.
16. Muth CM and Shank ES. Gas embolism. *N Engl J Med* 2000; 342(7): 476–482.
17. Weiner MM, Wicker J, Fischer GW, et al. CASE 5–2015: early detection and treatment of an air embolism during cardiac surgery. *J Cardiothorac Vasc Anesth* 2015; 29(3): 791–796.
18. Wijman CA, Dase CS, Jacobs AK, et al. Cerebral air embolism as a cause of stroke during cardiac catheterization. *Neurology* 1998; 51(1): 318–319.
19. Markus H, Loh A, Israel D, et al. Microscopic air embolism during cerebral angiography and strategies for its avoidance. *Lancet* 1993; 341: 784–787.
20. Orebaugh SL. Venous air embolism: clinical and experimental considerations. *Crit Care Med* 1992; 20(8): 1169–1177.
21. Suri V, Gupta R, Sharma G, et al. An unusual cause of ischemic stroke: cerebral air embolism. *Ann Indian Acad Neurol* 2014; 17(1): 89–91.
22. Helps SC, Meyer-Witting M, Reilly PL, et al. Increasing doses of intracarotid air and cerebral blood flow in rabbits. *Stroke* 1990; 21: 1340–1345.
23. Weenink RP, Hollmann MW and van Hulst RA. Animal models of cerebral arterial gas embolism. *J Neurosci Methods* 2012; 205(2): 233–245.
24. Hills BA and James PB. Microbubble damage to the blood-brain barrier: relevance to decompression sickness. *Undersea Biomed Res* 1991; 18(2): 111–116.
25. Tsetsou S, Eeckhout E, Qanadli SD, et al. Nonaccidental arterial cerebral air embolism: a ten-year stroke center experience. *Cerebrovasc Dis* 2013; 35(4): 392–395.