

Endoscopic Papillectomy into the Treatment of Neoplastic Lesions of Vater Papilla

G. GHIDIRIM⁽¹⁾, I. MIȘIN⁽¹⁾, V. ISTRATE⁽¹⁾, S. CAZACU⁽²⁾

⁽¹⁾Department of Surgery "N. Anestiadi", Hepato- Bilio-Pancreatic Surgery Laboratory, University of Medicine and Pharmacy "N. Testemitsanu", Chișinău, Moldova; ⁽²⁾ Internal Medicine. Gastroenterology. Hepatology Department, University of Medicine and Pharmacy of Craiova, Gastroenterology Department – Emergency Hospital Craiova

ABSTRACT Adenomas of the duodenal papilla are rare. The frequency of malignant adenomas is 15-30%. Villous adenoma is a premalignant lesion with the highest rate of transformation. Options for surgical treatment include endoscopic and ablation resection, transduodenal ampullectomy, duodeno-pancreatectomy. **Aim:** Evaluation of the efficacy and safety of endoscopic papillectomy for ampullary adenomas. **Material and method:** 12 patients were selected (F:M, 5:7, age range 37 - 68 years) with ampullary adenoma, treated by endoscopic papillectomy. Biliary sphincterotomy was performed in 6 cases; and pancreatic sphincterotomy was performed in 3 cases. Biliary stenting was performed in 2 cases; pancreatic stent was placed in 11 cases. **Results:** En bloc resection was performed in 8 cases, and piecemeal resection in 4 cases. Complete resection R0 was noted in 10 cases. Pathology examination has show: tubulo-villous adenoma (5 patients); villous adenoma (4 patients), tubular adenoma (2 cases), adenocarcinoma (one case). Complications were immediate: bleeding (2 cases) and pancreatitis (1 case). Follow-up endoscopy reveals no ductal stenosis or recurrence. **Conclusion:** Endoscopic papillectomy is a safe and well-tolerated alternative to surgical treatment of ampullary adenoma.

KEY WORDS ampullary adenoma, Vater papilla, endoscopic papillectomy, bleeding, pancreatitis, sphincterotomy

Introduction

Papillary adenoma (PA) have a frequency of 0,04 to 0,12% relative to general population [1], have a malignant potential, in conformity to „adenoma-adenocarcinoma” succession [2], [3], [4], and are considered as precancerous lesions, presenting a malignisation ratio of approximate 30% [5].

The use of endoscopy, and especially of duodenoscopy and endoscopic retrograde cholangio-pancreatography (ERCP) has facilitated an early and frequent recognize of Vater papilla tumors in pre-infiltrative phase of evolution, with indications for minimally invasive, endoscopic treatment. [5], [6].

Pathology show often malignant tissue foci into the adenoma tissue [7], [8], so a complete resection of these lesions is very important. Minimally invasive procedures include endoscopic papillectomy (EP) and endoscopic ablation (argon-plasma, YAG-Nd laser, electro coagulation et al.) [8], [9]. The advantage of endoscopic resection (ER) is the accurate visual control into the surface and accurate pathology control in depth for the resection (R0), the entire piece or multiple fragments reconstruction being offered for pathology qualitative analysis [6], [7], [10]. For this moment, endoscopic approach for the evaluation and treatment of PA represent a viable alternative to classical surgery [8].

Aim of the study

The evaluation of efficacy and safety of endoscopic papillectomy (EP).

Material and method

From 1998 to 2008 we have diagnosed 17 (2%) neoplastic lesions of the Vater papilla during a total of 846 ERCP examinations. For EP 12 cases (1.42%) were selected (5 females and 7 males; age between 37 and 68 years). Clinical abnormalities were obstructive jaundice (12 cases), biliary colic (8 cases), cholangitis (1 case), and pancreatitis (2 patients). Two patients with PA were diagnosed after the visualization of ultrasonographic dilation of the biliary and/or pancreatic tree associated with no clinical symptoms. 4 patients have papillary tumor below 10 mm (**figure 1a**), 6 patients have a tumor between 10 and 19 mm (**figure 1b**), and two patients have the diameter of the tumor above 20 mm.

The selection was based by K. Binmoeller modified criteria (1993) [11]:

1. Lack of peri-papillary indurations and erosions;
2. The possibility of tumoral elevation by submucosal injection;
3. Lack of bilio-pancreatic duct involvement at a depth greater than 1.0 cm from papillary orifice (ERCP);

4. Tumoral diameter below 2.5 cm, extended below 1/3 of duodenal lumen.

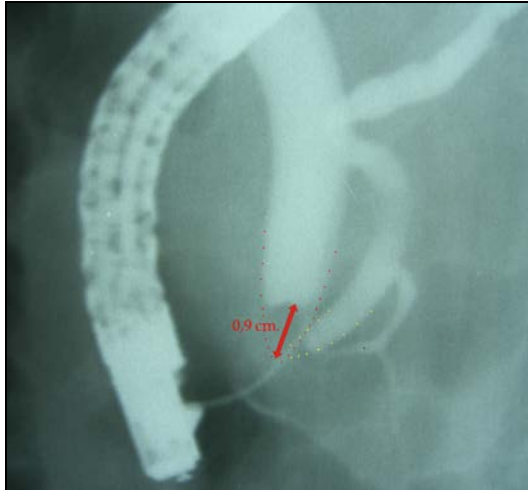


Figure 1a. Papillary adenoma with minimally ductal invasion diagnosed by ERCP (9 mm)

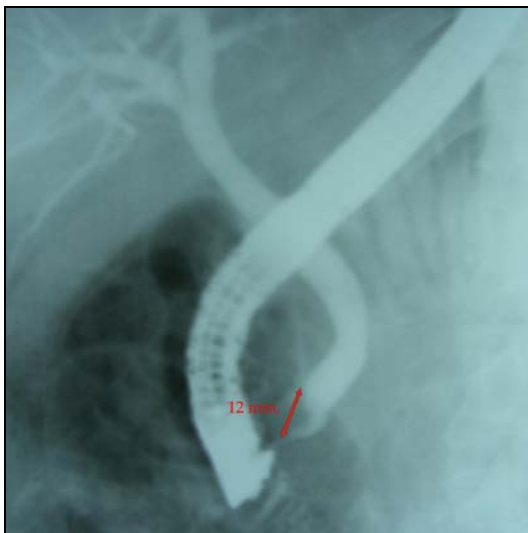


Figure 1b. Papillary adenoma with extended ductal invasion diagnosed by ERCP (12 mm)

For EP the duodenoscope JF-1T20 and TJF-130 (Olympus®, Tokyo) were used, we preferred an endoscope with 4,2 mm working channel, enough for adequate aspiration during the procedure, video guiding and documentation. EP was performed in all cases by using classical polypectomy snare (DPMS-1-15, Wilson-Cook®) or asymmetrical diathermic snare (PEA-Replacement snare crescendo 127-350-15, Paudrach, Germany) (**figure 2**). We are using electro-surgical device BARD system 3000 (USA) (regimen cut. Blendmax, output power 60 W) and Olympus PSD 2E (regimen Blend cut, 60 W). Resected fragments were immediately retired into the stomach and collected after that by using an endoscopic Roth-Net or Dormia basket. Smaller fragments were aspirated by endoscope channel

and were collected into polyp trap, attached at aspiration tube.

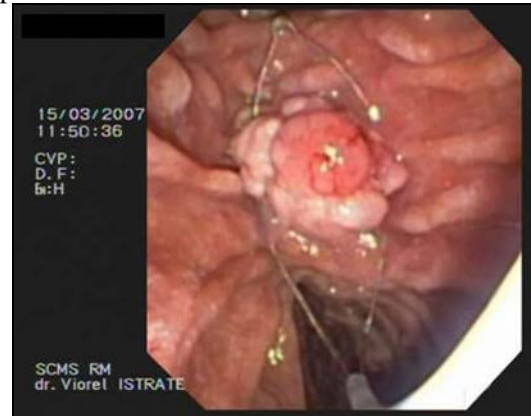

Figure 2 Papillary tumor, diathermic snare used for EP

The cannulation and sphincterotomy (ST) were performed using a KD-6G11Q-1 OLYMPUS papillotoma and Pauldrach Zebra guide wire, 0,035 with a length of 4000 mm). We are using also biliary stents Wilson-Cook® (9-11 Fr. 12 to 14cm), pancreatic stents Wilson-Cook®, (4-7Fr. 4 to 5cm) for plastic material, with lateral holes and flanges. Submucosal lift was performed with a needle OLYMPUS NM-1K and solutions: NaCl 0.9% with Adrenalin 1:10000; Human Thrombin 125 U/5.0 ml NaCl 0.9%. In case of bleeding haemostatic clips OLYMPUS HX-200U-135 were used (**figure 3**).

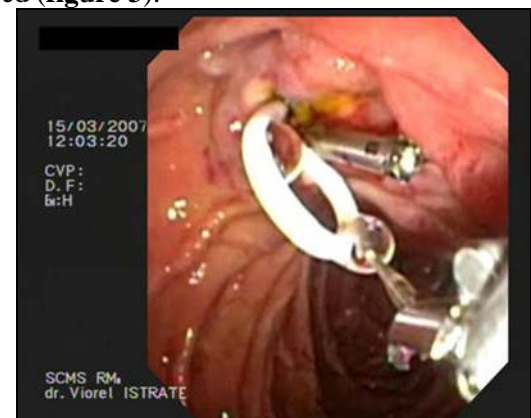


Figure 3 Papillary site after EP, haemostatic clip placed for bleeding control, stent placed into the Wirsung duct

Ampullary tumors were classified using Vienna classification of the epithelial gastrointestinal neoplasia [12] as: non-invasive with low-grade dysplasia (LGD), non-invasive with high-grade dysplasia (HGD), invasive neoplasia (AC).

The result was characterized in general parameters:

Endoscopic therapeutic success was defined by complete excision of the lesion, regardless of

number of necessary sessions, and by the absence of tumoral recurrence or a single recurrence during monitoring period, which was successfully treated by endoscopy.

Endoscopic therapeutic failure was defined by lack of complete elimination of the lesion, regardless of session's number, by surgically treated recurrences or by discovery of carcinoma above mucosal layer.

Complications of EP were noted as early (pancreatitis, bleeding, perforation) and late (post-papillectomy stenosis).

The technique of the procedure (figure 4): Immediately before EP we performed submucosal fluid injection, similarly to another endoscopic mucosectomy. The volume of the fluid had individual variations (from 5.0 to 15.0 ml) depending to the diameters of the tumor and another local anatomical factors, by visual control, without permitting the retraction of the papilla inside the submucosal fluid mass formed by injection. In some cases (n=2) of piecemeal EP submucosal staged lift was necessary. Submucosal lift is very useful especially in case of flat adenoma resection with superficial para-papillary spreading. Non-lifting effect has appeared in case of tumoral invasion of muscularis propria and was a contraindication for therapeutic EP (one case).

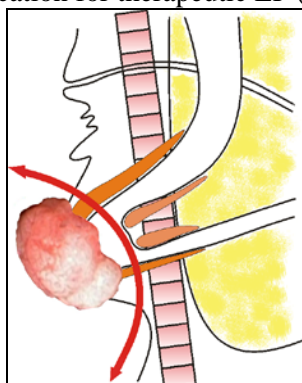


Figure 4 Scheme of EP

The orientation of the snare was: cranial (8 cases), caudal (3 cases), and oblique (one case). We have appreciate as more convenient and we have used more frequently (66.7% of cases), cranial orientation of the snare in EP. Cases with intraductal invasion (3 patients) confirmed by ERCP have necessitate trans-tumoral biliary or associated (biliary and pancreatic) sphincterotomy. Curative resection was decided if the tumor was fully accessible (2 cases) after sphincterotomy and was performed with smaller dimensions snare, with piecemeal technique, after a standardized numbered of the fragments. After EP the fragments were reunited and fixed by

needles to piece of cork, and send to pathology examination.

For a resection of mobile sessile adenoma, in case of a retracted papilla, we have successfully used an original resection technique with diathermic snare assisted by intraductal balloon-catheter (Figure 5).

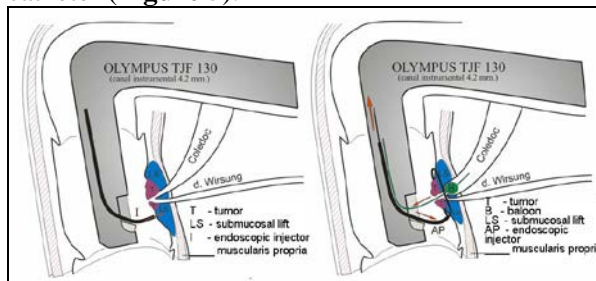


Figure 5 Endoscopic papillectomy assisted with endo-biliary balloon-catheter

Selective cannulation, with catheter over an atraumatic guide wire, is easy in most cases (figure 6a). For the cannulation of Wirsung duct, pancreatography before EP with Urographin colored with Methylene blue was especially useful (7 cases).

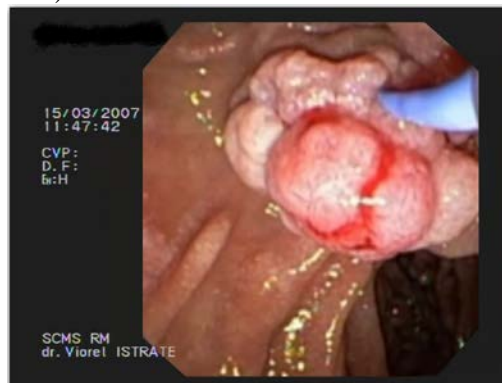


Figure 6a Papillary tumor, cannulation of the Wirsung duct

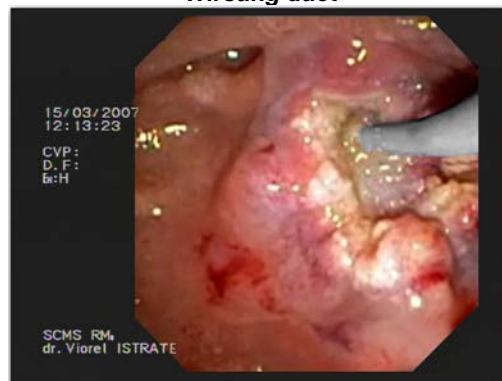

Figure 6b Papillary site after EP, stent placed into the Wirsung duct

In case of difficult cannulation, intravenous administered Buscopan may be also useful (2 patients). We have performed biliary and pancreatic sphincterotomy with the purpose of obtaining an optimal bilio-pancreatic drainage and for optimizing post-EP stenting. Pancreatic

sphincterotomy and temporary stenting can maintain the permeability of Wirsung duct and therefore reduces the risk of acute pancreatitis after this procedure [13], [14] (**figure 6b**). The stenting of Wirsung duct permit also a safer use of adjuvant coagulation methods, of endoscopic haemostatic clips and seems to minimize the risk of ductal stenosis after EP [14], [15], [16], (**figure 3**). The indication for biliary stenting was the cases when complementary sphincterotomy didn't permit to obtain a satisfactory drainage (considering also the possible early edema of adjacent tissue after EP), and a longer incision may risk a duodenal perforation.

Results

All interventions were performed during one stage. We succeed *en-bloc* EP in 8 cases (**figure 7a**). Piecemeal resection (4 cases) was performed is case of superficial spreading of the tumor to a diameter above 1.5 cm or in case on minimally intraductal invasion of the tumor (ERCP; sphincterotomy).

Biliary stenting was performed in 2 cases (one case with invasive ampullary carcinoma, for biliary decompression before surgery, and another case after snare resection of intra-choledocal invasion and bipolar electro-ablation of the resection area), with biliary stent 9Fr and 11Fr, for 10 and 14 days respectively, until the ERCP was repeated, residual tissue being excluded and biliary drainage being appreciated as satisfactory. Prophylactic pancreatic stenting was performed in 10 cases. In a case (with pancreatic ductal radiology appreciated as non-deregulated) without stenting acute pancreatitis was noted in the late period after EP. Median period for *in situ* pancreatic stent was 14 days. The essential criteria for stent extraction were complete epithelisation of the wound after EP. In cases (8) with concomitant choledocolithiasis the extraction of the calculus was possible after EP with Dormia basket in 4 cases with lithiasis below 1.0 cm. In the rest of 4 cases extraction was possible only after maximal biliary sphincterotomy. Biliary and pancreatic sphincterotomy open both ampullary area and may ease into the future the surveillance of this area, especially in case of recurrence, facilitating in this case repeated resection techniques.

The pathology after EP has show: tubulo-villous adenoma (TVA) - 5 patients; villous adenoma (VA) – 4 patients (with an area of in situ adenocarcinoma at one patient), tubular adenoma (TA) – 2 patients, adenocarcinoma (AC) – 1 patient.

Table 1. Succes EP, failure of EP, endoscopic complications after EP.

Tumoral growth	Success EP no (%)	Failed EPNo (%)	Endoscopic complications
Extraductal growth (n = 9) or minimal intraductal growth (n = 2)	10 (83,3)	1 (8,3)	Acute pancreatitis 1 Bleeding 2
Intraductal excessive growth (n = 1)	-	1(8,3)	-
Total (no=12	10(83,3)	2(16,6)	3(24,9)

The following endoscopic and pathological correlation was noted: in 6 cases of non-invasive neoplasia associated with low-grade dysplasia 2 were AT, 3 were TVA, and one was VA; in 5 cases of non-invasive neoplasia with high-grade dysplasia 2 patients have TVA (**figure 7b**) and 3 have VA (including one case of VA with an area of AC *in situ*). All cases cited before have minimally intraductal or extraductal growth. In a case with extensive intraductal growth, pathology has show adenocarcinoma.

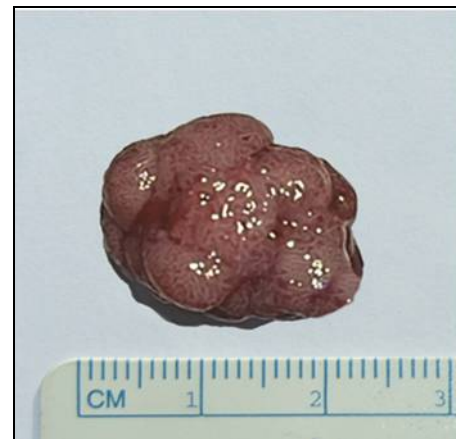

Figure 7a Post-EP specimen

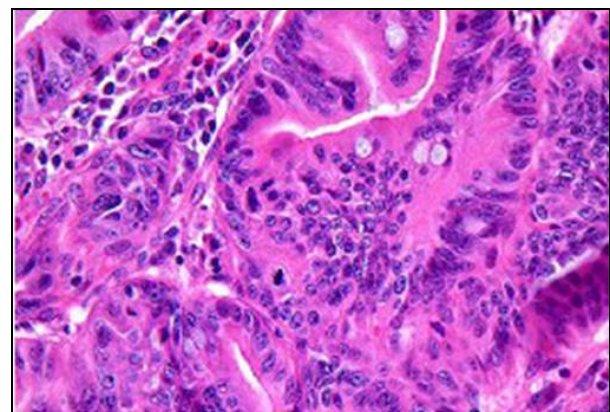


Figure 7b Pathology- tubulo-villous adenoma with high-grade dysplasia (HE stain, 400 x magnification)

After EP, in one case with adenocarcinoma and extensive intraductal growth (at maximal

sphincterotomy of 16mm, with margins of the intraductal invasion being not visualized) pancreaticoduodenal resection Kausch-Whipple was necessary. In another case of minimal intraductal growth, 0.7 cm approximate on distal choledocus, well visualized, after sphincterotomy the neoplasia was piecemeal resected. Pathology has show an area with adenocarcinoma (*in situ*) in a villous adenoma with high grade dysplasia, resection borders being unsafe (R1), transduodenal adjuvant surgical ampullectomy being therefore decided. Therapeutic endoscopic failure was therefore appreciated at 16.6 %.

In another case of TVA with low-grade dysplasia with intra-choledocal growth at 0.9 cm segment, after sphincterotomy a piecemeal resection (4 fragments) was performed, and intraductal surface after resection was treated by electro coagulation. For 10 patients, EP was curative (endoscopic therapeutic success 83.4%), pathology has show R0 resection and after 3 - 24 months with no recurrences. We didn't note intraductal Wirsung growth.

Early complications were: moderate bleeding - 2 cases (haemostasis: 1- by endoscopic clips, 1- local injection of Human Thrombin solution), and acute pancreatitis after EP in one case. After endoscopic follow-up 9 patients were available (3 - 24 months): we didn't noted ductal stenosis or tumoral recurrence.

Discussions

The safety and accuracy of EP in ampullary adenoma are argued in several studies [8], [9], [14], [16], and [17]. Success ratio in EP varied from 60% [18] to 80% [16]. In our series we have obtained a success ratio of 83.3%. The complications ratio was 8% (one case) for acute pancreatitis after EP and 16 % for controlled bleeding during EP, similar to literature data. We considered as an important factor, for bleeding prevention, the use of Human Thrombin into the solution for submucosal lifting. In our patients, when we use Human Thrombin we didn't noted any bleeding.

Although we excluded from our study all tumors with endoscopic stigmata of malignancy, we noted invasive adenocarcinoma in one case and in another case of villous adenoma D2 type with high grade dysplasia an area with adenocarcinoma *in situ*. Literature data showed pathological diagnosis using forceps-biopsy, may imply false negative results of tumor in up to 15% of cases [19], [20]. Endoscopic forceps-biopsy, even after sphincterotomy, has been proved unsafe

into the diagnosis of benign VPT from invasive carcinoma [19].

Table 2. Compared results of endoscopic treatment.

Authors	No. of patients	Pathology	Recurrence rate	Follow-up months	Morbidity	Mortality
SM Yoon et al., 2007 [17]	16	10 HGin/Tis 6 T1s	0%	18(HG in/Tis) 29 (T1)	0%	0%
Desilets et al., 2001 [16]	13	12 LGD 1HGin/Tis	0%	19	8%	0%
Saurin et al., 2003 ^a [15]	24	10 LGD 14HGin/Tis	6.2%	66	29.1%	0%
Catalano et al., 2004 [13]	103	83 LGD 14 HGin/Tis 6T1(surgery)	20%	36	9.7%	0%
Cheng et al., 2004 [11]	55	38 LGD 7 HGin/Tis 5 others ^b	33%	30	14.6%	0%
Our study	12	6 LGD 4 HGD 1 ACis 1 AC	0%	3-24	0%	0%

^a Endoscopic distruction methods (argon plasma, YAG-Nd laser).

^b Carcinoid (no=2); normal pathology (no=2); gastric heterotopia (no=1).

LGD – low grade dysplasia.

HGIN/Tis: intraepithelial neoplasia high grade dysplasia / in situ tumor.

En bloc resection of the lesion can realize optimal conditions for pathology examination and appreciation of the integrity of resection borders. But, lesions greater than 1.5 cm must be "piecemeal" resected for minimizing the risk of perforation. Circular peritumoral dissection (Isotome 02-12-81 Pauldrach) of the mucosa before EP (1 case) generate absolute safe resection into the surface but seems to have a greater risk of duodenal perforation in case of insufficient submucosal lifting.

Therapeutic modalities in case of vaterian non-invasive carcinoma and in case of orifice (biliary and/or pancreatic) invasion remain to be discussed. The treatment of non-invasive carcinoma of Vater papilla (T1 in TNM classification and D0-D1 in Japanese Classification) has today a new approach, EP being considered in many cases [8], [10], and [20].

Tumoral extension into the biliary or pancreatic orifices was long time considered as contraindication for curative EP, but this principle seems to be changed in cases with minimally

invasion and in parallel with endoscopic equipment upgrade.

Endoscopic ultrasound and especially intraductal miniprobe technique may be especially useful [19], but unfortunately we didn't have these possibilities.

In our opinion, limited technical possibilities and knowledge must suggest duodeno-pancreatectomy and surgical ampullectomy as main techniques, but in case of adequate equipment endoscopic procedures must be implemented and used.

Conclusions:

Endoscopic papillectomy represent a minimally invasive alternative to surgical treatment of intra-epithelial neoplasia of Vater papilla.

The main indication for EP is benign tumor resection.

Mono-bloc resection is "gold standard" in EP.

Stent placement into the pancreatic duct represents a recommended prophylactic technique for acute pancreatitis.

References

- Pandolfi M., Martino M., Gabrielli A. Endoscopic Treatment of Ampullary Adenomas. JOP. J Pancreas. 2008;9(1): 1-8.
- Stolte M., Pscherer C. Adenoma-carcinoma sequence in the papilla of Vater. Scand J Gastroenterol 1996; 31(4):376-82.
- Gouma DJ., Obertop H., Vismans J. et al Progression of a benign epithelial ampullary tumor to adenocarcinoma. Surgery 1987;101(4):501-4.
- Kaiser A., Jurowich C., Schonekas H., Gebhardt C., Wunsch PH. The adenoma-carcinoma sequence applies to epithelial tumors of the papilla of Vater. Z Gastroenterol 2002; 40(11):913-20.
- Scifert E., Schutle F., Stolte M. Adenoma and carcinoma of the duodenum and papilla of Vater: a clinicopathologic study. Am J Gastroenterol 1992; 87(1):37-42.
- Katsinelos P., Paroutoglou G., Kountouras J, et al. Safety and long-term follow-up of endoscopic snare excision of ampullary adenomas. Surg Endosc. 2006 20 608-613.
- Barthet M. Ampullectomie endoscopique. 26e Journées Nationales de Formation Continue en Hépatogastro-entérologie 2008; 215-219.
- Menzel J, Poremba C, Dietl KH et al. Tumors of the papilla of Vater - inadequate diagnostic impact of endoscopic forceps biopsies taken prior to and following sphincterotomy. Ann Oncol 1999; 10(10): 1227-31.
- Boix J., Lorenzo V., Moreno V., Gassull M. Endoscopic resection of ampullary tumors: 12-year review of 21 cases. Surg Endosc. 2009; 23(1) 45-49.
- Singh P., Das a., Isenberg G., et al. Does prophylactic pancreatic stent placement reduce the risk of post-ERCP acute pancreatitis? A meta-analysis of controlled trials. Gastrointest Endosc 2004; 60(4): 544-50.
- Cheng CL, Sherman S., Fogel EL., et al. Endoscopic snare papillectomy for tumors of the duodenal papillae. Gastrointest Endosc 2004; 60(5): 757-64.
- Zadorova Z, Dvofak M, Hajer J., Endoscopic therapy of benign tumors of the papilla of Vater. Endoscopy. 2001;33(4):345-7.
- Catalano MF, Linder JD, Chak A. et al. Endoscopic management of adenoma of the major duodenal papilla. Gastrointest Endosc. 2004;59(2):225-32.
- Schlemper RJ, Riddell RH, Kato Y, Borchart F, Cooper HS, Dawsey SM, Dixon MF, Fenoglio-Preiser CM, Fle'jou JF, Geboes K, Hattori T, Hirota T, Itabashi M, Iwafuchi M, Iwashita A, Kim YI, Kirchner T, Klimpfinger M, Koike M, Lauwers GY, Lewin KJ, Oberhuber G, Offner F, Price AB, Rubio CA, Shimizu M, Shimoda T, Sipponen P, Solcia E, Stolte M, Watanabe H, Yamabe H The Vienna classification of gastrointestinal epithelial neoplasia. Gut, 2000; 47(2):251-5.
- Saurin JC, Chavaillon A, Napoleon B. et al. Long-Term Follow-Up of Patients with Endoscopic Treatment of Sporadic adenomas of the papilla of Vater. Endoscopy 2003; 35(5): 402-6.
- Desilets DJ, Dy RM, Ku PM, et al. Endoscopic management of tumor of the major duodenal papilla: refined techniques to improve outcome and avoid complications. Gastrointest Endosc 2001;54(2):202-8.
- Yoon SM, Kim MH, Kim MJ, Jang SJ, Lee TY, Kwon S, et al. Focal early stage cancer in ampullary adenoma: surgery or endoscopic papillectomy? Gastrointest Endosc 2007; 66(4):701-7.
- Binmoeller KF, Boaventura S, Ramsperger K, Soehendra N. Endoscopic snare excision of benign adenomas of the apila of Vater. Gastrointest Endosc, 1993; 39(2): 127-31.
- Martin JA, Haber GB, Kortan PP, Rajjman I et. Al. Endoscopic snare ampullectomy for resection of benign ampullary neoplasms [abstract]. Gastrointest Endosc 1997; 45: AB458.
- Lee SY, Jang KT, Lee KT et al. Can endoscopic resection be applied for early stage ampulla of Vater Cancer. Gastrointest Endosc, 2006; 63(6): 783-88.

Correspondence Adress: Prof. G. Ghidirim, MD, PhD, Department of Surgery "N. Anestiadi", Hepato- Bilio-Pancreatic Surgery Laboratory, University of Medicine and Pharmacy "N. Testemitsanu", Chişinău, Moldova
